LANE MEDICAL LIBRARY STANFORD
2 45 0061 3303



DISEASES

OF THE

NOSE, THROAT AND EAR

MEDICAL AND SURGICAL

BY

WILLIAM LINCOLN BALLENGER, M.D.

PROFESSOR OF OTOLOGY, RHINOLOGY AND LARYNGOLOGY, COLLEGE OF PHYSICIANS AND SURGEONS, DEPARTMENT OF MEDICINE, UNIVERSITY OF ILLINOIS; FELLOW OF THE AMERICAN LARYNGOLOGICAL ASSOCIATION; FELLOW OF THE AMERICAN LARYNGOLOGICAL, RHINOLOGICAL AND OTOLOGICAL ASSOCIATION; FELLOW OF AMERICAN ACADEMY OF OPHTHALMOLOGY AND OTOLARYNGOLOGY, ETC.

ILLUSTRATED WITH 471 ENGRAVINGS AND 16 PLATES

LEA & FEBIGER

PHILADELPHIA AND NEW YORK

1908

PREFACE.

A NEW work, superadding itself to the already rich literature on the nose, throat, and ear, should justify its creation by some special features which may claim the attention of students and practitioners. Accordingly it may be said of the present volume, in the first place, that it includes the whole range of these three subjects, instead of dealing fully with the nose and throat, and only with the associated affections of the ear. It is no longer necessary to explain the advantages of considering these closely interrelated subjects together, since, obviously, they cannot be considered separately without missing most important connections. The relation of the eye to diseases of the sinuses is also introduced, though the significance of its relationship is not yet fully understood.

Moreover, our knowledge of the inflammatory diseases of the nose and accessory sinuses, and of the throat and ear, has been increasing with such strides that the time seems to have arrived for presenting the subject on a new and higher plane. The causes of infection and inflammation of the cavities lined with mucous membranes are better understood, and it has accordingly become possible to give them in their true relation to the diseases. Instead of their mere enumeration, each has been discussed here with the purpose of showing its exact relation to the disease under consideration. The exciting causes are pathogenic bacteria, while the predisposing causes are those extranasal and intranasal conditions which lower the resistance of the tissues. The numerous extranasal causes of infection and inflammation of the cavities of the nose and accessory sinuses have long been recognized. The intranasal causes of chronic inflammation of these cavities have not, however, been as well understood. The attempt has been made to show the effects of anatomical and pathological obstructions in the various portions of the nasal chambers upon chronic catarrhal inflammations of the nose, and upon chronic catarrhal and suppurative inflammations of the accessory sinuses. The advantage of this viewpoint is that it affords a more satisfactory explanation of the etiology and rationale of the treatment of infections and inflammatory diseases of all three regions.

The author has long believed that surgical technique could be most clearly elucidated by describing each step of the various operations in numbered paragraphs, and by complementing them with suitable drawings. Nearly every operation is therefore illustrated, some with more than twenty drawings. About five hundred original drawings and plates have been thus used in the preparation of this work. The original sketches were made by the author, and were redrawn by Mr. James Kelly Parker, to whose intelligent coöperation much credit is due, and is gratefully acknowledged. An endeavor has been made to combine the advantages of a text-book and atlas, and, it is hoped, with a measurable degree of success.

Tracheobronchoscopy and esophagoscopy have been brought to such a high degree of perfection, and the occasions for their employment are so numerous, that a fully illustrated chapter is devoted to their consideration.

Before beginning this work, the author wrote to many of the leading specialists in the United States, England, France, Germany, Austria, Spain, Italy, Holland, Switzerland, Canada, and Russia, asking for reprints of their published articles. The response was most generous, and resulted in the accumulation of nearly three thousand monographs, which have been freely used in the preparation of this volume. With every wish to name each one who so liberally responded, it is obviously impracticable in a work of this character. The author has, however, endeavored to give due credit in the text for writings consulted. A debt of gratitude is also due to colleagues who have so graciously contributed to whatever of success this volume may attain.

Grateful appreciation is also due to Dr. George F. Suker, Dr. Joseph C. Beck, and Dr. Mortimer Frank for their assistance in translations, and in the compilation of the material used in portions of the text, and also to Dr. Henrietta Gould and Miss Mary Regan for efficient attention to many minor but important details.

Finally, to the publishers, with whom he has maintained most cordial relations, the author expresses his thanks, not only for the physical appearance they have given to his work, but also for many valuable aids and suggestions, which have both lightened and added confidence to his labors.

W. L. B.

103 State Street, Chicago.

CONTENTS.

PART I.

THE NOSE AND ACCESSORY SINUSES.

PART II.

THE PHARYNX AND FAUCES.

PART III.

DISEASES OF THE LARYNX

PART IV.

THE EAR.

DISEASES OF NOSE, THROAT, AND EAR.

PART I.

THE NOSE AND ACCESSORY SINUSES.

CHAPTER I.

THE CLINICAL ANATOMY AND PHYSIOLOGY OF THE NOSE AND ACCESSORY SINUSES.

THE NOSE.

The Nasal Chambers.—The nose is divided, by the nasal septum, into two chambers, the right and the left. The nasal chambers are for respiratory, olfactory, phonatory, and gustatory purposes. The inspiratory current passes upward from the vestibules to the middle and superior meatuses, and is thence deflected downward and backward by the middle turbinals and the roof of the nose to the choanæ, and on into the epipharynx. The expiratory current is deflected from the vault of the epipharynx into the choanæ, and thence forward through the middle and inferior meatuses to the vestibules of the nose.

The practical clinical application of the foregoing facts lies in the different effects of stenosis in the inferior and in the superior portions of the nasal chambers. An obstructive deformity of the lower portion of the septum may interfere somewhat with the expiratory current, as it blocks the inferior meatus while the middle and superior meatuses are free, and the expiratory current, therefore, passes through the nasal chamber upon the obstructed side with but little or no impediment. The obstruction in the lower portion of the nasal chamber does not materially interfere with the inspiratory current, as its course is normally higher in the nasal passage. There are exceptions, however, to this rule. If, for example, the deformity of the septum extends well forward into the vestibule of the nose it will materially interfere with the respiratory current, as it blocks the entrance to the nose.

The indications for the correction of an obstructive lesion of the inferior portion of the septum depend very largely upon whether or not

it blocks the vestibule of the nose. If it does, its correction is positively indicated; if it does not, the indications for its correction are not so clear. If, however, it impinges upon the inferior turbinal, it may produce a sense of "stuffiness," or of a foreign body in the nose, and cause the patient to "sniff and blow" in the effort to relieve the disagreeable sensation. It may, in addition to the foregoing, cause mechanical irritation of the mucous membrane of the inferior turbinal, and cause it to become engorged with blood, thereby increasing the obstruction of the inferior portion of the nasal chamber upon the affected side.

When the obstructive lesion blocks the vestibule of the nose the entrance of the inspiratory current of air is materially interfered with. The descent of the diaphragm increases the air space in the lungs, and, according to a law of physics, the air from without tends to "rush in" to fill the vacuum thus created. The presence of the obstruction in the vestibule prevents its speedy entrance, and there is, therefore, a state of negative pressure in the nasal chamber—indeed, in both chambers, as their combined space is not sufficient to accommodate the required volume of air. The negative pressure or partial vacuum thus created results in a hyperemia of the mucous membrane of the nose and accessory sinuses. That is, the blood is attracted to the parts wherein there is a state of negative pressure. In addition to the hyperemia there is a greater or less transudation of serum into the loose submucous tissue. This condition is known as chronic rhinitis with turgescence. If the turgescence is perpetuated sufficiently long, true hypertrophy of the mucous membrane occurs. This is known as hypertrophic rhinitis.

It appears, therefore, that obstructions located in the inferior and anterior portions of the nasal chambers are of considerable clinical importance, though not of as great importance as obstructive lesions located higher in the nose, as we shall attempt to show in the following paragraphs.

When the upper portion of the nasal chamber is obstructed the path of the inspiratory current of air is blocked to a notable degree, and there is a sense of pressure through the upper portion of the nose. In addition to this the olfactory fissure is closed and the drainage of the secretions from the superior meatus and the accessory sinuses draining into it (the posterior ethmoidal and sphenoidal) is interfered with. The secretions are retained, undergo decomposition, and irritate the mucous membrane in this region. Chronic inflammation results. The epithelium is lowered in vitality, and is, therefore, less able to perform its functions of elaborating the mucus of the normal secretion and of propelling it to the choanæ by means of its ciliæ.

The irritation thus set up produces tissue proliferation or hyperplasia of the mucous membrane of the middle turbinal. This condition is known as hyperplastic rhinitis.

The foregoing conditions are favorable for pathogenic infection; hence, suppurative inflammation of the mucous membrane of the nose and accessory sinuses may develop. This condition is known as sinuitis.

It appears, therefore, that when the upper portions of the nasal chambers

are obstructed, there is not only a disagreeable sense of pressure across the bridge of the nose, but inflammatory diseases of the accessory sinuses may arise. One who has seen many of these cases knows how difficult it often is to thoroughly eradicate the sinus disease when it is thoroughly established in several of the sinuses, hence the importance of recognizing the clinical importance of obstructive lesions in the region of the middle turbinated body. This region is elsewhere described as the "vicious circle" of the nose.

The sinus labyrinth is so extensive, and much of it so inaccessible to actual inspection, that a complete effacement of morbid processes in them is often quite difficult except after the most complete exenteration of the sinuses, and especially of the ethmoidal sinuses.

The Septum.—This subject is fully discussed in connection with the deformities and malformations of the septum.

The Turbinated Bodies.—The turbinated bodies, three in number, are located upon the outer wall of the nasal chambers, and are known as the inferior, middle, and superior turbinated bodies. Only the inferior and middle are of clinical importance. These are characterized by the presence of venous plexuses in the submucous tissue of the membrane known as "swell bodies," or as the erectile tissue of the nose. The erectile tissue is chiefly distributed along the inferior border of the inferior turbinal, and on the posterior ends of the inferior and middle turbinals. Its function is supposed to be that of warming the inspired air and of regulating the amount of serous secretion. Either process is of vital importance to the lower respiratory tract. The lower respiratory tract does not secrete enough moisture for physiological purposes (protective), nor is it capable of warming the inspired air sufficiently to bring it to the body temperature without injury to its mucous membrane. It is important that the heating and humidifying apparatus of the nose should be in good physiological condition. When, therefore, the vasomotor nerves regulating the erectile tissue are disturbed in their function, the preparation of the inspired air for the lower air tract is imperfectly performed. The lower air tract is exposed to the irritating influence of the inspired air, and irritation of the lining mucosa and of the endothelial cells lining the air vessels of the lungs may result in a bronchitis, while the transfusion of the gases, oxygen and carbon dioxide, may be disturbed in the air vesicles. The processes of tissue metabolism or the chemistry of nutrition are perverted.

In addition to the foregoing conditions resulting from the disturbed functions of the "swell bodies," the patient may experience either a sense of "stuffiness" of the nose or of a foreign body, or the reverse, an unduly open nose. If, for instance, there is an anterior or vestibular obstruction from any cause, the negative pressure thus brought about causes an engorgement of the "swell bodies," with the resultant disagreeable symptoms already described. This condition is known as rhinitis with turgescence. If, on the contrary, the patient is anemic, the swell bodies may become collapsed and the nasal chambers unduly patulous. This condition is known as rhinitis with collapse of the erectile

tissue. The turbinated bodies are of clinical interest, for the further reason that they divide the nasal chambers into three partial chambers or meatuses. The inferior meatus is the space between the floor of the nose and the inferior turbinal. The middle meatus is the space between the inferior and middle turbinals. The superior meatus is the space above the middle turbinal. The meatuses are of great clinical interest on account of the accessory nasal sinuses opening into them.

The Meatuses.—The inferior meatus is of clinical importance, as the nasal orifice of the tear duct opens in its anterior portion (Fig. 165), and because it is a part of the expiratory air tract.

The Middle Meatus.—The middle meatus is of great clinical importance because the frontal, anterior ethmoidal, and the maxillary sinuses open into it. The frontal and the anterior ethmoidal cells drain into the infundibulum in 50 per cent. of the cases. The bulla ethmoidalis and the cells in the middle turbinal (Fig. 140) do not drain into the infundibulum, but open directly into the middle meatus. The bulla is often quite large and bulges so much toward the septum that it encroaches upon the infundibulum, entirely obstructing it. It thereby interferes with the drainage of the frontal maxillary and the anterior ethmoidal cells. The cells opening into the middle meatus are referred to for convenience as Series I.

When pus is present in the middle meatus it is significant of empyema of one or more of the cells comprising Series I, namely, the frontal sinus, the anterior ethmoidal, and the maxillary sinuses (antrum of Highmore).

The Superior Meatus.—The superior meatus is of clinical interest because the posterior ethmoidal and the sphenoidal cells (Series II) open into it. This meatus cannot be directly inspected on account of its hidden position above the middle turbinal. It can, however, be examined with a probe. When pus flows into it from the posterior ethmoidal and sphenoidal sinuses, and the olfactory fissure is not completely closed, it may be seen lying between the septum and the middle turbinal (the olfactory fissure). Pus in this region is, therefore, of great clinical value in making a differential diagnosis as to which series of sinuses is involved in the suppurative process.

The superior meatus is of still further clinical interest because the terminal filaments of the olfactory nerve are distributed there. Formerly it was held that the olfactory nerve was distributed over the superior turbinal and the upper and median surfaces of the middle turbinal and the corresponding portion of the septum. Recent anatomists have found its area of distribution restricted to the superior turbinal and a correspondingly small area of the septum (Fig. 5). In some of the lower animals its distribution is over a much larger area, and in those with a very acute sense of smell, into the accessory nasal sinuses.

The Sinuses' Residual Organs.—The nasal accessory sinuses in man are the residual remains of the olfactory organ, hence they have a low recuperative power after operations. I have repeatedly observed the slow and sometimes incomplete repair after operations even after the

most thorough exenteration, especially of the ethmoidal cells. I attribute this to the fact that the structures in man have ceased to perform the function they were originally designed to do. Through long ages of retrogression the tissues have lost some of their vitality and do not regenerate with the same vigor that is manifested by structures still performing their functions.

The Nerve Supply of the Nose.—The Sensory Nerves.—The sensory nerves of the nasal septum, the N. ethmoidalis anterioris and the N. nasopalatinus, send their filaments to the anterior and posterior portions of the septum, respectively. The N. ethmoidalis anterioris passes through the anterior portion of the cribriform plate (Fig. 1), thence forward and downward to the vestibule. The N. nasopalatinus extends forward and downward on the septum to the canalis incisivus, anastomoses with that of the other side and with the vessels of the mucous membrane of the hard palate.

FIG. 1

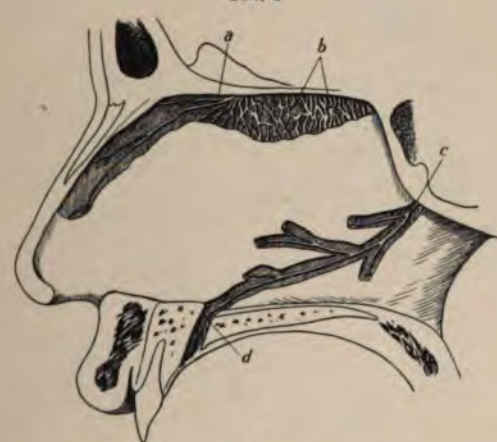

Nerve supply of the septum nasi. *a*, N. ethmoidalis anterioris; *b*, N. olfactorii; *c*, N. nasopalatinus; *d*, canalis incisivus. (After Spalteholz.)

The sensory nerve supply of the outer walls of the nose is derived from the N. ethmoidalis anterioris and from branches of the ganglion sphenopalatinum. The N. ethmoidalis anterioris supplies the anterior portion of the lateral walls in front of the turbinated bodies, and the turbinated bodies are supplied by branches of the sphenopalatine ganglion (Fig. 2). The hard and soft palates are also supplied from this ganglion. These anatomical facts may be utilized in injecting cocaine for anesthetic purposes (Killian) and in injecting alcohol in the treatment of hyperesthetic rhinitis (O. J. Stein).

Vasomotor branches are also supplied to the vessels of the mucous membrane and erectile tissue of the turbinated bodies from the ganglion sphenopalatinum, and is under the control of the vasomotor centres of the medulla, when there is probably a connection with the nuclei of the vagus through association fibers (Watson Williams).

The distribution of the accessory nerves over the septum and the outer walls of the nose, and especially the branches from the sphenopalatine ganglion over the turbinals, at once suggests the reason for the sensitiveness of these areas when the mucous membrane is inflamed, or is so swollen that it impinges against the septum. It also suggests the reflex phenomena, as asthma, often observed when there is inflammation or other disease in these regions. The association fibers, referred to above, connecting the sphenopalatine ganglion with the vagus establish a physiological relationship between the upper and the lower respiratory tracts, hence the asthma of nasal origin. I have repeatedly seen cases in which the asthma promptly disappeared after the removal of nasal polypi, or after an exenteration of the ethmoidal labyrinth for sinuitis. The irritation of the terminal filaments of the turbinal branches from

FIG. 2

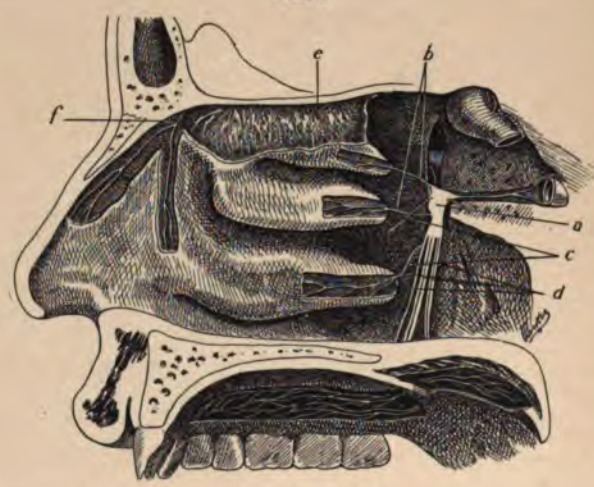

Nerves of the lateral wall of the nose. *a*, ganglion sphenopalatinum; *b*, rami nasales posteriores superiores laterales; *c*, rami nasales posteriores inferiores laterales; *d*, Nn. palatini; *e*, Nn. olfactorii; *f*, rami nasales interni, N. ethmoidalis anteriores. (After Spalteholz.)

the sphenopalatine ganglion was thus removed, and the reflex stimulus through the ganglion to the vagus and thence to the bronchial muscles ceased to be given off; hence the bronchial spasm (asthma) was cured.

The vascular engorgement present in chronic rhinitis with turgescence is due to a paresis of the vasomotor constrictor muscles supplied by the branches of the sphenopalatine ganglion. The paresis may be due to negative air pressure in the nasal chambers, whereby the vessels are overcharged with blood which "rushes in to fill the partial vacuum," or it may be due to the presence of toxic material in the blood, or to local morbid changes in the swell bodies.

The Olfactory Nerve.—The olfactory nerve descends through the lamina cribrosa (cribriform plate) from the under surface of the olfactory bulb and is distributed in the mucous membrane covering the upper portion

of the superior turbinal and a corresponding portion of the septum (Figs. 1, 2 and 5). Formerly it was thought that the distribution of the olfactory nerve in man was over a much more extensive area, the upper and median surfaces of the middle turbinal and a corresponding area of the septum being included in the area of distribution. In many of the lower animals the nerve has a wider distribution; the sinuses communicating more freely with the nasal chambers are utilized for the spread of the terminal olfactory nerve filaments. In man they are the residual remains of the organ of smell, and only communicate with the nasal cavities through small ostei or cell openings, as they are no longer needed for olfaction.

Inasmuch as the sinuses are the residual remains of the olfactory organs, D. Braden Kyle believes that they should not be needlessly opened by operative procedures and thus exposed to the irritating action of the inspired air, to which they are unaccustomed. He cites the uncomfortable sensations produced by the greater column of air sweeping through them after an exenteration of their walls, as an evidence of the possible harmful effects following an operation which opens the sinuses, so that there is free communication between them and the chambers of the nose. His point is well taken. The sinuses should not be needlessly attacked, as local treatment and probing will in many cases afford relief to the symptoms, if not cure the disease.

On the other hand, I have seen many cases in which the disagreeable sensations, caused by admitting a larger volume of air into the opened sinuses, disappear after a few weeks, the sinus disease being entirely eradicated. In some cases a choice must be made between the possible evil consequences of the disease and the evil consequences attending the cure of the disease.

To return to the olfactory nerve. It is obvious that, if the middle turbinal and the septum are in apposition, the inspired air does not reach the olfactory region, hence there is anosmia or loss of smell. It follows that if the obstruction to the olfactory fissure is overcome, either by the removal of the middle turbinal or by the correction of the deviation of the septum, air is admitted to the olfactory region and the sense of smell is restored, provided the nerve has not undergone degeneration.

Inasmuch as the distribution of the olfactory nerve is limited to the superior turbinal and the corresponding portion of the septum, the middle turbinal and the ethmoidal cells may be removed in their entirety without interfering with its distribution. In such operations the superior turbinal should be left intact in so far as it is compatible with a complete exenteration of the ethmoidal cells.

The Blood Supply of the Nose.—The middle meningeal artery gives off the sphenopalatine branch, which, when it reaches the posterior portion of the lateral walls of the nose, subdivides into the lateral posterior nasal arteries. These are distributed over the middle and inferior turbinals and in the middle and inferior meatuses. The superior turbinal and the anterior portion of the outer walls of the nasal chambers

are supplied by the posterior ethmoidal and the anterior ethmoidal arteries, respectively (Fig. 3).

As the posterior lateral nasal arteries are of considerable size, it is to

FIG. 3

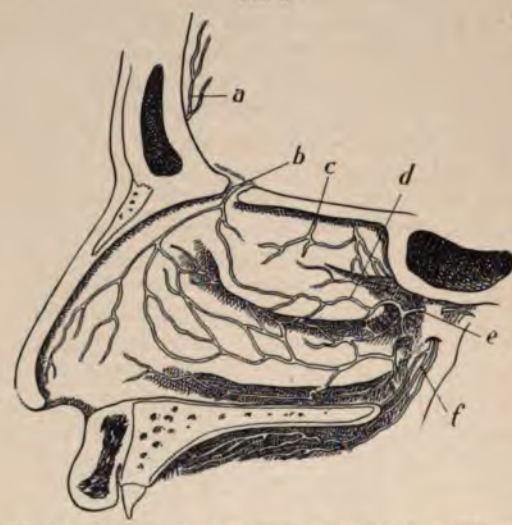

The arterial supply of the lateral wall of the nose. *a*, A. meningea anterior; *b*, A. ethmoidalis anterior; *c*, A. ethmoidalis posterior; *d*, Aa. nasales posteriores laterales; *e*, A. sphenopalatina; *f*, Aa. palatinæ major et minores.

FIG. 4

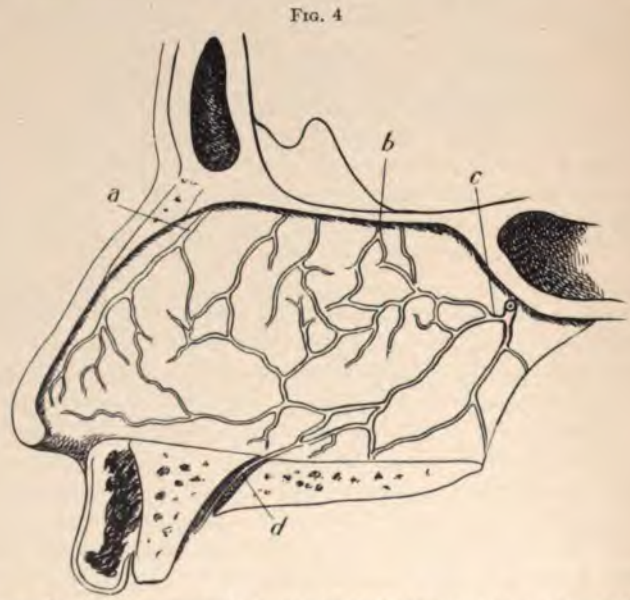

The arterial supply of the septum nasi. *a*, A. ethmoidalis anterior; *b*, A. ethmoidalis posterior; *c*, A. nasales posteriores septi; *d*, anastomosis with the A. palatina major. (After Spalteholz.)

be expected that the removal of either the middle or inferior turbinated bodies may be attended by considerable hemorrhage. As a matter of fact, the removal of the middle turbinal is usually followed by more or less bleeding for twenty-four hours. There is a free anastomosis between the lateral nasal arteries and the anterior ethmoidal artery, hence, after the removal of a turbinated body the bleeding may come from both sources though but one artery is injured.

The septum is supplied by the A. nasales posteriores septi, a branch of the A. sphenopalatina, through the foramen sphenopalatinum. It has three main branches: one supplying the posterior, another the inferior, and the other the middle and posterior portions of the septum.

The A. ethmoidalis anterior and the A. ethmoidalis posterior are distributed to the anterior and the superior portions of the septum (Fig. 4). Severe hemorrhage occasionally attends or follows operations upon the septum, especially when the operative field includes the middle branch of the A. nasales posteriores septi. A nasal douche of iced normal salt solution will often check the bleeding, though in some cases it becomes necessary to introduce a nasal tampon. I know of one case in which the bleeding continued at intervals for several weeks, with an ultimate fatal issue. Such instances are rare, however, and should not materially affect the question of operations upon the septum.

The question of tamponing the nasal chambers after operations should be briefly considered in this connection. As the nose is a part of the breathway and is constantly invaded by pathogenic bacteria, it is of the greatest importance that free drainage and ventilation be constantly maintained, as otherwise the growth of the pathogenic bacteria may be encouraged. I believe that many of the secondary hemorrhages occuring after operations are due to local sepsis affecting the blood clot in the severed arteries. The septic clot breaks down, the blood pressure dislodges it, and hemorrhage occurs. A nasal tampon should only be used after operations when the indications are positive, and never as a routine practice.

THE PHYSIOLOGY OF THE NOSE.

The functions of the nose are olfactory, phonatory, respiratory, and gustatory. The gustatory function in man is probably of least importance, the olfactory of secondary importance, the phonatory of tertiary importance, while the respiratory function is of the greatest importance.

The Sense of Smell.—The olfactory function, or the sense of smell, is presided over by the upper portion of the nasal chambers, the olfactory nerve (Fig. 5) being distributed over the attic of the nose as far downward as the upper margin of the middle turbinated body and on the septum over a corresponding area. A knowledge of the area of distribution of this nerve is of practical importance in the diagnosis, prognosis, and treatment of certain diseases of the nose. If there is anosmia, or loss of the sense of smell, the question arises as to whether the impairment is due to a degenerative change in the nerve itself, or

to an obstruction to the entrance of the odoriferous particles or emanations to the terminal cells of the olfactory nerve. If, upon examination, the middle turbinated body is resting against the septum, the removal of a portion of the middle turbinated body, or the correction of a deviation of the upper portion of the septum, may restore the sense of smell. As the normal inspiratory breathway through the nose includes the space above the middle turbinated body, it is apparent that an obstruction of the type just mentioned would prevent the odoriferous particles or emanations from coming in contact with the olfactory area of the nose during the act of inspiration. If, on the other hand, the examination shows the results of a long-continued suppurative process in the posterior ethmoidal cells, or an atrophic condition of the mucous membrane in the attic, with no obstructive lesion to prevent the inspired air entering, the anosmia may be due to degenerative changes in the terminal epithelial cells of the olfactory nerve.

FIG. 5

Showing the area of distribution of the olfactory terminal nerve cells in the human nose. The triangular flap is the septum turned upward; the area of distribution is limited to the region of the superior turbinal, and a corresponding area of the septum of the middle turbinal receiving few or no olfactory cells.

The lesions may, however, be intracranial, in which case there may be no evidence of either an obstructive lesion or of degenerative changes in the attic of the nose.

The loss of the sense of smell, while not comparable to the loss of the nasal respiratory function, is, nevertheless, attended by considerable inconvenience. The pleasure experienced by the recognition of certain odors is longed for by those affected by anosmia. More than this, they have lost one of the senses whereby they are protected from harm by certain substances, as ammonia, etc. By its aid we are warned of the near approach to decaying matter, or other foul-smelling and unsanitary substances. In the lower animals the sense of smell is of much greater utility in seeking food and in detecting the approach of hunters and animals intent upon their destruction.

Phonation.—The part played by the nose in the production of the speaking and singing voice is so great that Jeane de Reske has said that the more he studies the voice the more he is convinced that it is a question of the nose. I have often noted that popular public speakers have well-developed nasal resonance, while speakers otherwise gifted had difficulty in holding the attention of their audiences. While the initial tone is produced by the vibrations of the vocal cords, the voice

is decidedly unpleasant and unmusical if it is not rich in overtones from the resonance chambers of the nose, throat, and chest. (See *The Singing Voice.*) The nasal chambers and accessory cavities are of prime importance in voice production, and any obstruction from swelling of the mucous membrane, deflection, or other lesions of the septum so materially alters the quality of the voice as to make it disagreeable and inartistic. A knowledge, therefore, of the phonatory functions of the nose is of practical importance, as the removal of the lesions which impair this function will convert an inartistic into an artistic, an unpleasant into a pleasant, a comparatively useless into a useless voice.

Nasal Respiration.—As before stated, the respiratory functions of the nose are its most important ones. The nasal chambers are more than mere tubes through which air is drawn into the lungs; they produce certain changes in the air which prepare the air vesicles of the lungs so that they will permit of the normal transfusion of oxygen and carbon dioxide. The respiratory functions of the nose are threefold, namely: (*a*) to temper, (*b*) to humidify, and (*c*) to filter the inspired air.

Experiments have demonstrated that no matter what the temperature of the air may be before it is inhaled, it is raised or lowered, as the case may be, to near the body temperature. The delicate structures of the deeper respiratory tract are thereby protected against the great variations and extremes of temperature.

It has also been shown that the air in passing through the nasal chambers receives moisture from the nasal mucous membrane. The mucosa of the lower respiratory tract and the epithelial walls of the air vesicles of the lungs are thus protected from the varying humidity of the atmosphere in which we live. In passing through the nose the air is raised (usually) in temperature, thus expanding it and increasing its capacity to absorb moisture. The swell bodies or erectile tissue of the nose, and the serum secreting glands of the nasal mucosa, give off moisture, which is rapidly taken up by the expanded air and carried to the lower respiratory tract, where the serum secreting organs are much less developed. It has been estimated that approximately one pint of serum is thus transferred from the nasal cavities to the lower respiratory tract in twenty-four hours.

The part of the nasal structures chiefly concerned in the secretion of the serum is generally credited to the swell bodies or erectile tissue, located chiefly along the free border of the inferior turbinated bodies, and on the posterior ends of the middle and inferior turbinated bodies. It is these latter portions that sometimes become enlarged and form the so-called mulberry hypertrophies. It is probable that the mucous glands also secrete some of the serum. The swell bodies are under the control of the vasomotor nervous system, which, under normal conditions, regulates the supply of moisture to meet the demands. If the air is dry the swell bodies enlarge and become just active enough to fully saturate the expanded air in the nose; whereas, if the atmosphere is humid they are less active. When there are obstructive lesions, or catarrhal inflammation is present, the swell bodies and glands do not

respond normally to the atmospheric conditions, hence the air is not properly humidified in its passage through the nose. The treatment of these conditions should, therefore, be so directed as to restore the swell bodies and glands to their normal activity. In order to do this it may be necessary to give stability to the vasomotor nervous system by judicious bathing, outdoor exercise, etc. In addition, local massage of the mucous membrane and other treatment may be necessary. Surgical interference should always respect the location of the swell bodies, care being exercised to avoid their destruction, except in those cases in which they have already lost their function beyond hope of restoration. The surgery of the middle turbinated body may be practised with much greater freedom, because it does not have much to do with the respiratory functions of the nose. The inferior turbinated body, however, should be attacked surgically only when its secreting function is largely destroyed, or when it is so enlarged by hypertrophic or hyperplastic changes that it obstructs nasal respiration.

That the nose is a filter is made evident upon inspection of the secretions, and the vibrissæ of the vestibule, as they are loaded with dirt. The vibrissæ guarding the atrium of the nostrils act as a coarse filter, the larger particles lodging on them, the smaller ones entering the nasal cavities, where they are caught upon the irregular surface of the moist mucous membrane. The lower air tract is thus protected from the irritation which would otherwise result.

The Gustatory Function of the Nose.—The real gustatory or taste sense (sweet, sour, acid, bitter, and salt) is supplied by the distribution of the glossopharyngeal and the fifth nerves to the fauces and the base of the tongue, whereas, the delicate flavors which give so much pleasure to the consumption of foods and drinks are appreciated through the olfactory nerve. If the nostrils are closed and the eyes covered, it is almost impossible to distinguish between coffee and water of the same temperature, as the aromatic flavor cannot be appreciated by the nose when closed.

Summary: The functions of the nose are fourfold, namely:

1. Olfactory, residing in the attic of the nose.
2. Phonatory, enriching the voice by overtones.
3. Respiratory.

(*a*) The air is warmed or tempered to or near the body temperature in passing through the nose, thereby preventing shock and irritation to the mucosa and air vesicles of the lower respiratory tract.

(*b*) The air is expanded by the warmth of the nasal chambers, and its capacity to absorb the moisture thrown off by the swell bodies and mucous glands is increased. The mucosa and air vesicles are thus moistened, or, at least, their moisture is not absorbed (the air being already saturated in its passage through the nose), and irritation is prevented. The nose keeps the inspired air in a state of saturation.

(*c*) The air is filtered in its passage through the nose by the vibrissæ and the moist mucous membrane. The irritation to the mucosa and air vesicles which would otherwise occur is thus prevented.

4. The gustatory (olfactory) sense complements the sense of taste.

CHAPTER II.

THE NOSE, THROAT, AND EAR IN RELATION TO GENERAL MEDICINE.

THE writings of William Meyer, of Copenhagen, William Daly, of Pittsburg, and E. P. Friedreich, of Leipsic, have given a breadth to rhinology, laryngology, and otology they did not have in the days when the practice along these lines was regarded as a "specialty." With this broader view they are now regarded as the pursuit of the practice of general medicine and surgery, with special reference to the diagnosis and treatment of diseases in general, and those of the nose, throat, and ear in particular.

A proper comprehension of the relation of the nose, throat, and ear to general medicine and surgery will be facilitated by a brief analysis of the interdependence and coördination of the various organs and parts of the body.

ELEMENTARY FACTS.

(*a*) **The Breathway.**—The upper respiratory tract is the channel in which the air is prepared for the interchange of gases which takes place in the air vesicles of the lungs. The nose is specially concerned in the process of humidifying, warming, and filtering the inspired air, and it is obvious that any disease or obstruction that interferes with these physiological processes will affect the transfusion of gases through the capillary walls of the air vesicles. The absorption of oxygen by and the elimination of carbon dioxide from the blood will not occur in normal ratio. The blood will be deficient in oxygen and surcharged with carbon dioxide. As oxygen is essential to the processes of assimilation and nutrition, its lessened quantity in the blood gives rise to certain disturbed conditions of the digestive, the assimilative, and the nutritive functions. The presence of an excess of carbon dioxide also adds to these disturbances. It is well known that the excessive accumulation of carbon dioxide in the blood acts as a poison to the leukocytes, thus interfering with their functional activity. A normal amount of carbon dioxide in the blood favors the assimilative and the nutritive process, and it is only after a greatly increased amount of it is present that there are marked disturbances. It not only interferes with the activity of the leukocytes, but also with other cellular structures of the body as well. The combined effect, therefore, of an increased amount of carbon dioxide, and a diminished quantity of oxygen in the blood is to produce general anemia, indigestion, malassimilation, and malnutrition.

The xanthin group of toxins, including indican, are thrown into the circulation and give rise to certain nervous phenomena, as restlessness, peevishness, headache, mental depression, aprosexia, and a general feeling of malaise.

The digestive disturbances are still further increased by the infected secretions from the epipharynx and the tonsils. Putrefactive as well as pathogenic bacteria are swallowed with the secretions from the nose and throat, and give rise to what is commonly known as chronic dyspepsia or indigestion. It is probable that the putrefactive germs are more potent in this connection than the streptococci and the staphylococci. The conditions of the nose and throat which most commonly give rise to this kind of discharge are nasal stenosis, atrophic rhinitis, chronic rhinitis, sinuitis, epipharyngeal catarrh, and chronic follicular tonsillitis.

There are certain conditions of the stomach and of the intestinal tract which affect the mucous membrane of the upper respiratory tract. If, for example, there is chronic indigestion, there is also malassimilation and faulty metabolism. The imperfect products of indigestion are imperfectly oxidized and are thrown into the circulation, where they irritate the mucous membrane of the nose, as well as the vasomotor nerves, thus causing local congestion and overnutrition. The secretions of the glands of the mucous membrane of the upper respiratory tract are also thereby modified, thus predisposing to, or at least intensifying, the catarrhal disease present. In the same way hyperacidity and subacidity of the stomach may irritate the mucosa of the nose and throat. One of the most potent influences exerted by the products of indigestion is through the reflex nervous system, pharyngitis, hypersensitiveness, sneezing, etc., being the direct expressions of this condition.

In atony of the stomach there is a putrefactive formation of gases, which act reflexly and through the circulatory system on the mucous membrane of the upper respiratory tract and cause phenomena quite similar to those just mentioned. Another condition which is quite similar in many respects to the foregoing is that which occurs in gout or lithemia. In connection with this disease the larynx and the pharynx are particularly affected. In the pharynx there may be an itching behind the pillars of the fauces, associated with a similar irritation in the external meatus of the ear. Some observers regard these signs as characteristic of gout.

When such symptoms appear, the administration of calomel and the bicarbonate of soda, followed in twelve hours by a saline purge, will give marked relief. After this it is well to administer teaspoonful doses of the phosphate of soda two or three times daily for a few weeks.

Vomiting and eructation of gases from the stomach exert an irritating effect upon the mucous membrane of the pharynx, the nasopharynx, and the nose. The irritation is due to biochemical as well as mechanical causes. Catarrhal inflammation in the epipharynx is thus perpetuated and may finally extend to the Eustachian tube and the middle ear, thus giving rise to tinnitus and deafness.

(*b*) **Intimate Relation between Organs.**—All the organs of the body are more or less intimately connected by the vascular, the lymphatic, and the nervous systems, hence disturbances in one more or less affect the others. The bloodvessels and the lymph channels carry toxic and infective material to all the organs of the body, including the nose, throat, and ear, and thus influence the functions and the pathological processes present in these organs. While the data considered under this subject somewhat overlap those considered under (*a*), it is well, nevertheless, to emphasize certain features more prominently in this connection.

Anemia is a condition of the blood due to various causes, and often gives rise to collapse of the erectile tissue of the nose. This is usually spoken of as "rhinitis with collapse of the turbinated bodies." While rhinitis with collapse is not of great importance, its presence is, nevertheless, a source of information to the examining physician. When, for example, upon examination of the interior of the nose the inferior turbinated membrane is found tightly collapsed over the bony framework which supports it, the mucous membrane being comparatively dry and with no crusts distributed over it, it should lead at once to a suspicion that general anemia is present. It is bad practice to limit the treatment to the local nasal condition, as this will disappear under appropriate treatment for the anemia.

On the other hand, another condition of the nasal mucous membrane which may *cause anemia* instead of being a result of it, as related in the preceding paragraph, is atrophic rhinitis. It is characterized by anemia, which is probably due to the absorption of toxic material from the nose, and to the loss of the respiratory functions of the nose.

If the lymphatic vessels are charged with infective material, which is finally transferred to the bloodvessels and the tissues of the entire body, a state of general toxemia is induced, the nose, throat, and ear being brought more or less under the influence of the disturbed conditions in the lymphatic circulation. On the other hand, one of the commonest clinical pictures is that wherein the lymphatic glands are enlarged by suppurative diseases of the ear, nose, and throat. This subject is discussed more fully in the chapter on the Clinical Anatomy of the Tonsils. I wish, however, to emphasize the influence of suppurative diseases of the ear upon the lymphatic glands of the neck. As the ear is more intimately connected with the lymphatic glands of the posterior triangle of the neck, it is to the glands in this region that we should look for enlargement in inflammatory disease of this organ.

The close approximation of the mucous membrane of the ear to the contents of the cranial cavity may also give rise to serious consequences by the conveyance of infective material thereto. Brain abscess, meningitis, septic thrombophlebitis, etc., may thus be caused, although the usual channel of invasion is through the necrotic area in the tegmen tympani or the tegmen antri.

The nervous system, when disturbed in its function, necessarily influences the upper respiratory tract, as well as other parts of the body.

We may thus have vasomotor rhinitis and asthma, as well as certain functional disturbances of the ear and the larynx.

Hysteria probably comes under this heading, and while it is not demonstrable histologically, it has, nevertheless, a histological basis. Hysteria of the nose, throat, and ear, as in other parts of the body, is characterized by the disturbance of those functions which are more particularly under the control of the mind, the involuntary functions not being affected. In the larynx, for instance, the normal respiratory movements are not disturbed, as they are involuntary; whereas the movements of the larynx which are concerned in the production of speech, being under the control of the mind, are voluntary, and are affected.

Hay fever, laryngeal cough, sneezing, bronchial asthma, anesthesia and hyperesthesia of the mucous membrane of the ear, nose, and throat are *reflex* phenomena, which may result from the irritation of the nervous system by the toxic material in the circulation.

Another very important disease generally regarded as due to infection of the blood is *rheumatic fever*, or acute articular rheumatism. The gateway of infection is often through the tonsils, or, at least, through the Waldeyer's ring. The throat symptoms of this disease are a reddened pharynx, with a defined or circumscribed inflammation of the larynx, redness and swelling in the arytenoid region, and sometimes fixation of the arytenoid cartilages. Pain and difficulty in phonation and deglutition are also present in rheumatic fever. The physician should not only look upon the tonsils as the portals of infection, but he should look into the pharynx and the larynx for the symptoms of the disease itself. Acute rheumatic fever also gives rise to certain symptoms which are not commonly recognized. For instance, it may cause nose-bleed in children, and in some cases is undoubtedly the cause of chorea.

Malaria is another disease affecting the blood which gives rise to certain diseases or symptoms in the ear, nose, and throat. Mastoid pain, and, indeed, mastoid suppuration, has been observed in which the malarial element was prominent. In view of some recent observations, it may be questioned, however, whether these cases were distinctly malarial in their origin. We know now that there are certain septic conditions which give rise to symptoms so nearly like those due to the plasmodium of malaria that it may be questioned whether these cases were truly malarial, or whether they were septic. It is known, however, that the malarial poison may cause nasal hydrorrhea and vasomotor rhinitis.

The bloodvessels and lymph vessels are channels of communication between the *throat* and the *appendix*. In certain cases of appendicitis it has been shown that streptococcus infection was present both in the throat and in the appendix. Another possible source of communication in these cases is through the alimentary tract.

(*c*) **The Digestive Tract.**—The digestive tract, which prepares the food for tissue building, is affected by the putrefactive and the pathogenic microörganisms from the nose, throat, and ear. The primary treatment should be addressed to the relief of the diseased conditions of

the upper respiratory tract, rather than to the stomach and the intestines. The presence of dyspepsia, or other functional disturbances of the stomach and the intestines, should lead to the examination of the nose and throat, with special reference to the discharges from them, which may be swallowed by the patient. On the other hand, if there is an irritable state of the nasal, pharyngeal, and laryngeal mucous membranes, which is not explained by any local source of irritation, careful attention should be given to the condition of the stomach and the intestines, or to the organs of digestion and assimilation in general, with a view to determining whether they are properly performing their functions. If they are not, the nutritive properties of the food are thrown into the circulation imperfectly or insufficiently prepared for their purposes. The irritation thus carried to the nasal mucous membrane and to the nerves supplying it may be the chief cause of the local disturbances. It is obvious that under these circumstances the treatment should be addressed to the correction of the disorders of the digestive tract, rather than to the nose, throat, and ear.

(*d*) **Excretory Organs.**—The function of the excretory organs is to throw off the refuse material formed during the processes of nutrition. The refuse consists not only of the material not needed for the nutrition of the body, but also of the toxic material and the half-way products of oxygenation already referred to. Hence, any impairment of the functions of these organs results in an excess of toxic material in the blood and the lymphatic vessels, thereby causing congestion, irritation, hypertrophy, hyperplasia, or altered secretions in the upper respiratory tract. This feature of the subject is intimately associated with those in the preceding paragraphs. Nevertheless, it has its place in this connection, and should be considered apart from them.

The *skin* and the *kidneys* being the chief excretory organs of the body, our attention will be given largely to their consideration. We will dismiss the skin with a brief reference to the fact that eczema, lupus, etc., affecting other portions of the body, may also involve the external nose and the external ear. Or, the pathogenic processes may begin with the skin of the nose or the external ear, and extend to other parts of the body. We will also mention incidentally that erysipelas of the nose may involve the nasal mucous membrane, and that erysipelas of the skin over the mastoid process may extend to the middle ear and the mastoid cells, or even to the cranial cavity through the lymphatics and the bloodvessels of this region.

The *kidneys*, however, are the excretory organs which chiefly interest us in this connection. Bright's disease may manifest its earliest symptoms in the mucous membrane of the throat. The throat symptom complained of is dryness. This same symptom may also be present in diabetes. Diabetes is mentioned here not because it is a disease of the kidneys, but because its chief symptom is to be found in the examination of the excretions from the kidneys.

When a patient complains of persistent dryness of the pharynx his urine should be examined for albumin, casts, and sugar. In some cases

albumin will not be found at first, but after a few years its presence may be detected. In other words, the dryness of the pharynx is by some regarded as one of the earliest symptoms of this disease.

Edema of the glottis, causing laryngeal stenosis, is often due to uremia developing as a result of Bright's disease. In the milder forms of uremia, bronchial asthma and hemorrhage of the upper air passages are sometimes found to be the chief expressions of the disease. In the more pronounced uremic conditions there may be aphasia from edema of the brain.

(*e*) **Proximity of Organs.**—The close proximity of the organs of the head favors a correlated pathological activity. The eye is near the nose and has immediate communication with it through the tear duct, as well as through the lymphatics, the bloodvessels, and the nervous system; hence, disease in one often gives rise to certain symptoms in the other. Experiments with certain colored solutions dropped into the eye have shown the coloring matter within a very short time in the nasal mucous membrane. The instillation of bacteria yields the same results. Clinically it is not uncommon to observe an inflammatory condition in the eye simultaneously with or following a similar process in the nose. I have often had cases referred to me by ophthalmologists who were unable to prescribe satisfactory glasses until after I had corrected the nasal condition, usually involving the middle turbinated body or the ethmoid cells. The proximity of the nose to the ear, as well as the physiological communication between them *via* the Eustachian tube, gives rise to a very intimate relation between these organs.

It is well known that inflammation of the epipharynx sometimes extends through the Eustachian tube, by continuity of tissue, to the middle ear. This condition may develop until there is suppurative otitis media, mastoiditis, and even intracranial complications. Adenoids are also a fruitful source of mischief to the ear and the mastoid process. They may mechanically obstruct the Eustachian tube, or the epipharyngitis which almost invariably accompanies them may cause the ear disease. The removal of adenoids in children is often followed by immediate relief of deafness or even of suppurative inflammation of the middle ear.

While the stomach is not so closely related to the ear as the epipharynx, nevertheless it has a close pathological and anatomical connection through the esophagus. In vomiting, foreign matter may be forced into the Eustachian tube and the middle ear, and may cause otitis media, with all its attending complications. From this same organ eructations of gas may also cause irritation in the epipharynx and the Eustachian tube.

The nasal discharges, especially when there is *empyema* of the *accessory sinuses* of the nose, usually pass backward into the epipharynx and cause irritation and inflammation in this region. They also pass to the larynx and cause more or less trouble there. Stenosis of the nose interferes with the functions of that organ, and thus allows the air to pass into the epipharynx, the larynx, and the bronchial tubes insufficiently warmed, insufficiently moistened, and imperfectly filtered. Irritation

of the mucosa of the respiratory tract below it is thus caused and gives rise to catarrhal inflammation.

The ear is separated from the cranial cavity by a partition of bone which in places is not more than one-sixteenth to one-eighth of an inch in thickness. Chronic suppuration within the middle ear and the mastoid cavity often results in necrosis of this thin plate of bone, thus opening a channel of communication between the middle ear and the cranial cavity. The sequels or complications of mastoiditis, such as meningitis, brain abscess, septic thrombophlebitis, etc., may thus result from ear disease.

The nose is but slightly separated from the cranial cavity, and through the ophthalmic veins may cause thrombophlebitis of the cavernous sinuses, which is attended by such fatal consequences.

(*f*) **Infections.**—Systemic infections from the upper respiratory tract have already been more or less considered in this chapter as well as in the one on the Tonsils as Portals of Infection; hence, the subject will not be elaborated here.

(*g*) **The Central Nervous System.**—It is obvious, inasmuch as the central nervous system supplies the innervation of the nose, throat, and ear, that in disease of the central nervous system the parts which it supplies with innervation must be affected. In other words, in certain diseases of the central nervous system some of its characteristic symptoms may be found in the upper respiratory tract.

In tabes dorsalis there may be certain motor laryngeal disturbances, which may be either bilateral or unilateral. There may be ataxic movements of the vocal cords. Laryngeal crises, as spasmodic cough, may be present.

Ear symptoms in tabes are rare. The cochlear and vestibular nerve endings may, however, be congested. In this event there will be diminished or entire absence of bone conduction and hearing for the higher tones. Ménière's symptom-complex may also be present in exceptional cases.

In multiple sclerosis the laryngeal symptoms are a tremulous voice, which is easily fatigued, and is deep and hoarse in character. Muscular palsy of the laryngeal muscles is rare. The ear symptoms in this disease are tinnitus, and loss of hearing by bone conduction through the sclerotic degeneration of the nuclei.

The symptoms found in paralysis agitans are about the same as those found in multiple sclerosis.

(*h*) **The Lymphatic System.**—There are certain constitutional symptoms due to infections through the lymphatic system which should be especially singled out, although they have already been referred to in Section (*a*) of this chapter.

We now recognize that a fever, characteristic of childhood, which has heretofore been regarded as one of the ill-defined malarial infections, is due to an infection through the adenoid growths in the nasopharynx. The fever usually runs an irregular course of about ten days, and is characterized by an afternoon temperature of 100° to 104° with rest-

lessness, peevishness, sharp pains through the ears at night, anemia, general debility, loss of appetite, coated tongue with indentations from the teeth, constipation, and cervical adenitis. Mouth breathing is not essential as a factor in causing the infection. A small amount of lymphatic tissue in the epipharynx is a sufficient portal for the entrance of the bacteria. The presence of this type of fever is almost always an indication for the removal of the adenoids. If the child is known to be tuberculous, some consideration may be given to the matter before removing them, for, if the removal is imperfectly done, it may give rise to a recrudescence of the tuberculous infection, which may extend to the lungs and lead to a fatal issue.

Another blood disease which may express itself through certain pathological changes in the ear, nose, and throat is syphilis. The nose may be the primary seat of the lesion, the infection taking place in the removal of crusts from the septum with the finger. The tonsils are occasionally the seat of the primary lesion or chancre through the use of infected instruments in the throat. The author has seen cases in which both tonsils were the seat of chancre as a result of the instruments used in lancing the tonsils during an attack of peritonsillar abscess.

In one case there was the characteristic initial lesion in the left tonsil, with the cervical bubo on the same side, which was followed a few days later by the characteristic skin eruption. The source of the infection in this case was the dirty instruments used in lancing a peritonsillar abscess. I first saw the case six weeks after the tonsils were lanced. The patient had been complaining of sore throat for two or three weeks. The tonsils and the bubo were still very much in evidence and the eruption on the skin had just begun to show. In the course of another week the *corona veneris* developed. The copper-colored eruption on the face showed much plainer at a distance of twelve or fifteen feet than it did when viewed near by.

Secondary syphilis may manifest itself by mucous patches in the buccal cavity, by hyperemia of the larynx, hoarseness, and syphilitic coryza with scanty, thick secretion from the nose. Syphilitic coryza is not always recognized by the family physician, being regarded as a simple obstinate cold in the head. The scanty, thick discharge, with stenosis of the nose, should, however, excite suspicion of the true nature of the disease.

I once saw a case in which there was a marked arrest of development of the bones of the face because, when in childhood the syphilitic coryza developed, the family physician regarded it as an ordinary cold. He treated him for the same without success, and was finally surprised to find the nasal bones and the septum giving way. The soft palate and the pharynx later became involved and rapidly melted away under the blighting influence of the syphilitic poison. The patient is now thirty-four years old, and has the most pronounced "frog" face I ever have seen. Adhesive bands bind the soft palate to the pharyngeal wall, making it difficult for him to speak distinctly, though he is now successfully engaged in business.

The *tertiary manifestations* of syphilis are syphilitic pharyngitis and laryngitis, with a raucous voice. Syphilitic lesions of the tonsils, presenting a dirty grayish necrotic surface resembling diphtheria, are occasionally observed. Syphilitic gummata are not excessively destructive in character. Syphilitic papillomata of the tonsils and the soft palate are elsewhere described.

Recent investigations have discredited the oft-repeated statement that the skin and the mucous membranes of the animal organism are insurmountable barriers to microörganisms so long as the epithelial coat is intact. Bono and Frisco report that the researches undertaken at the Institute of Hygiene at Palermo have established the fact that "germs deposited on the intact skin or mucosa are found soon afterward in the lymphatic ganglia of the respective regions. If the germs are so numerous or so virulent as to overcome the resistance offered by the lymphatic ganglia, general infection may result. If not, there is merely a local reaction on the part of the ganglia, which become tumefied and undergo various modifications in their structure proportional to the number of germs which reach them."

To establish the relationship between the nasal mucous membrane and the eye, microörganisms were placed on the nasal mucous membrane, both with and without obliteration of the nasolacrymal canal. The result of the experiments showed the penetration of the germs into the vitreous and the aqueous humors of the eye on the same side.

"None of the animals exhibited any signs of general infection. One or two colonies, at most, could be derived from the blood in the heart, the liver, the spleen, and the lymphatic ganglia of the neck, and occasionally from the anterior auricular, the submaxillary, the deep jugular, and the carotid lymphatic ganglia. This fact, considered in connection with the presence of large numbers of germs in the aqueous and the vitreous humor, and the absence of general infection, warrants the conclusion that the bacteria penetrated directly into the eye from the nasal and the conjunctival mucous membrane, and that they also arrived secondarily in the eye through the blood, but reduced in numbers and virulence. Part of the germs were retained by the ganglia connected with the anterior lymphatic vessels of the eyeball and its appendages. In further experiments with instillations of India ink it was possible to trace the exact route followed by the particles from the conjunctival lymphatics along Schlemm's canal into the anterior chamber and thence into the vitreous. From the lymphatics of the nasal mucosa the particles passed into the ethmoid cells and the lamina papyracea, thence into Ténon's capsule, and on into the eyeball. The practical results of these researches are particularly important in the pathology of the eye."

Eye Diseases Due to Nasal Lesions (especially Optic Nerve Lesions).—F. Mendel, after observing many cases, comes to the conclusion that the nasal infection and inflammation is transferred to the eye by the direct connection or continuance of the epithelium of the nasal mucous membrane to the conjunctiva, as well as by the intimate vascular association.

The ophthalmic artery gives off the anterior ethmoidal, which supplies

the nose and the lacrymal canal. The venous supply of the nasal mucous membrane, by means of the lacrymal plexus, is in direct communication with the ophthalmic vein.

Heber Nelson Hoople, in a paper read before the American Laryngological, Rhinological, and Otological Association, 1901, advances the theory that faulty pressure within the nose can cause asthenopia of both the ciliary and external ocular muscles. That is, mechanical pressure in a limited area of the nose, called by Mackenzie the reflex area, can cause muscular asthenopia. By muscular asthenopia he means the impairment of the efficiency of the ocular muscles in the performance of their ordinary functions.

The pressure to which Hoople refers is confined chiefly to the middle turbinal, especially to great enlargement of the middle turbinated body.

A concomitant symptom usually occurring in conjunction with the asthenopia is a browache or headache referred to the frontal region or to the occiput in rarer instances.

He cites a number of cases in his own practice and in that of others in which the asthenopia disappeared as soon as the nasal trouble was cured. The asthenopic cases referred to belong to the so-called normal type rather than to the excessive type.

He concludes that a moderate amount of pressure or mechanical irritation of the middle turbinated body against the adjacent septum will temporarily impair the function of the ciliary muscle; to a lesser or more variable degree, it will also impair that of the external ocular muscles. If mechanical irritation (from congestion or swelling of the soft tissues) can impair the function of these muscles, how much more would a continuous pressure from a septal spur or other deviation of the septum digging into the middle turbinal keep up this impairment?

The reason for the association of headache with asthenopia is that they have a common cause—pressure upon the sensori-motor branches of the trigeminus. So far as the sensory part is affected, a radiated or a reflex headache is produced; so far as the sympathetic fibers are affected a vasomotor reflex is produced. This is equally true where there are inflammatory conditions, as ethmoiditis. It matters little whether the pressure is from within the ethmoid cells and turbinal or from without these structures. The important point is that the same branches of these nerves are pressed upon, and, therefore, the same kind of disturbances should be expected to follow.

The asthenopic disturbance is probably due to irritation of the sympathetic fibers in this particular class of cases. That it is such in all cases is also probable. It could be inferred from other facts, *e. g.*, when treatment addressed to the uterus, the bladder, or the stomach has given relief of the asthenopic symptoms.

In the light of the foregoing views expressed by Hoople, asthenopia or disturbed function of the ciliary and external ocular muscles is usually due to intranasal pressure and irritation in the middle turbinal and ethmoidal regions, rather than to toxemia from infection of the sinuses. The speedy relief of the asthenopia following the divulsion or the removal

of the offending middle turbinal seems to prove this view rather than the view referring the disturbance to toxemia.

In the cases referred to by Hoople the headaches were of the ocular rather than the sinus type, as they were induced, or aggravated, by the use of the eyes, and were relieved upon retiring for the night. Sinus headache is not always aggravated by using the eyes, and is often most pronounced upon awakening in the morning or in the night.

CHAPTER III.

THE OFFICE EQUIPMENT.

THE chief thought in the equipment of an office should have reference to facility in handling and treating patients. The treatment and consultation rooms should be equipped for work rather than for entertainment. Everything for facility and thoroughness; nothing for show. "Bluff" is a confession of unfitness. Thorough knowledge and frankness of statement will inspire confidence and give an impression of mastery as no amount of bluffing will do.

The essential furnishings of the consultation-room and treatment-room should consist of the following outfit:

(*a*) Treatment and operating chair. (*b*) A revolving stool for the surgeon. (*c*) A treatment table or cabinet. (*d*) A fountain cuspidor. (*e*) A linen cupboard. (*f*) A writing desk. (*g*) A sterilizer. (*h*) A revolving desk chair. (*i*) Two small chairs. (*j*) An adjustable bracket for the examination lamp. (*k*) A selection of instruments and apparatus for examinations, treatments, and operations.

The Treatment and Operating Chair.—The treatment and operating chair should have a revolving bottom, as suggested by Dr. Robert Levy, as it is desirable to turn the patient from side to side in treating his ears, and for other reasons as well. The bottom should be on a central screw pin, so that it can be adjusted to different heights for children and adults. The back should be so constructed that it can be lowered on a level with the bottom in case of faintness and in case it is desirable to operate in a prone position. An adjustable head-rest should be attached to the back of the chair. Chairs responding to the foregoing requirement are shown in Figs. 6 and 7. An ordinary chair may, of course be used, but, in the case of faintness, etc., the work is greatly facilitated and the comfort of the patient assured if the chair is of the adjustable type described.

The Treatment Table or Cabinet.—If an assistant is employed it is preferable to have the instruments in a separate cabinet adjoining the sterilizing room or corner. The treatment cabinet may then consist of a metal enamelled frame with a plate-glass top, or it may be a double-decked table, with top and shelves about one foot apart. These tops afford ample room for the distribution of bottles containing remedies for topical applications and for the instruments of examination and operation.

The treatment table or cabinet (Fig. 8) is an important item of furniture. Its selection should depend largely upon whether the surgeon has an assistant or nurse to wait upon him. If he has such an assistant the cabinet need not be constructed to contain all his instruments, as the

assistant will bring the necessary instruments for each case. If he does not have an assistant, it is convenient to have the instruments in the cabinet within his reach.

The Hot-water Basin.—A most excellent addition to the table is a basin set in the centre of the upper glass top, with running hot water for rinsing instruments during the course of treatments. If preferred, the hot-water basin may be attached to a special wall bracket (Fig. 9), as it is only intended to provide a convenient arrangement for rinsing instruments during treatments and operations. It is also convenient for

Fig. 6

Fig. 7

Operating chairs.

cleansing and warming the laryngeal mirror during throat examinations. No matter how sterile the tongue depressor is when brought in, its introduction into the mouth the second or third time without cleansing is, to say the least, disgusting to the patient.

A basin of running hot water is, therefore, an invaluable, and I might add an indispensable, adjunct to the office equipment. It is not indispensable in so far as the safety of the patient is concerned, as only his own secretions contaminate the instrument used. If the fundamental principles of common cleanliness are to be recognized it is a valuable

and necessary office fixture. It is not a question of whether it pays, but rather one of common decency, and that always pays.

Fig. 8

Medicine and instrument cabinet

Fig. 9

Clark's hot-water basin.

Fig. 10

Clark's fountain cuspidor.

A bowl of antiseptic solution is not a substitute for running hot water unless the bowl is refilled for each rinsing. The solution would soon become thick with secretions and detritus, and the introduction of an

instrument into it for rinsing purposes would be even more digusting than no rinsing at all.

The Examination Lamp.—The examination lamp may be a kerosene, gas, or an electric lamp, preferably the latter, as it gives off less heat and requires less attention. The lamp may or may not have a hood with a focusing lense, according to the preference of the surgeon. Personally, I prefer an electric lamp of 50 candle-power (Fig. 11), with a ground-glass surface except a circular area on one side, where the glass is clear. This affords plenty of illumination, is simple, throws out little heat, and is inexpensive.

Fig. 11



A 50 candle-power electric lamp.

A wall bracket to support the lamp is an important item, inasmuch as it is constantly used, and should, therefore, be well constructed and accommodate itself to the varying conditions under which it is used. That is, it should be so constructed that the lamp can be raised and lowered and turned from side to side with the least trouble to the operator. It should be so well made that it will never get out of order, a state or condition into which many wall-lamp brackets are prone to lapse. That shown in Fig. 12 has proved quite satisfactory in nearly every respect, though the

Fig. 12

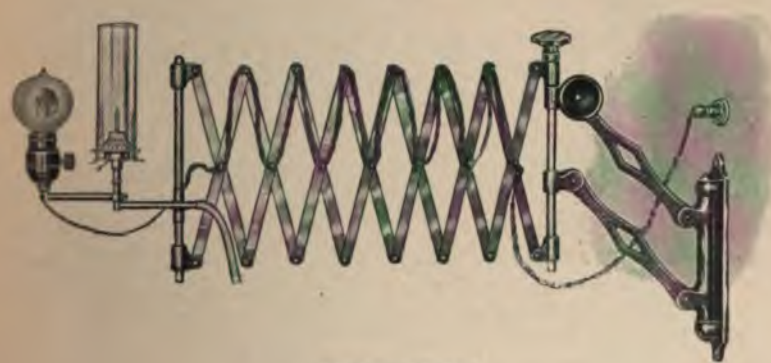

Wall-lamp bracket.

electric bulb attached should be turned upward. A Kierstein head lamp (Fig. 13) is preferred by some operators.

Compressed-air Apparatus.—The compressed-air apparatus may be one of three types: (*a*) A hand bulb; (*b*) a tank pumped by hand or some automatic device, as a water pump; or (*c*) a system of compressed air supplied throughout the building by means of pipes from a central compressed-air tank. The latter is preferable when it can

be obtained, as it requires no attention whatever. A compressed-air tank in the office automatically supplied by means of an hydraulic pump is the next most preferable arrangement. A hand pump is inconvenient and entails considerable labor. The hand bulb is suitable when eight pounds or less of pressure is required.

An Accessory Regulating Air Tank.—An accessory regulating air tank is a very convenient and valuable addition to the compressed-air system, as it enables the surgeon to use the amount of pressure required for various purposes. The nasal mucous membrane, for example, will not tolerate a higher pressure than ten pounds with the De Vilbiss spray tube, whereas the pharynx will tolerate from twenty to forty pounds' pressure. A nebulizer requires a higher pressure than the spray tube, and in inflation of the Eustachian tube and middle ear the pressure required varies from eight to twenty pounds, according to the degree of obstruction present. Hence a regulating air tank is a convenient

Fig. 13

Kierstein lamp and head bracket.

if not a necessary apparatus. The tank should be connected with the main reservoir and the compressed air turned on until the gauge indicates the required pressure, say twenty pounds. If at another time in the treatment but ten pounds' pressure is needed the escape valve may be opened until the gauge indicates ten pounds. There are many other ways in which such a regulating air tank may be used to advantage. The gauge regulators on the market are not nearly so satisfactory as the regulating tank, and are not recommended.

Massage Apparatus.—Ear Drum.—Pneumomassage or the massage of the ear drum by the alternate rarefaction and condensation of the air in the external auditory meatus is accomplished by means of a hand pump, as first devised by Delstanche, of Brussels (Fig. 14), or it may be operated by an electric motor, as first devised by Chevalier Jackson, of Pittsburg, and later, in 1893, improved by Pynchon (Fig. 15). The pneumomassage of the ear drum is recommended in deafness and ear

noises of catarrhal origin, though its value has been greatly exaggerated. Delstanche was of such high repute, that he was awarded the Lavele prize

Fig. 14

Delstanche's rarefactor and artificial leech.

Fig. 15

The Victor electrocautery and pneumomassage pump.

for having designed the best instrument for relief of deafness, hence the procedure was adopted by aurists all over the world. Subsequent

experience with it and its modifications has not met the high expectations with which it was received. Pneumomassage has a place in aural practice, however, as by it the mucous membrane is brought into a more active and resistant state, and the labyrinth is also stimulated to greater functional activity by it. The ossicles of the ear are rendered more mobile and transmit sound better after its application in a limited number of cases. Tinnitus is also occasionally improved by it. Such cases require rare skill and knowledge to determine what is best to do for them. Routine of inflation and of pneumomassage lead to bitter disappointment except in a few cases. Accurate diagnosis is of first importance; then the treatment should be very carefully and intelligently prescribed. Not every case of deafness and tinnitus is improved by pneumomassage or any other method of treatment.

Then, too, the massage apparatus, hand or mechanically driven device, should be regulated to suit each case. The length of the piston stroke, the frequency of the vibrations, and the length of time the massage should be used are questions to be settled according to the peculiarities of each case and the experience and judgment of the surgeon. Massage *per se* is of no value as a therapeutic agent. It is only when it is mixed with "brains" that it becomes of value. Surgeons who are uninformed and inexperienced are often tempted to furnish their offices with formidable looking mechanical devices, with the belief that they are thus preparing themselves to adequately cope with disease. If they are intelligent observers, they soon learn that the "man behind the gun" is the first requisite for the attainment of success. I must confess that I have rarely observed marked improvement in deafness and tinnitus that was clearly due to pneumomassage.

I have, however, found the hand apparatus of Delstanche of the greatest value as a diagnostic agent. With it the ear drum may be observed under compression and rarefaction, points of adhesions and of atrophy being clearly demonstrated. When the air is rarefied in the meatus the ear drum is pulled outward, the points of adhesion being fixed while the balance of the membrane bulges outward, leaving no room for doubt as to the condition of the middle ear. If there is an atrophic area in the ear drum it bulges like a blister beyond the balance of the membrane. If the otoscopic portion of the apparatus is provided with a magnifying lens the texture of the ear drum is clearly demonstrated.

Aside from the diagnostic value of the Delstanche apparatus its greatest usefulness is in the treatment of the exudative forms of middle-ear catarrh. It is in the protracted course of these cases that the adhesive processes form. The viscid exudate agglutinates the ear drum to the inner tympanic wall, becomes organized, and thus permanently fixes it to the inner wall of the middle-ear cavity. The timely and intelligent use of the Delstanche rarefactor, or other pneumomassage apparatus, may prevent permanent adhesions. The apparatus should in the beginning be used daily with a slow, long stroke of the piston. After the inflammatory process has abated and the exudate is less viscid and less profuse the treatment may be gradually reduced in frequency and finally aban-

doned. The length of the stroke (force of the suction) should be gradually diminished, as a too long-continued stretching of the membrana tympani will render it abnormally lax from pressure (suction) atrophy.

Another device for the massage of the ear drum consists of a glass tube partially filled with metallic mercury (Fig. 16). The open end of the tube is shaped to fit the external meatus, and when not in use is closed with a rubber cork. Its application is simple, the uncorked end being placed firmly in the external meatus, and the patient instructed to move the head from side to side, allowing the mercury to drop against the ear drum. This procedure is repeated several times at each daily seance. According to Dr. Joseph C. Beck, its originator, the *rationale* of its use consists in the impact of the mercury against the malleus and ear drum, the force being transmitted to the entire ossicular chain and to the labyrinth. This stimulates the functional activity of these structures and improves the condition present. Dr. Beck has found its chief usefulness in the relief of the tinnitus rather than the deafness, a fact which to my mind is significant. That is, the mechanical shocks thus applied to the membrana tympani and transmitted to the labyrinth affect the circulation of the labyrinth, improve the nutrition and increase the local leukocytosis. These changes affect the labyrinth in such a way as to relieve the tinnitus.

Fig. 16



Beck's mercury massage.

Dr. Beck has also noted that the improvement was usually transient, lasting only a few days or weeks after discontinuing the treatment.

The Electrocautery.—So much has been said within the past six years about the use, or rather the uselessness, of the electrocautery (Fig. 15) that I feel impelled to rise in its defence. It is still a very useful apparatus, and an office is incomplete without it. It is true that it has been too frequently, indiscriminately, and unintelligently used, but it still fills a place of great usefulness in the armamentarium of the specialist. Its usefulness in turgescent rhinitis has been greatly abridged by the improved methods of operating upon the nasal septum (notably the submucous resection), but even in this condition it still affords a means of temporarily overcoming the excessive swelling of the inferior turbinated bodies. It also affords a valuable means of treating chronic granular pharyngitis with lymphoid enlargements along the lateral and posterior walls of the pharynx. Still other uses could be described, but as they are mentioned in connection with the respective diseases, the two citations are sufficient to show that the electrocautery apparatus is not an obsolete instrument.

Spray Tubes.—The spray tubes and the medicated fluids used in them have also come under the ban as therapeutic agents. There was a time when the rhinologist and laryngologist was called the "spray

specialist," more derisively the "squirt-gun doctor." Whatever grounds there may have been for these characterizations it is certain that they do not apply to the specialist of the present time. Nearly all special surgeons now recognize the futility of attempting to cure diseases of the nose and throat by means of medicated water and oil. The etiology of the catarrhal and suppurative inflammations of the nose and throat is better understood, and the ideas concerning their treatment have undergone corresponding changes. It is being more and more recognized that mucous-lined cavities are subject to catarrhal and infective inflammation somewhat in proportion to the degree of obstruction to their drainage and ventilation. This one factor is probably the most significant etiological factor emphasized in recent years. Goodale and Jonathan Wright emphasize it in reference to the crypts of the tonsil. Heath has recently emphasized the same truth in reference to the mastoid antrum and the

Fig. 17

De Vilbiss' atomizer and nebulizer.

middle ear. (See Heath's *Mastoid Operation;* also the *Clinical Anatomy of the Nose*, and the *Inflammatory Diseases of the Nose and Accessory Sinuses.*)

In view of this more modern conception of the etiology of the inflammatory diseases of the ear, nose, and throat, surgical procedures have largely replaced the topical, medical, and caustic applications once in popular favor. The spray tube or atomizer occupies a less conspicuous place than it did a few years ago (Fig. 17). An array of fifty or a hundred spray bottles, each with a different medicated or perfumed solution, is no longer a necessary part of an office outfit; indeed, such an array of spray formulæ is in some ways a confession of an antique, if not altogether obsolete, conception of medical practice. Spray tubes are, nevertheless, necessary adjuncts to the office outfit, as they should be used to cleanse the nasal and throat cavities before operating and to treat acute and chronic inflammations.

The Mechanical Vibrator.—Some years ago the mechanical vibrator was mentioned as acting favorably upon tinnitis and deafness, but its more general use by English and American otologists has demonstrated its comparative uselessness for these purposes. At that time it was stated that when applied over the spinal column it seemed to act favorably upon the ear. I have tried it faithfully for this purpose, with no appreciable effect. Its chief field of usefulness is in reducing the swelling and sensitiveness of the glands of the neck and the headache accompanying the various sinus affections. But even these conditions are better and more pleasantly ameliorated by the leukodescent lamp. The vibratory or mechanical massage increases the lymphatic flow, improves the nutrition, and increases local leukocytosis. Hence, it

Fig. 18

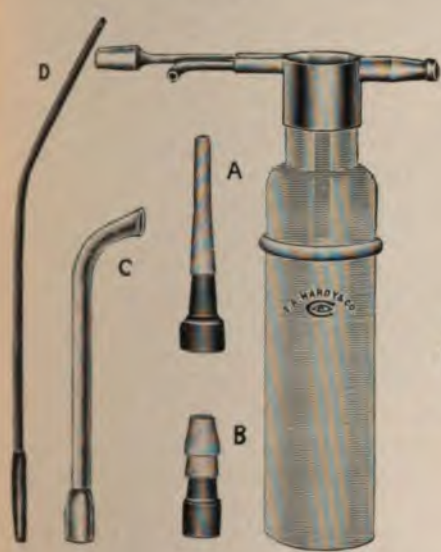

Pynchon's modification of Dabney's vacuum aspirator.

Fig. 19

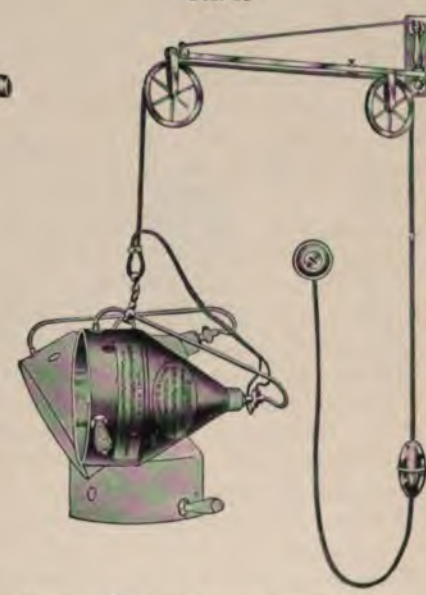

The leukodescent therapeutic lamp.

relieves pain and tenderness, and reduces the activity of an inflammatory process, provided it can be applied to the parts. In this respect it acts upon the principle of Bier's constriction and negative pressure treatment, and the leukodescent-light treatment; that is, they each increase the local leukocytosis, improve the local nutrition, and thus diminish the inflammatory process.

Negative Pressure Apparatus.—This apparatus consists of a device whereby the air pressure is reduced in the upper air passages, notably the nose and accessory sinuses (Fig. 18). The negative air pressure within the nose and accessory sinuses facilitates the discharge of the secretions and purulent accumulations, increases the local nutrition and leukocytosis, and acts favorably upon the inflammatory process. Its chief

field of usefulness seems to be in the treatment of the subacute inflammations of the sinuses, though it exerts a favorable influence upon chronic sinuitis.

The Leukodescent Lamp.—The leukodescent lamp is a single incandescent globe of 500 candle-power (Fig. 19), around which is placed a reflector eighteen inches in diameter. The reflector focuses the rays of light, thus increasing their penetrating power. The therapeutic properties of the leukodescent light is in the heat and chemical rays. The leukodescent light is rich in blue-violet rays, in addition to the light and heat rays. The blue-violet are very active chemical rays and increase the tissue metabolism and the leukocytosis, thus providing for the destruction of the pathogenic bacteria.

Clinically, I have found the leukodescent light of value in inflammatory and infectious processes. For instance, I have seen cases of chronic maxillary empyema with granulations cease discharging under its influence. The pain, tenderness, and swelling likewise disappeared. In no case, however, have I seen a cure by this mode of treatment. In acute sinuitis I have seen marked and rapid improvement follow its use. Infective inflammation of the mastoid wound rapidly improves under its use three times daily. Cervical adenitis usually responds readily to the rays. Pain of almost any origin is relieved and in many cases stopped by it. The pain of sarcoma is almost invariably checked. It seems to exert a slight control over an oozing postoperative hemorrhage. Its power to increase tissue metabolism and local leukocytosis reduces the bacterial activity. The latter is probably due more to the increased leukocytosis than to the bactericidal property of the rays. While they are bactericidal when applied continuously for ten minutes at a distance of thirteen inches in the laboratory, they are probably not batericidal at eighteen inches for a few moments at short intervals in their clinical application. The rays are too hot to be tolerated constantly at close range, hence the effects produced in laboratory experiments cannot be duplicated in actual practice.

Lamps of less candle power are correspondingly poor in the blue-violet rays, the 50 candle-power lamp having scarcely a trace of them. It has also been shown that ten 50 candle-power lamps in group have indentically the same quality of rays as a single 50 candle-power lamp, and that the rays are in no way similar to those given off by a 500 candle-power lamp. I therefore recommend that a single 500 candle-power lamp be chosen, as a lamp of less capacity is not sufficiently rich in chemical rays to produce the best results.

A Sterilizer for Instruments and Gauze.—An office outfit is not complete without a sterilizer of some kind. All instruments should be boiled for at least twenty minutes before they are used, for either examinations, treatments, or surgical operations. The instruments may be boiled in a porcelain-lined bucket or pan, or in a specially designed sterilizer, as shown in Fig. 20. The apparatus shown in the illustration is provided with a drying chamber in addition to the boiling tray, and is recommended on this account. Instruments are often damaged or

altogether ruined because they are not dried after being sterilized. With this sterilizer they may be boiled and dried after an operation.

Topical Applications.—Topical remedies which should be upon the treatment table are numerous, though individual preference may greatly modify their number and character. I shall only refer to those which have proved satisfactory in my practice.

Nitrate of Silver.—The following solutions of nitrate of silver should be kept on the treatment table in blue-glass bottles, or in a cabinet within convenient reach of the surgeon or his personal assistant.

℞.—Argenti nitratis . . . . . gr. x
Aquæ des. . . . . ℥ij—M.

This is approximately a 2 per cent. solution of the silver salt, and is useful where a mild but positive astringent action is required, as in simple subacute catarrhal inflammations of the upper respiratory tract. It may be applied with a spray tube, the essential parts of which are made of hard rubber and aluminum, or of glass. Other metals are acted

Fig. 20

Pynchon's sterilizer and instrument dryer.

upon by the silver salt, and are not suitable for the silver solutions on this account. The silver solution may also be applied with a cotton-wound applicator. A camel's-hair brush is not recommended, on account of the difficulty of keeping it sterile.

℞.—Argenti nitratis . . . . . gr. xx
Aquæ des. . . . . ℥j—M.

This solution is approximately 4 per cent. in strength, and may be used as No. 1 when a more positive astringent and antiseptic action is required.

℞.—Argenti nitratis . . . . . gr. xl
Aquæ des. . . . . ℥j—M.

This solution is approximately 8 per cent. in strength, and is useful in the more chronic catarrhal inflammations of the upper respiratory tract. Solutions of greater strength than this are rarely indicated in chronic inflammations of the mucous membrane except when a caustic action is required. Higher strengths are apt to cause irritation and an aggravation of the local chronic inflammation.

In the very acute inflammations a much higher percentage of silver may be used.

℞.—Argenti nitratis . . . . . ʒss
Aquæ des. . . . . q. s. ad ℥j—M.

This is a 12½ per cent. solution and is a valuable local remedy in acute lacunar inflammation of the tonsils. The more acute the attack and the more edematous the tissue the stronger the silver solution should be.

℞.—Argenti nitratis . . . . . ʒij
Aquæ des. . . . . q. s. ad ℥j—M.

This is a 25 per cent. solution and is useful as a local application in acute infectious inflammations of the fauces and the nasopharynx. It is especially useful in acute lacunar tonsillitis, one application in the primary stage often being sufficient to abort the inflammatory process.

℞.—Argenti nitratis . . . . . gr. ccccxxxij
Aquæ des. . . . . q. s. ad ℥j

This is a 90 per cent. solution and is useful in acute lacunar tonsillitis in the most virulent and acute stage. It should only be applied when the inflammation is very recent and aggravated in type. The tissues should be succulent and highly inflamed. In such a case of acute lacunar tonsillitis it is a specific remedy. I have never seen a case corresponding to the above description in which a second application of the remedy was necessary. Its use in this strength is not painful, but, on the contrary, relief immediately follows its use.

If this strength of solution were applied to a subacute inflammation the chemical trauma would probably aggravate the existing inflammatory process rather than relieve it. Solutions of silver salt in the higher strengths coagulate the mucous secretions and blanch the surface of the inflamed mucous membrane. It is also a powerful germicide. The inflammatory infiltration of the tissue is checked and the vitality of the infective bacteria is lowered or destroyed.

A caution as to the use of silver nitrate. The silver salt in any strength has a marked irritating effect on the intrinsic muscles of the larynx. To avoid this accident the cotton-wound applicator should be freed of the excess of the solution by squeezing it with a liberal wad of cotton. When this is done the inflamed area should be lightly brushed with it.

Silver Maxims.—(*a*) The milder the inflammation the milder the solution. (*b*) The more intense the inflammation the stronger the solution.

Guaiacol Solutions.—Solutions of guaiacol in olive oil are useful local remedies in acute inflammation of the fauces and the pharynx.

The strengths recommended are 10, 25, and 50 per cent. of guaiacol in pure olive oil. The more severe the inflammation the stronger the solution required.

While guaiacol is not as efficient a remedy in acute tonsillitis as the stronger solutions of silver, it is nevertheless very positive in its action, many cases requiring but a few applications to check the inflammatory

process. It produces a pungent, hot sensation which lasts for about thirty seconds.

Compound Tincture of Benzoin.—The compound tincture of benzoin is a valuable local remedy in the throat where a mild but positive astringent and antiseptic remedy is indicated. It may be used in chronic granular pharyngitis during the mild exacerbations of the disease with good effect.

Its chief value is as an adjunct in dressing the nasal accessory cavities. The gauze should be moistened in the solution, the excess removed by squeezing, and packed in the nasal cavity. It prevents decomposition and stimulates healthy granulations. A plain gauze dressing in the nasal chambers, if allowed to remain more than twenty-four hours, often takes on a very offensive odor. If the gauze is moistened with the compound tincture of benzoin, it may remain in the nose seventy-two hours without acquiring an offensive odor.

A foul-smelling chronic otorrhea may be rendered sweet by mopping the cavity dry and applying a dressing of gauze moistened with the compound tincture of benzoin.

Fig. 21

Powder insufflator.

Subnitrate of Bismuth Powder.—This powder may be used with gauze dressings as a substitute for the compound tincture of benzoin. It also prevents decomposition, though not over so extended a period.

It may also be insufflated (Fig. 21) into the nose after an intranasal operation, where it forms a coating which acts as a mechanical and a chemical protection to the underlying tissue.

Ichthyol Solutions.—Ichthyol in aqueous and glycerin solutions may be used as a topical application in the nasal chambers where there is a foul or ozenic secretion. The nose should be packed with cotton or gauze saturated with the solution. Personally I prefer to use a corkscrew applicator wound with cotton and dipped in the ichthyol solution. This is then introduced into the nasal cavity and the applicator removed with a reverse screw motion, leaving the ichthyol pad in the nose. This should be left in place for from ten to thirty minutes, according to the degree of infection and tumefaction of the tissue. If the secretions are profuse and dried in the nasal cavities, the aqueous solution should be used; if there is a state of sepsis and local tumefaction of the tissues, the glycerin solution should be used on account of its hygroscopic action.

Iodine Solutions.—Iodine in a glycerin menstruum is a valuable remedy in chronic granular pharyngitis, and in those cases of middle-ear catarrh associated with granular pharyngitis.

The following formulæ may be used in such cases:

℞.—Tr. iodini . . . . . ♏xlviij
Glycerini . . . . . q. s. ad ℥j—M.

℞.—Iodoformi . . . . . gr. j
Potas. iodidi . . . . . gr. x–xx
Morphia sulphatis . . . . . gr. j
Glycerini . . . . . ℥j—M.

℞.—Iodini . . . . . gr. v–xx
Potas. iodidi . . . . . gr. x–xxx
Ol. gaultheriæ . . . . . ♏v
Glycerini . . . . . ℥j—M.

℞.—Tr. iodidi,
Tr. ferri chl.,
Glycerini . . . . . aa q. s. ℥j—M.

The fourth formula is very astringent and is used to promote even healing by granulation after tonsillectomy in adults. It is also of great value in the subacute type of granular pharyngitis.

Carbolic Acid.—Carbolic acid may be used in any strength from 10 to 95 per cent. aqueous or glycerin solution.

℞.—Carbolic acid . . . . . gr. xx
Glycerin . . . . . ℥j—M.

This is approximately a 4 per cent. solution and may be used in subacute dry dermatitis of the external auditory meatus and in subacute otitis media.

℞.—Carbolic acid . . . . . ℥j
Glycerin . . . . . q. s. ad ℥j—M.

This is a 12 per cent. solution and may be used in acute otitis media. It should be dropped into the meatus two or three times daily and a cotton plug introduced to prevent its escape. It is claimed that if dropped into the meatus in the initial stage of acute suppurative otitis media it aborts the further progress of the inflammation in nearly every instance (A. H. Andrews). On the other hand it is claimed that its frequent use causes a fibrosis and thickening of the ear drum, and thus causes permanent diminution of hearing. It may be said, however, that its frequent use is not often required to abort an attack of acute otitis media.

℞.—Carbolic acid . . . . . gr. ccclvj
Aquæ des. . . . . gr. xxiv—M.

This is a 95 per cent. solution of carbolic acid and may be used when a superficial caustic effect is desired, as in infective granulomata of the middle ear and mastoid, either before or after operation. I have occasionally used it in old foul-smelling otorrheas to diminish the odor and to stimulate healthy granulation.

It should be carefully dropped into the middle ear without allowing it to come in contact with the meatal skin, and at the end of one minute alcohol should be instilled to check its action.

Alcohol.—Alcohol is also a valuable remedy for topical applications. I know of no better ingredient for a gargle than alcohol. It is astringent and antiseptic, and, when properly diluted, is grateful to an inflamed surface.

℞.—Alcohol,		
Cinnamon water	āā	ʒij
Formaldehyde		♏ij
Glycerin		ʒv
Aquæ des.	q. s. ad	℥viij—M.

The above formula is a good gargle in acute tonsillar and pharyngeal inflammations and in the soreness following the removal of the tonsils.

In very young children it may be used in a more diluted form.

In chronic otorrhea alcohol may be used in the following dilutions and mixtures.

℞.—Alcohol	1 part
Aquæ des.	2 parts—M.
℞.—Alcohol	1 part
Aquæ des.	1 part—M.
℞.—Alcohol	2 parts
Aquæ des.	1 part—M.
℞.—Alcohol	3 parts
Aquæ des.	1 part—M.
℞.—Alcohol	95 per cent.

The alcoholic dilutions given above are used principally in the treatment of chronic suppurative otitis media.

They constitute the so-called "alcohol treatment" of this disease: The meatus is first filled with the weakest solution, then mopped out, and each solution applied in series until the patient tolerates the 95 per cent. solution. If the strongest solution is applied at once it causes considerable pain and irritation, whereas if the strength is gradually increased unpleasant results are avoided.

Alcohol is a positive astringent and antiseptic remedy of considerable value.

℞.—Alcohol (95 per cent.)	ʒj
Boric acid	gr. xx—M.
℞.—Alcohol (95 per cent.)	ʒj
Iodoform	gr. v—M.

The addition of boric acid and iodoform is supposed to give the local antiseptic effects of these drugs. If an excess of either drug is added, and the solution is agitated just before the instillation of the solution, a precipitate of the partially suspended drug is deposited on the diseased mucous membrane.

These solutions should be used after having applied the weaker alcoholic solutions.

Ointments.—Various drugs may be prepared with an oily menstruum, preferably lanolin, as it has greater affinity for the mucous membrane

than vaseline. Pure olive oil may also be used as a menstruum. The following mixtures are recommended:

℞.—Zinc oxide	gr. xlviij
Lanolin	℥j—M.

℞.—Zinc oxide	gr. xlvij
Morph. sulph.	gr. j
Atropine	gr. $\frac{1}{100}$—M.

The first formula is soothing to an inflamed surface, and may be applied in those cases in which there is an irritating mucous or seromucous discharge in catarrhal sinuitis. It is also of use in the massage of the nasal mucous membrane in rhinitis with collapse, and in turgescence of the swell bodies. For this purpose a delicate silver applicator should be wound with a small wisp of cotton and dipped into the ointment. The nasal mucous membrane should then be gently massaged with the ointment, the probe being lightly held between the thumb and forefinger. The wrist movement, or the combined wrist and forefinger movement, should be used in performing the massage. The applicator should be held so lightly that if the cotton-wound applicator should strike a turbinated body or other obstruction the probe will slip through the fingers and do no damage.

The sensitiveness of the mucous membrane may be quickly removed by the above procedure.

The second mixture is of value when the nasal mucous membrane is sensitive and when there is an acute exacerbation of the inflammation. The morphine and atropine relieve the sensitiveness and reduce the congestion.

℞.—Ichthyol	gr. xlviii
Lanolin	℥j—M.

The ichthyol ointment may be used in those cases where the secretions are dried in the nasal cavities to stimulate the glandular functions. It may be applied by massage, as described above.

Chemical Caustics.—Chemical caustics are largely replaced by the electrocautery, though there are instances in which the chemical caustics are preferable. The following are recommended:

Carbolic Acid (95 per cent.).—Where a superficial and diffused cauterization is desired, as in an unhealthy granulating surface, carbolic acid is an ideal caustic agent. It does not penetrate deeply, nor does it produce pain. It is also of value in old suppurative ear cases in which there is a foul odor and exuberant granulations. The ear should first be thoroughly freed from secretions with a cotton-wound probe, and the carbolic acid applied afterward. After one minute has elapsed alcohol should be dropped into the meatus to check the action of the carbolic acid and to prevent its action upon the skin of the meatus and auricle during its removal. The carbolic acid should be dropped into the middle ear with a medicine dropper, care being exercised to avoid getting it in contact with the cutaneous surface.

Carbolic acid may also be used in the pharynx where a diffused superficial caustic action is desired, as in a mild case of granular pharyngitis, though in these cases it is usually preferable to puncture the follicles or nodules scattered over the pharyngeal wall with the galvanocautery.

Chromic Acid.—Chromic acid has long been a favorite chemical caustic in the nose, throat, and ear, though it has been largely replaced by the galvanocautery. A few crystals are engaged upon the end of a probe and held over an alcohol or gas blaze to drive off the water of crystallization, but not long enough to reduce them to an ash or cinder. The bead of acid thus formed is drawn across the area to be cauterized, where it rapidly abstracts the water from the tissue and thus destroys or cauterizes its superficial layers.

It may be used in turgescent rhinitis, follicular pharyngitis (granular pharyngitis), and in any other condition requiring cauterization. It is not as deep in its pentration as is usually desired in either of these conditions, hence it is not as reliable as the galvanocautery.

In order to increase its efficiency, Norval H. Pierce and Max A. Goldstein have devised instruments for its subcutaneous use. The submucous method has not, however, appealed strongly to the profession, as the galvanocautery is easily and efficiently applied with equally good or even better results.

It should be remembered that chromic acid is quite irritating to the kidneys, and may cause albuminuria. Its extensive use is, therefore, contraindicated in cases already thus affected.

Technique.—(*a*) Local cocaine anesthesia. (*b*) Puncture the mucous membrane at the anterior end of the free border of the inferior turbinated body. (*c*) Introduce a probe or other elevator through the puncture and tunnel the substance of the mucous membrane, keeping near the periosteum. (*d*) Introduce the Goldstein concealed probe containing the bead of chromic acid into the depth of the tunnel. (*e*) Uncover the bead of chromic acid and withdraw it through the tunnel. This cauterizes the wall of the tunnel within the mucous membrane. If sloughing does not occur the result is very good.

Trichloracetic Acid.—This is a valuable chemical caustic agent and is generally used in a 20 per cent. solution. It has been employed chiefly in tuberculosis of the larynx, in conjunction with curettage, and in hypertrophied and diseased tonsils after splitting the crypt walls.

In laryngeal tuberculosis after the intralaryngeal removal of all the tuberculous tissue available by this route the operated area is swabbed with a 20 per cent. solution of trichloracetic acid, to destroy any remaining tuberculous tissue and to seal up the lymphatic openings to prevent the spread of the tuberculous process.

Kaufmann has recommended the free and deep incision of the crypt walls of the tonsil, especially of those crypts opening into the supratonsillar fossa, and applying a 20 per cent. solution of trichloracetic acid to the incised surfaces. More than one sitting is usually required for this purpose. The object of this procedure is to destroy the diseased

epithelial lining of the crypts and to cause cicatricial contraction of the substance of the tonsil. In this way the tonsil is reduced in size and its non-resistant cryptic epithelium is destroyed.

The acid applications are very painful for a prolonged period of time. This, together with the fact that repeated applications are often necessary, renders the procedure an undersirable one. The complete removal of the tonsil by dissection is a more certain and desirable procedure, as both tonsils may be removed at one sitting.

The Nitrate of Mercury.—A 10 per cent. solution of the nitrate of mercury may be used to cauterize deep sloughing syphilitic ulcers of the nose and throat, as it excites healthy granulation, and thereby checks the sloughing and syphilitic ozena.

Antiseptic and Detergent Solutions.—Cleansing the nose and throat with detergent sprays and washes is not as popular a procedure now as formerly. Experience has shown that such applications exert little curative action on catarrhal and other diseases. They do, however, promote temporary increase in the hyperemia and leukocytosis. Such solutions also stimulate the constrictor muscle fibers of the swell bodies of the turbinals, and thus temporarily reduce the turgescence. The antiseptic action is probably but slight and of little value. The three useful effects of the antiseptic and alkaline nasal washes are therefore as follows: (*a*) Detergent or cleansing effects. (*b*) Muscular contraction of the interlacing fibers of the swell bodies. (*c*) Slight promotion of the reaction of inflammation. The detergent and stimulating solutions recommended are as follows: (1) Seiler's solution. (2) Dobel-Pynchon solution.

(2) ℞.—Powd. sod. bibor. (Squibb).
Powd. sod. bicarb. (Merck).
Thymolin . . . . . Oss
Glycerin (C. P.) . . . . . Oiss

First mix and triturate the two salts and place same in one-gallon bottle, adding one-half the quantity of glycerin; then let it stand twenty-four hours uncorked, with frequent agitations. Next add the remainder of the glycerin and continue the agitations for another twenty-four hours, with the bottle uncorked as before. Lastly, add the thymolin and let stand twenty-four hours. One ounce of this mxture should be added to one pint of water, when it is ready for use.

The solutions may be used with an atomizer, a nasal douche, or a syringe. They may also be used as gargles, although the distinctly alkaline taste is usually disagreeable to the patient.

Oily Solutions for Use with a Nebulizer.—Aromatic and antiseptic drugs may be added to an oily menstruum and thrown into the respiratory tract with a nebulizing device. The action of such mixtures is as an emollient or protective agent, and as a stimulant to the mucous glands. They also cause contraction of the circular muscle fibers of the arterioles, and thereby reduce the congestion. The effects are transient and afford relief without exerting a marked curative effect.

The following formulæ are recommended:

1. Chloretone inhalant.

℞.—Chloretone		gr. xv
Camphor		gr. xxx
Menthol		gr. xxx
Oil cinnamon	ad	♏v
Oil petrolatum		℥ij—M.

2. Acetozone inhalant.

℞.—Chloretone		vij
Acetozone		xv
Oil petrolatum	q. s. ad	℥ij—M.

The spray bottles and nebulizing bottles devised by De Vilbiss (Fig. 17) have proved more satisfactory than any others, as their construction is simple and they rarely need repairing or other attention.

The nasal douche is also a useful device for washing the nasal cavities, and is often preferable to the spray tube, as it does not injure the epithelium of the nasal mucous membrane.

The air pressure allowable for spraying the various mucous surfaces with De Vilbiss' spray apparatus is as follows: (*a*) The nasal mucous membrane, 4 to 10 pounds. (*b*) The epipharynx (nasopharynx), 8 to 20 pounds. (*c*) The mesopharynx (oropharynx), 10 to 30 pounds. (*d*) The hypopharynx and larynx, 10 to 30 pounds. The air pressure needed for the De Vilbiss nebulizing bottles, 10 to 40 pounds.

The regulating tank elsewhere mentioned is of great value in conjunction with the spray and nebulizing tubes.

Solutions Producing Ischemia.—Solutions producing local blanching of the mucous membrane are chiefly derived from the suprarenal glands of sheep. They produce a powerful contraction of the circular muscle fibers of the arteries, which lasts for several minutes. They are on this account of diagnostic and therapeutic value. They also reduce the amount of primary hemorrhage in operations.

The following formulæ are recommended:

℞.—Adrenalin chloride	1 to 1000
℞.—Adrenalin chloride	1 to 2000
℞.—Adrenalin chloride	1 to 4000

It is rarely necessary to use the first formula except when there is a great deal of secretion and blood to dilute the solution. If applied to a clean mucous membrane the second and third formulæ are of sufficient strength to contract the vessels. Local ischemia is produced for diagnostic purposes in the various forms of rhinitis and in reducing the engorgement of the tissues so as to admit of a view of the nasal chambers. Adrenalin is also used to check local oozing of blood after operations.

CHAPTER IV.

THE ETIOLOGY OF DEFORMITIES AND DEVIATIONS OF THE SEPTUM NASI.

"THE chief cause of deviations, and probably of many other deformities of the septum, is *the lack of development of the hard palate.* Trendelenburg was, perhaps, the first to associate the high-arched palate with deformity of the septum, but did not, so far as I can learn, consider it due to a lack of development of the maxillary bones. Loewy expresses somewhat the same idea, but regards the Gothic, or high-arched palate, as of rachitic origin. Zückerkandl rather scouts this idea and says he has been unable to associate rickets with deviated septa, and that it is chiefly the lower jaw, not the upper, which exhibits the rachitic influence. On the other hand, it is in the every-day experience of us all to find the high-arched palate associated with a deviated or otherwise deformed septum" (Freeman). Thus in 302 cases of high-arched palate there were only twelve where there was no marked deformity of the septum. We have 96 per cent. of deformed septa, which shows that there is undoubtedly a very close relationship between the high arch and septal deformities. One must not, however, in drawing conclusions as to the relationship between the Gothic-arched palate and deformities of the septum, consider that every high arch is an abnormal one. In studying the skulls in the Mütter collection, Freeman found that a perfectly straight septum was not uncommonly associated with a high arch. This, however, was chiefly in dolichocephalic heads, in which, with the high, narrow skull, there was associated a high, hard palate, and, in spite of the latter's position, the choanæ were also very high and narrow. The skulls were those of non-Europeans, in whom, as Zückerkandl has pointed out, one finds deformities of the septum much more infrequent than with us. The infant hard palate is of the Gothic type, and anything which interferes with the skull and perfect development of the child prevents also the development of the hard palate and consequently its descent. Indeed, as years go by, the Gothic arch becomes more and more peaked by the further development of the alveolar processes and the eruption of the teeth. On account of the high position of the palate the septum must bend or twist, accommodating itself to the boundaries imposed by the unyielding framework of the bones with which it articulates. Another point in favor of this view is that mentioned by Welcker, that in some cases there is a descent of one of the maxillary bones, the other remaining high arched, in which case the convexity of the deviation of the septum is toward the lower (Freeman).

Eugene S. Talbot has written more extensively and carried on a wider range of observations regarding deformities of the facial bones, including those of the nose, than perhaps any other investigator. His views are briefly presented in the following quotation:

"Morgagni believed they were due to excessive development of the vomer. Trendelenburg held that they were due to a crowding up of a high-arched palate, as he had observed the two conditions frequently connected. Jarvis has reported 4 cases, all in the same family, and suggests they are due to direct hereditary defect, while neurotic or degenerate conditions which underlie the building up of the system may produce the deflection; direct heredity here, as elsewhere, is rare. Schaus' and Welcker's investigations show there is a family development of the facial skeleton. Bosworth and others believe that septal deformities are due to traumatism.

"According to Bosworth, the clinical history of many of these cases affords direct evidence of this, and even in those cases in which the direct injury is not testified to, I think it safe to say that an injury has occurred which may have been of so slight a character as not to have excited special attention at the time of the occurrence. An injury to the nose need not necessarily give rise to the immediate development of a notable deformity, as in fractures, but it may set up a low grade of morbid action, which, going on through a number of years, finally develops a condition by which the normal function of the nose is seriously hampered. The point on which he lays special emphasis is that the deformity is primarily the result of traumatism, and secondarily of a slow inflammatory process which results therefrom.

"Deviation of the nasal septum to one side or the other is the result of an unequal development of adjacent bony parts, more especially and directly of that of the turbinated bones. It depends largely, if not exclusively, upon the development and position of the latter. They, in turn, are dependent in great measure upon the development of the facial bones, which are modified as the facial angle increases and prognathism is lost, the turbinated bones being, as it were, exostosed, not moulded in many directions by adjacent parts, encroaching more irregularly upon the nasal cavity, as their origins are disturbed or dislocated. Freedom of the nasal passages for the transit of respired air is essential. In normal respiration the tendency is for both nostrils to share equally. The natural consequence is that the vomer, the ossification of which is incomplete until puberty, is deflected and occupies, as a rule, nearly a midway position between the bony prominences on either side. Deflection of the septum therefore is a compensatory arrangement in the evolutionary variations of facial development. It is therefore most frequent in the higher races, while in the lower its occurrence is markedly less.

"Instability of tissue building is to be expected in neurotics and degenerates. It is easy to see how, with such an unstable bone tissue to build upon, the mucous membrane of the nose may undergo atrophy, hypertrophy, or adenoid growths resulting in mouth breathing.

"Total collapse of the outer walls of the nose is frequently observed among neurotics and degenerates. This is associated with arrest of development of the bones of the face and jaws, deformities of the dental arch, contracted chest, round shoulders, husky voice, etc. In most cases of this description the nose is very long and thin. The nasal bones are excessively developed, and there is marked deflection of the septum. Frequently nasal catarrh is present. During inspiration turgescence of the swell bodies is produced and nasal breathing is impossible."

An analysis of the foregoing quotations from Freeman and Talbot gives an epitome of some of the theories that have been advanced as to the etiology of deformities of the nasal septum. These theories may be tabulated as follows:

1. Morgagni thought they were due to excessive development of the vomer; the vomer crowding upward against the descending perpendicular plate of the ethmoid caused septal deflection to one side, in order to allow of continued development.

2. Trendelenburg and Freeman think the chief cause of the deflection is in the persistent high or Gothic arch of the hard palate. The vomer and the perpendicular plate of the ethmoid are thereby crowded and deflected in order to find room for further complete development.

3. Jarvis believes the chief cause is heredity and quotes observations in support of this theory.

4. Schaus and Welcker advance the hypothesis of a faulty development of the facial bones, including those of the nose.

5. Bosworth argues that traumatism is the chief cause of deflections.

6. Talbot takes the theory of Schaus and Welcker and carries it still farther, and says that malformations of the septum are due to neuroses or stigmata of degeneracy, which result in irregular development of the facial bones. He believes that the pigeon chest, adenoids, and deformed nasal septa are all due to the same neurotic influences, which arrest development in some parts while in others there is an increase in the development.

It is difficult to arrive at a final conclusion concerning these theories, as data of almost any kind can be found by one who diligently searches for it. It is easy to say there is excessive development of the vomer, and to report so many thousands of observations on skulls in which this theory is substantiated. Trendelenburg and Freeman have satisfied themselves that the Gothic arch is the cause. They say the high arch of childhood does not descend as it should, and that the space for the vomer and the ethmoid plate is thereby encroached upon and deflection results. Talbot and others have studied the so-called high arch and find that it rarely exists, also that in some instances there is lack of lateral development of the superior maxillæ, which gives rise to the Gothic arch, or what appears to be an abnormally high arch. Actual measurements show them to be no higher than normal. Then, too, Talbot claims that many hard palates which are lower than the average are attended by septal deformities. He does not deny that traumatism does in some instances account for septal deformities, but he does deny that it is the chief cause

of deviations. He believes that consanguineous marriages predispose to the neuroses and that facial deformities result therefrom. He holds that the facial bones are transitory and more subject to developmental influences than most parts of the skeleton, hence are either arrested or overdeveloped in those tainted with the stigmata of degeneracy.

Dr. Talbot's views present the most rational explanation of this much mooted question that has yet been offered. He does not name the overdevelopment of a particular bone nor does he claim the failure of the palatine arch (roof of the mouth) to descend as being the cause of deviations of the septum. If these conditions are present he claims they are incidental signs of a neurosis or degeneracy. The factor back of an excessive development of the vomer or of a Gothic or narrow (not high) arched palate is also back of the deformed septum.

In conclusion I will epitomize the etiology of deformities of the nasal septum as follows, in the order of their importance:

(*a*) Neuroses or stigmata of degeneracy which cause either an arrest or an excessive development of the bones of the face, including the nose; one of the expressions of the neurosis being deformed septa (Talbot).

The theories of Trendelenburg, Freeman, Morgagni, Jarvis, Schaus and Welcker are swallowed up in that of Talbot. The individual theories they advance imperfectly convey the true explanation, while Talbot's comprehends them all and strikes at the root of the matter.

(*b*) Bosworth's traumatic hypothesis is true as to a certain number of cases. That it explains a majority or even a large percentage of them is doubtful.

The phraseology used by Talbot may be objectionable, inasmuch as it assumes that there are "stigmata of degeneracy" present in all cases not due to traumatism. It would be better perhaps, to say that deflections of the septum are usually due to an incoördination in the development of the bones of the face, including those of the nose.

A CLINICAL CLASSIFICATION OF DEVIATIONS OF THE SEPTUM NASI.

Malformation and deviations of the nasal septum may be either developmental or traumatic in origin. When developmental, any or all portions of the septum may be involved, whereas if it is of traumatic origin the anterior or cartilaginous portion only is affected, except in exceptional cases. The point of chief clinical interest, however, is in the type and location of the deformity rather than in its origin. Even the type and location of the deviation have to a considerable degree lost their clinical significance in so far as treatment is concerned, since the perfection of the submucous resection of the septum has been accomplished, and so many types of septal malformations are found to be amenable to it.

Cartilaginous Deviations.—When the deformity is limited to the cartilaginous portion of the septum it is one of three types, viz.:

(*a*) A deflection of the anterior portion generally known as the columnar cartilage (Fig. 22). The antero-inferior border of the cartilage is turned outward into the vestibule of the nose and obstructs the respiratory passage. This type of deviation is not as serious in its consequences as those that obstruct the nasal chamber in the region of the middle turbinated body, as it only interferes with the areation of the nasal chamber and accessory sinuses, the drainage being unimpaired, except in so far as it depends upon the mechanical aid of the air current in propelling the secretions to the epipharynx.

Fig. 22

Deviation of the anterior portion of the septal cartilage, which may be removed through Hajek's incision by sharp dissection.

(*b*) An angular deviation in an antero-posterior direction is serious in proportion to its proximity to the middle turbinal. If it is limited to the region of the vestibule or of the inferior turbinal it is of less clinical importance, though its removal is still indicated. If it obstructs both the middle and the inferior meatuses its removal is of the greatest importance, as it interferes with both the drainage and ventilation of the nasal chamber and the accessory sinuses of the nose.

(*c*) A perpendicular deviation of the cartilage only interferes with the ventilation, without blocking the drainage of the secretions, except anteriorly, which is inconsiderable.

Osseous Deviations.—For clinical purposes osseous deviations of the septum may be divided into three types:

(*a*) A bony ridge or crest along the upper border of the crista nasalis and the vomer. The direction of this deformity is backward and upward, usually beginning anteriorly about one-half inch from the border of the inferior portion of the nasal opening, near the floor of the nose. A ridge in this location does not necessarily obstruct the normal inspiratory tract (middle and superior meatuses), nor does it greatly interfere with the drainage of the secretions. It does, however, encroach upon the inferior turbinated body, and thus causes irritation of this important physiological organ and produces a sense of stuffiness of the nose. It interferes also to some extent with the posterior drainage of the secretions. It also projects to some extent into the respiratory pathway and forms a favorable place for the desiccation of the secretions. Crusts are, therefore, generally found upon the anterior extremity of the ridge, and in blowing the nose become detached, tear the epithelium, and give rise to epistaxis. While the ridge may not cause nasal obstruction, it should be removed on account of the mechanical irritation of the inferior turbinal and the resulting turgescent and hypertrophic rhinitis.

(*b*) The perpendicular plate of the ethmoid bone is often convex or cup-shaped and impinges upon the middle turbinal upon the side of

convexity. This is, perhaps, one of the most serious obstructive lesions of the septum, as it obstructs both the drainage and the ventilation of the superior meatus, and of the frontal, ethmoidal, and sphenoidal cells. Sufficient importance has not been given this type of deviation, hence I wish to lay special emphasis upon it. It is this type of deviation, more than any other, that gives rise to conditions which eventuate in catarrhal and suppurative inflammations of the accessory sinuses. In the first place the secretions are retained, undergo decomposition, and impair the vitality of the mucous membrane. Infection and inflammatory reaction naturally follow. The ostei of the sinuses become closed from swelling of the mucosa, and this still further interferes with the drainage. Furthermore, the ventilation of the superior meatus and of the obstructed sinuses is partially or completely lost, and the decomposition of the secretions is thereby encouraged. The oxygen of the air within the obstructed sinuses is absorbed and rarefaction results.

The blood of the lining mucous membrane is attracted to the parts by the negative pressure thus created, and catarrhal inflammation is favored. If, in the course of events, active pus-producing microbes, as the streptococci, staphylococci, diplococcus pneumoniæ, etc., find lodgement there a suppurative inflammation of the sinuses results.

It is obvious that this type of deviation is of the greatest importance and that the indications for its removal are urgent.

Fig. 23

A compound deviation of the septum. The upper deviation is of the greater clinical importance, as it blocks the ventilation and drainage of the sinuses.

(*c*) The combined deviation, including the ridge along the crest of the vomer and the convexity of the perpendicular plate of the ethmoid bone (Fig. 23), is a very common type of septal deformity, and often calls for correction at the hands of the surgeon. The indications for operative interference are given under (*a*) and (*b*) of Osseous Deviations, and need not be further discussed here. The indications are obviously more urgent than in either the simple ridge or the convex perpendicular plate of the ethmoid, as the ill effects of both deviations are to be reckoned with. It should be noted that the convexity of the perpendicular plate of the ethmoid is usually on the opposite side from the ridge along the crest of the vomer, though it may be on the same side. It should also be noted that the cartilaginous portion of the septum is deviated with the perpendicular plate of the ethmoid, and should, of course, be included in the operative field.

(*d*) There are still other deformities of the osseous septum, as the so-called spurs on the anterior portion, which in reality are composed of the crista nasalis and cartilage in combination, though they may be true osteomata.

THE COMPLICATIONS AND SEQUELS OF OBSTRUCTIVE LESIONS OF THE SEPTUM.

A review of the preceding paragraphs naturally leads to the conclusion that many of the catarrhal and suppurative inflammations of the nasal and accessory sinuses are often due either directly or indirectly to obstructive malformations of the septum.

The whole truth is not expressed in the above statement; nevertheless, the deduction is fundamental and should form the working basis in a large majority of cases. The etiology of the inflammatory diseases of the nose and accessory sinuses is given in Chapter VI.

The following morbid conditions within the nose and accessory sinuses are either directly or indirectly caused, or their course is often largely influenced, by a preëxisting deviation of the septum:

1. Acute rhinitis or coryza.
2. Chronic turgescent rhinitis.
3. Chronic hypertrophic rhinitis.
4. Chronic hyperplastic rhinitis.
5. Acute sinuitis, catarrhal and suppurative.
6. Chronic sinuitis, catarrhal and suppurative.
7. Polypoid degeneration of the mucosa of the nose and sinuses.
8. Atrophic rhinitis.

It is apparent, therefore, that deviations of the nasal septum should be a primary rather than a secondary subject in a systematic text-book on diseases of the nose. They are, therefore, herein discussed before taking up the consideration of the inflammatory diseases which are so largely dependent upon them.

The indications for the correction, or the removal, of obstructive deviations of the septum are based upon the following considerations:

1. If the deviation of the septum does not interfere with (*a*) the functional activity of the swell bodies of the inferior turbinals, (*b*) the ventilation of the middle and superior meatuses and the accessory sinuses, and (*c*) the drainage of the same areas it should not be subjected to surgical treatment. In other words, deviations of the septum should never be corrected simply because they are departures from the median line of the nose, but only when they obstruct ventilation and drainage, or interfere with the function of the swell bodies.

2. The positive indications for the correction of deviated septa are present when the septum (*a*) interferes with the normal functional activity of the swell bodies, or (*b*) prevents the normal ventilation and (*c*) drainage of the nasal chambers and accessory sinuses.

If, for instance, a ridge along the crest of the vomer is so prominent

as to touch the inferior turbinal, or if it extends forward into the vestibule far enough to partially obstruct the inspiratory current of air, and thereby produces rarefaction of the air posterior to the obstruction, it should be removed. The same is true in reference to anterior angular deflections of the cartilaginous septum.

If the deviation is higher up, in the region of the middle turbinal, and interferes with the ventilation of the superior meatus and the accessory sinuses draining into it, it should be corrected.

If a septum is tested by the foregoing standards, with a negative result, it should not be subjected to surgical correction, no matter how great the deviation or deviations may be.

If, on the contrary, a septum is tested by the foregoing standards, with a positive result, it should be corrected by some surgical procedure.

THE SYMPTOMS OF DEVIATIONS OF THE SEPTUM.

The Subjective Symptoms of Obstructive Deviations.—The subjective symptoms of nasal obstruction are (*a*) a sense of fulness, either in the lower or upper portion of the nasal chambers, according to the location of the deviation. If, for instance, the deviation impinges upon the swell body of the inferior turbinal there is a sense of stuffiness or fulness in the lower portion of the nose; whereas, if it is in the region of the middle turbinal there is a sense of stuffiness or pressure through the bridge of the nose between the eyes.

(*b*) If the obstruction in the region of the middle turbinal is great enough, or has given rise to a catarrhal inflammation in the anterior ethmoidal cells, there may be pain at the inner angle of the orbit over the lacrymal bone, either with or without pressure. When pain is elicited upon pressure in this region, it is very significant of anterior ethmoidal inflammation and possibly of the frontal sinus as well.

(*c*) Frontal headache is frequently present in high deviations, and is most severe in the morning upon awakening. If of ocular origin it disappears at night and recurs during the day while using the eyes.

(*d*) Dizziness or vertigo is sometimes a direct expression of pressure or irritation in the ethmoidal and the frontal sinuses. The dizziness is often exaggerated, or is produced by stooping forward or suddenly rising from the stooping posture, and is present when the eyes are closed. Dizziness or vertigo of ocular origin is often relieved when the eyes are closed, as the irritation from the light is thereby eliminated. Dizziness of nasal origin is aggravated by jarring the body.

(*e*) Asthma of reflex nasal origin is sometimes due to intranasal pressure and irritation in the middle turbinal and ethmoidal regions. This is particularly true when polypi are present.

(*f*) The nasal secretions are changed in character and quantity. If a chronic catarrhal inflammation of the lower portion of the nasal mucous membrane has developed the secretions are heavier than normal, and expulsion is only accomplished by blowing the nose. If the obstruction

FIG. 24

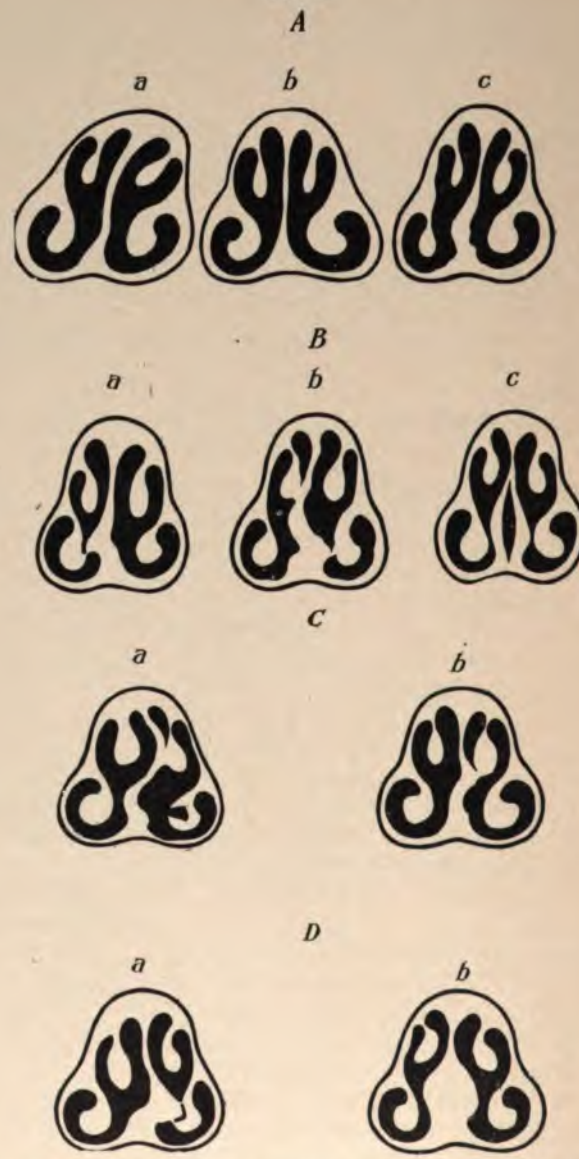

A. Types of non-obstructive septa. *a*, deviated from the median line; *b*, normal, straight septum in the median line; *c*, deviation of the lower portion of the septum with a concavity in the left nasal chamber, but with compensatory hypertrophy of the left inferior turbinated body.

B. Types of obstructive septa. *a*, ridge pressing against the inferior turbinal; *b*, ridge pressing against the left inferior turbinal and a convexity higher up on the right side obstructing the olfactory fissure on that side; *c*, a split septum causing double obstructive convexity of the septum.

C. *a*, an S-shaped septum causing obstruction in the inferior portion of the nasal chamber on the right side and the superior portion of the chamber on the left side; *b*, a high, angular deviation of the septum causing obstruction of the olfactory fissure of the left side.

D. *a*, marked deviation of the septum along the crest, the vomer wedged firmly against the left inferior turbinal; *b*, abscess or hematoma of the septum obstructing both nasal chambers.

is in the middle turbinal and ethmoidal regions and a simple inflammation is present in the ethmoidal cells the secretion is sometimes watery in consistency, though it may be mucoid and quite acrid in character. Associated signs of this type of secretion are the reddened and irritated appearance of the mucosa and a fissure or eczematous eruption of the margins of the nostrils and the upper lip.

(*g*) Postnasal or epipharyngeal "dropping" is usually complained of. The olfactory fissure may be obstructed, and, as the closure prevents drainage through the fissure, the secretions flow backward over the middle turbinal into the epipharynx.

(*h*) Intermittent stenosis is usually present in those cases in which there is an anterior deviation which does not completely block the nasal passage. The obstruction interferes with the intake of air, and the descent of the diaphragm acts as the piston valve of a syringe and produces

FIG. 25

A traumatic deformity of the external nose and of the septum. The straight dotted line indicates the median line of the nose while the curved one indicates the deviation of the septum.

rarefaction of the air in the nasal chamber posterior to the obstruction. This in turn developes turgescence of the erectile tissue and a temporary stenosis.

(*i*) Alternating stenosis is another sign of an obstructive lesion in the lower portion of the nasal chambers and is due to the same causes given in the preceding paragraph. The associated disease is usually turgescent rhinitis.

The Objective Symptoms of Obstructive Deviations.—(*a*) The appearance of the septum and its relation to the various aspects of the outer walls of the nose constitute the most important objective symptoms. For example, if the septum is characterized by a ridge on the left side opposite the inferior turbinal and by a convexity in the region of the middle turbinal on the right side an examination shows the deviations and the impingement of the same against the inferior turbinal on the left side and the middle turbinal on the right side (Fig. 24 B, *b*). Each

case should be carefully examined with reference to the equal distribution of space in the respiratory tract of the nose and with reference to its adequacy for physiological purposes. The various types of deviations, of course, present different pictures upon examination, each having its peculiar clinical significance in proportion to the degree of obstruction caused by it, and in particular to its proximity to the middle turbinated body.

(*b*) The presence of pus and dried secretions in the olfactory fissure between the deviation of the septum and the middle turbinal is suggestive of the causative relationship of the deviation to the diseased posterior ethmoidal sinuses, from which the secretions in all probability flow.

(*c*) Hemorrhage or epistaxis is often a sign of a deviated septum, more particularly in its lower and anterior portions. A prominent crest projecting into the breathway is subjected to an undue exposure to the air current and the secretions become dried and adherent to it. When the crust is detached, either by blowing or picking the nose, the epithelium is torn from the mucous membrane and hemorrhage results.

(*d*) External deformity of the nose is often indicative of a corresponding deviation of the septum (Fig. 25).

CHAPTER V.

THE CHOICE OF SEPTUM OPERATIONS. THE SURGICAL CORRECTION OF OBSTRUCTIVE LESIONS OF THE SEPTUM.

THERE is no one method of correcting obstructive deviations or malformations of the septum nasi. The submucous resection of the septum is the most nearly universally applicable, though there are some deviations in which it can be used with great difficulty, whereas another method of surgical procedure can be easily and successfully used. Under such conditions poor judgment would be shown in selecting the submucous operation. In choosing a surgical procedure a method should be adopted that will remove the obstructive lesion of the septum with the simplest technique and the least risk to the integrity of the nasal septum. The object of the operation should be to establish free drainage and ventilation of the nasal chambers and of the accessory nasal sinuses (see Etiology of the Inflammatory Diseases of the Nose and Accessory Sinuses), rather than to exploit one method of operating over another. It will be my endeavor, therefore, to give some general rules to guide the surgeon in the proper selection of an operation for the correction or removal of obstructive lesions of the nasal septum.

Cartilaginous Deviations.—When the deviation is limited to the septal cartilage other operations than the submucous resection may often be chosen to correct it; indeed, they may often be chosen in preference to the submucous resection. This is not of universal application, however. An extreme angular deviation of the septal cartilage (Fig. 35) is rather difficult to correct by the submucous method, and is easily corrected by the Sluder operation (Figs. 34, 35 and 36). The Sluder operation is practically limited to extreme angular deviations, as stated by its author.

A cup-shaped deviation may be corrected by the Asch, the Gleason, the Watson, the Price-Brown, or the submucous resection operation. The simpler of these procedures are the Watson, the Gleason, and the Price-Brown operations, and of these the Watson is, perhaps, the more simple. The choice of operation will largely depend upon the location of the cup-shaped deviation and the thickness of the cartilage surrounding it. If, for example, the cartilage anterior to the deviation is extremely thin, or has become fibrous from an antecedent chondritis, the triangular flap of the Watson operation will not engage against the opposing incised cartilage. If, on the other hand, the cartilage anterior to the cup is of the usual thickness and texture the Watson operation may be used with excellent effect. The cup deviation may also be corrected by the Gleason operation if the cartilage below the cup is firm and of the usual thickness. The H-incision of Price-Brown is also well adapted to this type

of deviation. The perpendicular incisions should be made, one anterior and the other posterior to the cup, and the intersecting horizontal incision through the centre of the cup. The two rectangular flaps thus made are forced to the side of the convexity, thereby removing the obstruction. The flaps should be held in position with a splint tube or gauze dressing for two or more weeks. If for any reason neither of these operations is applicable or desirable the removal of the cup-shaped cartilage may be accomplished by submucous resection (Figs. 32, 33, 37, 38, 39, 44 and 50).

Compound or S-shaped deviations or compound angular deviations of the septal cartilage are peculiarly well adapted to the Kyle operation (Figs. 47 and 48). The redundancy of cartilage may be removed with the V-shaped file saws at the crest of each convex surface, thus permitting the septum to be forced to an upright position in the median line. This type of deviation is also easily corrected by the submucous operation by the author's method with the swivel knife, and is perhaps more fully and surely thus corrected. In this type of deviation there is usually little difficulty in elevating the mucoperichondrium, after which the cartilage is readily encircled with the swivel knife and removed *en masse* with dressing forceps.

Simple angular (anteroposterior) deviations and L-shaped angular deviations of the septal cartilage are usually very successfully corrected by the Watson operation (Figs. 32 and 33), though they are equally well adapted to the submucous resection operation with the swivel knife.

The deviated portion of the cartilaginous septum may be readily removed by submucous resection in practically all types of deviations except the extreme angular type, and even this may be thus removed. It is often preferable, however, to use one of the other methods of operating, as they are simpler and almost, if not quite, as satisfactory in their results. When, however, the obstructive deviation also involves the bony portion of the septum it is often expedient to adopt a method of operating that will be equally applicable to both the cartilaginous and bony deviations. Obstructive deviations usually involve both the cartilaginous and osseous framework of the septum, hence the indications given above are not unqualifiedly applicable, except in deviations limited to the cartilaginous portion of the septum. One of the chief objections to the operations other than the submucous resection is the necessity of wearing a dressing or splint in the nose for two or more weeks. This alone should often influence the surgeon to elect the submucous operation.

Osseous Deviations.—As osseous deviations of the septum are nearly always associated with one or the other of the types of cartilaginous deviations already referred to a method of operating should be adopted that will successfully remove both the cartilaginous and the bony deviations. The operation most universally applicable is the submucous resection. There are, however, important exceptions to this rule, notably a simple spur or ridge, unattended by other deviation of the septum. Another important exception is a deviation limited to the perpendicular plate of the ethmoid, which may be successfully reduced with Roe's forceps.

1. *A simple spur or ridge* may be successfully removed with a saw or spokeshave, with less risk to the integrity of the septum than it can by submucous resection. If, however, the spur or ridge is accompanied by a deviation of the cartilage or the perpendicular plate of the ethmoid it will become necessary to adopt some other method of procedure, preferably the submucous resection.

2. *Spurs or Ridges Associated with a Cartilaginous Deviation.*—These types of compound deviation may be effectively corrected by first removing the ridge with a saw or spokeshave, and subsequently correcting the cartilaginous deflection by one of the methods described under cartilaginous deviations; or both may be removed at one time by the submucous resection operation.

3. *Spurs and Ridges Associated with an Obstructive Deviation of the Perpendicular Plate of the Ethmoid.*—These types of compound osseous deviations may also be corrected by two operations, or by a single operation. The ridge or spur may be removed with a saw or spokeshave at one time and the deviation of the perpendicular plate of the ethmoid at a subsequent time, with Roe's crushing forceps. The submucous resection operation is usually preferable, as the operation is completed at one sitting, and the results obtained are usually much better than by the two operations.

4. *A Simple Deviation Limited to the Perpendicular Plate of the Ethmoid.*—Two operative procedures are applicable to this type of deviation, one the Roe operation and the other the submucous resection operation. Of the two operations my own experience is limited to the submucous resection, though I can readily conceive the successful application of Roe's method with his crushing forceps.

As generally practised, the submucous resection operation sacrifices more or less of the cartilage, whether it is deviated or not. This is done to expose the bony parts to operative interference. I have, in a few cases, in which the deviation was limited to the perpendicular plate of the ethmoid, made the incision just anterior to the union of the cartilage and perpendicular plate of the ethmoid, elevating the mucoperiosteum over the ethmoid plate on the side of the incision, then extending the incision through the cartilage and elevating the mucoperiosteum on the opposite side of the plate, as is done when the Killian incision is made. After the elevation was thus completed the deviated portion of the perpendicular plate of the ethmoid was removed with the Foster-Ballenger forceps (Figs. 65 and 70). While this procedure is rather difficult, on account of the inability to see the parts while the forceps are in the nasal chamber, it can be done by exercising the proper care in instrumentation. The chief difficulty encountered is to avoid the inclusion of the mucoperiosteum, upon the side of the incision, within the bite of the forceps. A probe, or flat applicator, introduced into the mucoperiosteal pouch, to lift the mucoperiosteal membrane away from the bone, will effectually guard the membrane from the forceps.

Finally, it should be said that the submucous resection operation is of the most universal application for the correction of obstructive

deviations of the septum, and that by it the most perfect correction may be made. On the other hand, there are many cases in which the deviation may be satisfactorily corrected with greater ease, with less danger of affecting the integrity of the septum and with less shock to the patient. Furthermore, there is always a possibility of producing a sunken nose by the removal of a portion of the cartilaginous septum by the submucous operation. While the accident has rarely been recorded, it has doubtless occurred oftener than is generally known. This accident is particularly liable to occur in deviations of traumatic origin, as in these cases perichondritis and chondritis sometimes followed the injury and destroyed the cartilage, especially along the ridge of the nose. If the parts are still further weakened by the removal of cartilage the ridge of the nose may fall in. In all cases sufficient cartilage should be left along the ridge of the nose to ensure ample support.

THE SURGICAL CORRECTION OF OBSTRUCTIVE LESIONS OF THE NASAL SEPTUM.

Having first determined that the deviation is an obstructive one (see indications) the surgeon should next elect the procedure that will afford the greatest amount of correction with the least shock and inconvenience to the patient. The type of deviation will have much to do with the election of the operative procedure. No hard-and-fast rules can be laid down as to the choice of operation, each case being somewhat different from all others.

The following operative methods will, however, with slight variations in technique meet nearly all the indications for the surgical correction of the various types of septal deviations.

1. **Soft Hypertrophies of the Septum.**—Soft hypertrophies of the mucous membrane of the septum occur at two points, namely: (*a*) at the anterior portion just opposite to or below the inferior margin of the middle turbinated body, and (*b*) at the posterior end of the vomer. In the first instance the enlargement closes the anterior end of the olfactory fissure and interferes with the proper ventilation of the superior meatus and the sinuses draining into it. Its reduction is best accomplished as follows:

First, induce local anesthesia with a 5 to 10 per cent. solution of cocaine applied to the parts with a thin pledget of cotton.

Second, make one or two linear incisions through the hypertrophied tissue with the actual cautery at a bright cherry-red heat (Fig. 26).

This procedure may be repeated two weeks later if the first application was insufficient to reduce the mass.

In posterior hypertrophy of the septum the same procedure may be followed, having first reduced the engorgement of the turbinated bodies with a spray of 1 to 2000 solution of adrenalin.

2. **The Removal of Spurs and Ridges with a Saw.**—When the septum is normally placed, with the exception of a spur or ridge, the obstructive

lesion may be removed with a nasal saw (Fig. 27). If the deviation is a pronounced one, it may be preferable to resort to the submucous resection operation, as all other deflections can be removed by it at one time.

FIG. 26

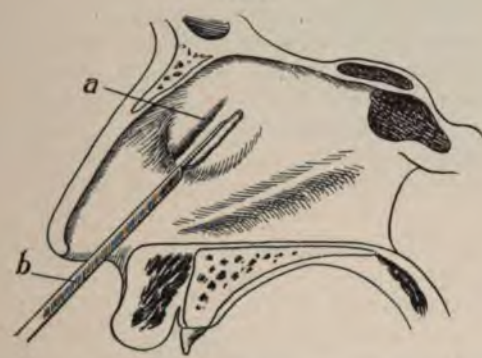

The reduction of an anterior hypertrophy of the mucous membrane of the septum. (Pynchon.) Region of anterior end of the middle turbinal. It is sometimes called the tubercle of the septum. *a*, linear cauterization; *b*, cautery electrode making a second linear incision. Apply at cherry-red heat.

FIG. 27

Bosworth's saw.

FIG. 28

FIG. 29

FIG. 28.—*a*, ridge or deformity of the septum; *b*, the inferior turbinal encroached upon by the deviation; *c*, line of incision to be followed in removing the ridge with a saw.

FIG. 29.—Showing the method of applying the saw to remove ridges from the septum.

The technique of the saw operation is as follows:

(*a*) Induce local anesthesia over the spur or ridge by the application of pledgets of cotton saturated with a 5 per cent. solution of cocaine. After ten minutes remove the cotton, as anesthesia is usually complete in this time.

(*b*) Introduce the nasal saw beneath the ridge or spur with its cutting edge turned inward and upward, as though it were the intention to saw obliquely through the septum (Figs. 28 and 29).

(*c*) After the saw is engaged in the bony tissue direct it upward (Fig. 29), parallel with the surface of the septum, until the ridge or spur is completely severed from it.

It is not necessary to make a preliminary incision along the crest of the spur or ridge for the purpose of elevating the mucoperiosteum, as experience has shown that healing takes place quite as quickly and satisfactorily when the mucoperiosteum is removed with the bone. Healing takes place by granulation and the periosteum is extended by the same process of repair over the sawed surface. In a number of cases thus operated, and subsequently operated upon by the submucous method, I have had little difficulty in elevating the mucoperiosteum over the old field of operation.

FIG. 30

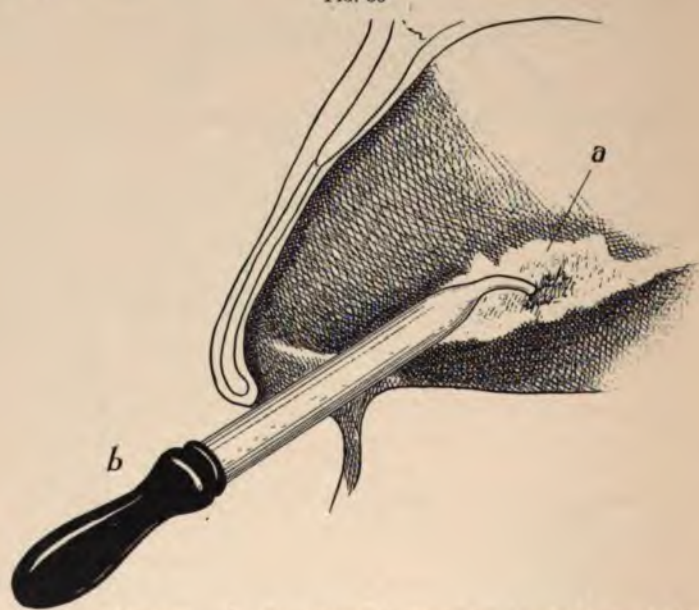

Pischel's collodion dressing. *a*, a thin pledget of cotton placed over the wound after the removal of a septal ridge with a saw; *b*, the collodion being applied to the cotton with a medicine dropper.

The postoperative dressings should be omitted altogether unless the method described by Dr. Pischel is adopted. He first secures absolute dryness of the wound, and then applies a thin pledget of cotton over the surface and saturates it with an ethereal solution of collodion by means of a medicine dropper and allows it to dry in place (Fig. 30). He thus hermetically seals the wound with the collodion film and protects it from the nasal secretions. The collodion dressing should be left in position until it is voluntarily thrown off, which usually occurs in three or four days. Subsequent dressings are not required.

3. **The Removal of Spurs and Ridges with the Spokeshave.**—The spokeshave may be used instead of the saw, though it is attended by more risk to the integrity of the septum and shock to the patient.

The technique is as follows:

(*a*) Local anesthesia.

(*b*) Make an elliptical incision around the base of the spur or ridge so as to prevent tearing of the mucous membrane with the spokeshave.

(*c*) Introduce the spokeshave (Fig. 31) into the nostril until its blade engages the posterior end of the ridge, and then pull it forward with considerable force, again and again if necessary, until it splinters the ridge from the septum. The elliptical incision previously made saves the mucous membrane from mutilation.

(*d*) The dressing may be omitted or the collodion dressing may be used.

Caution.—So much force is usually required to engage the spokeshave that there is danger of fracturing the cribriform plate and causing meningitis.

Another accident which should be taken into consideration is perforation of the septum. It is not possible to exercise full control over the course of the spokeshave, as it does not cut through the tissue (bony) but acts as a wedge. I have sometimes resorted to a little procedure which in a measure controls the direction of the splintering, as follows:

After making the elliptical incision, grooves are made with a saw at the base of the ridge on its upper and lower aspects. The grooves guide the spokeshave as it comes forward through the bone and thus prevent cutting too deeply into the tissue. The grooves weaken the attachment of the ridge and render its removal possible with less force.

Fig. 31



Chaleway's spokeshave.

The Watson Operation.—The Watson operation consists in making one or more incisions through the septum and then pushing the projecting or deviated portion toward the concave side, the bevelled edges formed by the incision retaining the septal flap in its new position.

Indications.—This operation is suitable for angular deviations of the cartilaginous portion of the septum, but is not applicable to bony deviations or thickenings. When the deviation is simple, that is, when there is a single angular deviation extending anteroposteriorly, the incision is made from the convex side, beginning at the posterior extremity of the deviation and beneath it, extending to its anterior extremity, and thence curving forward and upward beyond it, as shown in Fig. 32.

In compound deviations two incisions are made—one beneath the horizontal crest and the other at right angles to the first, and behind the perpendicular deviation, as shown in Fig. 33.

Technique.—(*a*) Local anesthesia.

(*b*) Make the incision or incisions with a short-bladed bistoury.

(*c*) Introduce the index finger or a broad, blunt instrument into the nose on the side of the septal convexity and force the deviated portion to the opposite side. If the single incision is made (Fig. 32), force the angu-

lar flap to the opposite side along the entire line of incision. If the double incision (Fig. 33) is made, first force the anterior triangular flap (*a*) to the concave side and then force the posterior triangular flap (*b*) to the concave side. The bevelled edges formed in making the incision help to hold the flaps in the new position.

(*d*) Additional support should be given to the flaps by a tampon on the side of the convexity or by a septum tube splint (Fig. 45) for a period of from seven to ten days.

Sluder's Operation.—Dr. Greenfield Sluder has used a modification of the Watson operation, with excellent results, and he especially recommends it in children with extreme angular cartilaginous deflections.

FIG. 32

FIG. 33

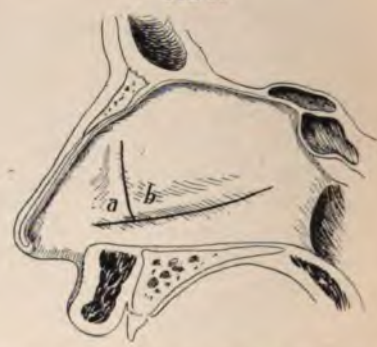

FIG. 32.—The Watson operation for correcting a simple angular deviation of the cartilaginous septum. The angular flap is forced to the opposite or concave side, and held in position with a gauze dressing or with a nasal tube.

FIG. 33.—The Watson operation for a combined horizontal and perpendicular bowing of the nasal septum. An incision through the mucous membrane and framework of the septum beneath the horizontal convexity, and a secondary perpendicular convexity. The secondary incision should unite with the primary one. The anterior triangular flap *a* thus formed should be pushed with the finger to the concave side, and then the posterior flap *b* should likewise be forced to the concave side and held in position with nasal splints for a week or ten days while union takes place.

Technique.—(*a*) Cocaine anesthesia.

(*b*) Make three parallel incisions through the entire thickness of the septum parallel with the crest (Figs. 34 and 35). The middle incision should extend the whole length of the crest. The other incisions are made at the apices of the less acute angles *a* and *b*. Two strips of cartilage are thus formed, their only attachments being at the anterior and posterior extremities.

(*c*) Either the upper or lower strip is then forced to the concave side with the index finger or a blunt instrument.

(*d*) The other strip is likewise displaced to the concave side, thus causing the strips to overlap, as shown in Fig. 36.

(*e*) An Asch nasal tube is then introduced on the side of convexity to hold the strips in position while union takes place, that is for from two to three weeks. The tubes are removed and cleansed every two to seven days, according to the amount of irritation produced by them.

If the opposed surfaces are curetted before coaptation, union will take place more rapidly. Dr. Sluder reports 24 cases, 5 in adults and 19 in children, without perforation of the septum, all of his cases being extreme deflections.

4. **The Gleason Operation.**—The election of this operation may be made when the septum is bowed or cup-shaped, and without a heavy

Fig. 34

Fig. 35

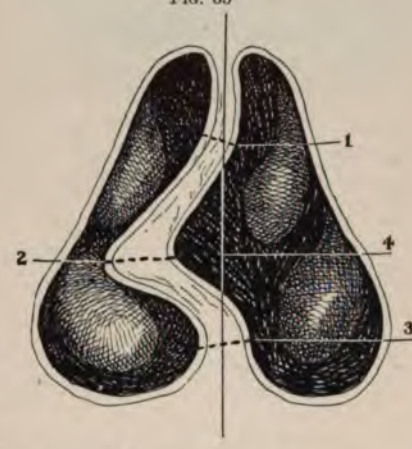

Fig. 34.—Sluder's septum operation. 1, 2 and 3, the lines of incision.

Fig. 35.—Sectional view of the nose before the Sluder operation. 1, 2, 3, the lines of incision shown in Fig. 34. 4, the median line of the nose.

ridge along the crest of the vomer. It consists essentially of a U-shaped incision extending either entirely through the septum and both its mucous coverings, or only through the mucous membrane of one side and the bone and cartilage, the opposite membrane being left intact. The incision may be made with a saw, though the portion through the cartilage may be made with a knife.

Fig. 36

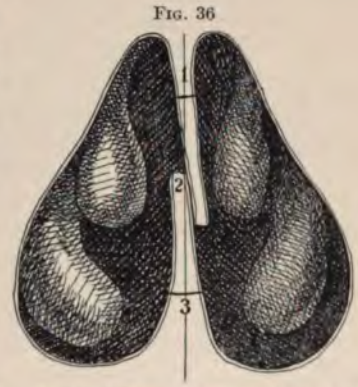

Sectional view of the nose after the Sluder operation. 1, 2, 3, the lines of incision as shown in Fig. 34. The bands of cartilage overlap and should be held in position with a nasal tube.

The Technique.—(*a*) Local anesthesia is induced with a 5 to 10 per cent. solution of cocaine applied to the mucous membrane on both sides of the septum.

(*b*) The nasal saw is applied on the convex side of the septum at its inferior portion, and the incision is carried through the septum in an upward direction, the ends of the saw remaining upon the side of convexity while its middle portion passes through to the concave or opposite side. A U-shaped incision is thus made with a tongue-flap suspended between the limbs of the U (Figs. 37 and 38).

On account of the low position of the nasal orifice the anterior limb of the incision is usually too short. This is obviated by removing the saw and re-inserting it through the anterior limb and continuing the incision upward, or it may be extended with a knife, as the framework of the septum is cartilaginous in this region.

Fig. 37

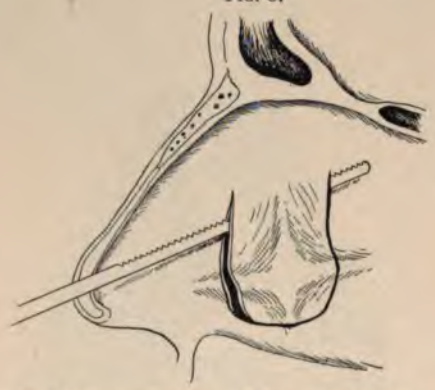

The Gleason operation. A tongue flap of the deviated portion of the septum.

Fig. 38

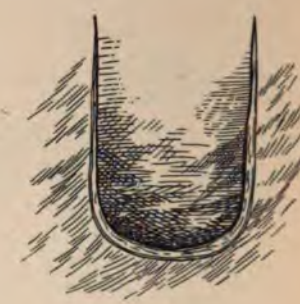

Gleason's tongue flap.

If it is not desirable to extend the incision through the mucous membrane on the concave side the saw should be directed upward parallel with the septal surface on the concave side just beneath the mucous membrane. This is not at all difficult, as the mucoperichondrium and periosteum usually separate very readily from the cartilage and bone. Or the membrane may be first elevated on the concave side by the injection of normal salt solution beneath the mucoperichondrium and periosteum, thus lifting it away from the cartilage and bone.

Fig. 39

a, sectional view of the septum after the Gleason operation.

(*c*) Having made the U-shaped incision, the tongue-flap should be forced from the convex side through to the concave side with the finger inserted into the nostril. The bevelled edges of the flap and those of the fixed portion of the septum engage so as to hold it in its new position on the concave side (Fig. 39). The tongue-flap has a tendency to spring back into its former position, owing to the elasticity of the cartilaginous and bony tissue contained in it, hence it is necessary to overcome its resiliency by forcing it as far to the concave side as possible, the flap being thus fractured at its upper extremity.

By the foregoing procedure the convex portion of the septum is displaced toward the side of the greatest nasal space, and the obstructed side is opened for freer drainage and ventilation.

Objections.—One objection to this operation is that it is sometimes followed by perforation of the septum. The same is true, however, of nearly all other operations which may be substituted for it.

Another and more serious objection to it is, that better results can often be obtained by the submucous resection of the septum. It is obvious that the obstructive portion of the septum can be but partially displaced by this operation, whereas, it can be completely removed by the submucous resection.

Dressings.—It may be necessary to insert a nasal tube (Fig. 45) on the side of convexity for a day or two to ensure the fixation of the tongue-flap in its new position. Otherwise, dressings are not needed.

5. **The Roe Operation.**—The Roe operation may be used in the same type of deviation described under the Watson, Sluder, and Gleason operations, and it may also be used to correct the bowing of the septum in the region of the middle turbinal, where there is also a ridge on the lower portion of the septum, though it is not applicable for the correction of an obstruction due to a heavy ridge. Roe has devised special forceps, with a male and a female blade (Fig. 40), for this operation.

FIG. 40

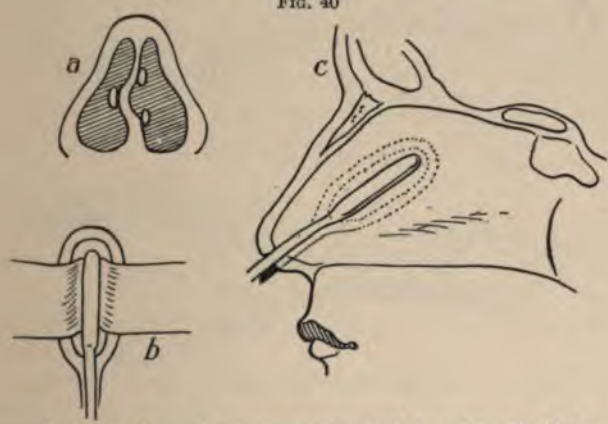

The Roe operation. *a*, schema showing correct method of applying the blades of Roe's comminuting forceps; *b*, schema showing the deviated septum forced to the concave side; *c*, schema showing the forceps applied to the septum, the male blade over the convexity and the female blade over the concavity.

Technique.—(*a*) Local anesthesia upon both sides of the septum, indeed of the whole nasal mucous membrane, is necessary; or the operation may be done under general anesthesia.

(*b*) The Roe forceps should be introduced, the male blade into the side of convexity and the female blade into the opposite side. By closing the forceps blades the convex portion of the septum is forced toward the opposite side through the opening of the female blade. The entire area of obstruction may be thus fractured and forced toward the concave side.

(*c*) The fractured portion of the septum should be held in its new position with nasal splints, or with strips of bismuth gauze, for two or more weeks, or until it becomes fixed in its new position.

6. **The Asch-Meyer Operation.**—This operation consists of a crucial incision through the cartilaginous portion of the septum, the four tri-

angular flaps thus created being pushed toward the side of concavity and held in their new position with a Meyer nasal tube (Fig. 45). The operation may be used in curved or cup-shaped deviations of the cartilaginous septum. In other words, the Gleason, Watson, Sluder, Roe, and Asch-Meyer operations are suitable for much the same type of deviated septa. I have often included the deviated portion of the perpendicular plate of the ethmoid in the field of operation with good results, and see no objection to it, though the operation as originally devised by Dr. Asch was limited to the cartilaginous portion of the septum.

Technique.—(*a*) The operation may be performed under local anesthesia, though it is generally preferable to do it under general anesthesia, as the shock and pain are otherwise considerable.

Fig. 41

Asch's curved scissors.

Fig. 42

Asch's straight scissors.

Fig. 43

Asch's septum forceps.

(*b*) After cleansing the nasal chambers and the face, the straight Asch scissors (button-hole) (Figs. 41, 42 and 43) should be introduced into the nostrils, the narrower blade into the side of convexity and the wider into the opposite from three-eighths to one-half of an inch above the floor of the nose, and the septum cut through. The Asch angular scissors are then introduced and the perpendicular incision made, bisecting the middle of the horizontal one. Four triangular flaps are thus made (Fig. 44).

(*c*) The septum should next be seized with forceps and fractured by rotating it from side to side. It has been my practice to include the

perpendicular plate of the ethmoidal bone in the grasp of the septum forceps, as it is nearly always deviated with the cartilaginous portion. I have also included the remnants of the ridge left after the sawing operation, thus fracturing it (the vomer) from its attachment to the maxilla.

(*d*) The index finger is then inserted into the nostril on the side of septal convexity and the four triangular flaps pushed as far as possible to the opposite side (Fig. 44), care being exercised to fracture the flaps at their uncut bases. If this is not done the resiliency of the cartilage gradually brings them back to their original position.

Fig. 44

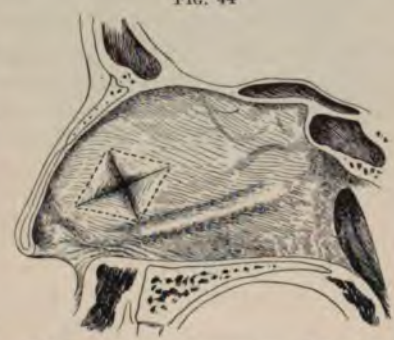

Schema of the Asch operation. The crucial incision is made through the deviated portion of the quadrilateral cartilage of the septum, thus forming four triangular flaps. The flaps are then pushed forcibly to the convex side of the septum and fractured at their bases, as shown by the dotted lines. This is done to overcome the resiliency of the cartilage.

(*e*) Severe hemorrhage usually occurs, but it may be quickly checked by the introduction of the Meyer nasal tubes. The tubes are primarily used, however, for the purpose of holding the incised and fractured septum toward the concave side (Fig. 45). The tube selected for the convex side should be large enough to force the septum beyond the point it is desired to fix it, as it will swing back a little toward its old position in spite of all precautions. A smaller tube should be introduced into the opposite nostril to exert counterpressure against the septum to check the hemorrhage.

After-treatment.—Both tubes should be left in position for two or three days and then removed. A tube one size smaller should then be introduced into the side of convexity but none into the opposite side. The tubes should be worn for about six weeks, being removed and

Fig. 45

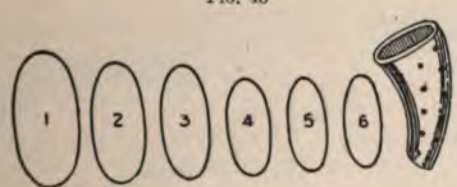

Meyer's nasal tube splints.

cleansed every alternate day during this period. Experience has shown that the septum gradually swings back to its former position if the tube is not worn for about this length of time.

Objections.—(*a*) Perforation of the septum sometimes follows the operation. (*b*) The shock attending the operation is often pronounced. (*c*) The inflammatory reaction is sometimes severe. (*d*) The presence

of the tube in the nose for six weeks is a source of considerable annoyance. (*e*) The hemorrhage is occasionally severe and difficult to control.

In spite of these objections, the operation has served, and will doubtless continue to serve, a useful purpose, though the submucous resection of the septum bids fair to take its place in most cases.

7. **The Kyle Operation.**—The Kyle operation may be used in simple and compound curvatures of the thin portion of the septum. It consists in making V-shaped grooves in the septum along the lines of greatest convexity, the object being to remove tissue where it is redundant, so that the septum may be made straight without overlapping along the lines of incision.

FIG. 46



Fetterolf's file saw.

FIG. 47

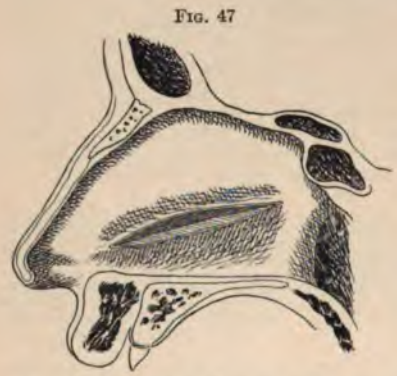

FIG. 48

FIG. 47.—Side view of septum after groove is made.

FIG. 48.—*a*, sectional view of the septum after the V-shaped incision; *b*, Kyle's malleable tube holding the septum in position. (Kyle's operation.)

FIG. 49

Kyle's malleable tubes.

Technique.—(*a*) Local anesthesia of both sides of the septum should be induced.

(*b*) A linear incision with a small bistoury should be made along the lines of convexity.

(*c*) The Fetterolf V-shaped file saw (Fig. 46) should be used along the lines of incision until the thickness of the cartilage and bone are penetrated (Fig. 47).

(*d*) The incised septum should then be forced into the median line by the introduction of Kyle's malleable tubes into either nasal chamber (Figs. 48 and 49).

(*e*) The after-treatment consists in removing and re-introducing the tubes until all tendency of the tissues to return to their former position is overcome.

The Price-Brown Operation.—This method of operating consists of making two perpendicular incisions and uniting them by an intersecting horizontal incision as shown in Fig. 50. The two rectangular flaps thus formed are pushed through to the side of concavity and held in position

FIG. 50

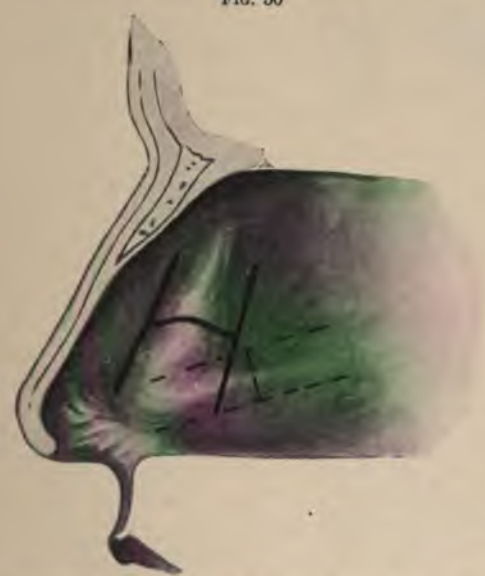

The Price-Brown operation. Two parallel incisions are made, one on either side of the long axis of the deviation. An intersecting incision is then made across the long axis of the deviation. All incisions are made with bevelled edges, so that when the two quadrilateral flaps are pushed to the concave side they will engage in the opening as in the Watson and the Gleason operations. If this operation is applied to a horizontal deviation (dotted lines), the two parallel incisions would be parallel with the ridge. If bony tissue is involved, the incisions should be made with a chisel.

for a few days or weeks with a nasal splint or dressing upon the side of the convexity. The operation is extremely simple, and is especially applicable to cup-shaped deviations of the cartilaginous portion of the septum. This operation is also applicable to simple perpendicular or horizontal angular deviations of the cartilaginous septum, the intersecting incision being made across the crest of the angular deviation, as shown in Fig. 50.

Moure's Operation.—Moure's method of straightening the septum is especially applicable to those cases in which there is a concavity on one side of the septum and a marked thickening or ridge of bone upon the

opposite side (Fig. 52). This type of deviation is also well suited for the submucous operation.

Technique.—(*a*) Cocaine anesthesia.

(*b*) Remove the ridge with a spokeshave or saw as indicated by 2 in Fig. 52. The removal of this ridge of bone materially relieves the pressure upon the middle (5) and inferior turbinated bodies (4). The septum may still crowd too much to the convex side, hence Moure advises the following procedure to force the remaining portion of the septum (3) to the opposite side:

FIG. 51

The removal of the bony ridge of the septum, the preliminary step in Moure's operation for the correction of deviations of the septum.

(*c*) Having removed the ridge, two incisions are made as shown in Fig. 53. One is made below the ridge, and the other above and in front of it, parallel with the ridge of the nose (Fig. 54). The incisions are made with specially devised scissors resembling those of Asch.

(*d*) A malleable metal splint is then inserted on the side of convexity and spread with forceps until the septum is sufficiently forced to the opposite side, as shown in Fig. 55. The two incisions permit the septum to be forced to the opposite side, where it should be held with the malleable splint until it becomes fixed in its new position.

After-treatment.—The splint should be removed in three or four days, cleansed, and re-inserted and moulded to the parts. This procedure should be repeated every two or three days for from two to five weeks, or until firm union has taken place. Should exuberant granulations form they should be reduced with fused chromic acid crystals. The open skeleton tube used by Moure permits of free respiration and of nasal irrigation while it is in place.

THE SUBMUCOUS RESECTION OF THE SEPTUM.

1. Apply a 1 to 2000 solution of adrenalin to the entire surface of both sides of the septum on thin pledgets of cotton, which should be left in position for from eight to ten minutes.

2. Local anesthesia: A small cotton-wound probe, slightly moistened in water, is dipped into pulverized cocaine and applied about one-half minute, by massage, to each side of the septum (Freer). Applications should be made every seven minutes. From three to five applications induce complete local anesthesia. Occasionally a 20 per cent. solution of cocaine applied over the septum with thin pledgets of cotton acts better than the above method.

3. Blanching and local anesthesia being induced, the incision of the

Fig. 52

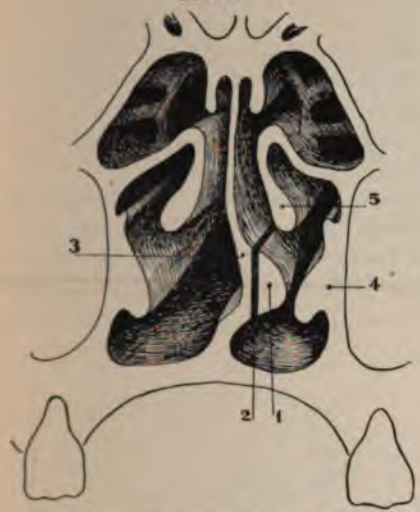

Fig. 53

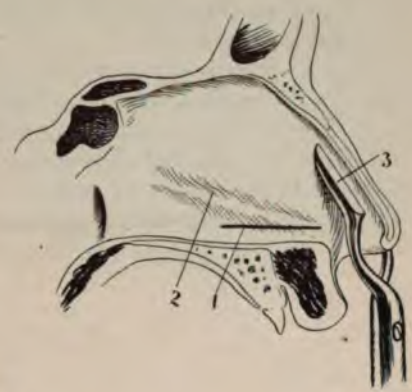

Fig. 52.—Cross-section of the nose, illustrating certain details of Moure's septum operation. 1, the ridge severed with the spokeshave; 2, the incision with the spokeshave; 3, the septum; 4, the inferior turbinate crowded upon by the ridge of the septum; 5, the middle turbinate also crowded upon by the deviated septum.

Fig. 53.—The incisions of the septum in Moure's operation. 1, the incision along the floor of the nose below the septal ridge; 2, the thickened septal ridge; 3, the upper incision through the septum being made with Moure's scissors.

Fig. 54

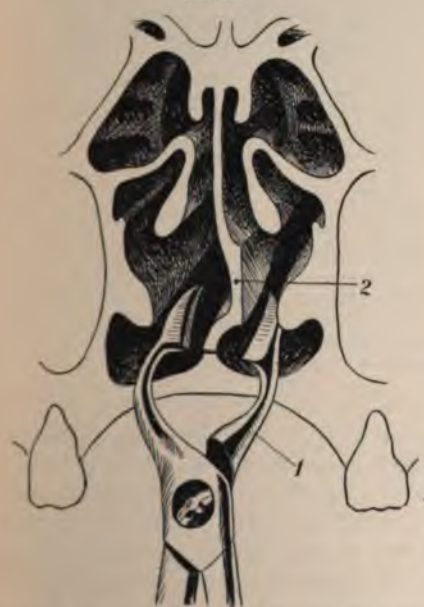

Fig. 55

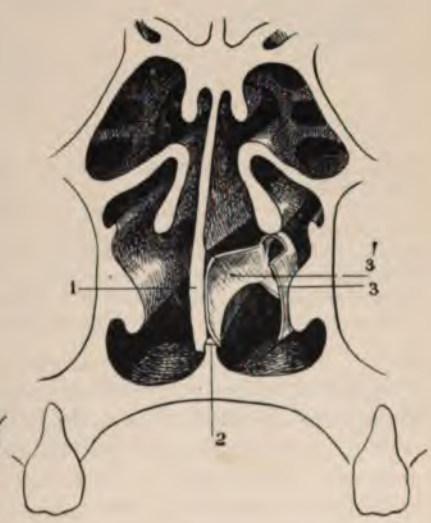

Fig. 54.—Making the incisions through the septum with Moure's scissors. 1, Moure's scissors; 2, the septum.

Fig. 55.—Moure's malleable splint in operation. 1, the septum displaced to the right side of the nose; 2, the incision made with Moure's septum scissors; 3, the outer wall of the nasal splint resting against the inferior turbinated body; 3', the inner wall of Moure's nasal splint crowding the septum to the right side of the nose.

mucoperichondrium upon one side only, by Hajek's or Killian's method, is performed (Fig. 56), though in exceptional cases, Freer's incision is preferable (Fig. 57).

4. The mucoperichondrium (and periosteum) is next elevated upon the side of the incision (Figs. 58 and 59).

5. The incision is next carried through the cartilage, but not through the opposite mucoperichondrium (Fig. 60). To carry the incision through both membranes results in a permanent perforation, unless one side is closed by suture.

Fig. 56

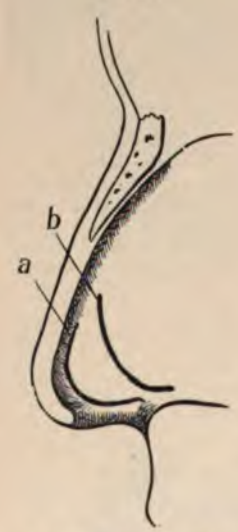

Fig. 57

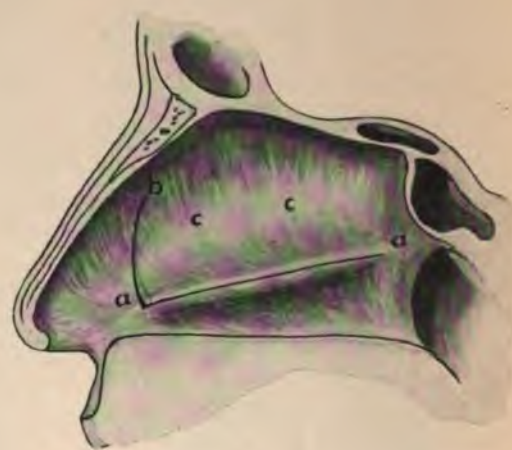

Fig. 56.—Incisions for the submucous resection of the septum. *a*, the Hajek incision; *b*, the Killian incision.

Fig. 57.—Freer's L-shaped incision; *a a*, anteroposterior incision along the crest of the ridge; *a b*, perpendicular incision at the anterior end of the horizontal incision. The mucoperiosteum should be elevated over the triangular area (*a a b*) and the curved deviation (*c c*) of the cartilage and perpendicular plate of the ethmoid removed, after which the ridge (*a a*) is removed. This incision should be used when the operator is reasonably certain that he cannot avoid mutilating the mucous membrane in operating through the Hajek or Killian incision.

6. Elevate the mucoperichondrium on the opposite side by introducing the elevators through the incision in the cartilage (Fig. 61).

7. Remove such portion of the cartilaginous septum as may be necessary with the author's swivel knife (Figs. 62 and 63).

8. Remove the deflected portion of the perpendicular plate of the ethmoid bone with the Foster-Ballenger biting forceps (Figs. 64 and 65).

For the removal of the deformed vomer, or ridge, the author uses a septum forceps for fracturing it from its attachment to the superior maxillæ (Fig. 66), though the gouge or Hurd forceps may be used (Fig. 67).

Thus far Hajek's elevators seem to be best suited for the separation of the mucoperichondrium from the cartilage, though smaller and sharper elevators are occasionally necessary.

Additional reasons for adopting a simple armamentarium, requiring few introductions for instruments, are the lessened shock and the shorter time required for the performance of the operation. These are all-important matters from the patient's point of view. The patient has a right to expect the best results, with the least shock, in the least period of time, and with the greatest safety to his septum. The author believes the method herewith illustrated possesses these qualities.

Fig. 58

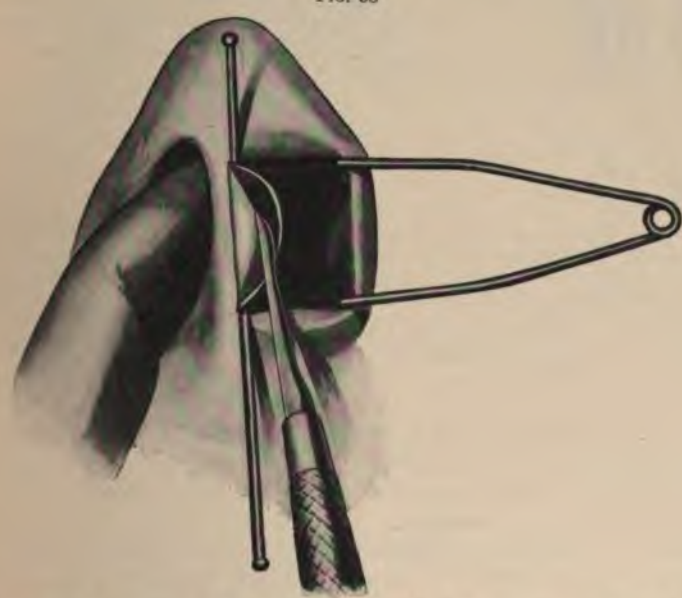

The elevation of the mucoperichondrium upon the side of the primary incision in the mucous membrane. The elevation is begun with a sharp or semisharp elevator and is completed with the blunt elevator.

The successful elevation of the mucoperichondrium depends upon several factors, namely: (*a*) The location of the incision, (*b*) the degree of adhesion of the perichondrium to the cartilage, (*c*) the care with which the incision is made, (*d*) the instruments used in the elevation, (*e*) the personal equation.

The location of the incision, whether in the vestibular skin or posteriorly in the mucous membrane (Fig. 56) largely determines the ease with which the membrane is elevated. If made in the skin of the vestibular portion of the septum, as practised by Hajek, the elevation is difficult on account of the close adherence of the membrane to the underlying fibrocartilage, unless a certain technique is followed. When the incision is thus made, injections of Schleich's solution should be made beneath the

mucoperichondrium before making the incision. This separates or partially separates the perichondrium from the fibrocartilage and renders the remaining steps of the elevation comparatively easy. Indeed, if this technique is followed the membrane is more quickly elevated than by any other method in any location.

If Killian's incision is made in the mucous membrane just posterior to the vestibular skin, considerable difficulty is sometimes encountered in starting the elevation, many minutes often being consumed in this step. The difficulty is not so much on account of the close adhesion of the perichondrium to the cartilage, as the faulty technique employed. The mucous membrane is rather loosely adherent to the perichondrium and the operator failing to engage the elevator beneath the perichondrium proceeds to separate the mucous membrane from the perichondrium. The elevation proceeds slowly and the operator wrongly infers that the mucoperichondrium is bound down by an inflammatory exudate. The so-called adhesions are exceptional rather than the rule. When the elevation proceeds with difficulty the membrane should be pushed away, the wound dried with a cotton-wound applicator, and the denuded surface examined. If it presents a velvety pink surface, the perichondrium is still attached to the cartilage. If it presents a smooth, white, glistening surface, the elevator is beneath the perichondrium and the elevation may be safely continued. An experience in about 300 submucous resections has taught me that the perichondrium is less tightly adherent in certain areas than others. This knowledge has led me to seek the path of least resistance, namely, along the ridge of the nose. In other words, the elevation should be begun at the upper end of the incision and continued beneath the ridge of the nose for the distance of an inch or more before attempting to elevate the lower portion. Having thus successfully begun the elevation do not make the mistake of using the tip of the elevator to complete it. The tip of the elevator is only of use in starting the elevation. After this is accomplished the long edge of the instrument should be used to complete it. It is obvious that the tip is more liable to perforate the mucoperichondrium than is the long, dull edge of the elevator. The perichondrium and periosteum may be readily stripped from the underlying framework of the septum, while they are dissected from it with difficulty and hazard. This is a fact that should be understood, for if it is not understood, operators will tear the membrane in endeavoring to elevate it with the tip of the instrument.

Fig. 59

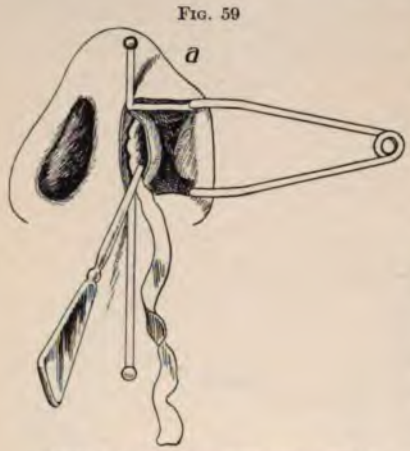

Elevation of the mucoperichondrium by Beck's method.

FIG. 60

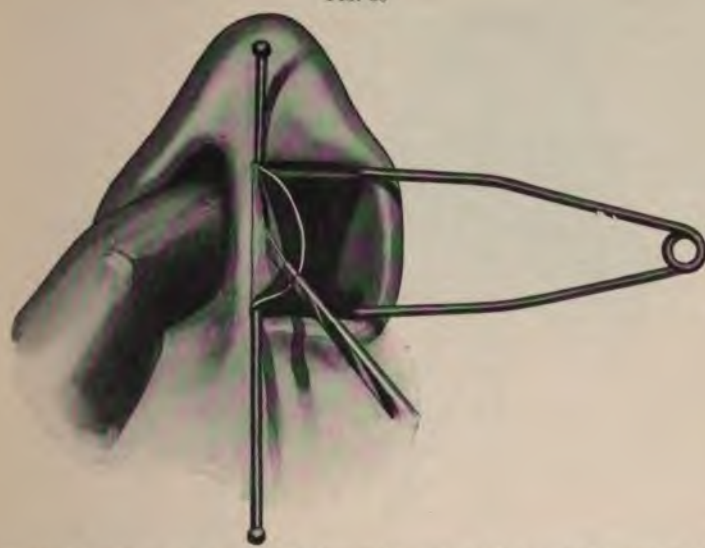

The mucoperichondrium being elevated, the cartilage is incised, care being exercised to avoid perforating the mucoperichondrium upon the opposite side of the septum. The finger is introduced into the opposite nasal chamber to detect the point of the knife the moment it penetrates the substance of the septal cartilage. The incision should be slowly and delicately performed. Should the mucous membrane upon the opposite side of the septum be incised, it will be necessary to suture it to prevent permanent perforation of the septum.

FIG. 61

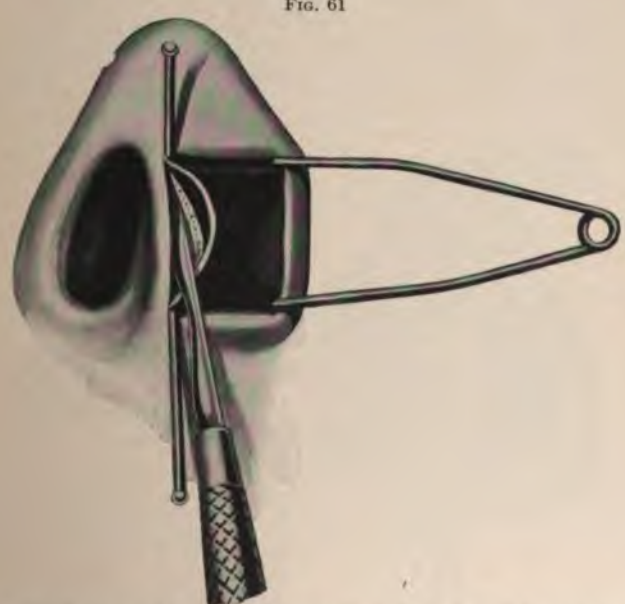

The cartilage being incised, the mucoperichondrium of the opposite side of the septum is being elevated. The elevation is begun with a sharp or semisharp elevator and is completed with a blunt elevator.

Fig. 62

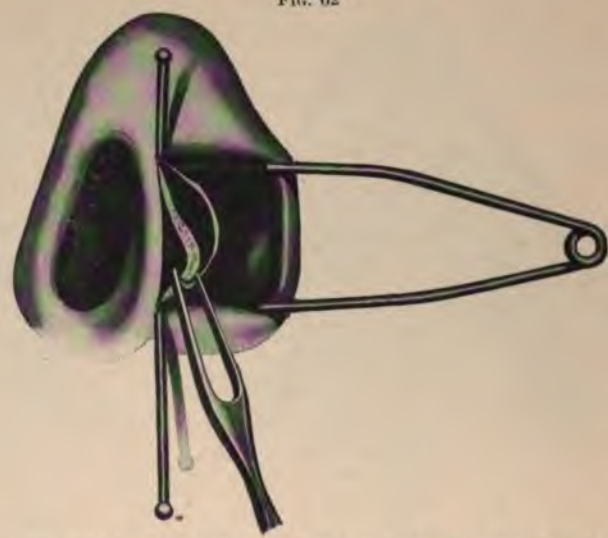

The mucoperichondria being elevated on both sides of the septum over the area of the obstructive deviation, the cartilage is removed with the swivel knife. The tines or prongs of the knife are placed astride the cartilage and between the mucoperichondria (a Foster septum speculum (Fig. 78) being used to separate the mucoperichondria if desired). The swivel knife may be engaged at either the inferior or the superior aspect of the cartilage, according to the preference of the operator. The anterior portion of the cartilage is sometimes fibrous, and the incision should then be started with a knife or scissors. If the swivel knife is engaged in the inferior portion of the cartilage, as shown in this illustration, it should be pushed along the crests of the spina nasalis and vomer to the junction of the perpendicular plate of the ethmoid and the vomer. The knife should then be drawn forward and upward along the antero-inferior border of the perpendicular plate of the ethmoid, and thence downward and forward to the superior end of the incision in the cartilage. The cartilage of the septum is thus completely encircled and ready to be removed. The advantages of this method of removing the cartilage are the simplicity of the procedure, the short time consumed, and the preservation of the specimen for inspection.

Fig. 63

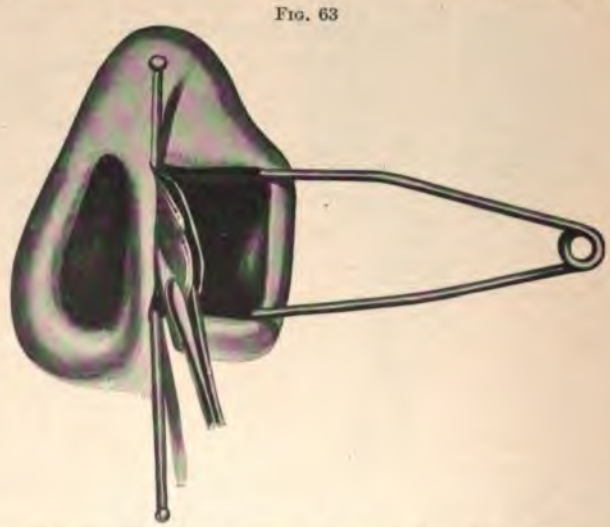

The cartilage having been excised submucously with the swivel knife, is removed from the mucoperichondrial pouch with dressing forceps.

Another point in the technique of the elevation of the mucoperichondrium is how to elevate beyond a perpendicular angular deviation.

Fig. 64

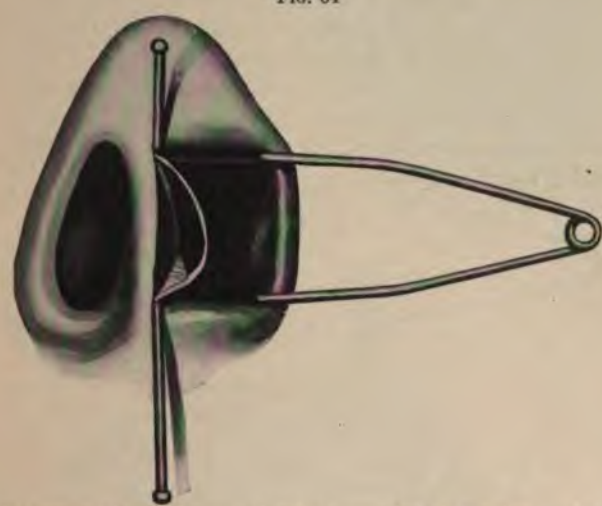

Showing the mucoperichondrial pouch after the removal of the cartilage. The bony crest of the vomer is shown in the bottom of the pouch, while deep in the pouch is shown the perpendicular plate of the ethmoid extending upward from the crest of the vomer. This should be removed with the Ballenger-Foster forceps, as shown in Fig. 65.

Fig. 65

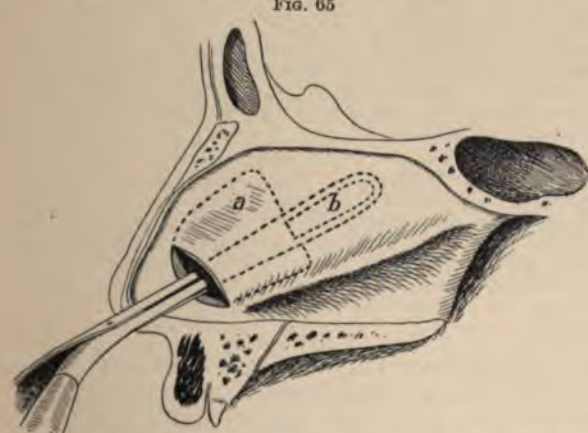

The removal of the perpendicular plate of the ethmoid bone with the Foster-Ballenger forceps. *a*, the area of cartilage previously removed with the swivel knife; *b*, the area of bone removed with a single bite of the forceps. Two or three bites remove nearly all of the perpendicular plate without removing the forceps from between the mucoperiostia. This is a matter of some importance, as each introduction of an instrument endangers the integrity of the mucous membrane.

Curved elevators have been devised for this purpose, and they may be used if the operator desires. My practice has been to spring the devi-

ated cartilage to the concave side, thus rendering it straight, and then to proceed with a blunt, heavy elevator. I have also taken advantage of the resilience of the tip of the nose, bending it to one side until the elevator was parallel with the surface of the cartilage posterior to the crest of the deviation. By taking advantage of the flexibility of the cartilage and even of the same quality in the perpendicular plate of the ethmoid I have been able to elevate the mucoperichondrium with ease when it appeared to be a difficult procedure.

Schleich's solution may be injected prior to making the Killian incision, thus facilitating the elevation.

Fig. 66

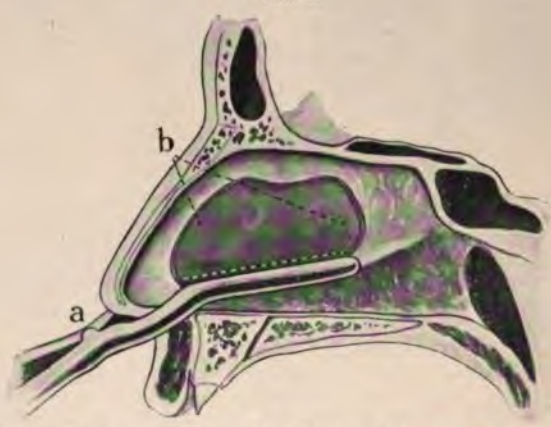

The author's method of removing the ridge of bone in the submucous resection of the septum. *a*, the septum forceps grasping the ridge, the blades being external to the mucous membranes. The forceps is rotated on its longitudinal axis as in the Asch operation, thus fracturing the vomer from its lower attachment. During the fracturing process the mucoperiosteum below the ridge becomes detached from the bone. *b*, the area of cartilage and perpendicular plate of the ethmoid previously removed. The mucous membrane is shown removed, though this is not actually done in the operation. Having fractured the ridge (vomer) from its attachment at the floor of the nose dressing forceps are introduced into the mucoperichondrial pouch, *i. e.*, between the elevated membranes, the bony ridge seized and removed through the anterior Killian or Hajek incision. A little gentle manipulation may be necessary to completely detach the bone. This method is only adapted to adults in whom ossification is complete. As the cartilage and bone between the vomer and cranial plate is removed the fracture of the vomer does not transmit shock to the brain.

Only when these facts are fully comprehended and observed will the submucous operation be performed with ease and success.

The author's swivel knife is made in two parts—the handle and the prongs, and the swivel blade. It is only used to remove the cartilaginous portion of the septum, which it does in one piece. The illustrations show the two widths of the swivel knife (Fig. 69). The wider one is for extreme deviations of the septal cartilage, and for the removal of part or all of the inferior turbinated body. The swivel knife is swung on pivots between the prong tips, between which it freely swings in a complete circle. The direction of the cutting edge (concave edge) is controlled by the resistance of the cartilage through which it passes.

In the submucous operation the cartilage is removed *en masse*, one minute rarely being required for this purpose. The operation is thus shortened, the number of instrumentations considerably diminished, and the speci-

FIG. 67

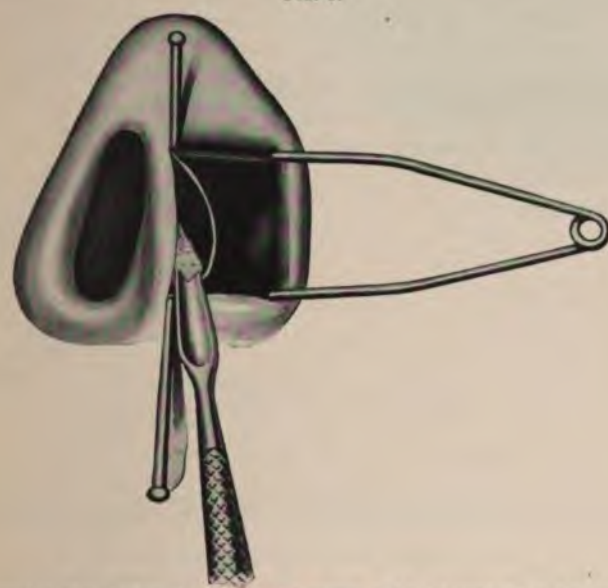

The removal of the thickened crest of the vomer with the author's V-shaped gouge. The gouge should be tapped with a mallet, and when well engaged, prying movements will splinter the bone. The whole of the thickened or deviated crest may be thus removed in one or more pieces. If the mucoperiosteum is adherent to the vomer beneath the deviated crest, it will separate as the bone splinters from its attachment to the intermaxillary bone. Should some portions of the deviated bone remain after the use of the gouge, they may be removed with bone forceps (Fig. 75).

FIG. 68

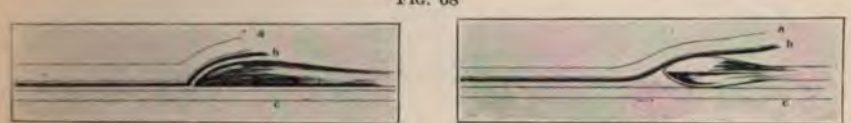

This shows the principle underlying the use of the semisharp and dull elevators in the subcutaneous resection of the septum. The first figure shows the semisharp elevator with its edge against the mucoperichondrium (*a b*). It is obvious that a false move would cut through the perichondrium and cause a perforation. The chief use of the sharp and semisharp elevator should be limited to starting the elevation at the original point of incision and at points where there is inflammatory adhesion. The second figure shows the dull elevator lifting the mucoperichondrium ahead of its tip or dull edge. As the mucoperichondrium and mucoperiosteum of the septum ordinarily strip readily, they may be elevated rapidly and safely with the blunt elevator.

FIG. 69



The author's swivel cartilage knife.

men is preserved for inspection. The swivel knife renders the submucous resection of the nasal septum, especially the cartilaginous portion, simple and attractive. The use of the instrument is so easily mastered that a novice should feel at home with it after the first trial. It is under the absolute control of the operator.

Fig. 70

Foster-Ballenger perpendicular plate bone forceps.

Fig. 71

Hajek-Ballenger mucoperichondria elevators.

Fig. 72

The author's mucosa knife.

Fig. 73

Hajek's septum gouge.

Fig. 74



F.A.HARDY & CO. CHICAGO

The author's septum gouge.

Some writers have stated that the swivel knife is objectionable because it is liable to tear the mucous membrane. Such a statement can mean but one of two things, namely, (*a*) that the operator is extremely awkward, or (*b*) that he failed to sufficiently elevate the membrane.

Any operator with but a moderate experience with the subcutaneous resection of the septum knows that it is next to impossible to tear the mucous membrane with the swivel knife if the mucoperichondrium is previously elevated over the entire operative field.

One writer makes the claim that the swivel knife is not an exact instrument—is not under the exact control of the operator. This is a mistaken idea and is not based upon personal experience, but is a theoretical deduction. As a matter of fact it is one of the most exact and

Fig. 75

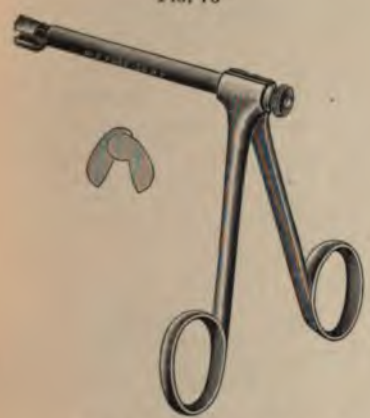

Hurd's bone septum forceps.

Fig. 76

Allen's nasal speculum.

Fig. 77

Beck's operative nasal speculum.

Fig. 78

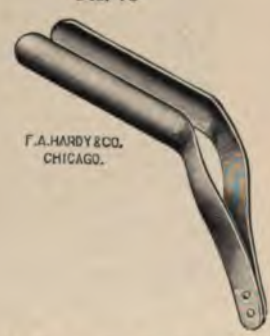

Ballenger-Foster septum speculum.

easily controlled instruments used in this operation. It cuts cartilage with but slight resistance, and may be directed with the greatest precision so as to encircle the amount of cartilage it is necessary to remove.

It is stated in the fourth edition of Kyle's *Text-book on the Diseases of the Nose and Throat* that the swivel knife was first suggested by Dr. N. H. Pierce and introduced by Dr. W. L. Ballenger. This is erroneous (without intention to misstate), as neither Dr. Pierce nor anyone else suggested the idea of the swivel knife to me. The idea occurred to

me when I first saw Killian's septum knife or spokeshave, which has a fixed blade between the prongs of the instrument. The thought occurred to me then that if the blade were pivoted at its edge to allow it to swing between the tines or prongs of the instrument, it could be made to encircle the cartilage and remove it *en masse*. I immediately had the instrument made by Mr. Kratzmüller, of F. A. Hardy & Co., and it has since then been kindly received by rhinologists in every country where rhinology is practised.

Fig. 79

Simpson's nasal sponge splint.

Author's differ as to the re-formation of the cartilage of the septum after its removal. According to J. C. Beck (Figs. 80 and 81), no cartilage cells were found in the tissues after a lapse of two and one-half years. The removed cartilage was replaced by dense fibrous tissue. Freer, on the other hand, claims that the cartilage re-forms, especially in the younger subjects.

Fig. 80

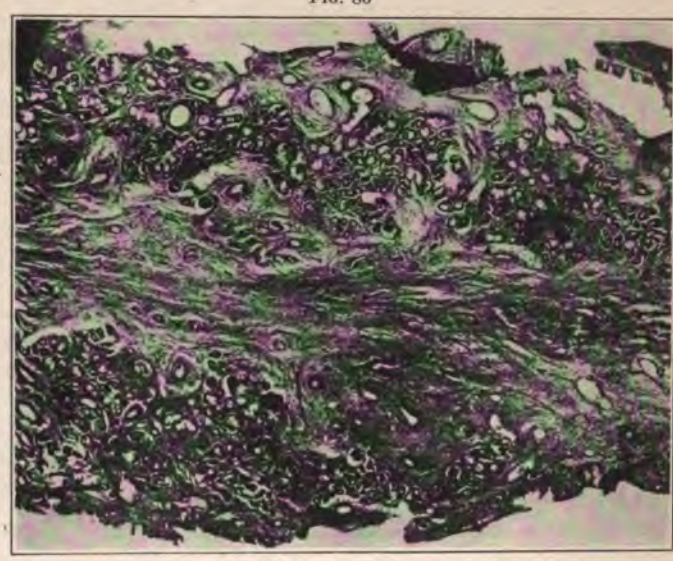

Section of septum two and one-half years after a submucous resection of bone and cartilage shows no regeneration of either bone or cartilage, but is replaced by a dense fibrous tissue. Age forty-seven years. (Specimen kindly loaned by Dr. J. C. Beck.)

After-treatment.—After all of the obstructive cartilaginous and bony frame of the septum has been removed, a Simpson sponge tent (Fig. 79) should be introduced into each nasal chamber to force the mucous membranes together. A few drops of sterile water should be instilled into the ends of the tents to cause them to swell and compress the septum. Gauze impregnated with subnitrate of bismuth powder may be used instead of the tents, or a thin rubber finger-stall may be placed in each

nasal chamber and packed with gauze (Casselberry). The Simpson sponge-tents should be removed in from twenty-four to forty-eight hours after the operation. They may be removed layer by layer and a thin lamina left over the line of incision for a day longer. If the mucous membrane along the line of incision is not torn, healing should take place by first intention. If the mucoperichondrium is torn or otherwise destroyed at any point, healing will occur by granulation and will require from five to fourteen days, according to the area of mucous membrane destroyed. Th's constitutes the chief objection to the extensive Freer incision. The flap is large and retracts and leaves a large surface to heal by granulation.

Fig. 81



Same as Fig. 80, only higher power.

General Remarks.—The Asch, Watson, and Gleason spokeshave, the sawing operation of Bosworth, and the submucous resection of the septum may be followed by perforation of the septum. The Asch and Gleason spokeshave, the Moure and the submucous resection operations are more liable to this accident than the sawing operation, the Sluder, Roe, and Watson operations. The submucous resection of the septum, if carefully carried out, is no more liable to perforate than either of the other operations. I am partial to this operation, because by it any type of deviation of any portion of the septum may be removed, whereas, the other methods of operating are only applicable to certain types of deviations. In view of the difficulties encountered in the performance of the submucous resection of the septum, the average operator should carefully consider the simpler methods of correcting the obstructive deviation before resorting to the submucous resection operation. The submucous resection of the septum is a major operation, and should be reserved for

those cases which cannot be corrected by the simpler operations. Unfortunately, a majority of the cases requiring the removal of septal deviations cannot be adequately corrected by any operation other than the submucous resection. It is often better to correct the deviation in the region of the middle turbinated body, even at the risk of leaving a permanent perforation of the septum, than it is to do a simpler operation which but partially overcomes the obstructive lesion. If further experience demonstrates the wisdom of removing the middle turbinal and the ethmoidal cells rather than the high deviations of the septum, the indications for the submucous resection of the septum will be greatly modified.

In view of the difficult technique and of the possible complications attending the submucous resection of the upper portion of the septum, I am still endeavoring to find a method of procedure attended by less technical difficulties and fewer complications and sequels. Notwithstanding this fact, I am of the opinion that, as we now understand nasal and sinus diseases, the submucous resection of the septum should be the operation of choice in a majority of the cases of obstructive deviations of the septum.

PERFORATION OF THE SEPTUM.

Etiology.—The causes of perforation of the septum may be divided into (*a*) congenital, (*b*) chronic granuloma, (*c*) traumatic, (*d*) acute infection, and (*e*) atrophic or perforating ulcer.

(*a*) Congenital perforation is extremely rare, Zuckerkandl having reported a few cases.

(*b*) Chronic granulomata, as syphilis, tubercle, and lupus, are responsible for a considerable percentage of the cases, some authors attributing as high as 50 to 60 per cent. to syphilis alone. In my experience the percentage due to syphilis is much less than this; syphilis is not, however, as common in this as in some other countries. Syphilitic perforations almost always include the bony portion of the septum, whereas, tubercle and lupus are limited to the cartilaginous portion. The tuberculous and lupous origin of the perforating ulcer may be determined by finding the tubercle bacilli, or tuberculous histological changes in the tissues. A slow but a reliable method of demonstrating the tuberculous process is to inject a guinea pig with some of the tissue from the ulcer. Six weeks later hold a postmortem on the pig and note the presence or absence of a tuberculous process.

(*c*) Traumatic perforations may include any portion of the septum, as they are usually due to surgical procedures, though they may be due to accidental violence and to picking the nose with the finger nail.

(*d*) Acute infectious diseases, as diphtheria, scarlet fever, typhoid fever, phlegmonous abscess, etc., may result in perforations.

(*e*) Atrophic or perforating ulcer of the septum is probably the most common type of perforation. Several conditions contribute to the etiology of this type of perforating ulcer. An anterior spur or deviation

of the cartilaginous portion of the septum is usually present, and on account of its projection into the field of the inspiratory current of air, it is subjected to constant mechanical irritation and to the desiccation of the secretions which constantly accumulate upon it. The ciliated columnar epithelium undergoes retrograde changes to a less specialized type of epithelium (pavement epithelium). The dust and other foreign substances in the air also irritate the epithelium and mucous membrane.

Fig. 82

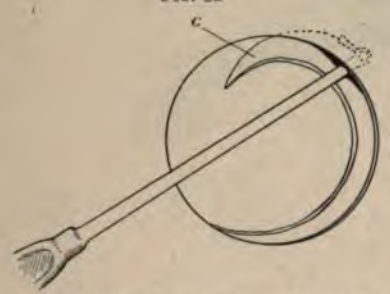

The cartilage (c) being removed with the author's single-tined swivel knife in Goldstein's plastic septum operation.

The crusts thus formed in this area become adherent, and are forcibly blown or picked off with the finger nail, the epithelium coming away with them. Hemorrhagic deposits in the mucous membrane occur, and epistaxis is of frequent occurrence. The retrograde process continues until the entire thickness of the septum is destroyed. Infection plays a part in the foregoing process.

Symptoms.—The symptoms of perforation of the septum vary with the size, cause, and location of the perforation. A small anterior perforation sometimes gives rise to a musical whistling sound, whereas a

Fig. 83

The author's mucosa swivel knife.

large one does not. If the perforation is associated with a prominent bony spur, there may be a sense of stuffiness in the nose. Crusts, if of large size, may cause the feeling of a foreign body in the nose, and, if forcibly blown or picked off, may give rise to nasal hemorrhage. Repeated epistaxis should arouse suspicion of a perforating ulcer. Syphilitic ulceration is usually accompanied by an offensive necrotic odor. Many cases will progress to complete perforation without the patient's knowledge of the fact.

Treatment.—If seen in the ulcerative stage, before perforation, the progress of the local retrograde changes may be checked by appropriate

FIG. 84

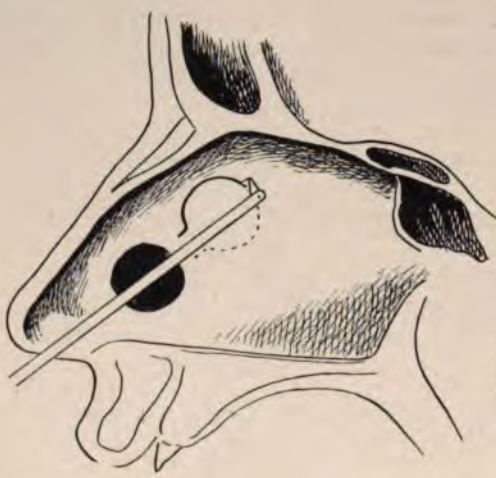

FIG. 85

FIG. 84.—Showing the method of outlining the flap with the author's swivel mucosa knife for the closure of a perforation of the septum.

FIG. 85.—*f*, the plastic flap sutured in the perforation; *c*, the pedicle of the plastic flap; *b*, the denuded area from which the plastic flap is removed heals by granulation; *d*, the edge of the plastic flap between the mucoperichondria of the septum.

FIG. 86

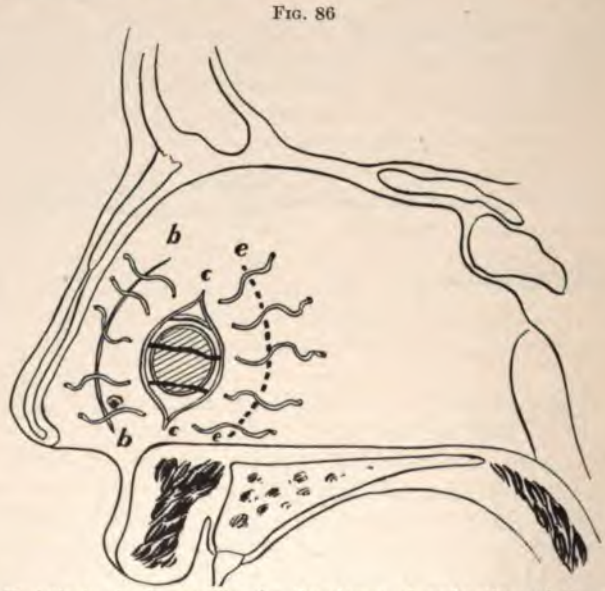

Schema of Hazletine's plastic operation for the closure of perforations of the septum. *a b*, incision in front of the perforation; *e e*, the incision posterior to the perforation on the opposite side of the septum; *c c*, the freshened edges of the perforation.

local cleansing and antiseptic washes and ointments, or, if due to syphilis, by the administration of the proper remedies for this disease. When the perforation is complete, little can be done except in a surgical way. Large perforations are not, however, amenable to surgical closure. Small ones may often be closed by proper plastic surgical procedures.

Goldstein's Plastic Flap Operation.—Dr. M. A. Goldstein has suggested and successfully used a plastic flap of mucous membrane turned into the opening and inserted and sutured between the elevated membranes of the two sides of the septum.

Fig. 87 Fig. 88

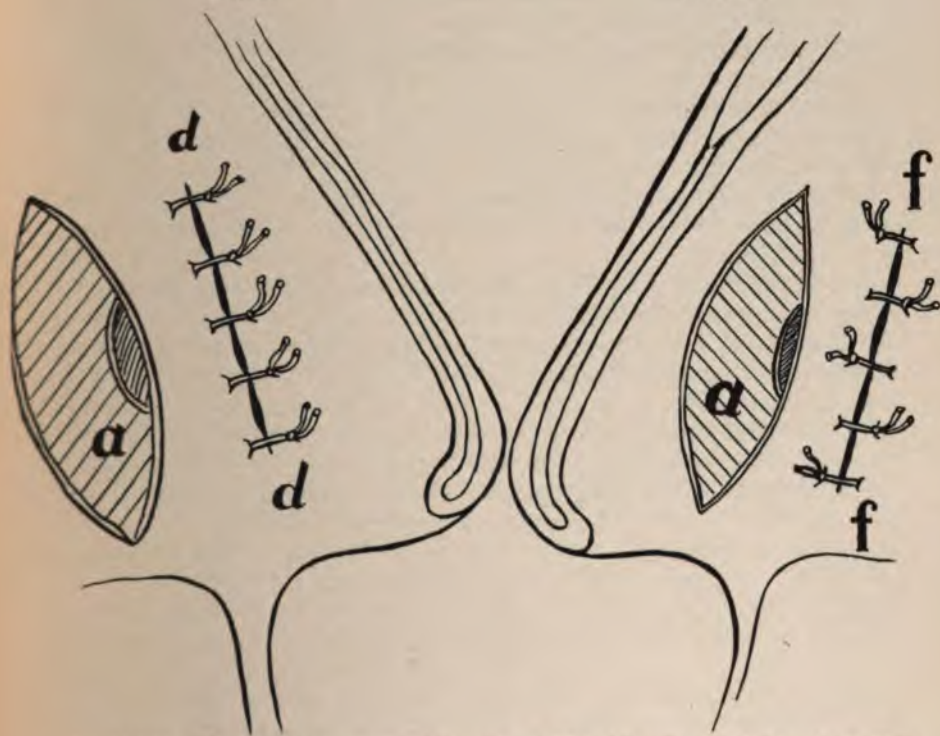

Detail of Fig. 86, showing the opposite side of the septum.

Detail of Fig. 86. *a*, the denuded cartilage after the plastic flap is sutured (*f f*).

Technique.—(*a*) Cocaine anesthesia.

(*b*) The rim or edge of the perforation is freshened by paring off the epithelium and mucous membrane.

(*c*) The mucoperichondrium is then elevated for a distance of one-half inch around the edge of the perforation.

(*d*) A ring of cartilage is then resected for one-eighth to one-fourth inch from the edge of the perforation, the author's single-tined swivel knife being used for the purpose (Fig. 82).

(*e*) A mucous membrane flap, the area of which is considerably larger than the perforation, is then dissected from the most convenient surface

of the septum and turned into the perforation and tucked between the elevated membranes around the perforation. I have devised a trailing swivel knife (Fig. 83) for outlining this flap. The method of using it is is shown in Fig. 84.

(*f*) When the pedicled flap is in position (Fig. 85) three or four stitches hold it in position. One surface is covered by epithelium, while the other is left to heal by granulation from the edges of the closed perforation.

Hazletine's Plastic Operation.—This operation is also only suited to small perforations. It is simpler than the pedicled flap operation, and appears to be a more satisfactory procedure.

Technique.—(*a*) Cocaine anesthesia.

(*b*) Freshen the edges of the perforation and elevate the mucoperichondrium, as in the submucous resection operation.

(*c*) Make a long curved incision (Fig. 86 *b b*) through the mucoperichondrium one-fourth to one-half inch anterior to the perforation, as shown in Fig. 86.

(*d*) Make a long curved incision (*e e*) through the mucoperichondrium of the opposite side of the septum, one-fourth to one-half inch posterior to the perforation.

(*e*) Suture the anterior flap to the freshened posterior edge of the mucous membrane of the perforation (Fig. 88), and the posterior flap on the opposite side of the septum to the freshened anterior edge of the membrane of the perforation, as shown in Fig. 87. The areas *a* and *a* heal by granulation.

(*f*) Remove the sutures in twenty-four to thirty-six hours. By this procedure the perforation is covered by two mucous membranes, and, the lines of suture not being apposite, closure of the perforation follows.

CHAPTER VI.

THE ETIOLOGY OF INFLAMMATORY DISEASES OF THE NOSE AND ACCESSORY SINUSES.

INFLAMMATION.

BEFORE discussing the causes of inflammation, it will be well to define inflammation.

Acute Inflammation.—Acute inflammation is a threefold reaction excited by the presence of certain noxa, or irritant material, in the tissues. The noxa or irritant is usually a pathogenic microörganism and its toxin, or it may be of chemical or traumatic origin. When of chemical or traumatic origin the irritant primarily consists of the dead or broken-down cells of the tissues.

Dead or broken-down cells, when present in the tissues in excess, become foreign bodies, and, as such, a reaction of the living cells is excited for the purpose of eliminating them from the body. Furthermore, the dead cells in the process of disintegration give off a ferment or chemical substance which also excites a reaction, the purpose of which is to free the tissues of its presence. The reaction thus far excited is directly traceable to the presence of dead and disintegrating tissue cells. Ordinarily, after a short time, a secondary irritant gains entrance to the injured tissues and becomes the more important factor in the reactionary process. That is, pathogenic bacteria infect the impaired tissues so that in nearly every acute inflammatory process, whether it is due to primary infection or to chemical or mechanical trauma, pathogenic microörganisms must be regarded as the paramount exciting or noxious agent causing the reaction of inflammation.

The reaction of inflammation is, therefore, an increased physiological activity of the living tissues of the body for the purpose of disposing of a noxious or irritant substance or organism that has invaded them in excess of the normal quantities.

The reaction of acute inflammation is a threefold process, namely:

1. Increased hyperemia.
2. Increased nutrition (increased resistance).
3. Increased leukocytosis.

1. Increased hyperemia is a constant and important reaction, as through it the cells are provided with the extra nutrition they need under conditions of stress. The increased blood supply also stimulates and facilitates the increased migration of leukocytes, and it flushes the poisoned area and dilutes the noxious substance, and thus reduces the intensity of the irritation. The hyperemia is nearly always passive in

type. It has been demonstrated that passive hyperemia is more potent in overcoming bacterial irritation than active hyperemia, though active hyperemia, when well established, is also very efficient.

2. Increased nutrition of the tissues is promoted by the hyperemia for obvious reasons. They are under stress because of the presence of noxious substances, and need extra nutritional facilities. Their vital force, or resistance, is not equal to the emergency placed upon them, and upon their resistance depends the issue of the warfare. Their means of defence may be characterized as twofold, namely: (*a*) Their ability to envelop and digest microörganisms, and (*b*) their ability to produce and emit a biochemical substance or ferment, the purpose of which is to weaken or destroy their foe. This all requires increased nutrition (blood), which begets increased powers of resistance.

If the nutrition is not adequate for these purposes, the microörganisms and their toxin, or biochemical irritant, may cause destructive and what we are accustomed to call pathological changes in the tissues.

3. Increased leukocytosis is also an important reaction of inflammation. While the function and modes of activity of the leukocytes is not fully understood, it has been fairly well demonstrated that the polymorphonuclear leukocytes envelop and destroy bacteria, while the lymphocytes envelop and destroy broken-down cells. Other cells, as the fibroblasts, also participate in these functions under certain conditions. I have not time to enter into a discussion of all the processes included in the reaction of inflammation, and only desire briefly to suggest the more important and well-known processes in order to prepare our minds for a clearer understanding of the etiology of the inflammatory diseases of the nose and accessory sinuses.

Quality of Reaction.—Parenthetically, I wish to add one additional statement concerning the adequacy of the reaction of inflammation. According to Adami the reaction of inflammation may be of three types:

1. Adequate reaction.
2. Inadequate reaction.
3. Excessive reaction.

The reaction is usually inadequate. That is, the increased hyperemia, cell nutrition, and migration of leukocytes is insufficient to dispose of the pathogenic microörganisms before they have caused considerable damage to the tissues. It follows, therefore, that in the treatment of inflammatory diseases the reaction of inflammation should be promoted rather than diminished. By so aiding the defensive and offensive activities of the tissues, the bacteria, their toxins, and the broken-down tissue cells may be speedily removed and a cure effected.

Inflammation Affecting Mucous Surfaces.—Adami says: "The main distinguishing feature of the mucous surface is the presence there of a layer of mucous cells of a glandular type, capable, when stimulated, of forming and discharging relatively large amounts of mucin. The hyperemia, the exudation of serum, the migration of leukocytes, all these occur in the submucous layer just as in the subserous layers. The changes in the reaction are due solely to the interposition of this layer of mucous

cells. There is, in the first place, a more definite basement substance interposing a certain amount of resistance to surface exudation. The layer of mucous cells is more complicated, and although the fully developed cells may be discharged, they are apt to remain relatively undifferentiated 'mother cells' at the base; or otherwise the same intensity of irritation does not lead to as extensive a denudation. And, thirdly, by the combined action, it may be, of the irritant and of the hyperemia, the fully formed mucous cells are stimulated to produce increased amounts of mucin, so that an inflammation of moderate grade is characterized by an abundant amount of mucinous discharge rather than of fibrinous deposit.

"We speak of such a moderate case, with exudation of serum containing abundant mucin, cast-off mucous cells, and relatively few leukocytes, as a 'catarrhal inflammation;' if there be sufficient leukocytes extruded the character is altered to that of a 'mucopurulent inflammation;' if more severe, with complete destruction of the mucous membrane proper, then, as in serous surfaces, there is the same tendency for the leukocytic exudation to favor a deposit of fibrin upon the surface, and then we obtain a 'membranous inflammation.'

"Despite the fact familiar to all that diphtheria is a disease set up by a specific bacillus, and the equally well-known fact that a like membranous inflammation may be induced by several forms of microbes, we still commonly speak of such a membrane as being diphtheritic. It would be better to confine this term purely to cases in which we know that the Bacillus diphtheria is the causative factor; failing this, we may accept the term diphtheritic as covering all such membranous inflammation, and employ the term diphtherial for such cases as are of pure diphtherial origin.

"Further, if there be yet more severe destruction of the surface cells, this may go on to ulceration. Where we have pyogenic organisms present, there is a dissolution and breaking down of any fibrin that is formed and consequent absence of a membrane. In such cases there is a distinct tendency for the process to extend in the submucosa beneath the still intact mucous membrane, the part becoming infiltrated with pus. This form is spoken of as 'phlegmonous inflammation.'"

Chronic Inflammation.—The reaction of chronic inflammation consists of the following phenomena:

(*a*) Slightly increased hyperemia.
(*b*) Slightly increased cell nutrition.
(*c*) Slightly increased migration of leukocytes.

It is needless to add that the reaction is inadequate to remove the noxa or irritant, which, according to pathologists, is usually bacteria of low virulence.

A product of chronic inflammation that is always present is the proliferation of fixed cells, usually of the least differentiated type, namely, connective-tissue cells.

Having thus briefly defined inflammation, we are prepared to discuss its causes.

The causes of inflammatory diseases of the nose and accessory sinuses are divided into two groups, namely:

1. Exciting causes.
2. Predisposing causes.

1. **Exciting Causes.**—The exciting causes are bacteria and chemical and traumatic destruction of tissue cells. This phase of the subject has already been discussed under Inflammation, and will not be dwelt upon in this connection further than to say that pathogenic bacteria cannot irritate the tissues of the body so long as the resistance of the cells is normal; that is, so long as they are healthy. There may be an exception to this rule when the germs are exceptionally virulent, though this is rare. Virulent pathogenic bacteria are constantly present in the upper respiratory tract, though they are harmless until the resistance of the cells is lowered by some intracorporeal or extraneous influence.

2. **Predisposing Causes.**—There are many predisposing causes of inflammatory diseases of the nose, some of which are best explained by grouping them around a well-recognized physiopathological law, namely, *When the drainage and ventilation of a mucous membrane-lined cavity is impaired or blocked, the conditions are favorable for the growth of pathogenic bacteria.*

If this is true, each case of inflammatory disease of the nose and accessory sinuses should be examined to ascertain if the drainage and ventilation of these spaces are impaired or blocked. If they are, the obvious therapeutic duty is to remove the obstruction by such remedial measures as will best accomplish the purpose. These measures may be either medicinal, hygienic, or surgical.

If, on the contrary, no obstructive lesion is found, other causes for the lowered resistance of the tissue should be sought for. If the inflammation is a primary acute one, and the lowered resistance is due to shock from exposure, it may be useless to attempt to remove the cause, as it was transient. The immediate duty in such a case is to promote the reaction of inflammation and thus check the inflammatory process. As Adami so aptly says, the way to cure inflammation is to increase it.

In order to logically approach the consideration of the causes of the lowered resistance of the mucous membrane of the nose and accessory sinuses they should be divided into two groups, namely:

(*a*) Extranasal.
(*b*) Intranasal.

Extranasal Predisposing Causes.—*Age* seems to exert some influence upon the resistance of the nasal mucous membrane. Young children and young adults are more frequently subject to inflammatory diseases of the nose and accessory sinuses than those of more advanced years. This is, no doubt, due in part to indiscretion, as the improper care and protection of the body from the inclemencies of the weather. Persons of more mature years have more mature minds and better judgment, and they do not expose themselves needlessly, as in youth and childhood. Then, too, the tissues acquire a resistance, or immunity to the noxious irritations.

Sex, perhaps, exerts some influence on the occurrence of inflammatory processes. Males are more exposed and more reckless than females, hence they are more often affected by inflammatory diseases. They are more pugilistic and more often have broken noses and consequent nasal obstruction than females.

Climate undoubtedly influences the occurrence of inflammatory processes. In regions where there is much cold, wet weather with sudden changes of temperature and of hygroscopic conditions of the atmosphere, it is more difficult to protect the body, particularly the feet, from the shock incident to such exposures. The shock thus sustained by the vasomotor nervous system leads to a lowered resistance of the mucous membranes, especially of the nose and accessory sinuses, hence the growth of bacteria in these regions is favored.

Exposure, especially unusual or unequal exposure of the body to damp, cold, or other atmospheric and metallurgic conditions, weakens the resistance of the tissues. The exposure of the feet to damp and cold is a most fruitful source of rhinitis and inflammations elsewhere in the body. Draughts striking a single portion of the body are detrimental to the resistance of the tissues much more than when the whole body is thus exposed. Within certain limitations the exposure of the whole body often has a tonic effect, as all the animal mechanisms of the body are equally and simultaneously stimulated. When partial exposure is experienced, only a portion of the mechanism is stimulated, and an unbalance of the functional activities results; that is, there is confusion and havoc in the cellular activities, the nasal expression of which is often some form of inflammation.

The *clothing* is an important factor in maintaining or lowering the resistance of the mucous membrane of the upper respiratory tract. Too much is as productive of evil as too little clothing. If too much is worn, the skin is rendered sensitive to slight exposures, and if too little is worn, the body is subjected to continual stress, and exhaustion of the vital forces results. Either condition prepares the soil for the growth of pathogenic bacteria in the respiratory passages. Perhaps the most vulnerable part of the body is the feet, through the soles of which course large bloodvessels. Anyway, cold, wet feet is a common cause of acute rhinitis and sinuitis.

The proper selection of underwear is a much mooted question. Wool is advocated by some, while linen or linen mesh is strenuously recommended by others. In the meantime, most persons buy cotton for summer and cotton and wool mixtures for winter wear; not because they believe they are the best, but because they are cheaper. My ideas on the subject are as follows:

Linen absorbs moisture better than either cotton or wool, and is, therefore, better for summer wear. Wool is warmer than either cotton or cotton and wool, and is better for winter wear. Some persons perspire easily in winter, and for them linen should be worn next to the skin. If this does not retain enough body heat, light wool should be worn over the linen underwear. Cotton or cotton and wool mixtures are perhaps

never preferable to wool and linen, and wool combinations for the winter months.

The outer garments should be medium weight for the winter months, the overgarments being depended upon for extra protection for outdoor wear. If the indoor clothing is too heavy, the skin becomes tender and subjects the wearer to shock upon undue exposure when out of doors. The underclothing and outer garments should, therefore, be selected for their absorptive and heat retaining properties. Hard-and-fast rules cannot be laid down in reference to the clothing, each subject being a law unto himself. The aim should be to so regulate the clothing as to avoid either extreme, as to do otherwise subjects the system to shock, and thus lowers the cellular resistance and prepares the soil for the growth of microörganisms and inflammation.

The *digestive tract* is by some writers justly held responsible for inflammatory processes of the upper respiratory tract. If the processes of digestion and nutrition are imperfectly performed, noxious material enters the vascular lymphatic circulation and thus places extra stress upon all the fixed and migrating cells of the body. Lowered resistance, therefore, naturally follows.

Certain *constitutional diseases* likewise produce a lowered resistance of the tissues, including the mucous membrane of the nose and accessory sinuses. Diabetes, syphilis, and all diseases due to faulty metabolism especially affect the tissues of the respiratory tract, and predispose them to infection and inflammation.

Heredity probably has no direct influence in the predisposition to infectious and inflammatory diseases of the nose. Indirectly it may have such an influence. That is, certain anatomical conformations of the nasal chambers may be transmitted from parents to the child and thus lead to a predisposition to infection and inflammation.

Adenoids may interfere with the drainage and ventilation of the nose and accessory sinuses, or inflammation focalized in them may lower the resistance of the mucous membrane of the nasal and accessory sinuses, and thus predispose to infection and inflammation. These and other extranasal influences may prepare the soil for the growth of pathogenic bacteria in the nose and accessory sinuses and may eventuate in empyema of the sinuses without obstructive lesions in the nose. Whatever the cause of the lowered resistance of the mucous membrane the result is the same.

I do not wish to be understood as saying that infection and inflammation always follow a lowered resistance of the nasal mucous membrane. I only claim that a lowered resistance predisposes to such a process. The virulence of the microörganisms and other conditions enter in the equation.

Intranasal Predisposing Causes.—In this connection I wish to repeat the physiopathological law which largely explains the occurrence of infection and inflammation of the nose and accessory sinuses, namely: *Cavities lined with mucous membrane are predisposed to inflammation when their drainage and ventilation are obstructed.*

From experience, we know that when such obstructions are present

and are removed, either by local applications or by surgical interference, relief often promptly follows.

Let us direct our attention, therefore, to some of the obstructive lesions of the nose which predispose the mucous membrane to infection and inflammation.

Obstruction of the Lower Portion of the Nose.—I desire to first call attention to a fact that has long impressed me as very important, namely, that obstructions in the lower portion of the nasal cavity have a different clinical significance than obstructions located higher in the nasal passages. I also wish to call attention to the clinical significance of anterior obstructions as contrasted with obstructions otherwise located.

Obstruction of the Inferior Portion of the Nose.—Obstruction of the inferior portion of the nasal passages causes an approximation or an impingement of the inferior turbinal against the septum, at least at certain points. The pressure may be either intermittent or constant. The question of greatest importance is, How does such an obstruction affect the drainage and ventilation of the nose and sinuses? As most of the mucous membrane of the nose and sinuses is located above the inferior turbinal, it is obvious that ventilation is but little affected by such an obstruction. The pathway of the inspiratory current is largely limited to the middle and superior meatuses of the nose, and, inasmuch as an obstruction located inferiorly does not materially occlude the inspiratory tract, there is comparatively little disturbance of function. Furthermore, the drainage of the secretions is not materially blocked. The usual obstructive lesion in this region is a spur or ridge on the septum. The ridge is rarely equally prominent along its entire length. On the contrary, it presents one or two prominent spines or knuckles which approximate or impinge against the inferior turbinated body, thus leaving wide gaps through which the secretions may drain to the floor of the nose without marked impediment.

The practical deduction to be drawn from these facts is, that an obstruction in the lower portion of the nose does not markedly reduce the resistance of the mucous membrane, especially in the upper portion of the nasal chambers and in the accessory sinuses. It does, however, have some influence in this direction, and in a degree predisposes to infection and inflammation. The crests of the spines or knuckles may accumulate secretions, which become desiccated in the form of moist or dry crusts. The tissue cells beneath the crusts are injured and their resistance lowered, and to this extent there is a predisposition to infection and inflammation. Furthermore, the impingement of the spur or spine against the outer wall of the nose causes traumatic injury and results in some degree of lowered resistance, which may lead to bacterial infection and inflammation. The irritation is not usually pronounced and only causes an increased hyperemia and nutrition of the tissues.

Obstructive lesions in the lower portion of the nose, therefore, may cause a turgescence of the mucous membrane, which is richly supplied with erectile tissue (the swell bodies), which after a more or less pro-

longed period may result in hypertrophy. In the early or turgescent stage the condition is called turgescent rhinitis; in the later stage it is called hypertrophic rhinitis. If, however, repeated infection occurs, the irritation is of a different type and causes hyperplastic changes.

Unfortunately, however, a deviation of the lower portion of the septum is usually accompanied by a deviation of the upper portion of the nose in the region of the middle turbinal. When this is the case the type of inflammation is radically different from that present in an uncomplicated lower deviation. That is, a deviation in the region of the middle turbinal often obstructs the drainage and ventilation of the superior meatus and of all, or nearly all, of the nasal accessory sinuses. The secretions are retained, undergo decomposition, liberate a ferment, and irritate the mucous membrane. In brief, the inflammation is attended by the proliferation of the least differentiated of the fixed cells, or connective tissue cells. In other words hyperplasia of the mucous membrane occurs. This is known as hyperplastic rhinitis. The irritation from the middle turbinal region may extend by continuity of tissue to the inferior turbinal and cause hyperplasia of this structure as well. Hence, hyperplastic rhinitis often involves both turbinated bodies. In simple deviations, however, limited to the lower portion of the nasal chambers the inflammation is usually of the hypertrophic type.

Obstruction of the Anterior Portion of the Nose.—Deviation of the anterior portion of the septum from traumatism is the common cause of obstruction of the anterior portion of the nasal chamber. The relationship it bears to inflammatory processes of the nose and accessory sinuses is interesting and instructive. An anterior deviation does not interfere with the drainage of the secretions except in so far as it may affect the mechanical force of the respiratory currents of air. The mechanical force of the inspired air is especially manifested in the region of the infundibulum and posterior ethmoidal cells where the inspiratory current sweeps over the hiatus semilunaris and the ostei of the posterior ethmoidal cells and causes slight rarefaction of the air within the sinuses drained by these openings. The mechanical impact facilitates the flow of secretions from the ostei and hiatus semilunaris, and thus prevents desiccation and blockage of these openings. To this extent obstructive anterior deviations of the septum interfere with drainage.

The ventilation upon the obstructed side is, however, very materially affected. The slight interference with the flow of the secretions caused by the absence of the mechanical impact of air results in a moderate retention of secretions. Decomposition of the secretions may therefore take place and cause a lowered resistance of the mucous membrane, and thus establish a predisposition to infection and inflammation.

When the ridge or spur in the lower portion of the nose extends well forward into the vestibule, it also interferes with the ventilation and drainage, as described in the preceding paragraph.

When either type of anterior obstructive deviation is present, another and more important etiological factor must be taken into consideration, namely, the rarefaction of air posterior to the obstruction. Air being

unable to enter the nostrils rapidly enough during the descent of the diaphragm is rarefied, or a state of negative air pressure is established. This, according to Bier's theory, should prevent serious inflammatory processes, as the negative air pressure thus produced promotes the reaction of inflammation and should prevent serious inflammatory disease. Doubtless the negative pressure thus automatically produced does exert a favorable influence upon the inflammatory process excited by the lack of ventilation and the slight retention of the secretions. Thus, strange as it may seem, the anterior obstructive lesion predisposes to infection and inflammation, and at the same time tends to cure it.

Clinically, I have often noted the comparatively slight inflammatory disease of the nasal mucous membrane present in simple anterior deviations.

The chief departure from the normal is a turgescent or a hypertrophic rhinitis of the inferior turbinals. Little pathological change is present in the middle turbinal region unless there is an associated obstruction in that location. The negative air pressure easily accounts for the turgescence of the erectile tissue of the inferior turbinals. After a prolonged duration of the turgescence, whether intermittent, alternating, or constant, hypertrophy occurs as a result of the increased nutrition.

Obstruction in the Middle Turbinal Region.—Obstruction in this portion of the nasal chambers is productive of more serious inflammatory disease of the nose and accessory sinuses than obstruction in any other portion of the nose. The reason is obvious when we recall the fact that the ostei and sphenoidal sinuses drain into the superior meatus above the middle turbinal, while the frontal, anterior ethmoidal, and antral sinuses drain into the middle meatus beneath the middle turbinal.

If the septum is deviated so as to press against or approximate near to the middle turbinal, the olfactory fissure is blocked and the drainage of the posterior ethmoidal, and possibly of the sphenoidal cells, is interfered with.

Clinically I have noted the presence of two types of deviations of the septum that close, or nearly close, the olfactory fissure. One is a bowing of the perpendicular plate of the ethmoid bone and triangular cartilage, and the other is a thickening of the septum in the region of the middle turbinated body. The bowed septum is thin and easily corrected by the submucous resection of the septum, whereas the thickened septum often involves only the mucous membrane and is more difficult to correct.

In some subjects there are large pneumatic spaces in the middle turbinal which may either close a part or all of the olfactory fissure, or they may encroach upon the hiatus semilunaris beneath it. In the first instance the drainage and ventilation of the superior meatus of the nose, and in the second instance the drainage and ventilation of the frontal, anterior ethmoidal, and maxillary sinuses are impaired.

A large bulla ethmoidalis projecting medianward and downward may obstruct the hiatus semilunaris, and thus obstruct the drainage and ventilation of the cells draining into the infundibulum, namely, the frontal, anterior ethmoidal, and maxillary sinuses.

Likewise, the occasional pressure of cells in the inner wall of the infundibulum, or uncinate process of the ethmoidal bone, may block the infundibulum and cause serious inflammatory disease of the frontal and anterior ethmoidal cells and the maxillary antrum ("vicious circle").

In about 50 per cent. of the cases the frontonasal canal does not communicate with the infundibulum, but opens directly into the middle meatus more anteriorly. In these subjects an enlarged projecting bulla ethmoidalis and cells in the uncinate process would not block the drainage and ventilation of the cells draining through the frontonasal canal, namely, the frontal and anterior ethmoidal cells. The ostium of the antrum, however, may be obstructed as it always opens into the infundibulum.

The Results of High Obstructions in the Nose.—When the olfactory fissure is obstructed by either septal or turbinal deformity, the drainage of the secretions and the ventilation of the posterior ethmoidal and sphenoidal sinuses are impaired. The secretions are retained and undergo retrograde changes. The mucous membrane bathed in the secretions is injured and its functional activity and resistance are lowered. The biochemical substances liberated in the process of decomposition constantly irritate the mucous membrane, especially of the middle turbinated body. Acute infection occasionally occurs. During the intervals between the acute inflammatory processes a mild staphylococcal or other infectious inflammation persists. Under these conditions there is a proliferation of fixed cells in the tissues, usually the least differentiated of the fixed cells, viz., connective-tissue cells.

The result is known as hyperplastic rhinitis, which chiefly involves the middle turbinated body, though it often extends to the inferior turbinal as well.

Obstruction of the Olfactory Fissure.—The partial or complete closure of the olfactory fissure and the consequent retention of the secretions of the superior meatus, and the ethmoidal and sphenoidal sinuses draining into it, cause hyperplastic changes in the mucous membrane, not alone of the middle turbinal, but of the superior meatus and of the ethmoidal and sphenoidal sinuses opening into it. The conditions thus produced are favorable for infection and inflammation. The inflammatory process may be either catarrhal, purulent, fibrinous, or phlegmonous in type, and in each instance it is in part due to pathogenic microörganisms.

The sinuitis thus excited may continue for years without engaging the attention of either the patient or physician. Headache and slight dizziness, aggravated upon stooping, may be the only symptoms complained of, except, possibly, recurrent attacks of acute coryza. Or the sinuitis may be distinctly and frankly purulent, with copious discharge into the epipharynx, and possibly to some extent through the olfactory fissure into the middle meatus.

Atrophic rhinitis with ozena is, in my opinion, in adults often a suppurative sinuitis with atrophy of the mucous membrane. Space does not permit of a full discussion of this phase of the subject. Personally I have repeatedly overcome the ozenic secretion by treating the case as though it were a suppurative sinuitis. I have made skiagraphs of

several cases of atrophic rhinitis with ozena, and without exception they have shown the existence of sinus disease. This does not, of course, determine which was primary, the atrophic rhinitis or the sinuitis. My opinion is largely based upon the results following the treatment for the sinuitis.

Obstruction Due to the Bulla Ethmoidalis in the Middle Turbinal and Uncinate Cells.—As previously stated, a large bulla ethmoidalis may occlude the infundibulum and thus block the drainage and ventilation of the maxillary sinus, the frontal and anterior ethmoidal cells. This, as heretofore explained, causes the retention of the secretions and lowered resistance of the tissue, thus establishing a predisposition to infection and inflammation. (See "Vicious Circle" of the Nose.)

Cells in the middle turbinated body and uncinate process likewise may block the infundibulum and cause similar results. The exception has been referred to wherein the frontonasal canal opens directly into the middle meatus anterior to the infundibulum.

It appears, therefore, that there are several factors entering into the causation of inflammatory diseases of the nose and accessory sinuses. The exciting cause is nearly always pathogenic microörganisms, while the predisposing causes are numerous extranasal influences which are often combined with obstructive lesions in the nose. The latter should always be studied with reference to whether they interfere with the drainage and ventilation of the nose and accessory sinuses. If only extranasal causes of lowered resistance are found, the treatment should be addressed to their removal; and if in addition to the extranasal influences obstructive lesions are found, they should be corrected by probing or by surgical interference.

Conclusions.—1. Acute inflammation is usually a threefold reaction excited by pathogenic bacteria and their toxins, namely:

(*a*) Increased passive hyperemia.

(*b*) Increased nutrition of the tissues.

(*c*) Increased migration of leukocytes.

The reaction of acute inflammation is the response of Nature's forces for the purpose of destroying the bacteria and their toxins.

2. The reaction of inflammation is usually inadequate to quickly remove the infective bacteria and their toxins, hence the inflammation continues for several days, or it may be indefinitely prolonged.

3. Chronic inflammation consists of the same reactions in much less degree, and is still further characterized by the proliferation of fixed cells into the tissues, notably connective-tissue cells.

4. The exciting cause of inflammation is generally some pathogenic microörganism.

5. Pathogenic bacteria do not, *per se*, cause inflammation. There must be a lowered resistance of the tissues before they will rapidly multiply and produce inflammation.

6. Anything that lowers the vitality or resistance of the mucous membrane of the nose and accessory sinuses predisposes it to infection and inflammation.

7. The extranasal influences that lower the vitality of the mucous membrane are sex, climate, exposure, improper clothing, digestive disorders, constitutional diseases and dyscrasias, hereditary anatomical peculiarities of the framework of the nose, adenoids, etc.

8. The intranasal predisposing causes of inflammation of the mucous membrane of the nose and accessory sinuses are, perhaps, best explained by the well-recognized law: *Obstruction of the drainage and ventilation of mucous-lined cavities predisposes them to infection and inflammation.* The character of the inflammation and the end result are partially determined by the location of the obstruction in reference to the various tissues of the nose and to the accessory sinuses.

9. Anterior and inferior obstructions more often cause turgescent and hypertrophic rhinitis, as they do not materially interfere with the drainage of the secretions, and therefore cause very little or no irritation.

10. Obstruction higher in the nose, in the region of the middle turbinal and the infundibulum, causes the retention of the secretions and interferes with the ventilation of the superior meatus and the accessory sinuses, thus lowering the resistance of the tissues and establishing a marked predisposition to infection and inflammation of the nasal and accessory sinuses. The inflammation may be catarrhal or suppurative, and acute or chronic in type.

11. The long-continued mild irritation excited by obstructive lesions in the middle turbinal region often results in hyperplastic rhinitis, which may be limited to the middle turbinal, though it may extend to the inferior turbinal.

12. Inflammation also extends to adjacent parts by the continuity of tissue, hence it may extend from one part of the nasal mucous membrane to another, or it may extend from the nasal mucous membrane to the sinuses, the Eustachian tube and cavum tympani.

CHAPTER VII.

THE PRINCIPLES OF TREATMENT OF INFLAMMATIONS. THE MODALITIES FOR PROMOTING THE REACTIONS OF INFLAMMATION.

Acute Inflammation.—As Adami so aptly says, "Inflammation is a danger signal, but by no means necessarily a danger." Inflammation is a beneficent reaction, Nature's attempt to ward off or destroy an invading irritant. The inflammatory process thus started should be encouraged rather than discouraged, at least for a short time. The increased hyperemia and leukocytosis should be added to rather than detracted from. Cold applications are generally contraindicated, as they diminish the hyperemia and leukocytosis and lower the cell resistance.

Heat is indicated, as it increases the cellular resistance and leukocytosis, at least up to a certain point. Passive hyperemia by Bier's method of treatment is along the right line. The hot-air treatment and the leukodescent light also increase the hyperemia and leukocytosis, hence the irritant causing the inflammation is disposed of, the inflammation subsides, and normal conditions are restored.

Whatever the mode of treatment, its object should be to augment the hyperemia and leukocytosis. As Adami says, the inflammation is not the real danger, but is the signal of danger, and as such its warning should be heeded.

Physiological and physical rest for the inflamed part should be prescribed. If the middle ear is infected, quiet should be enjoined. If the eye, a darkened room. In addition to physiological rest, local hyperemia and leukocytosis should be augmented by the use of the leukodescent light, Bier's treatment, etc., to hasten the destruction of the infecting bacteria. If cold applications are used, the local hyperemia and leukocytosis are reduced, the cell resistance is lowered, and Nature's effort to throw off the irritant is thwarted. Remember that inflammation is not a destructive process, but is a benign process for the purpose of destroying the microörganisms and their toxins.

Promotion of the Reaction of Inflammation.—The grand purpose of treatment should be to promote the inflammatory reaction. Failing in this, or if, for various reasons to be discussed later, it is not deemed wise to wait the full establishment of the reaction of inflammation, operative interference may be called for. Adami classifies reactions of inflammation as follows:

(*a*) Adequate.
(*b*) Inadequate to neutralize the irritant and bring about repair.
(*c*) Excessive for these purposes.

(*a*) Adequate reaction is present in aseptic incised wounds, the natural healing of fractures, etc. Such conditions need no local treatment, as the reaction of the tissue cells is adequate to dispose of the irritant noxa; that is, the passive hyperemia and leukocytosis is sufficient to destroy the bacteria, toxins, and broken-down cells. At the end of about twenty-four hours the reaction has reached its maximum. The cell resistance and the nature of the lesion are favorable for the establishment of adequate reaction; hence, interference, other than to maintain these conditions, is contraindicated. Healthy blood and a normal nervous system are prime requisites for establishing adequate reaction. Physiological rest of the injured parts and the regulation of the excretory organs are the only indications for treatment in such cases.

If the infection is virulent, or the condition of the blood and the excretory organs are below normal, the beneficent reactions of inflammation will be inadequate to speedily remove the infectious irritant, at least before impairment of the tissues has occurred. Thus in mild but prolonged middle-ear inflammation the repair is usually so slow that, unaided by the aurist, the integrity of the conduction apparatus may be impaired and permanent deafness follow. In such a case there is inadequate reaction, hence the reaction of inflammation should be promoted.

(*b*) Inadequate reaction is usually present in most cases of acute inflammation. Formerly most surgeons regarded the reaction as excessive and attempted to reduce it. Such a course is inimical to the well-being of the patient. The reaction needs promotion rather than abatement. It should be remembered that the increased temperature, pulse, and respiration are not essential parts of the reaction; they are incidental concomitant phenomena. The reaction, that is, the aroused forces of Nature to combat the invading microörganisms, the passive hyperemia and the leukocytosis being inadequate to dispose of the noxa or irritant, should be promoted, not abated.

Many methods of increasing the hyperemia and leukocytic migration are in vogue. Among them are poultices, counterirritation, scarification, constriction by ligature, negative air pressure, massage, leukodescent light, heat, incisions, and irrigations with bland irritants, as normal salt solutions.

Some of the modes of treatment have been in use for many centuries, perhaps all of them in some modified form, at least in isolated instances. Dr. Brawley called my attention to the fact that certain American Indians cured acute coryza by constricting the neck of the patient with the hands, thus practising what Bier has reduced to scientific principles. Rhinologists have long resorted to irrigation of the accessory sinuses of the nose in the treatment of sinuitis. They have also used more irritating solutions. Irrigations with normal salt solution have been used with the idea of removing the products of inflammation, rather than increasing the hyperemia and the leukocytic migration. Perhaps an increased familiarity with the principles underlying the treatment of inflammation will materially modify the technique employed in the treatment of in-

flammatory diseases of the upper respiratory tract. Each case should be studied individually and the modality applied that best meets the peculiar conditions present.

In acute inflammation of the maxillary sinus the surgeon should decide whether he will resort to counterirritation, irrigation, the leucodescent light, negative air pressure, or some surgical procedure. The chief question is, What method of treatment will best promote hyperemia and the migration of leukocytes? The aim should not be to check the inflammatory process in the sinus, as that is established to rid the parts of the irritant noxa (pathogenic microörganisms) and to prevent its extension to contiguous structures. A counterirritant is not desirable, as it may temporarily, and possibly permanently, disfigure the face. Irrigation is usually impossible, except through an artificial puncture. The leukodescent light is easily applied, relieves pain, and increases the migration of leukocytes to the infected area. The expense of the apparatus practically limits its use to office and hospital practice. Its use is also limited to districts supplied with electric power. Where it is practicable to use it, it is a valuable mode of treatment. Bier's constriction treatment necessitates the application of an elastic band around the neck, and is more or less uncomfortable. It is, nevertheless, easily applied, and may be used by any physician understanding its application. Negative air pressure may be used in the nasal chambers by bulb suction, hence its application is not limited by expense or complex apparatus. Each treatment should extend over a period of several minutes, hence the bulb apparatus necessitates prolonged personal attention and muscular effort on the part of the patient or an attendant. Other and better negative air-pressure apparatuses require water, compressed air, or electric motor power, and are, therefore, practically limited to office and hospital practice. The mode of treatment is of considerable therapeutic value in acute sinus inflammation, and should be utilized much more than it is. Puncture through the inferior meatus increases the hyperemia and leukocytic migration, but it soon closes and necessitates a repetition of the procedure. It is a disagreeable procedure, and is sometimes complicated by a deeper infection of the tissues, marked soreness being present. It appears from the foregoing cursory review of some of the methods of procedure that the leukodescent light and the negative air pressure offer the most rational and effective modes of promoting adequate reaction in acute sinuitis. None are of universal application, for the reasons already given, hence, the surgeon may be compelled to resort to puncture, or puncture and irrigation combined, or to some other method of procedure.

This discussion is given not because it is intended as a guide in the treatment of sinus inflammation, but to show that various factors have to be considered in each case.

In acute otitis media the various modalities must be considered in connection with the peculiar anatomical and physiological conditions present. The location of the middle ear in a deep bony recess is an obstacle to the application of the leukodescent light. Heat is easily applied

by means of a hot-air apparatus or by hot irrigations through the external meatus. Counterirritation over the mastoid is but feebly effective. Cold is ordinarily contraindicated, as it diminishes the congestion and leukocytic migration. An exception in its favor is in inflammation of an encapsulated organ. The organ of hearing, being encased in bony tissue, is essentially an encapsulated organ, its capacity for expansion under congestion being limited. Only its outer wall, the membrana tympani, allows of expansion. Cold should be considered as a therapeutic measure under certain conditions. The congestive reaction following the ischemia produced by the cold may be beneficial. Another factor of great importance is the presence of the delicate chain of bones concerned in the transmission of sound waves to the labyrinth. If the inflammation, with its attending inflammatory products, continues for any considerable length of time, the inflammatory exudates become organized and the hearing is impaired. It is important, therefore, to institute some therapeutic measure that will quickly check the infectious process. Two alternatives suggest themselves, namely, incision of the drumhead and the local application of an irritant drug to the ear drum. A 12 per cent. solution of carbolic acid in glycerin has proved of decided value for this purpose (A. H. Andrews).

In acute laryngitis the following considerations are presented. Counterirritation is inadequate to sufficiently promote the inflammatory reaction. Scarification and incision are impracticable. The leukodescent light is probably not active enough, unless it is applied three or four times a day. The patient should be confined to the house, hence the light is practically out of the question unless a lamp is installed. The inhalation of hot medicated vapors promotes hyperemia and leukocytosis, but not sufficiently to be of great value except as an adjunct to other modes of treatment. The marked muscular activity of the soft parts of the larynx is a great impediment to the successful treatment of laryngitis. The prime object of treatment should, therefore, be to abolish the functional activity of the intrinsic muscles of the larynx. This can be done by prohibiting the use of the voice, requiring all conversation to be carried on with pencil and paper. Twenty-four hours of such functional rest often results in the triumph of the reactive inflammatory process over the invading bacteria and their toxins. Vibratory massage applied externally over the larynx increases the congestion, unloads the lymphatic vessels, and promotes leukocytic migration.

The foregoing illustrative cases suggest the method of thought to be applied in the selection of the modalities for the promotion of the reactions of inflammation in the treatment of acute inflammation, where inadequate reaction is the rule.

(*c*) Excessive reaction is rarely present. When present it is usually due to an excessively virulent microörganism, or to marasmus or other cause of lowered vitality. In such conditions a moderately virulent microörganism may cause excessive reaction. The tissues are intensely swollen, and a linear incision quickly promotes normal reaction by converting the passive into active congestion and unloading the engorged

lymphatics. With these changes normal or adequate reaction is established.

It is in these cases that the application of cold is indicated. Cold reduces the hyperemia, checks leukocytic migration, and diminishes the excessive cell proliferation.

General Systemic Treatment.—The objects of all systemic treatment for the promotion of normal reactive processes are (*a*) to increase the resistance of the cell structures, and (*b*) to eliminate the infecting microorganisms. To accomplish these ends the food should be highly nutritious but bland in character, while the elimination of the toxic products should be encouraged by the administration of saline cathartics. The skin, liver, and kidneys should also be rendered more active.

Excessive febrile reaction should be overcome by hydrotherapy or the administration of quinine, salicylates, etc.

Pain may be relieved by the administration of opiates or belladona, though the leukodescent light is a better remedy.

Treatment of Chronic Inflammation.—Adami says: "It is through no desire to be epigrammatic that one makes the statement that there is no treatment for chronic inflammation. The process consists, as we have seen, of hyperemia, slight exudation, slightly increased leukocytosis, and great tissue proliferation.

"The last-named process is probably not to be checked by any direct means we can employ; and any mechanical or chemical means we use is likely, *per se*, to increase rather than diminish it. But our mechanical means, directed toward an increase of the rapidity of income and output of the tissues, do more good in this way than harm in the other way. It may thus be said that our treatment of a case of chronic inflammation is not applied so much to the condition as in spite of it. If fibrosis has taken place, we cannot wholly undo it; but by increasing the vitality of the tissues we may check the continuance of the process and may render the absorption of the debris more rapid.

"Newly formed fibrous tissue may, however, in some cases undergo absorption. The remarkable diminution in size of syphilitic gummata under potassium iodide can mean nothing else; as, also, fibroid tubercles scattered over the peritoneum seen at one laparotomy have been found wholly absent at a subsequent laparotomy some months later. This fact affords the suggestion that a mild grade of acute inflammation superimposed upon a chronic favors absorption and explains the good effects of induced hyperemia in leading to the removal of adhesions and the restoration of movements in joints.

"If a low degree of microbic inflammation be still present there is an accompanying hyperemia, with slowing of the blood stream; the nutrition of the part, while appearing to be excessive, is often under par, and by the use of various agents we strive to increase its nutrition. Such modes of treatment are as follows: The use of cold for short times at intervals, bringing about an alternation of contraction and dilatation of the bloodvessels; the use of heat more or less continually; the use of electricity; rubbing, handling, and massage of the tissues, to the end that

the venous exodus from the part may be more rapid and more thorough; active and passive movement of the part, to accomplish the same result by pressure of contracting muscles; the use of counterirritation, rubefacients, vesicants, etc., which have this in common, that they probably increase the total amount of blood brought to the part. The use of the seton, now discontinued, had in view the same end.

"The result of all these modes of treatment is that the overturn of blood is rendered much greater, the venous return assisted, and the arterial blood permitted to enter more freely. The normal diapedesis of leukocytes tends to the removal of cellular debris, and the circulation in the part is approximated to the normal."

In the early stages of adhesive processes of the middle ear the application of the foregoing principles of treatment may accomplish much toward their removal. The internal administration of theosinonin has proved beneficial in such cases. Its use in old fibrosis of the middle ear is without appreciable effect. It is probable that any beneficial effects of pneumomassage is due more to the increased lymphatic flow, the increased nutrition, and to the absorption of the inflammatory products than to the increased mobility given to the ossicles.

In hyperplastic rhinitis the object of treatment should be to remove the cause of the irritation, usually a chronic sinus inflammation with its discharge. Operative interference is usually necessary. In addition to the removal of the primary source of irritation, a reactive acute inflammation is superimposed upon the chronic inflammation. This favors the absorption of the products of chronic inflammation.

MODALITIES FOR PROMOTING THE REACTION OF INFLAMMATION.

In the first part of this chapter I have shown that acute inflammation is a series of reactions excited by the presence of bacteria, their toxins, and the cellular debris. The object of the reactions is to rid the tissues of the bacteria, toxins, and cellular debris. Experience has shown that in acute inflammation the reaction is not sufficient to do this as quickly as should be to prevent damage to the tissues. That is, necrosis, cellular deposits, and adhesive processes are liable to occur before the reaction frees the cellular structures of the irritants. It is rational therapy, therefore, to promote the inflammatory reaction rather than to repress it. As a concrete example, I will cite acute coryza, or "cold in the head." This is a reaction due to certain bacteria and their toxins. It is understood, of course, that certain predisposing causes have prepared the soil for the growth of the bacteria. Ordinarily, the reaction (increased hyperemia and leukocytosis) is inadequate to quickly throw off the bacteria and the toxin. The question naturally arises, how to promote or increase the reaction? Do not make the common mistake of assuming that the inflammatory reaction is already excessive. It may be, but it is usually inadequate. Those who assume the reaction to be excessive

often apply adrenalin locally to reduce the reaction. This reduces the hyperemia, cell nutrition, and leukocytosis, whereas, they should be increased. It does establish better drainage.

The same law applies to nearly all acute inflammations of the upper respiratory tract, including the ear. It is the purpose of this section to discuss the various procedures whereby the reaction of inflammation is promoted or increased, and to outline the indications and the methods for their therapeutic application.

Counterirritation.—Counterirritation has long been used to counteract inflammatory processes, the prevalent idea being that it diverted the blood to the surface and away from the seat of inflammation. We know now that while its use was rational, the explanation of its good effects was irrational. Counterirritation applied over the inflamed area not only increases the superficial hyperemia, but it increases it in the deeper tissues as well. It also increases the leukocytosis and cell nutrition. Thus, instead of counteracting the inflammation, it promotes the inflammatory reaction.

Counterirritation has but little place in otolaryngological practice, for two reasons: (1) Because the blistering and scarring which occasionally result from it are objectionable for cosmetic reasons, and should surgical interference become necessary the skin is in bad condition; (2) because there are other modalities that are more efficacious.

Poulticing.—This is also an old method of treating inflammation. The moist pabulum of bread and milk, or other ingredients, is usually applied hot, the whole being covered with cloths or oiled silk to retain the heat and moisture. While poulticing promotes inflammatory reaction, it has fallen into disuse, because better modalities have taken its place. It obviously has little place about the head.

Scarification and Wet Cupping; Artificial Leeching.—Scarifiers were once in every family physician's outfit, whereas they are now rarely seen. Scarification was usually combined with cupping, and was designated "wet cupping." With a comb-like knife or with a series of concealed blades liberated by pressing a spring, the superficial layers of the skin were many times incised, and a cup in which a few drops of alcohol or a piece of paper was burned was quickly applied over the incised surface, and the negative air pressure created by the heat in the cup caused free oozing of blood. The idea prevailed that this diminished the excessive inflammatory reaction, whereas, as a matter of fact, it increased it. That is, it increased the hyperemia and leukocytosis, established adequate reaction, and hastened the elimination of the bacteria, toxins, and cellular detritus.

Wet cupping was formerly much practised in acute mastoiditis, and doubtless with beneficial results. I have often used it for this purpose, and recommend it as a valuable mode of treatment in the early stages.

Leeching.—This is a venerable therapeutic measure of great value in promoting inflammatory reaction. I have seen children with bronchopneumonia quickly pass from a state of stupefaction, with a pulse of 200 per minute, to one of complete consciousness, with quiet respirations

and a pulse of 100 per minute after the application of a few leeches to the chest. Likewise, I have seen the pain and tenderness in acute mastoiditis subside under leeching. With the improved technique of mastoid surgery, and with the accumulated observations of aural surgeons to the effect that, while many of the cases of acute mastoiditis subsided, but few were cured, leeching and kindred measures have been gradually abandoned. The keynote to the present-day mastoid therapy is the total eradication of the diseased process at the earliest possible moment by surgical intervention. Doubtless the pendulum has swung too far to the surgical side. An increased knowledge of the pathology of inflammation and of the processes of repair will enable the surgeon to differentiate more closely between the operative and non-operative cases.

From three to six leeches may be applied over the mastoid process and in front of the tragus in the very early stages of acute mastoiditis with decidedly beneficial effect. This is good treatment while watching the development of a case, and in some cases promotes the inflammatory reaction (increased hyperemia and leukocytosis) to such a degree as to lead to a speedy recovery. It is doubtful if leeching is efficacious after the disease has continued several days. Even then, however, it will affect the inflammatory process favorably, though not enough to effect a cure. The case must then be treated surgically (removal of adenoids in children, and possibly the exenteration of the ethmoidal sinuses in adults, or a mastoid operation) or allowed to assume a latent or chronic form.

Irrigation or Lavage.—This mode of treatment has long been applied to inflamed mucous-lined cavities of the nose and accessory sinuses of the nose. The prevalent idea as to its mode of action is that the solution used mechanically removes the inflammatory secretions, and thus lessens the noxa or local irritant, all of which is doubtless true. It also increases the local hyperemia and migration of leukocytes, *i. e.*, promotes the inflammatory reaction. Its action, however, is usually slight and transient, and inadequate for the purpose. The inflammatory process passes into the chronic type with tissue deposit, thus causing permanent changes detrimental to the physiological integrity of the structures. There are circumstances, however, under which lavage must be used in the treatment of sinuitis. If, for any reason, operation is refused or is not advisable, lavage may be practised through the ostia or through artificial openings into the sinuses. In acute cases the reaction thus established quickly overcomes the noxa, and healing speedily results. In chronic cases the reaction thus promoted is inadequate, and, indeed, in the nature of things, is not calculated to arrest the noxious process. Chronic inflammation consists of hyperemia, slight exudation, slight migration of leukocytes, and great tissue proliferation. The last-named process is probably not to be checked by any direct means we can employ.

From the foregoing it is plainly good treatment to employ such solutions by irrigation as will increase the hyperemia, the migration of leukocytes, and the nutrition of the chronically inflamed mucous membrane.

To these ends normal salt, boric acid, mild iodine, and other solutions may be employed. Even normal salt solution promotes the reaction of inflammation. It is to be expected, therefore, that while lavage will not remove the tissue proliferation, it will promote the inflammatory reaction, increase the nutrition, and remove the infective noxa still remaining. It also removes the irritating toxic secretions and thus relieves the tissues of another source of vicious irritation.

Massage.—Under this term are included three modalities of treatment, namely: (*a*) Manual massage, (*b*) mechanical massage, and (*c*) alternate rarefaction and condensation of air in a cavity, the so-called pneumomassage as devised by Delstanche and as modified in the various mechanically driven machines so commonly used in America.

The effect of massage upon inflamed tissue is to increase the hyperemia and nutrition, and the diapedesis of leukocytes. The inflammatory reaction is thereby promoted and the tissues measurably relieved of the irritant noxa.

(*a*) Massage of the larynx in acute laryngitis and for the relief of singers' nodules has been used with decided benefit. It may be applied by hand manipulations or by a vibratory massage machine. The motion and physical force thus applied to the exterior of the larynx increases the hyperemia and leukocytosis of the parts, and thus aids in the removal of bacterial infection and improves the nutrition of the cells, thereby fostering resistance to mechanical irritation from faulty use of the vocal apparatus.

(*b*) Mechanical or vibratory massage is of special value in acute adenitis of the cervical glands, its application quickly reducing the swelling and tenderness. It is not good treatment, however, to limit the attention to this mode of procedure, for to do so is to ignore the primary source of the glandular disease, namely, the tonsils, adenoids, and pharyngeal glands. The massage is only an adjunct to the treatment.

(*c*) Pneumomassage by means of hand or mechanically driven devices has been used extensively and almost empirically for the relief of deafness and tinnitus, with but little result. The same procedure applied in cases of acute otitis media would be of vastly more use to patients. That it has been used for this purpose I am unprepared to say. It stands to reason, however, that the movements thus imparted to the membrana tympani and the ossicular chain would increase the hyperemia, the cell nutrition, and the migration of the leukocytes in the inflamed mucous membrane, and thus hasten the reparative process.

Leukodescent Light.—During the past few years radiant energy in the form of light from a 500 candle-power incandescent globe has been used in the treatment of inflammatory processes. The beneficial effects are, perhaps, best explained by saying that it promotes inflammatory reaction (by hyperemia, cell nutrition, and diapedesis of leukocytes) and thus hastens the removal of the bacteria and other noxious material causing the irritation. I have been using the light for about three years, and have found it one of the most useful, if not the most useful, mechanical agency for promoting reaction in inflammatory diseases of the upper

respiratory tract. Acute coryza sometimes succumbs under its influence. I have repeatedly seen chronic suppurative sinuitis become painless and cease to discharge purulent secretions into the nose. I have never cured such a case with it, the purulent discharge returning in a few days or weeks after ceasing its use. Whether its prolonged use would have effected a cure I am not prepared to state. The light relieves pain, tenderness, and swelling in a surprisingly short time, and superficial infections sometimes disappear rapidly. This is not surprising in view of our knowledge of radiant energy from the Finsen light, the Röntgen ray, and the high-frequency electrical currents. The 500 candle-power lamp is known to possess high chemical and penetrating properties. In addition to this the heat rays are, of themselves, of great usefulness in promoting inflammatory reactions. The combination of the chemical and the heat rays is ideal for the treatment of inflammatory diseases, as the reaction excited is more profound than with either the heat or the chemical rays alone. The range of application of the 500 candle-power lamp is as wide as inflammation itself. It will not cure all cases, but if the reaction is inadequate it will benefit in so far as it promotes adequate reaction. If there is excessive reaction its use is contraindicated, cold being indicated. If adequate reaction is present, as in incised wounds healing by first intention, its use is contraindicated. It should be remembered that the inflammatory reaction usually reaches its maximum of efficiency at the end of about twenty-four hours, and that to get the maximum results by any of the modalities referred to in this section they should be applied within the first twenty-four hours, before tissue proliferation begins. Tissue proliferation of a permanent type begins at about the fifth day of acute inflammation, and becomes more and more established as time goes on. This is practically illustrated in acute mastoiditis, where the simple operation is almost always successful if performed within the first five days of the disease, whereas after that period its permanent success is more and more doubtful.

The explanation is obvious in view of the well-known fact that tissue proliferation is a manifestation of chronic inflammation, and that chronic inflammation is not readily checked by any direct mechanical means at our command, except by a most thorough exenteration of all the diseased tissue and the establishment of free drainage.

Bier's Treatment.—Bier's treatment has attracted a great deal of attention within the last few years. It is based upon the promotion of hyperemia in the treatment of acute suppurative, tuberculous, and other conditions. He promotes both active and passive hyperemia; active by the use of hot air, and passive by constriction of the parts and by negative air pressure in cavities. He finds active hyperemia of more value in chronic cases, where proliferated tissue is to be absorbed. He also finds it useful in acute cases, but not so useful as passive hyperemia induced by compression so applied as to temporarily obstruct the efferent veins of a part, without arresting the entry of blood through the afferent arteries. He also employs suction by cupping over small inflamed areas, and by large glass chambers into which the affected

part, as the hand or foot, may be introduced and the surrounding air rarefied.

Sondermann has devised an apparatus especially adapted for producing negative air pressure in the air cavities of the head. Brawley, Dabney, and Pynchon have also devised apparatuses for this purpose.

Bier's treatment is applicable to those cases of acute inflammation in which the inflammatory reaction is inadequate to cope with the irritant noxa causing the inflammation. The treatment should not be applied so as to produce excessive reaction (white edema) of the tissues. It should never cause pain. It must not produce paresthesia or false sensation. In the nasal chambers it should not be kept up for more than one-half to one hour at a time. The mode of treatment requires great caution in its use, as much harm can be done with it. If white edema is induced, the bacteria spread through the tissues and the process becomes more generalized. Heat is then indicated.

Inflammation is not yet fully understood, and until it is cases cannot be individualized for treatment. Wright's demonstration of *antitrophins, precipitins,* lysins, and opsonins in the blood, and that the opsonins are of greater importance than the leukocytes, as the latter are dependent upon the former for their efficiency, has disturbed existing ideas to such an extent that there is a "shuffling of dry bones" in the scientific world. It appears that the leukocytes cannot digest or neutralize the bacteria until they have been acted upon, weakened, or rendered vulnerable by the opsonins. It would seem that these researches show that Bier's method of inducing hyperemia does not simply flush out the inflamed area, but that the supply of leukocytes and antitropins causes a rapid removal of the dead bacteria from the field of action through the energized leukocytes (Adami). It appears therefore that the opsonic index is of even greater importance than the leukocytic index. Should the leukocytosis be marked and the opsonins scanty, the bactericidal and scavengerial properties of the leukocytes would be greatly impaired, and the reaction, while apparently adequate according to the older standard, would be inadequate according to the newer standard of the opsonins. (See the Opsonic Index and Vaccine Treatment of Infectious Diseases.) However this may be, further observations are necessary before the older standard is abandoned for clinical purposes.

Technique.—In acute inflammatory diseases of the nose and accessory sinuses negative air pressure produced by the Sondermann, the Brawley, or the Dabney-Pynchon devices may be obtained as follows:

(*a*) Introduce the nasal tip or tips into the anterior naris, turn on the exhaust power (hand bulb, water, or compressed air, according to the apparatus used), and instruct the patient to swallow. This brings the soft palate in contact with the posterior wall of the pharynx and closes the communication between the epipharynx and the mesopharynx. The air in the nose and accessory sinuses and the Eustachian tubes is rarefied, and hyperemia of the mucous membrane results. After a little practice the patient is able to maintain the state of negative pressure for several minutes at a time.

(*b*) The negative pressure should be alternated every three to five minutes with periods of rest, the whole period of treatment extending over fifteen to forty-five minutes.

(*c*) If the treatment is attended by pain, bleeding, or white edematous swelling the negative pressure is too great and should be reduced. Heat in the form of hot air is indicated to counteract the white edematous swelling should it occur.

(*d*) The nose-piece should be patterned after the Seigel otoscope, so that the mucous membrane may be inspected during the course of application of the negative air pressure, and if the membrane becomes pale and edematous, or bleeds, the treatment should be abandoned for twenty-four hours; that is, paralysis instead of dilatation of the vessels has occurred, and the nutrition of the cell structures and the local leukocytosis have been still further diminished. The method of treatment, therefore, requires the greatest care and intelligent application to be beneficial. Its careless and indiscriminate use can only produce harmful effects. The greatest objection to the mode of treatment is the ease of application and ease with which great harm can be done with it.

Indications.—(*a*) In the first five days of acute rhinitis. (*b*) In the first five days of acute sinuitis. (*c*) In the first five days of acute inflammation of the pharyngeal tonsil. (*d*) In acute tubal catarrh. (*e*) Chronic purulent inflammation of the sinuses. In chronic cases the negative air pressure should be very moderate, as otherwise it might produce edema and white swelling and add fuel to the flames. Its greatest efficiency will be found in acute inflammation. In chronic inflammation, either catarrhal or suppurative, heat in the form of hot air is a more rational mode of treatment, as it produces an active hyperemia and increases the cell nutrition. The negative pressure produces a passive hyperemia and leukocytic migration, processes much needed to promote speedy resolution of the inflammatory process.

(*e*) When purulent secretions are present they are drawn into the bottle reservoir of the apparatus. In these cases the negative air pressure not only promotes the inflammatory reaction, but it removes the irritating secretions as well.

(*f*) The treatment should be repeated every day or every other day.

THE OPSONIC INDEX AND VACCINE TREATMENT OF INFECTIOUS DISEASES.

The opsonic index and vaccine treatment is essentially a painstaking laboratory process, and cannot be used as a routine mode of treatment. It should only be attempted, therefore, when such facilities are at the service of the physician. The method appears so promising, however, that it should be tried whenever suitable cases and expert laboratory control are available. The value of the opsonic index control has been best demonstrated in local tuberculous lesions, but it has also been demonstrated in a lesser number of cases in which streptococcal, staphylococcal, colon, and other bacterial infections are present.

The opsonic index is based upon the average value of a number of healthy non-tuberculous subjects, and is indicated as 1.0. The principle underlying the vaccine treatment under the guidance of the opsonic index is as follows:

Certain white blood cells and endothelia are enabled to take up and destroy bacteria. This process is called phagocytosis. Wright and others have shown that these corpuscles can only do this after the bacteria have been acted upon by the opsonins of the blood. If the amount of opsonins is normal, or 1.0, phagocytosis is normally and rapidly performed; if the opsonins are below normal, phagocytosis is imperfectly performed. The opsonic bodies probably attach themselves to the bacteria, and weaken or otherwise prepare them, so that they are readily enveloped and destroyed by the white blood corpuscles. If, therefore, the opsonins are deficient, the bacteria are not sufficiently prepared for destruction by the white corpuscles. The opsonins appear to be an index of what has formerly been called the "resistance" of the cells of the body. *Opsono* is a Latin verb, which means, "I prepare for food."

When a subject is infected by tubercle bacilli, or other pathogenic microörganisms, he has less than the normal amount of opsonins in the blood and is said to have a lowered opsonic index, or lowered resistance. This fact has been utilized in diagnosticating obscure hidden local tuberculous processes.

Wright and others have shown that when a subject affected by local tuberculosis is injected with Koch's new tuberculin, the opsonic index first falls a little, then rises to, or above, normal. The opsonic index is taken daily, and after a few days it begins to fall. When it has again receded considerably below normal another injection of Koch's tuberculin is given. In this way the patient's opsonic index is maintained near normal, and the maximum of bacterial destruction is maintained. The general condition of the patient is better when the opsonic index is high or near normal, and it is worse when it is low.

Too small or too large a dose of Koch's new tuberculin is ineffective. Indeed, too large a dose is marked by a rapid, steep fall in the opsonic index and the impoverishment of the patient. This shows the importance of using the opsonic index in regulating the dosage of Koch's new tuberculin, and explains the various and conflicting results reported from its improper use.

The serum treatment of sinuitis and mastoiditis under opsonic control, according to J. C. Beck, affords apparently good results, though it is too early to foretell its ultimate place in the therapy of the infectious diseases of the accessory cavities of the head. The leukodescent light also seems to give good results, though their permanency has not been demonstrated. A more rational therapeutic measure is to establish ventilation and drainage, thereby removing the chief predisposing cause of infection and inflammation, and then administer the appropriate serum prepared from the bacteria peculiar to each case, the opsonic index being determined at intervals of two or three weeks. This is in accordance with Wright's own statement.

CHAPTER VIII.

THE INFLAMMATORY DISEASES OF THE NOSE.

ACUTE RHINITIS DUE TO MICROÖRGANISMS OF SPECIFIC FEVERS AND TO CONSTITUTIONAL DYSCRASIAS.

It is a well-recognized clinical fact that the initial stage of the various exanthematous or specific fevers is characterized by an attack of acute rhinitis. Certain constitutional dyscrasias also give rise to acute rhinitis. The infectious or exanthematous fevers commonly characterized by an attack of acute rhinitis are smallpox, typhoid fever, acute articular rheumatism, epidemic influenza (la grippe), erysipelas, and diphtheria.

The symptoms of all the foregoing types of specific acute rhinitis are about the same, except in diphtheria, where a pseudomembrane may be present. There are the usual manifestations found in coryza with conjunctivitis and photophobia. An examination of the mucous membrane of the nose and fauces sometimes shows an eruption quite similar to that found on the skin.

The treatment should consist in the use of mild alkaline solutions with an atomizer or a nasal douche. The objection to the douche is the possibility of carrying the infection to the middle ear should the patient happen to swallow while the fluid is in the nose. The nose should be irrigated three or four times daily.

The constitutional dyscrasias which cause acute rhinitis are acute articular rheumatism, diabetes mellitus, and scorbutus. In diabetic rhinitis the symptoms when present rise and fall with the percentage of sugar in the urine. Scorbutic rhinitis is associated with infantile scurvy, and is characterized by an excoriation about the nasal orifice.

The *treatment* should be addressed to the relief of the local nasal symptoms and to the improvement of the constitutional dyscrasias.

ACUTE RHINITIS.

Symptoms.—Acute coryza; cold in the head.

Definition.—Acute rhinitis is an acute inflammation of the nasal mucous membrane, characterized by chilly sensations, lassitude, nasal discharge, and a swelling of the mucous membrane of the nose. The patient also complains of a stuffiness of the nose and sneezing.

Etiology.—The chief predisposing cause of acute rhinitis in adults is an obstructive lesion of the nasal septum, which predisposes to the local growth of the pathogenic bacteria and the development of their toxins,

hence the inflammatory reaction in the form of an acute rhinitis. The ridge or other deviation of the septum impinges upon, or is closely approximated to, the inferior nasal concha (inferior turbinated body), thus interfering with drainage and ventilation of the nose and accessory sinuses. When the anterior portion of the septum is thus deformed it obstructs the breathway, and each descent of the diaphragm acts like the piston valve of a syringe and rarefies the air in the nasal chamber posterior to the obstruction. The negative pressure thus created causes the blood to fill the vascular tissue of the swell bodies on the inferior and middle turbinals, hence the stuffiness of the nostrils. Furthermore, the mechanical irritation caused by the pressure of the ridge or other deviation against the turbinals still further aggravates the irritation and swelling of the mucous membrane. The secretions are thereby increased in quantity and changed in character.

Inquiry usually elicits the statement that the patient (if an adult) has been inclined to chronic rhinitis; indeed, a complete examination often shows the patient to have been subject to acute exacerbations of a chronic rhinitis, and that a septal deformity is present. Septal deformity is not, however, always present, hence each case should be studied for the peculiar etiological factors back of it, so that the treatment for the ultimate cure and prevention of the acute exacerbations may be intelligently directed.

Another very common cause of acute rhinitis is an imbalance in the vasomotor nervous system. There is a paralysis of the vasoconstrictor muscle fibers of the capillaries or an irritant in the blood which affects the dilator fibers.

The paresis and irritation may be due to the presence of uric acid and its kindred products or to other acquired dyscrasia. The imbalance of the vasomotor nervous system may also be due to the inadequate ventilation of the living and sleeping rooms, offices, etc., or to the wearing of improper clothing. The removal from the country to the city is often followed by frequent attacks of acute rhinitis on account of the changed conditions of living. In the country the houses are less tightly constructed and but partially heated, whereas in the city the houses are more tightly constructed and either overheated or, as is often the case, is underheated in all its rooms. In either event the conditions are worse in the city dwelling, as fresh oxygen is a negligible quantity on account of the poor ventilation. Then, too, while resident in the country much of the day is spent in the open air, whereas in the city it is spent in crowded and illy ventilated offices and shops. It is obvious, therefore, that rhinitis due to poor ventilation should be treated by changing the mode of living to one which keeps the patient in the open air or in a well-ventilated residence and business buildings.

The causative relationship of clothing to acute rhinitis is unquestioned, though it is difficult to describe the exact mode of clothing that predisposes to rhinitis. It may be said, however, that clothing which favors perspiration is vicious. There is normally some evaporation of moisture from the body, hence the underwear should be of such material as to

readily absorb it. The function of underwear is twofold, namely, (*a*) to retain the body heat between it and the skin; (*b*) to absorb the excess of perspiration. If, therefore, the clothing is of such density that it causes undue perspiration, and of such material that it does not absorb it, the conditions are favorable for the development of acute rhinitis, even though the septum is normal. Wool retains the body heat, but is a poor absorbent. Cotton is neither a good heat retainer nor an absorbent. Linen is a fair heat retainer and a good absorbent. In some cases wool retains too much heat and induces profuse perspiration. A garment of wool and cotton, or wool and linen, or of thin linen under a light woollen garment, seems to be suitable to the proper protection of the body. Linen mesh in some cases is insufficient protection during the winter months for some people, whereas it is worn with the greatest comfort and satisfaction by others throughout the year. It should be determined in each case whether the rhinitis is due, in part, at least, to excessive protection and perspiration, or to deficient absorption of the perspiration. Then, too, the question extends to the external garments worn both in and out of doors. For the sake of convenience the outer garments should be lessened or added to as the exposure to the temperature and weather demands, while the undergarments should be of moderate weight and capable of absorbing the visible and invisible perspiration.

A preëxisting chronic rhinitis is a common factor in the causation of acute rhinitis, especially in adults, whereas infants and young children are more susceptible, and often have colds in the head without a preexisting chronic rhinitis.

As stated in Chapter VI, inflammation is almost always of bacterial origin, the conditions necessary for the growth of the bacteria being a lowered vitality of the cells of the tissues. I also stated that mucous membrane-lined cavities with blocked drainage and ventilation were especially subject to infection and inflammation. Trauma, chemical injury, and shock also lower the cell vitality and prepare the soil for infection and inflammation. Exposure to cold and draughts are common sources of shock that result in acute coryza or inflammation of the nasal mucous membrane, hence obstructive lesions of the nasal septum are not always present in patients subject to acute coryza. Certain constitutional diseases, as diabetes, rheumatism, etc., reduce the vitality of the mucous membrane of the nose and accessory sinuses, and are, therefore, predisposing causes of this disease. All conditions, local and general, which lower the vital resistance of the mucous membrane of the nose act as predisposing causes to infection and inflammation of the nasal mucous membrane. I wish to emphasize again the fact that in many instances the chief predisposing cause of acute coryza (acute infectious inflammation of the nasal mucous membrane) is an obstructive lesion of the septum. The influence of exposure to cold, draughts, foul air, poor ventilation of houses, offices, etc., have heretofore been given undue prominence, to the neglect of nasal stenosis (partial and complete), which so often bears an important relation to this disease. It

follows that chronic rhinitis is often present in persons subject to recurrent attacks of coryza, a condition which still further lowers the vitality of the nasal mucosa and predisposes to the growth of bacteria and the development of their toxins, which excite the inflammatory reaction known as acute coryza, acute rhinitis, and a "cold in the head."

In emphasizing these facts I do not wish to obscure or belittle the other factors that reduce the vitality of the tissues and which predispose to the acute inflammatory disease. I only wish to give a true perspective to the underlying causes of acute coryza, so that in the treatment a more rational basis of procedure may be adopted.

Acute rhinitis undoubtedly has an infectious origin, the foregoing etiological factors predisposing to the infection.

Nasal polypi and other morbid processes within the nasal chambers also predispose to rhinitis.

Pathology.—The vasomotor constrictor muscle fibers of the capillaries are paralyzed and the dilator fibers irritated, and, as a consequence, there is a passive hyperemia of the venous capillaries and lymph vessels, and the nose becomes "stuffed." There is also an increased migration of leukocytes and a transudation of lymph and serum. The production of mucus is temporarily checked, but later is increased. The epithelium is exfoliated and admixed with the other inflammatory products and secretions.

During the first stage the secretions are greatly reduced in quality or are entirely absent. In the second stage the secretions are at first serous, and later become thick and viscid from the excessive degeneration of the goblet and glandular epithelial cells. In the third stage the secretions are mucopurulent or purulent in character.

The duration and course of the inflammatory process varies. The natural history of the average case is completed in from eight to ten days, though under appropriate treatment it may be greatly shortened.

Symptoms.—The symptoms are, for clinical purposes, divided into three groups, as follows:

First Stage, or Onset.—The patient experiences a sense of dryness or prickling in the nose, with itching at the inner canthi of the eyes. Chilly sensations and a feeling of malaise are complained of. Examination shows the mucosa to be red and hyperemic, but not fully turgescent. The mucous membrane is abnormally dry and free from secretions. Headache is usually present, and there is a sense of fulness between the eyes. This stage lasts but a few hours. The temperature ranges from 100° to 103°.

Second Stage.—This stage is characterized by a profuse serous discharge and turgescence of the mucous membrane. In some cases the headache and the sense of fulness between the eyes are diminished, whereas in others it is increased, depending upon the patency or closure of the ostei of the accessory sinuses. In those cases in which there is a marked deviation of the nasal septum in the region of the middle turbinal the obstruction of the ostei on one side may be great and the pain and sense of fulness correspondingly increased on that side.

Third Stage.—This stage is characterized by a mucopurulent or purulent discharge and by a marked decrease in the temperature. The headache and the sense of fulness between the eyes may be diminished so as to amount to a dull heavy feeling across the forehead and between the eyes. If the nasal accessory sinuses are also markedly involved in the inflammatory process the frontal headache and the sense of pressure are correspondingly pronounced. If the sinuses are not involved these symptoms may be entirely absent. Dizziness and vertigo also may be present if the sinuses are involved. The use of the eyes in reading, sewing, or at the theatre often produces headache and other evidence of ocular irritation when the sinuses are involved in acute rhinitis.

Prognosis.—The natural duration of acute rhinitis is from eight to ten days. When the sinuses are also involved the duration is extended to two weeks, or even longer, unless the attack is aborted by appropriate treatment. Some writers claim there is no curative treatment of acute rhinitis. I believe this to be an erroneous view, and hold that nearly all cases may be cured if taken sufficiently early and rational treatment is used.

Treatment.—The treatment of acute rhinitis should be undertaken with a knowledge of the nature of inflammation and the chief predisposing and active etiological factors in mind. These are (*a*) obstructive lesions; (*b*) lowered tonicity of the cellular structures of the nasal mucous membrane, and (*c*) the infectious microörganisms.

(*a*) If there is an obstructive lesion in the nose it should be located by rhinoscopic examination. When found, and demonstrated to be spongy or erectile tissue, local applications of cocaine, adrenalin, and antipyrine should be made to this region to reduce the swelling and to establish the patency of the nasal chambers. By so doing drainage and ventilation are reëstablished, points of immense value in promoting the reaction against the bacteria and toxins causing the disease. It is not advisable to attempt to remove by surgical means the obstructive lesion during the acute symptoms, though such a procedure may well be undertaken after they have subsided. The retention of the secretions and the lack of ventilation, together with the mechanical irritation from pressure, aggravate the existing irritation and tend to perpetuate the reaction of inflammation and prolong the disease. The reaction is often inadequate to throw off the bacteria and their toxins, hence measures should be used that will promote the reaction of inflammation, which is Nature's effort to cure the disease.

The question naturally arising in this connection is, How may the reaction of inflammation be promoted? That is, what measures may be adopted that will aid in combating the bacteria and their toxins? As stated in the section on Inflammation, acute inflammation consists in three reactions, namely: (*a*) Increased hyperemia; (*b*) increased cell nutrition, and (*c*) increased migration of leukocytes. The purpose of these reactions is (1) to increase the vitality of the attacked tissues (2) to remove the bacteria and toxins, and (3) to remove the dead and broken-down cells.

The increased hyperemia furnishes extra food for the attacked and weakened cells, while the increased migration of leukocytes provides for the destruction and removal of the invading bacteria and the dead and broken-down cells. Adami has shown that in acute inflammation the inflammatory reaction is usually inadequate for these purposes, although it has generally been held that it is excessive. He advises, therefore, that acute inflammations be treated by such modalities as will promote the reaction of inflammation, rather than check it. According to former formulæ of thought, remedies which acted favorably upon acute inflammations were said to lessen the inflammatory reaction, whereas a more correct and scientific statement is, that the remedies promoted the inflammatory reaction (Nature's effort to rid the tissues of bacteria and their toxins) and thereby hastened the cure of the disease. It is with this understanding that I advise the use of such remedial measures as will promote the reaction of inflammation.

The exact effect of the many drugs upon these reactions is so little understood that it is a difficult task to undertake to give their use a scientific basis. The empirical use of drugs has long been practised, and must doubtless continue to be practised, empirically at least, until their action is better understood. We know enough about a few of them to criticise their use in acute coryza. Adrenalin has been much used in this disease because it was thought that the progress of the disease would be affected favorably by reducing the inflammatory reaction. I believe that its use for this purpose is contra-indicated, because the inflammatory reaction is an effort to remove certain noxa or irritants from the tissues, and should not, therefore, be checked by the local use of adrenalin or any other substance. The physician should recognize the activities known as inflammation as forces directed against a noxious foe, and should aid or promote them rather than thwart or check them. The chief difficulty in arriving at a correct understanding of inflammation is that the results of inflammation are confused with the process itself. When I advise the promotion of inflammatory reaction, I do not mean that it should be made worse, that cell proliferation should be increased, that the pain and soreness should be increased, that adhesive processes should be encouraged, etc. These are the results of inflammation, and are not essential features of the reaction. What I mean by promoting the reaction of inflammation is to use such modalities of treatment as will increase the hyperemia, the cell nutrition, and the migration of leukocytes. By so doing the irritant noxa is removed, and the cell proliferation, pain, and adhesive processes are quickly relieved or altogether prevented.

Unfortunately, the treatment of acute coryza has not been systematically treated upon the basis herein outlined, hence there is little accumulated evidence upon which to base a scientific and well-established mode of treatment. Science is not science until proved; hence there is no scientific method of treating acute rhinitis.

While the methods of treatment to be given are somewhat hypothetical and in some instances purely empirical, they have been rather extensively tried and have proved to be of more or less value in promoting the

inflammatory reaction of acute coryza; that is, they have hastened the destruction of the bacteria and noxa causing the disease.

(*b*) The tonicity of the vasomotor nervous system should be maintained by the administration of strychnine and arsenous acid in the usual tonic doses. Furthermore, the patient should have plenty of fresh air in his room, if it can be arranged without exposing him to a draught. The administration of aconite or belladonna may be resorted to for the immediate effect upon the turgescence and the secretions, especially in the second stage. An alcohol rub over the entire body also acts as a tonic to the vasomotor nervous system and increases the hyperemia of the arterials and capillaries, and thereby increases the nutrition of the mucous membrane.

(*c*) While it has not been shown that the disease is due to a specific microörganism, it is evident that bacteria are the exciting cause of the disease. An endeavor should be made, therefore, to establish conditions favorable for their destruction and elimination. This is best done by establishing and maintaining drainage and ventilation and promoting the reaction of inflammation. The use of antiseptics has no effect in destroying the bacteria, though they do promote reaction of inflammation. Surgical experience has shown that free drainage is of prime importance in the treatment of infected cavities, as, for instance, in septic peritonitis complicating a ruptured appendix. Irrigation of the abdominal cavity has been abandoned and simple drainage substituted, with the most brilliant results. The operative procedure promotes the reaction of inflammation, and thus hastens the destruction of the infecting bacteria. The same principle applied to acute infectious inflammations of the nasal and accessory sinuses brings equally brilliant results. Hence, the mode of treatment described in paragraph (*a*) will, in most instances, meet the indications. If it does not, the obstructive lesions of the septum (or other lesion) should be removed by surgical means at the earliest possible time, so as to prevent such a complication during subsequent attacks of acute rhinitis.

In addition to the foregoing measures the use of the leukodescent lamp over the nose and eyes is recommended, to promote the reaction of inflammation. The light from this lamp is rich in blue violet rays, in addition to the heat rays, and they exert a powerful and immediate salutary effect upon the inflammatory process; that is, they greatly increase the hyperemia and the leukocytosis, and thus dispose of the bacteria, their toxin, and the dead cells of the tissues. Having done this, the reaction often rapidly subsides and a cure is effected.

A treatment with the lamp should cover a period of from twenty to thirty minutes, at a distance of about eighteen to twenty inches from the face. The light is more effective if applied over the closed eyes, as the tissues are soft and easily penetrated by the rays, and because the veins of the accessory sinuses empty into the ophthalmic vein. Hence, any increased flow through the ophthalmic vein favors the flow from the veins of the sinuses and the nose. As acute rhinitis is essentially an acute sinuitis, the reaction affecting the sinuses effects a speedy relief or a cure.

The above mode of treatment is based upon rational principles, which, for the sake of emphasis, are recapitulated here:

(*a*) The establishment of ventilation and free drainage of the nasal accessory chambers.

(*b*) The establishment of the tonicity of the vasomotor nervous system.

(*c*) The promotion of the elimination of the bacteria by the drainage and ventilation of the nasal and accessory sinuses.

(*d*) The promotion of the reaction of inflammation by the leukodescent light.

Other Methods of Treatment.—1. The administration of full doses of quinine and a hot lemonade at bedtime will, in some instances, during the first stage, abort acute rhinitis by increasing the hyperemia and leukocytosis. If given during the second or third stages they are ineffective. This method is not so efficacious as the one given above, but is worth trying.

2. Ten grains of Dover's powder and a hot mustard foot bath at bedtime promote the reaction of inflammation to a considerable degree, and during the first stage may abort the disease. During the second and third stages it is more difficult to promote the reaction of inflammation, hence this mode of treatment is not powerful enough to be of much value.

3. The administration of rhinitis or coryza tablets, containing quinine, belladonna, and morphine, during the first stage will in a number of cases abort acute rhinitis. One tablet should be given every twenty minutes until dryness of the nose is produced.

4. Aconite administered hourly in the first stage in 1 minim doses until dryness of the throat or tingling of the fingers is produced will sometimes abort the disease. During the second and third stages the remedy is of little use.

CHRONIC RHINITIS WITH TURGESCENCE.

Synonyms.—Alternating stenosis; simple chronic rhinitis.

Definition.—Chronic rhinitis with turgescence is characterized by fugitive swelling or turgescence of the swell bodies of the inferior turbinated bodies, the patient complaining of attacks of nasal obstruction and a thick mucous discharge.

Etiology.—The causes of rhinitis are given under the etiology of acute rhinitis, and will not be repeated in detail here. It should be stated, however, that in most cases there is a deviation of the septum in its lower and middle portion. The deviation may also be an anterior one near the vestibule of the nose in the cartilaginous portion of the septum, thereby producing anterior nasal stenosis. With each descent of the diaphragm the air is rarefied posterior to the obstruction, and a negative pressure in the nasal chambers results. The blood in the mucous membrane lining the nasal chambers is thus determined to the venous plexuses (swell bodies) of the turbinals, and turgescence or engorgement results.

In the section on the Deviations of the Septum I have shown that

obstructive lesions in the region of the inferior turbinal act in such a way as to produce engorgement of the tissues without much irritation. Hence, the effect at first is simply one of turgescence, which in the course of years of increased nutrition results in hypertrophy or hypertrophic rhinitis. If, in addition to the local turgescence, there is an associated obstruction in the region of the middle turbinal, the retention and decomposition of the secretions in the superior meatus and the posterior ethmoidal cells cause a prolonged low-grade irritation which may result in a hyperplasia of the mucous membrane, not only of the middle turbinal, but of the inferior as well. As an obstructive lesion of the septum in the middle turbinal region often co-exists with the obstructive ridge or spur in the inferior turbinal region, hyperplasia or hyperplastic rhinitis affecting the inferior and middle turbinals is often present. When, however, the upper obstruction is absent, the rhinitis is usually of the turgescent or hypertrophic type.

Pathology.—In the early stage there is a distention of the venous or cavernous tissue of the conchæ (turbinals). If the inflammatory process continues a true hypertrophy or hyperplasia of the tissues takes place on account of the increased nutrition from the large blood supply.

Symptoms.—The symptoms are chiefly referable to transient stenosis of the breathway of the nose. In addition, the secretions are heavier; that is, the mucoid element is increased, while the serous element may be decreased in quantity. The patient believes there is an actual increase, whereas, as a matter of fact, there is probably a decrease in the amount of secretion. The apparent increase is due to the increased consistency of the secretion, which renders it less absorbable by the ingoing current of air. In a normal nose the secretions are comparatively thin or serous and are largely absorbed for physiological purposes in the lower respiratory tract.

The transient stenosis is either intermittent or alternating; that is, both sides may be stenosed for a period and then open, or the stenosis is on one side and changes to the other. These symptoms are quite characteristic of turgescent rhinitis.

The objective signs of turgescent rhinitis are chiefly found in the evidences of the engorged swell bodies of the inferior turbinals. Upon inspection by anterior rhinoscopy the outline of the inferior turbinal is smooth and bag-like, whereas, in true hypertrophy, hypertrophic rhinitis it is firm and unyielding. The application of cocaine or adrenalin shrinks the mucous membrane covering the inferior turbinal, whereas, in hypertrophic rhinitis there is little or no shrinkage.

The secretions are mucoid in character, and when the swell bodies are contracted strings of mucous extend from the septum to the inferior turbinal.

A spur or ridge is usually present upon the lower portion of the septum, causing obstruction in some degree in the region of the inferior turbinal. The cartilaginous portion of the septum may also be deflected, thereby causing anterior nasal stenosis and a consequent rarefaction of the air within the nasal chambers with each inspiratory current.

Epistaxis is also occasionally comp'ained of. The ridge or crest of the septum projects into the inspiratory tract, and is thereby subjected to excessive evaporation of the secretions accumulated upon it. The dried crusts are blown or picked off, tearing the underlying epithelium and the capillary vessels, hence the epistaxis.

Cough may or may not be present, and is due to an associated bronchitis or to a nasal reflex.

A posterior examination of the nasal choanæ may reveal an enlargement of the swell bodies upon the posterior ends of the middle and inferior turbinated bodies. The enlargement has often been likened to a mulberry. It is nodular in outline and of a grayish-blue color.

Prognosis.—If allowed to run its course, true hypertrophy of the tissues in the region of the swell bodies occurs. Under appropriate treatment the disease is curable.

FIG. 89

Method of moistening a thin pledget of cotton with cocaine or adrenalin solution. *a*, the solution in an inverted bottle; *b*, the pledget of cotton.

Treatment.—The treatment should be twofold in character: (*a*) The removal of the predisposing causes, and (*b*) the control of the immediate symptoms.

(*a*) The removal of the predisposing causes is usually accomplished by the correction of the deviated septum. (See Treatment of Deviations of the Septum.) When this is done the negative air pressure in the nasal chambers disappears and the blood ceases to be determined to the mucous membrane, and the tendency to intermittent and alternating stenosis is greatly reduced. The operation of election should be determined according to the type and location of the deviation of the septum.

(*b*) The palliative treatment should be addressed to the immediate control of the distressing symptoms, namely, the stenosis and the heavy secretions. The transient stenosis may be controlled by the use of the electric or chemical cautery or by incising the turgescent swell bodies.

Electrocauterization.—The technique of electrocauterization is as follows:

(*a*) Induce cocaine anesthesia by the application of a 4 per cent. solution of cocaine on a thin pledget of cotton to the swollen free border of the inferior turbinal for a period of ten minutes (Figs. 89 and 90).

(*b*) Turn on the electric current until the point of the cautery electrode is of a bright cherry-red color.

(*c*) Introduce the electrode into the nasal chamber cold and place it on the free border of the interior turbinal (Figs. 91 and 92). Then move it backward and forward, while still cold, until sure of its correct position. Maintain the to-and-fro motion and press the contact spring of the cautery handle for one or two seconds, when the contact should be broken. The to-and-fro motion should be continued until the electrode is cold, that is for two or three seconds after the spring contact is broken, and then it should be removed from the nose.

Fig. 90

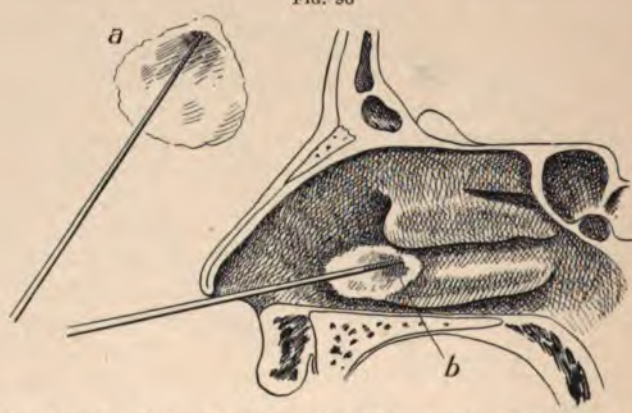

Method of applying the pledget of cotton to the inferior turbinated body. *a*, the pledget of cotton after being moistened with the cocaine or adrenalin solution is engaged upon the tip of a delicate silver probe; *b*, the pledget of cotton being "pasted" or spread upon the inferior turbinated body.

If these instructions are followed the procedure is painless and does not tear the eschar from the turbinal. If the to-and-fro motion is not maintained before, during, and after the electrode is heated, the eschar will be torn off and the cautery effect lost.

The eschar must be left in place. If bleeding follows the removal of the electrode, the eschar is lost and the cauterization rendered useless.

The cauterization should be linear, and should be about one inch in length. The whole length of the inferior turbinal may be cauterized in three sittings (Fig. 93), never in one, as too great a reaction and sloughing may follow.

The sittings should be from five to seven days apart. A week after the first cauterization the opposite side may be treated in like manner. At the end of another week the middle portion of the inferior turbinal

first cauterized may be thus treated. And so continue to cauterize the turbinals alternately, at weekly intervals, until the whole length of both turbinals has been cauterized.

The after-treatment of a cauterized turbinal should consist in an immediate spray of an alkaline solution—Dobel's or Seiler's solution.

Fig. 91

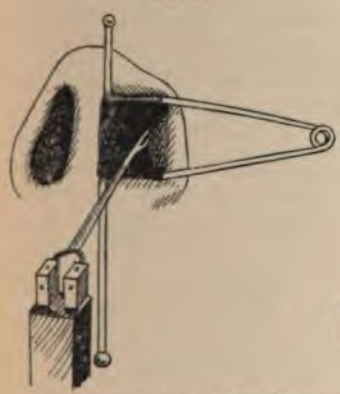

Cauterization of the inferior turbinated body.

Fig. 92

Lateral view, showing the cautery electrode in position for cauterizing the inferior turbinated body.

An oily aromatic nebula should follow this. Prescribe Seiler's solution for daily use by the patient. The wash should be used with a glass nasal douche rather than an atomizer, as the force of the spray might injure the eschar covering the cauterized surface.

Fig. 93

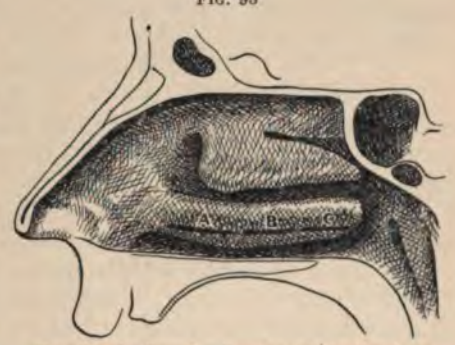

Showing the lines for linear cauterization in turgescent rhinitis. *A*, *B* and *C*, representing respectively the first, second, and third cauterizations, which should be made one week apart.

Should infection occur, gently pack the nose with small cotton pledgets saturated with a 10 per cent. aqueous solution of Merck's ichthyol. Remove the pledget in about fifteen minutes and insufflate bismuth powder into the nose. The clothing should receive thoughtful attention and be regulated according to the indications. Heavy-soled shoes should be prescribed.

Submucous Cauterization.—N. H. Pierce first introduced the submucous cauterization of the inferior turbinated body for the reduction of turgescent and hypertrophic rhinitis. The mucous membrane was punctured near the anterior end of the free border of the turbinate and a tunnel made with a blunt probe beneath the turgescent membrane. A fused bead of chromic acid was then introduced into the artificial tunnel or

channel. M. A. Goldstein improved the instrument for this procedure, as shown in Fig. 94. By Goldstein's method the bead of chromic acid is concealed in the cannula while being introduced, the fused bead of acid then being thrust from the end of the cannula and withdrawn through the channel in the submucous tissue.

Fig. 94

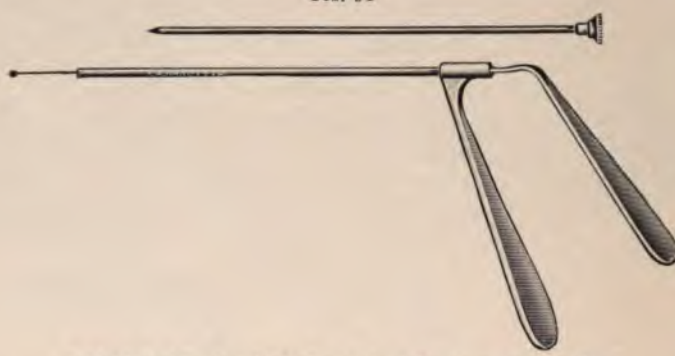

Goldstein's chromic acid applicator for submucous cauterization.

Sloughing sometimes follows this method of cauterization. Chromic acid is very irritating to the kidneys and may cause nephritis. It should never be used in a patient already subject to nephritis, for obvious reasons.

HYPERTROPHIC RHINITIS.

Synonyms.—True hypertrophic rhinitis; obstructive rhinitis; hypertrophic nasal catarrh; hypertrophic ozena; hypertrophy of the turbinated bodies; hyperplastic rhinitis.

Definition.—Chronic hypertrophic rhinitis is characterized by a more or less constant stenosis of the nasal passages. The mucous membrane along the free border of the inferior turbinals is usually hypertrophied, and the stenosis is chiefly referable to the lower portion of the middle turbinal by the bowing of the septum. Such cases are, therefore, sometimes complicated by catarrhal or suppurative sinuitis and hyperplasia. The uncomplicated cases of hypertrophic rhinitis usually present free and unobstructed olfactory fissures on both sides of the septum, the obstructive lesion being limited to the anterior portion of the cartilaginous septum, or to the ridge along the crest of the vomer.

Etiology.—The causes of hypertrophic rhinitis are essentially those given under turgescent rhinitis. When there is an anterior deviation of the septum there is a negative air pressure within the nasal chambers with each inspiratory effort. The hyperemia resulting therefrom leads to an overnutrition of the mucous membrane and especially in the region of the swell bodies. The contact of the deviated septum with the mucosa of the inferior turbinal irritates it and thus still further excites the hypertrophic process. The altered secretions add

to the irritation and still further increase the hypertrophy of the mucous membrane.

In those cases complicated by a high deviation of the septum, and in which there is a complicating sinuitis (catarrhal or suppurative), the tissue changes are somewhat modified. Instead of an hypertrophy, the irritating discharge from the sinuses often causes an hyperplasia of the mucous membrane. There may be present, therefore, both an hypertrophy and an hyperplasia of the tissue. Either the hypertrophy or the hyperplasia may predominate. The so-called hypertrophic rhinitis may, therefore, be divided into two groups: (*a*) The hypertrophic variety, and (*b*) the combined hypertrophic and hyperplastic variety. This subdivision is still further justified by the clinical fact that the symptomatology and treatment of the two conditions are often quite different. The hypertrophic variety presents symptoms chiefly referable to the anterior and the inferior obstruction of the nose, whereas the combined variety presents symptoms referable to obstruction in the middle turbinal region as well as to the obstruction in the anterior and inferior portions of the nasal chambers.

The causes of uncomplicated hypertrophic rhinitis are, therefore, those conditions which give rise to a chronic hyperemia of the mucosa and to a passive engorgement of the swell bodies. These conditions are the anterior and inferior obstructive deviations of the nasal septum and the climatic and hygienic conditions which affect the vasomotor nervous system. In addition to these factors, the mild infection remaining after attacks of acute rhinitis may cause the disease or contribute toward it.

Pathology.—The morbid anatomy of hypertrophic rhinitis consists in an increased blood supply and an increase of tissue from nutritional causes, rather than from irritative and inflammatory causes. The part most frequently hypertrophied is the mucous membrane containing the swell bodies, as there is naturally a greater determination of blood to these vascular bodies.

Symptoms.—The symptoms are chiefly those of more or less nasal stenosis. The secretion is usually heavier than normal, and pasty in consistency, although it may be comparatively thin and watery, especially during an acute exacerbation.

The nasal stenosis may be limited to one side, the side of greater septal convexity. The inferior turbinal on the side of the concavity is often greatly hypertrophied, a so-called compensatory hypertrophy, although, as a matter of fact, it may be due to a negative air pressure within the nasal chamber on that side. The anterior opening of the nose on that side, while normal in size, is, on account of the diminished size of the opposite chamber, inadequate to admit air rapidly enough for physiological purposes; hence, engorgement and subsequent hypertrophy result. It follows that both nasal passages are often more or less constantly blocked in the region of the inferior turbinal. The patient complains of stuffiness, or sense of a foreign body in the nose, and makes frequent but ineffectual attempts to remove it by blowing the nose.

Upon anterior rhinoscopic examination the inferior turbinal is observed to be enlarged and to have an irregular nodular surface. Probe pressure does not cause pitting, as in turgescent rhinitis, but elicits a sense of resistance and of thick, fleshy tissue. The application of cocaine or adrenalin is not followed by marked contraction of the tissue.

Epistaxis from the dislodgement of an adherent crust upon the crest of the deflection occasionally occurs.

Prognosis.—If allowed to run its natural course, hypertrophic rhinitis tends to become worse rather than better. Indeed, in the course of time the secretions may become so heavy and so adhesive in quality as to be removed with great difficulty. In such subjects irritation results and a hyperplasia of the tissue follows. If this is allowed to progress the vascular and glandular tissues become enmeshed in the contractile hyperplastic tissue, and atrophy of the mucous membrane begins.

If, on the contrary, appropriate treatment is instituted sufficiently early in the disease the prognosis is fairly good.

Treatment.—The treatment consists mainly in overcoming the stenosis and the removal of a part or all of the hypertrophic tissue. Sprays and douches of alkaline antiseptic solutions do little more than temporarily increase the reaction of inflammation and relieve the symptoms by the removal of the altered secretions. The removal of the nasal stenosis is accomplished by the surgical correction of the septal deformity and the removal of the excessively hypertrophied turbinal tissue (Fig. 95). (See Obstructive Deviations of the Septum and the Methods of Correcting Deviations of the Septum.) Be assured that in most instances hypertrophic rhinitis is a surgical rather than a medical disease. Be assured, also, that hypertrophic rhinitis cannot be cured by sprays and other local medicinal applications, although they may temporarily relieve some of the symptoms.

Fig. 95

Hypertrophy of the mucous membrane of the inferior turbinated body. *a*, anterior attachment; *p*, posterior attachment. Removed by the author with his turbinotome (Fig. 100). (Dr. Henrietta Gould's case.)

The actual cautery has been recommended for the reduction of the hypertrophied mucous membrane. I can only condemn it as it is inadequate for this purpose. If it is used freely enough to really accomplish anything, it produces excessive scar tissue, a result to be carefully avoided.

Surgical Treatment.—If the hypertrophy is great enough to obstruct the nasal passages, it should be removed surgically with scissors, saw, spokeshave, the swivel knife, or the submucous resection of the inferior turbinated bone.

The Scissors.—The scissors are usually used for the removal of the hypertrophied portion of the free border of the inferior turbinated body. The technique is as follows:

(*a*) Induce local anesthesia by the application of a 5 per cent. solution of cocaine by means of a thin pledget of cotton pasted over the hypertrophied area for ten minutes.

(*b*) With nasal scissors (Fig. 96) cut off the necessary portion of the hypertrophied membrane.

Fig. 96



Beckmann's serrated scissors.

(*c*) Use no dressing except an antiseptic dusting powder. An exception may be made, however, in favor of Pischel's collodion dressing if perfect dryness of the parts can be secured.

(*d*) If severe hemorrhage occurs, it becomes necessary to pack the nose to check it. This may be done by introducing a postnasal tampon with Boloc's cannula (Fig. 97), or with a rubber urethral catheter and then pack a long strip of gauze through the anterior nares against it When such a tampon is used it should be moistened with the compound tincture of benzoin or dusted with bismuth powder to prevent decomposition of the secretions. When either of these precautions is taken the tampon may be left in place for three or four days without putrefaction.

Fig. 97

Boloc's postnasal tampon cannula.

The Saw.—The saw may be used instead of the scissors when it is necessary to remove a portion of the inferior turbinated bone with the hypertrophied membrane (Holmes, Vail).

Technique.—(*a*) Induce local anesthesia with cocaine.

(*b*) Introduce a slender nasal saw beneath the inferior turbinated body and saw in an inward and upward direction through it. If it is impossible to insert the saw beneath the turbinated body it may be introduced above it and the incision carried downward and outward through the tissue.

(*c*) Either use no dressing or use the Pischel collodion dressing when conditions are favorable, that is, when all hemorrhage ceases.

The Spokeshave.—The spokeshave may be used if it can be engaged posteriorly in such a position as to enable the operator to control its direction in cutting forward. This operation is rarely justifiable, as too much of the turbinate is removed by it.

The Technique.—(*a*) Induce local cocaine anesthesia. (*b*) Make a linear incision along the mediosuperior surface of the inferior turbinal

Fig. 98

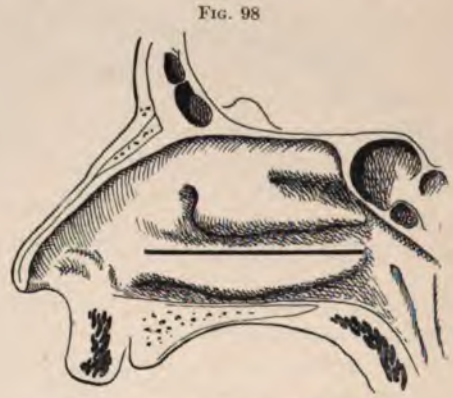

Showing the incision preliminary to the removal of the inferior turbinated body with the spokeshave or swivel knife.

Fig. 99

Spokeshave.

Fig. 100

The author's swivel turbinotome.

just at the upper margin of the hypertrophied tissue (Fig. 98). The incision is for the purpose of preventing laceration of the mucous membrane as the spokeshave is drawn through it. Healing is promoted by a clean cut.

(*c*) Introduce the spokeshave (Fig. 99) at the posterior extremity of the turbinal if there is a mulberry hypertrophy there, or along the free border of it if only that portion is involved. Engage the turbinated body and pull forward in such a direction as to only include the

hypertrophic tissue. The spokeshave should not be used unless it is desired to remove some bone as well as soft tissue.

Fig. 101

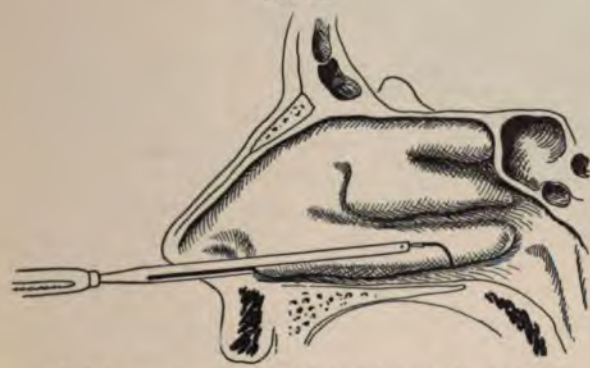

The removal of the anterior two-thirds of the inferior turbinal with the author's wide swivel knife (Fig. 100).

Fig. 102

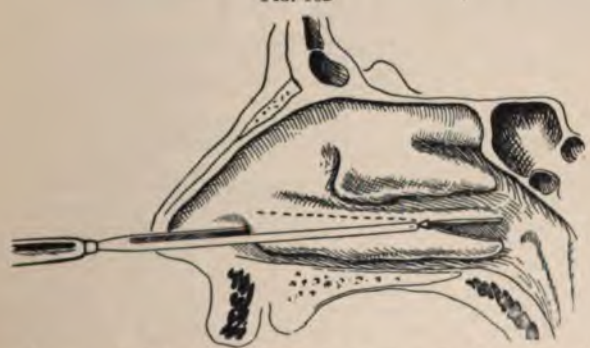

Showing the removal of the inferior turbinal with the author's large swivel knife.

Fig. 103

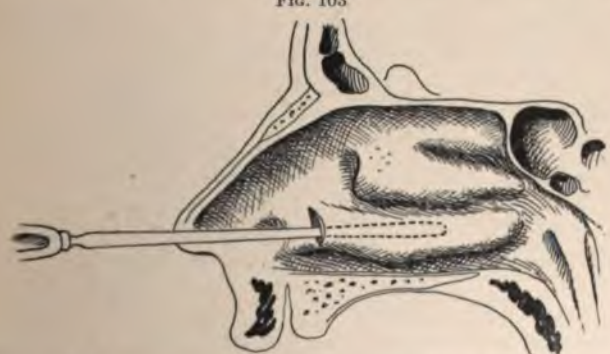

The elevation of the mucoperiosteum of the inferior turbinated body preparatory to the submucous resection of the bone.

(*d*) Follow the same method of after-treatment given in the previous operations.

Fig. 104

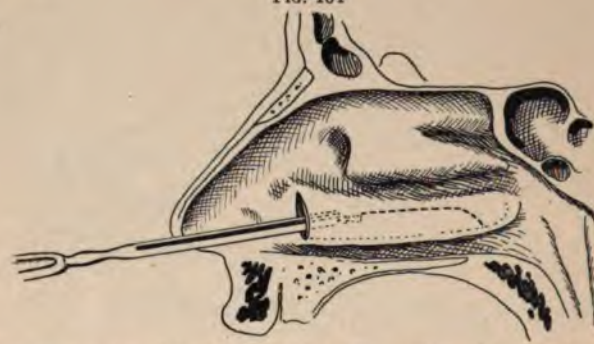

The submucous resection of the border of the inferior turbinated bone with the author's swivel knife.

Fig. 105

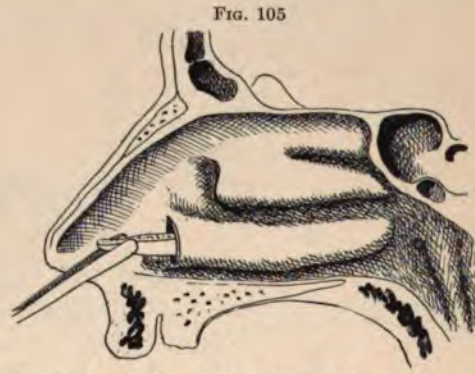

Removal of the severed border of the inferior turbinated bone after its submucous resection with the author's swivel knife.

Fig. 106

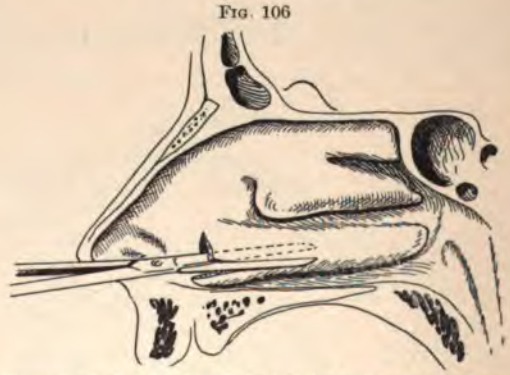

Removal of the hyperplastic free border of the inferior turbinal after the submucous resection of the bone shown in Figs. 103 to 105. The fleshy border is not thus removed, except when very pendulous, as it shrinks greatly upon being sutured. (Beck's method.)

The Swivel Knife.—The author's large swivel knife (Fig. 100) may be used with even greater advantage than the spokeshave, as it can be made to engage or leave the tissue at any desired point along the free border of the turbinal. The knife used for this purpose is especially designed with a view to its width and strength. Otherwise it is similar to the one used in the submucous resection of the nasal septum.

The Technique.—(*a*) Induce local cocaine anesthesia.

(*b*) Insert the swivel knife as though it were a spokeshave and force the blade into the turbinate posterior to the hypertrophied tissue (Figs. 101 and 102). When it has sufficiently engaged in the tissue pull it forward, as in the spokeshave operation, and disengage it by directing it downward toward the floor of the nose when the anterior limit of the hypertrophy has been reached. The preliminary incision of the membrane is un-

FIG. 107

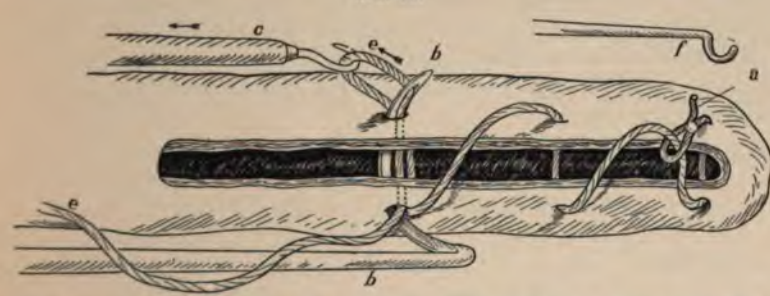

Schema showing the technique of making a continuous suture of the mucous membrane flaps after the submucous resection of the inferior turbinated bone. *a*, the slipknot at the posterior end of the turbinated body—the suture thread should be eighteen inches long, so that the slipknot may be arranged outside of the nasal chamber and then pulled into position; *b b*, the curved needle on a fixed handle; *c*, the hook for pulling the thread *e* through the needle wounds in the flaps, and from the eye of the needle. When the thread is thus liberated the needle is reversed and removed from the nose. It is again threaded with *e* and another stitch taken. Four or five stitches are sufficient to coapt the edges of the flaps. When all the stitches are made introduce the hook *f* and exert tension upon each stitch, beginning with the posterior one. At the same time keep up tension on the proximal end of the thread *e*. In this way the whole length of the wound may be closed. Fix the anterior end of the suture by a knot. Remove the suture on the third day.

necessary, as the cutting edge of the blade is concave and prevents laceration of the mucosa. Bone, as well as soft tissue, may be removed with it.

(*c*) The after-treatment should be the same as in the other operations.

The Submucous Resection of the Inferior Turbinated Bone.—Dr. J. C. Beck has developed the following technique for the reduction of enlarged and obstructing inferior turbinals:

(*a*) Cocaine anesthesia.

(*b*) Make an incision through the mucous membrane at the anterior end of the inferior turbinated body (Fig. 103).

(*c*) Introduce a small blunt probe or elevator through the incision and elevate the mucous membrane from the turbinated bone on its median and external surface (Fig. 103).

(*d*) Introduce the swivel knife through the anterior incision into the mucous pouch and engage the turbinated bone, and sever it as shown in Fig. 104.

(*e*) Remove the bone with small dressing forceps (Fig. 105).

(*f*) If this does not sufficiently reduce the size of the turbinated body, a portion of the hypertrophied membrane may also be removed with scissors (Fig. 106). In some cases the submucous removal of the bone alone will be sufficient to overcome the stenosis.

When the hypertrophied mucous membrane is also removed it is good practice to close the wound with sutures, as they prevent hemorrhage and the absorption of septic matter. Dr. Beck's method of suturing within the nasal cavity is simple and quickly accomplished, and is as follows:

(*g*) A short curved needle set at right angles to the shank of the instrument is introduced into the nasal chambers as far as the posterior end of the incision. The needle is then passed through both edges of the cut membrane, the thread caught with a small hook, and the needle withdrawn. For further description of the suture see Fig. 107 and the accompanying legend.

HYPERPLASTIC RHINITIS.

Synonyms.—The same as given under hypertrophic rhinitis, as the two conditions are often confused.

Definition.—Hyperplastic rhinitis is characterized by an increase in the thickness of the mucous membrane and its contents as a result of prolonged mild irritation by the secretions from the sinuses. It differs from hypertrophic rhinitis in its causation and in its morbid anatomy. In hypertrophy there is an increase in the size of the cells from overnutrition, whereas in hyperplasia there is an increase in the number of cells, and especially of the connective-tissue cells, from the slight but prolonged irritation.

Etiology.—The chief causes are pressure, or the close approximation of the septum to the middle turbinal, the resultant retention of the secretions, and the inflammation of the obstructed sinuses. The septum does not, in all cases, impinge upon the middle turbinal, and is not, therefore, a constant etiological factor in producing the hyperplasia. The sinuses may be diseased independently of the septal deviation, and may thus be the primary cause of the hyperplasia. In either event the irritation resulting from the secretions constantly flowing over the mucous membrane of the middle and inferior turbinals causes the morbid changes in these structures. The secretion is not necessarily purulent, but, on the contrary, is often serous or mucous in character; that is, the inflammation in the sinuses may not be suppurative, but may be catarrhal in character.

Symptoms.—The symptoms of hyperplastic rhinitis are often complex, as the disease is often associated with a catarrhal or a suppurative

inflammation of the ethmoidal, sphenoidal, and possibly the frontal sinuses.

The symptoms arising from the hyperplasia are those of nasal obstruction, especially in the region of the middle turbinal; that is, there is more or less nasal obstruction and a sense of stuffiness or of pressure in this portion of the nose. The handkerchief is frequently used in an effort to dislodge the secretions and to overcome the sense of stuffiness. While the secretions may be thus removed, the stuffy feeling remains, as it is due to the contact of the turbinate with the septum.

The secretions may be either serous or mucopurulent, depending largely upon the complicating disease of the sinuses.

Anterior rhinoscopy shows the inferior turbinal to be enlarged, paler than normal, although it may be red and boggy, and somewhat nodular in outline. If the septum is deviated, and it usually is, a ridge corresponding to the crista nasalis and the crest of the vomer may be present on one side, while there is a bowing of the septum toward the opposite side in the region of the middle turbinal. The septum is also often thickened in its upper portion on both sides, thereby obstructing both olfactory fissures.

If an empyema of the ethmoidal cells (cellulæ ethmoidales) is present, pus may be seen in the olfactory fissure as well as in the lower portion of the nose. If there is catarrhal ethmoiditis the anterior end of the middle turbinal may be red and boggy in texture. Patients with this type of ethmoidal inflammation sometimes complain of soreness or of fissures in the skin at the margin of the vestibule.

The subjective symptoms are due to obstructive lesions and to the disease in the accessory sinuses of the nose.

The obstruction in the upper part of the nose gives rise to a sense of stuffiness and of pressure across the bridge of the nose. These symptoms are rather constant, as the tissue enlargement is permanent.

The obstructive lesion in the upper portion of the nose gives rise to the additional symptoms of headache and vertigo peculiar to sinus inflammation; that is, there is headache in the frontal region limited to, or more pronounced on, one side, and to a feeling of soreness or tenderness of the eyeball upon ocular movements. The stooping posture increases the headache, and temporary vertigo is often thereby produced. The headache is also sometimes referred to the temporal, vertexial, and occipital regions.

The symptoms given in the above paragraph are due to the sinuitis, and are not always present in hyperplastic rhinitis. They are, however, often present, as a careful examination of the patients will show.

Prognosis.—The prognosis of hyperplastic rhinitis is not as favorable as that of hypertrophic rhinitis. The etiology is more complex and the disease more serious, and it entails more extensive surgical procedures for its eradication. If the diseased processes are allowed to run their natural course, they may eventuate in an atrophy of the mucous membrane, especially of the middle and inferior turbinated bodies, though there is but slight tendency to atrophy in hypertrophic rhinitis.

If the treatment is instituted sufficiently early, the atrophic process may be checked and the stenosis and sinus disease eradicated.

Treatment.—The treatment of hyperplastic rhinitis should have two grand objects, namely: (*a*) The removal of the obstructive lesion,

Fig. 108

Casselberry's plain scissors.

whether it be a deviation of the septum or the hypertrophic tissue of the middle or inferior nasal conchæ (middle or inferior turbinals); and (*b*) the cure of the catarrhal sinuitis, if present, whether it be in the ethmoidal and sphenoidal, or the frontal and maxillary sinuses.

Fig. 109

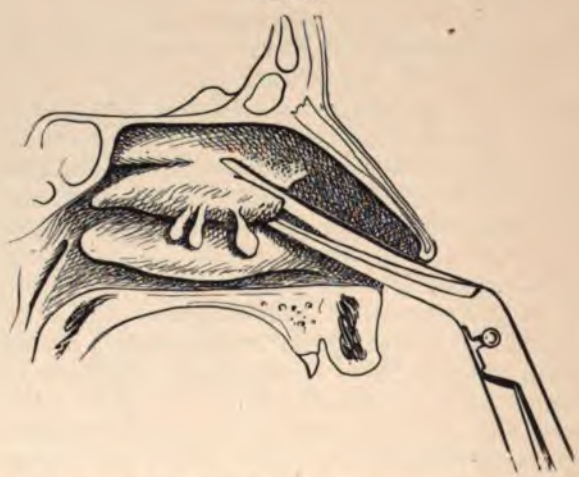

The removal of the anterior end of the middle turbinated body with Casselberry's scissors.

Hyperplasia of the inferior nasal concha (inferior turbinal) may be removed by any one of the operative procedures described under hypertrophic rhinitis.

Hyperplasia of the middle nasal concha (middle turbinal) may be removed with the scissors and snare, the author's turbinal knife (Figs. 100, 173 and 174), or with the swivel knife.

FIG. 110

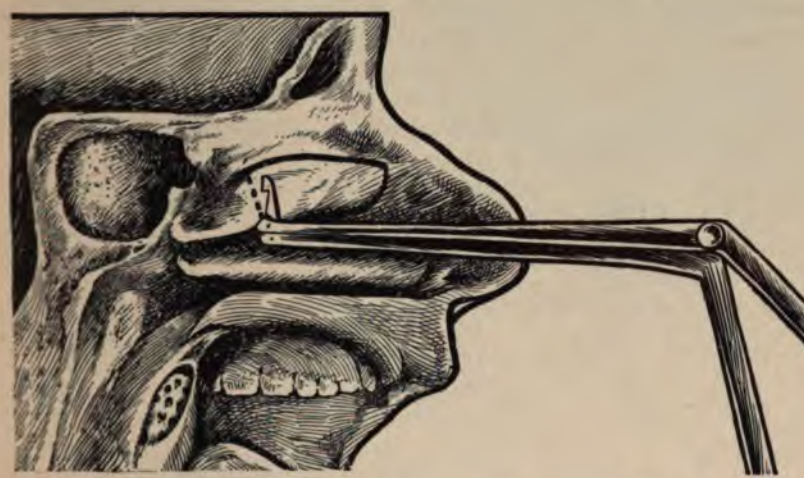

Grünwald's right-angle forceps may be used to complete the removal of the turbinate instead of a snare.

FIG. 111

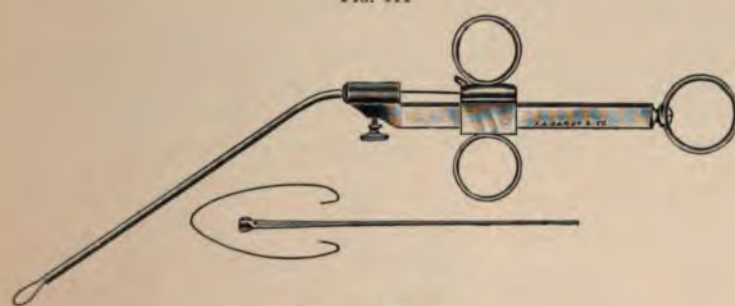

Krause's nasal snare.

FIG. 112

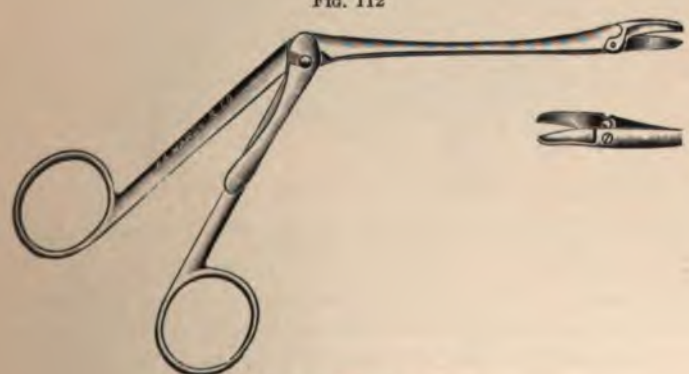

Holmes' middle turbinal scissors.

The Scissors and Snare.—The technique is as follows:

(*a*) Induce local anesthesia with a 10 per cent. solution of cocaine. A weaker solution is often inadequate in hyperplastic tissue.

(*b*) Grasp the anterior attachment of the middle nasal concha (middle turbinal) with the scissors (Fig. 108) and make an incision about one inch in length thus severing the attachment of the anterior one-third or one-half of the middle turbinated body (Fig. 109).

Fig. 113

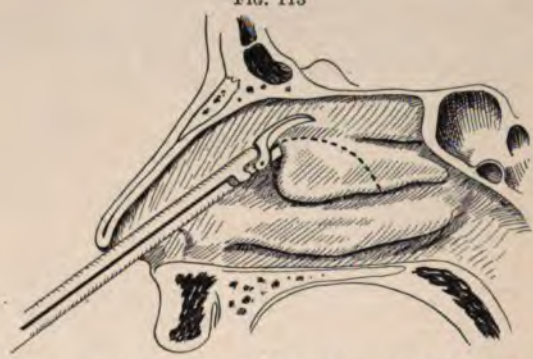

The removal of the anterior half of the middle turbinated body with Holmes' scissors.

(*c*) Introduce a cold wire loop over the detached portion of the turbinal and cut it off at the posterior limit of the incision, or sever the detached portion of the turbinal with Grünwald's forceps (Fig. 110). Still more tissue may be removed if necessary.

Fig. 114

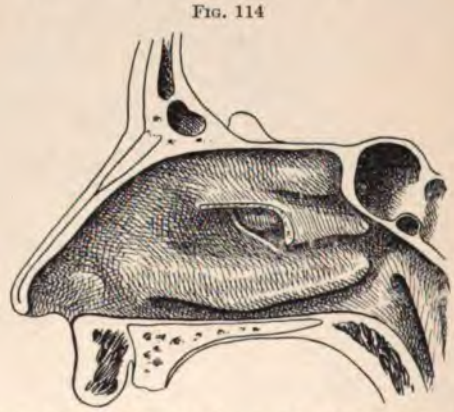

The anterior half of the middle turbinal removed with Holmes' scissors, exposing the bulla ethmoidalis.

Holmes' Scissors.—With Holmes' scissors (Fig. 112) the snare is not necessary, as the blades are so curved that the cut made with them extends backward and downward until it emerges from the tissue (Figs. 113 and 114).

The Swivel Knife.—The technique of the removal of the middle turbinal with the swivel knife differs from that employed with the same instrument in the removal of the inferior turbinal.

Fig. 115

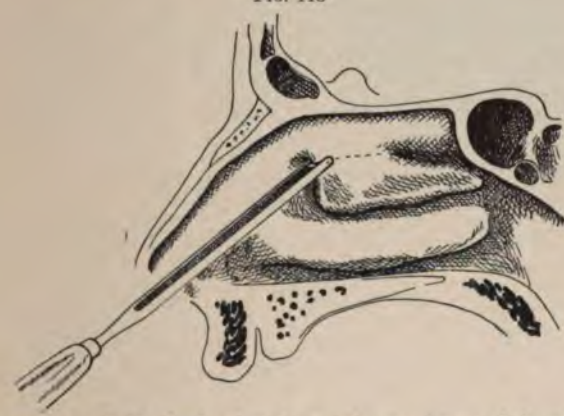

The author's narrow swivel knife placed at the anterior attachment of the middle turbinal preparatory to removing it as shown in Fig. 116.

The technique is as follows: (*a*) Induce local anesthesia with a 10 per cent. solution of cocaine applied on a thin pledget of cotton over the whole of the middle turbinal. It may be necessary to apply a 20 to 30 per cent. solution with a delicate cotton-wound applicator to the less accessible areas.

Fig. 116

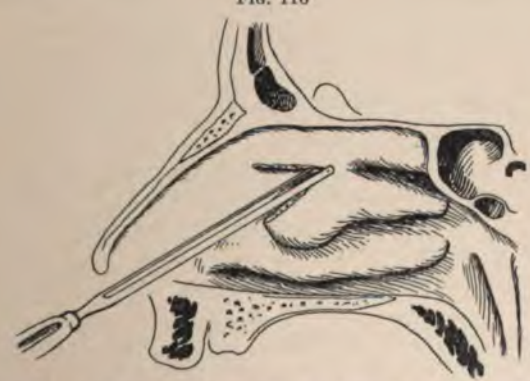

The removal of the middle turbinal with the author's narrow swivel knife.

(*b*) Introduce the swivel knife and engage the anterior attachment of the middle turbinal (Figs. 115 and 116), so that one prong tip is above and the other below the attachment.

(*c*) Carry the swivel blade backward with short strokes until the whole or a part of the middle turbinal is severed from its attachment. The severed middle turbinal does not pass between the prongs of the instru-

ment, but is pushed downward beneath them. If only a portion of the middle turbinal is to be removed, the swivel blade is directed downward through the turbinal at the desired point, or, failing in this, the swivel knife is removed and the loop of a snare is engaged over the detached fragment and the removal completed.

Remarks.—The swivel knife is not of universal use for turbinectomy or turbinotomy, although in many cases it is an ideal instrument for these purposes. In each case the instruments and mode of operation should be selected with reference to the conditions present rather than to blindly follow any described method of operating.

(*d*) The postoperative treatment should consist of the insufflation of an antiseptic powder, and, in the case of severe persistent hemorrhage, the nose should be packed with iodoform, or compound tincture of benzoin gauze.

Hemorrhage.—The middle turbinal is supplied with blood by the anterior and posterior ethmoidal arteries (A. ethmoidalis anterior et posterior) (Fig. 3), and hemorrhage of considerable severity may occur either at the time of operation or at a later period. As a matter of fact an oozing of blood continues in many cases for twenty-four hours.

The danger of septicemia and of meningitis is increased by nasal tampons, hence it is not advisable to pack the nose except in extreme necessity. The packing should be done firmly but with caution, and the gauze should be moistened with the compound tincture of benzoin and squeezed until the excess of fluid is removed.

CHRONIC RHINITIS WITH COLLAPSE OF THE ERECTILE TISSUE.

Definition.—This is not a true inflammatory disease, but is usually classed as such. It is a local manifestation of a general anemia, and is characterized by the collapse of the erectile tissue of the nose and simulates atrophy in this region.

Etiology.—Its chief cause is general anemia. Atrophic rhinitis is also characterized by anemia that is secondary to the conditions causing the atrophy. In simple collapse of the swell bodies the anemia is primary and the collapse secondary. It is most often found in women, as they are more subject to anemia. It is occasionally found in gouty individuals.

Symptoms.—The chief symptoms are dryness of the upper respiratory tract and patency of the nose. Upon anterior rhinoscopic examination the inferior turbinals appear quite small, on account of the collapse of the swell bodies. Upon probe pressure the mucous membrane is found to be thin and tightly drawn over the underlying bone. The great space in the nasal chambers and the small size of the inferior turbinals at once suggest an atrophic condition, though true atrophy is absent; crusts and ozena are, however, absent, nor is there a history of their previous presence. An examination of the blood shows anemia to be present. The sense of smell is unimpaired and ulceration of the mucosa and caries

of the bone are absent. The condition is always bilateral, as it is due to constitutional rather than local causes.

Treatment.—The treatment should be directed to the anemia. It is necessary, therefore, to ascertain the type of the anemia by blood examinations and to carry out the treatment accordingly. I wish to suggest in this connection that an examination of the rectum will sometimes reveal ulcerations or other pathological processes that may be the cause of the anemia and the resultant collapse of the erectile tissue.

ATROPHIC RHINITIS.

Synonyms.—Chronic dry rhinitis; simple mucous rhinitis; mucopurulent rhinitis; ozena.

Definition.—Atrophic rhinitis is characterized by a sclerotic change in the mucous membrane and occasionally of the underlying bone, and by the presence of crusts and an offensive nasal breath. The conditions giving rise to these phenomena are varied and often complex.

Etiology.—The three causes generally held to produce this condition are as follows:

(*a*) A simple atrophic process which is not dependent upon other local disease of the mucous membrane. Meissner holds that atrophic ozena (see below) is due to a primitive or broad, shallow nose, and to a congenital development of pavement epithelium instead of the columnar or mucus-producing variety.

(*b*) Pressure necrosis due to excessive distention of the bloodvessels. This is a *cyanotic congestion* due to a heart lesion, the general venous circulatory system participating in the sluggish venous flow. The mucosa covering the vessels is kept upon a constant stretch, and pressure atrophy results, as in red atrophy of the liver.

(*c*) Sclerotic atrophy due to a pre-existing sinus inflammation, during which there is an excessive proliferation of connective-tissue cells. These after a time become fibrous tissue and gradually cut off the blood supply and choke out the glandular and vascular structures of the membrane. The nutrition of the mucous membrane is diminished, and functional activity is diminished or destroyed.

These and various other theories are held as to the cause, or causes, of atrophic rhinitis. None of them is definitely proved, although the one advocated recently by Grünwald, and by Vieussens, Reininger, and Guns at the end of the seventeenth century, has rapidly gained ground in popular opinion. Those who hold to this theory believe that all or nearly all cases of atrophic rhinitis are due to suppuration of the accessory sinuses of the nose, more especially the ethmoidal and sphenoidal. My own experience is in accord with this view. I have seen many cases cured or greatly relieved by attention to the accessory sinuses. The ozena is invariably influenced favorably. In conjunction with Dr. Joseph Beck I have had skiagraphs of the sinuses made in cases of atrophic rhinitis, and without exception the sinuses appear cloudy, as

they do in sinuitis, *i. e.*, their outline is illy defined and the area of the cavities is opaque. This shows that in atrophic rhinitis the sinuses are often diseased, though it does not prove the sinus disease to be primary.

(*a*) **Simple Atrophic Rhinitis.**—Simple atrophy may take place in the nasal mucous membrane as well as in mucous membranes elsewhere in the body.

Etiology.—The etiology is not clear, and yet it is probable that it is due to the presence of some irritant in the blood, as in syphilis, tuberculosis, scrofula, etc. At any rate, the trophic nervous system is involved and nutrition modified.

Treatment.—The treatment should be addressed to the constitutional dyscrasias, upon the disappearance of which the atrophic and ozenic processes improve or disappear.

(*b*) **Atrophic Rhinitis Due to Pressure (Cyanotic Engorgement).**—*Etiology.*—(*a*) There is some lesion of the heart, kidneys, liver, or lungs which causes a damming back of the venous blood upon the nasal mucous membrane, as well as elsewhere in the body. (*b*) The organs thus affected do not eliminate the waste products as rapidly as they should, and they are retained in the blood, where they act as irritants, exciting inflammatory reaction of a low grade. These two factors account for the phenomena known as pressure atrophy as it occurs in the nasal mucosa.

Symptoms.—Although there is true atrophy, the membrane is congested to such a degree that there is nasal stenosis. The mucosa of the nose is boggy, purplish red in color, and inflamed. The ozenic odor may be slight. There is an exudation from the engorged vessels, but it is not a true mucous secretion. The skin of the nose may be red. There is a sense of fulness across the bridge of the nose, and frontal headache is commonly present. The conjunctiva may be infected and attended by an overflow of tears.

D. Braden Kyle refers to a case due to organic mitral lesion. I have seen a case of this character in which the whole mucosa of the upper respiratory tract was cyanotic; the tonsils were enlarged and markedly blue from cyanotic congestion.

Prognosis.—This depends upon the curability of the lesion giving rise to the cyanotic congestion. The patient had a valvular heart lesion.

It is obvious that the treatment in such cases must be palliative only.

(*c*) **Atrophic Rhinitis Due to Suppurative Sinuitis.**—*Etiology.*—All the causes given under the various types of catarrhal rhinitis may act as causes of this type of disease. The inflammation attending them is followed by a deposit of connective-tissue cells, which after they become organized cut off the blood supply and choke down the glandular tissue. The functional activity is gradually lost and the true mucous elements of the membrane finally disappear. The secretions become thick and inspissated. They dry upon the surface of the membrane, where, through biochemical changes, they develop the ozenic odor. Various theories have been advanced in explanation of the odor, but none of them is proved.

The following are suggestive but not conclusive:

(*a*) Simple decomposition of the mucopus.

(*b*) Degenerative changes in which certain fatty acids are liberated, giving rise to the odor.

(*c*) The presence of certain bacteria, as the bacillus fetidus.

Ozena a Symptom.—Ozena is not a disease, but a sign of certain diseased conditions. It is a "stench," and it is in this sense that it is used. The fetid odor is associated with an inspissated secretion, which is seen in the form of greenish crusts covering the whole of the nasal mucous membrane. There may be other peculiar conditions associated with it, especially in those cases in which there is marked atrophy of the mucosa. For example, the nose may be broad and flat, the tip somewhat elevated, and the blood anemic. The anemia is secondary and not primary as in chronic rhinitis with collapse of the erectile tissue. The absorption of septic material and the loss of the respiratory functions of the nose are probably the chief causes of the anemia. It is a well-recognized fact that in mouth breathing due to the presence of postnasal adenoids there is anemia, which quickly disappears after their removal.

The mucous membrane becomes atrophied in the later stages, and after a longer period the secretion and foul odor spontaneously disappear and leave a comparatively clean but sclerotic membrane. The ozenic odor disappears spontaneously after a number of years, hence it is a self-limited symptom. The mucous membrane, however, is left very much damaged. Its histological character and physiological function are changed or entirely lost.

The sclerosis and ozena in this type of atrophic rhinitis is in all probability due to a chronic sinuitis, or to other focalized suppurative processes, as has been shown by Grünwald in his work on *Nasal Suppuration.* In other words, the atrophy is not primary, but is secondary to a suppurative sinus inflammation. Indeed, nearly all cases of atrophic rhinitis probably fall under this category. This subdivision of atrophic rhinitis is, therefore, from a clinical standpoint of the greatest importance.

The *rationale* of the atrophic process is generally as follows:

The secretion from the sinuses, more particularly the frontal, ethmoidal, and sphenoidal, flows downward over the nasal membrane, where it becomes dried into crusts. It undergoes decomposition and irritates the underlying mucosa. There is, in addition, a mechanical irritation from the shrinkage and contact of the crusts with the mucous membrane. The chemical and mechanical irritation thus produced cause a proliferation of connective-tissue cells, which, when fully organized, contract and choke out the true elements of the mucous membrane. Shrinkage and atrophy progress until the mucous membrane is replaced by a sclerotic one, devoid of mucous glands and columnar ciliated epithelium, pavement epithelium replacing the columnar type.

During the progress of the atrophic process the ozena is a symptom, but after the true mucous membrane is destroyed the mucous secretion and ozena cease. Crust formation and ozena are self-limited phenomena, many years being required, however, to rid the patient of them.

Symptoms.—The symptoms vary with the state of advancement and activity of the process. The clinical picture presents the features shown in the comparative table given below. This is adapted from MacDonald's work on *Diseases of the Nose.*

COMPARATIVE TABLE OF THE SYMPTOMS OF ATROPHIC RHINITIS AND RHINITIS WITH COLLAPSE.

Chronic Rhinitis with Collapse of the Erectile Tissue.	*Atrophic Rhinitis with Sclerosis and Mucous Secretion. Ozena.*
1. Chiefly in anemic women. The anemia is primary.	1. Chiefly in women and children; all subjects become anemic.
2. No peculiarity of physiognomy.	2. Small, sunken wide nose with wide nasa fossæ.
3. Mucous membrane anemic.	3. Mucous membrane anemic.
4. Collapse of erectile tissue; no tendency to atrophy.	4. Collapse of the erectile tissue with tendency to atrophy.
5. No ulceration.	5. Sometimes there is ulceration, and necrotic bone if the disease is of sinus origin.
6. Always bilateral.	6. Usually bilateral; may be unilateral.
7. Spontaneous cure if the anemia is relieved.	7. After some years there is a tendency to improvement of the symptoms. The ozenic symptoms disappear as the atrophy becomes more complete.
8. Olfaction not affected.	8. Olfaction is often lost.
9. No characteristic odor.	9. Breath typically ozenic.
10. Little or no incrustation; if present, is limited to the anterior third of the middle turbinals.	10. Crusts are distributed over the entire mucous membrane.

Treatment.—When seen in the early stage the treatment should aim at (*a*) the removal of the causes of the inflammation that produces the sclerotic process, and (*b*) intranasal cleanliness.

(*a*) **The Removal of the Causes.**—The causes of the inflammation are numerous. Some have already been considered under acute catarrhal hyperplastic rhinitis, chronic suppurative sinuitis, and the congenital primitive nose with its pavement epithelium. Other causes are traumatism, deflections, and other obstructive lesions of the septum. By the removal of these exciting causes of the inflammation the sclerotic process may be modified or stopped altogether.

From the foregoing statements concerning focal suppuration within the sinuses and elsewhere in the nasal chambers, it is evident that in many cases the treatment should be addressed toward the cure of the suppuration of the sinuses, rather than to the atrophy resulting from it.

(*b*) **Intranasal Cleanliness.**—Intranasal cleanliness is obtained by the use of antiseptic douches containing a liberal amount of mild alkalies to soften and dissolve the crusts and tenacious mucopus. A solution of 8 grains of sodium bicarbonate to the ounce of water as hot as can be borne should be forcibly injected into the nostrils at frequent intervals during the day. A fountain syringe is well adapted for this purpose. The patient should be instructed to clear the nose by blowing after each injection. The injections may be administered by the physician at first, as the patient will not or cannot thoroughly cleanse his nose. To free the nostrils from crusts and tenacious mucus, a warm antiseptic aqueous solution of borax, sodium bicarbonate, oil of eucalyptus, carbolic

acid, glycerin, and alcohol should be injected into the nostrils. A two-ounce hard-rubber or an Alpha and Omega bulb syringe is well adapted for this purpose, as considerable force is necessary to dislodge the crusts.

Personally, I prefer to pack the nose with cotton-wool saturated with a 10 per cent. aqueous or glycerin solution of ichthyol, which should be removed in from twenty to thirty minutes, the crusts being softened and easily detached by blowing the nose or by the use of a cotton-wound probe. This course of treatment, if faithfully carried out, will afford great relief. Mild astringent stimulating solutions, or powders, are of value in reducing the local infection. Powder with 5 to 20 per cent. of silver nitrate or a 1 to 2000 trichloracetic acid solution may be used for this purpose. The associated sinus diseases should be treated as described under the Accessory Sinuses. Indeed, this is often the only method of treatment attended with success. Even this fails if the atrophy is far advanced.

Paraffin Injections in Atrophic Rhinitis.—Paraffin injections beneath the mucous membrane of the inferior turbinated body and of the septum have been used by several rhinologists with great improvement of the symptoms. The crusts are either diminished or disappear altogether. Most writers recommend using paraffin in melted form, although the danger of thrombosis is ever present. More recently paraffin has been used in semisolid form to obviate this danger. A special syringe (Fig. 196), adapted to the use of semisolid paraffin, has been devised by Dr. J. C. Beck for this purpose. With this device the danger of thrombosis is reduced to the minimum.

The injections should be made under local cocaine anesthesia. The amount injected at each sitting varies with the friability of the mucous membrane. In some cases only one or two minims or grains should be injected, as to exceed this amount would tear the mucous membrane. In other cases as much as one to two drams may be injected. The injections should be made at intervals of from five to ten days, enough time being allowed between the sittings for the subsidence of the reaction.

Either the inferior turbinal (nasal concha) or the septum may be chosen for the site of the injections. The needle should be introduced a half-inch or more beneath the mucoperiosteum, and a small amount of paraffin injected. It should then be withdrawn, a quarter of an inch and more of paraffin injected, and so on until the needle is withdrawn.

The effects produced are a lessening or the disappearance of the crusts, a thinning of the secretions, a sense of air passing through the nasal chambers, and occasionally edema of the eyelids. The good effects have remained for a period of two years and promise to last much longer. The lumen of the nasal chambers is diminished, thus accounting in a measure for the lessened desiccation of the secretions. It is also quite probable that the irritation of the paraffin, a foreign body in the tissues, produces an increased hyperemia and leukocytosis. Whatever the explanation may be, it appears that paraffin injections beneath the mucoperichondrium of the nasal septum and beneath the mucoperiosteum of the inferior turbinal materially improves the symptoms in the so-called atrophic rhinitis with incrustations. In those cases wherein the sinus

origin of the suppuration and crusts is in doubt, and wherein the patient refuses operative interference on the sinuses when they are known to be the focal centre of the disease, paraffin injections may be used with the reasonable assurance of an improvement of the symptoms.

SUPPURATIVE RHINITIS; NASAL SUPPURATION.

(A symptom, not a primary disease.)

Suppurative rhinitis has been described by various authors, notably by Bosworth in his work on the *Diseases of the Nose and Throat.* He described suppurative rhinitis in children as a primary disease, which, when neglected, eventuates in atrophic rhinitis in adults. The trend of opinion is gradually breaking away from the view that primary suppuration of the nasal mucous membrane is often found. On the contrary, it is believed that it rarely exists except secondarily to sinuitis. Personally, I hold the latter view.

Pus in the nasal chambers is present in the later stages of acute coryza, which is an infectious disease and is usually complicated by a purulent infection of the sinuses. Purulent secretions may also accompany syphilitic, tuberculous, and gonorrheal processes in the nose. The specific or exanthematous fevers are characterized by a purulent inflammation of the nasal and accessory sinus membranes. The various accessory sinuses, when affected by a purulent inflammatory process, discharge their purulent secretions into the nasal passages. Generally speaking, if after the nasal chambers are cleared of pus by mopping with a cotton-wound applicator the pus reappears within a few minutes in the middle meatus, it comes from the sinuses discharging into this meatus, namely, the frontal, anterior ethmoidal (including the bulla ethmoidalis), and the sinus maxillaris (antrum of Highmore). Occasionally one of the anterior ethmoidal cells discharges through the inner or median wall of the middle turbinal into the olfactory fissure or superior meatus. When the pus appears in the superior meatus, it is probably from the sinuses opening into the meatus, namely, the posterior ethmoidal and the sphenoidal sinuses. An occasional exception to this is when the sinus maxillaris (antrum of Highmore), whose posterior and superior median wall is in relation to the superior meatus, discharges through a perforation into the superior meatus. Such a condition is rare, hence pus in this meatus as seen in the olfactory fissure is generally indicative of suppuration of the posterior ethmoidal and the sphenoidal sinuses. It is barely possible that there may be a focalized ulceration of the nasal mucous membrane in the superior meatus, and that the pus is from the meatus rather than the sinuses. It appears, therefore, that nasal suppuration is rarely, if ever, a primary disease, but that it is always, or nearly always, secondary to some other disease of the mucous membrane and bony walls of the nasal chambers or the accessory sinuses of the nose. Suppuration of the nose as a primary disease will not, therefore, be described, but the other diseases to which it is secondary are described, and the reader is referred to them for further information.

PLATE I

Anterior Reconstruction. On account of the multiplicity of lines, the individual ethmoidal cells are not shown; however, the two groups are represented, the anterior being lined horizontally and the posterior perpendicularly. The left sphenoidal sinus lies far above the right; its inner wall extends almost as far to the right as the outer wall of the right sphenoidal sinus. (H. W. Loeb.)

PLATE II

Left Lateral Reconstruction. In this and Plate I the frontal sinus is colored yellow, the maxillary purple, the sphenoid green, and the ethmoid red, the anterior group being lined horizontally and the posterior group perpendicularly. The ethmoidal cells are to be noted in two groups, the anterior two in number, and the posterior three. The first anterior cell is shown displacing the anterior wall of the frontal. The frontal is seen opening into the frontonasal canal. The antero-inferior wall of the second ethmoid constitutes the bulla ethmoidalis. (H. W. Loeb.)

CHAPTER IX.

THE INDIVIDUAL SINUSES.

THE sinuses are divided for clinical purposes into two groups, namely, the anterior and the posterior sinuses. The anterior group is composed of the frontal, the anterior ethmoidal, and the maxillary sinuses. Hajek calls this group Series I. The posterior group is composed of the posterior ethmoidal and the sphenoidal sinuses, and is called Series II (Fig. 117).

Our knowledge of the etiology, symptomatology, pathology, and surgical treatment of the sinuses has increased so greatly during the last ten years that it seems to be proper to depart from the traditional manner of presenting this subject, wherein each sinus is separately described and treated. As a matter of fact, a single sinus is rarely diseased, two or more being commonly affected at the same time. Indeed, it is not uncommon to find all the sinuses on one side of the head affected. The maxillary sinus is perhaps more often affected singly than either of the other sinuses. This is accounted for by the fact that in about one-half of the cases it is infected from the teeth rather than from the nose, whereas the other sinuses are nearly always infected from the nose. Having a common source of infection, they are, therefore, more often simultaneously diseased.

For this reason a general discussion of sinus inflammations is to be preferred to a discussion of each sinus individually. Nevertheless, it will be advantageous to present the peculiar symptoms and other considerations of each sinus separately. The following considerations are therefore to be read in conjunction with the general description which follows.

SERIES I.

The Frontal Sinus.—The frontal sinus is an extension upward of the ethmoidal cells between the plates of the frontal bone. The extension occurs at about the age of puberty, hence in infants and young children the frontal sinuses are absent. The size and shape of the frontal sinuses vary greatly in different individuals, and indeed the two sinuses often vary greatly in the same individual. Reference to Plates I, II, III, IV and V show some of the variations in the frontal sinuses, the drawings being taken from skiagraphs of some of the author's cases. These variations are of surgical interest, as the difference in size will often determine the method of operating. If there is a large and deep frontal sinus, great external deformity may follow the complete removal of the anterior wall.

In such a subject the operation may be so executed as to avoid, or to greatly reduce, the probability of marked disfigurement.

H. W. Loeb's projections of the sinuses (Plate I and II) show more clearly than any other work the relations of the sinuses to one another

Fig. 117

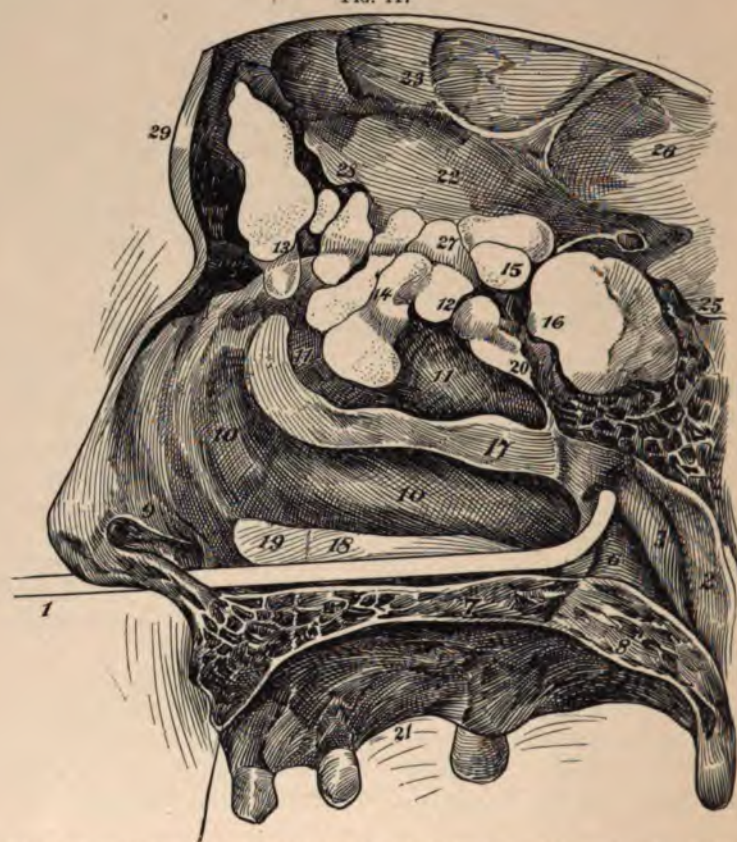

The anterior portion of the right side of the skull has been rendered transparent. A catheter is passed into the Eustachian tube. 1, catheter; 2, Rosenmüller's fossa (recessus pharyngeus); 3, tubal fold (torus tubarius) and plica salpingopharyngea; 4, pharyngeal opening of Eustachian tube; 5, plica salpingopalatina; 6, levator palati muscle; 7, hard palate; 8, soft palate and uvula; 9, external nose and naris; 10, inferior turbinate; 11, middle turbinate; 12, superior turbinate; 13, frontal sinus; 14, ethmoidal cells in middle nasal meatus—two ethmoidal cells appear, one above the other, extending to the middle turbinate; 15, ethmoid cells in superior nasal meatus; 16, sphenoidal sinus; 17, antrum of Highmore, seen through the interior of the nose in the middle meatus; 18, same in the inferior meatus; 19, mouth and lacrymonasal duct; 20, superior meatus; 21, alveolar process with three teeth—the roots are faintly seen within the alveolar process; 22, roof of orbit seen in anterior fossa of skull; 23, juga cerebralia and impressiones digitatæ; 24, lesser wings of the sphenoid with anterior clinoid processes and optic foramen; 25, sella turcica; 26, middle fossa of skull; 27, lamina cribosa; 28, crista galli; 29, frontal bone. (After Bruhl-Politzer.)

and to the structures of the nose. The anteroposterior and lateral projections are shown. Plates III, IV, V and VI also give a good idea of the distribution of the sinuses.

PLATE III

Fig. 1

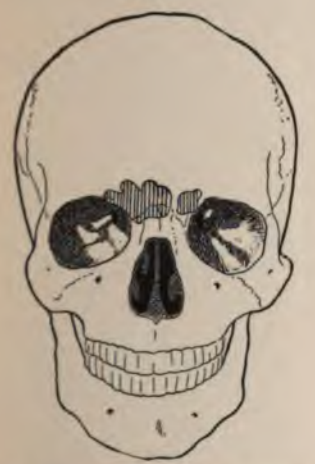

Large right frontal and a small left frontal sinus. (From author's skiagraph.)

Fig. 2

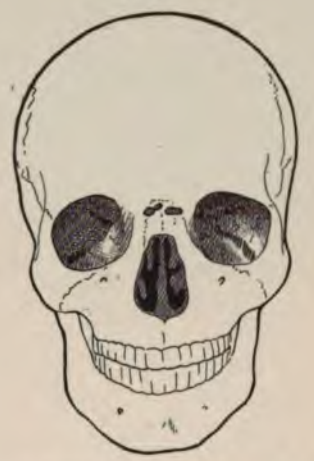

Absence of the frontal sinuses in a patient aged twenty-nine years. Small anterior ethmoidal cells are shown. This patient had extensive necrosis of the ethmoidal and sphenoidal bones, and secondary mastoiditis complicated by a brain abscess in the motor area for the arm and leg. The arm and leg on the opposite side were partly paralyzed. The ethmoidal and sphenoidal sinuses, mastoid and brain abscess were successively operated upon without result. (Author's case.)

Fig. 3

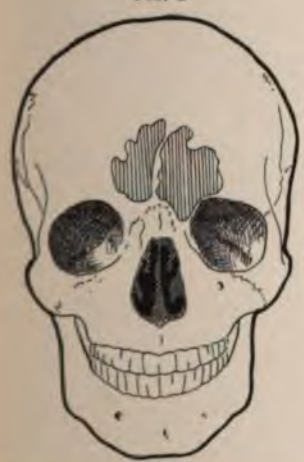

Very large frontal sinuses. (From author's skiagraph.)

Fig. 4

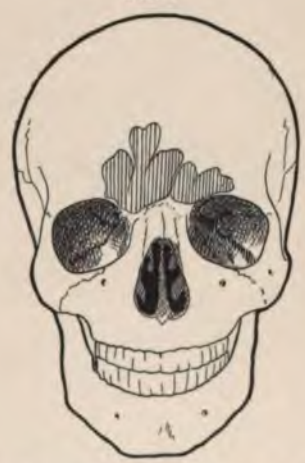

Very large irregular right frontal and a small left frontal sinus. (From author's skiagraph.)

The Distribution of the Frontal Sinuses as Shown by Skiagraphy.

PLATE IV

Fig. 1

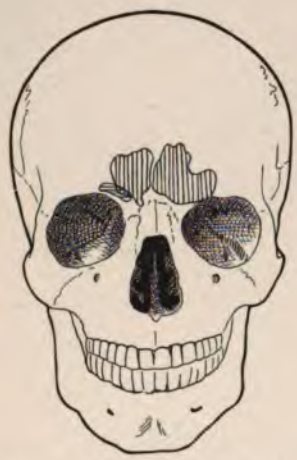

Large frontal sinuses and an anterior ethmoidal cell extending well over the right orbit. (From author's skiagraph.)

Fig. 2

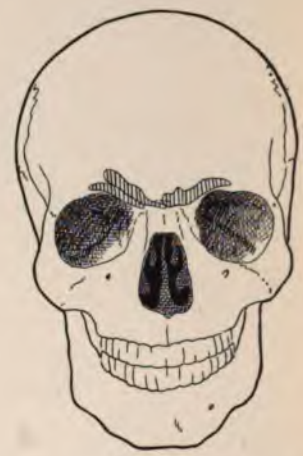

Narrow longitudinal frontal sinuses, the right having an ethmoidal cell encroaching upon its floor. (From author's skiagraph.)

Fig. 3

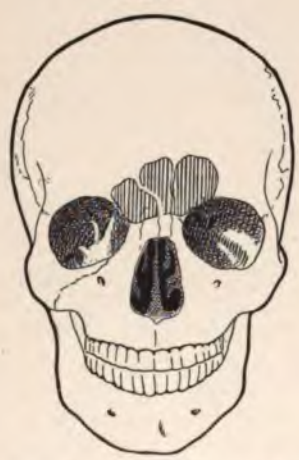

Very large left frontal sinus, almost divided by a septum. The left sinus extends about one-half inch beyond the median line. (From author's skiagraph.)

Fig. 4

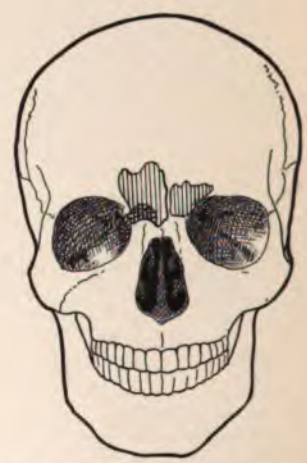

Large right frontal sinus with an anterior ethmoidal cell (bulla frontalis) encroaching upon its floor. (From author's skiagraph.)

The Distribution of the Frontal Sinuses as Shown by Skiagraphy.

PLATE V

Fig. 1

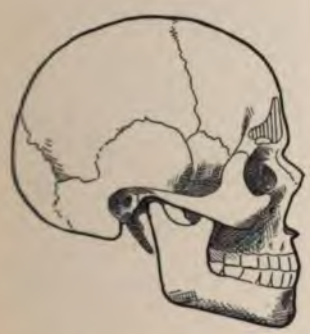

Side view of frontal sinus with great depth and upward extension. A small anterior ethmoidal cell, the bulla frontalis (see Fig. 117), encroaches upon its floor. (From author's skiagraph.)

Fig. 2

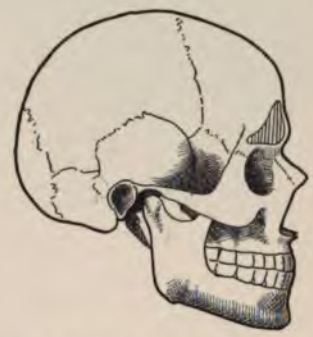

Another large frontal sinus with marked backward extension over the orbit. (From author's skiagraph.)

Fig 3

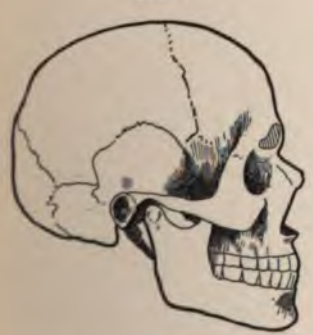

Side view of the frontal sinus with limited upward extension and moderate backward extension. (From author's skiagraph.)

Fig. 4

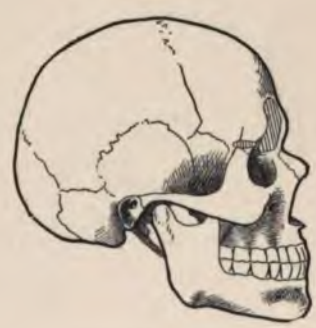

An unusual downward extension of the frontal sinus. (From author's skiagraph.)

The Anteroposterior Extension of the Frontal Sinuses as Shown by Skiagraphy.

PLATE VI

Fig. 1

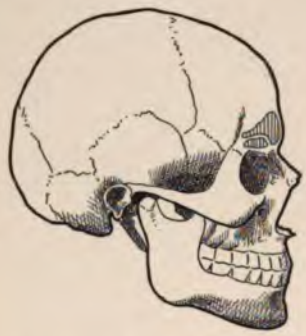

Frontal sinus with extreme extension backward, and with a large anterior ethmoidal cell encroaching upon the posterior portion of its floor. (From author's skiagraph.)

Fig. 2

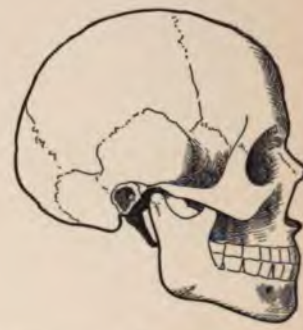

Side view showing absence of the frontal sinu in a patient aged twenty-nine years. Anter view shown in Plate III, Fig. 2. (From autho skiagraph.)

Fig. 3

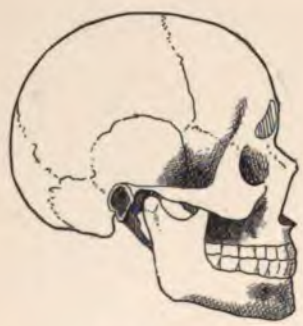

Side view showing a frontal sinus of moderate depth. (From author's skiagraph.)

Fig. 4

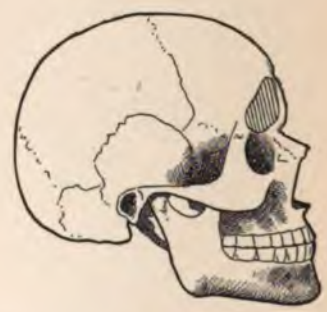

An extremely large and deep frontal sinus. (From author's skiagraph.)

The Anteroposterior Extension of the Frontal Sinuses as Shown by Skiagraphy.

Skiagraphy.—The skiagraphic plate affords good information concerning the presence or absence of disease in all of the sinuses except the sphenoidal if the exposure is properly made. It is not yet known what causes the cloudy appearance when the sinus is diseased. Coakley says it is not known whether it is due to the thickness of the inflamed membrane, to the presence of pus, or to the changed condition of the bone. I have a skiagraph of a patient affected with a severe chronic catarrhal sinuitis upon whom I performed a double Killian operation, in which the right frontal sinus as shown by the plate was cloudy, but less so than the left. Upon operating the right sinus was found to be free of pus, and its periosteum and mucous membrane were entirely gone. The bone was chalkv white and slightly roughened. The left sinus was free of pus, but was filled with granulation tissue and viscid mucous secretion. The patient had complained for several months of an acrid secretion which irritated the nasal mucosa. This case is related in this connection, as it is unique, and demonstrates that a frontal sinus devoid of membrane periosteum, and purulent secretion gave a cloudy effect in the skiagraph, though not so pronounced as that given by the sinus in which the membrane and granulations were present. Pus was not present in either sinus.

Fig. 118

The correct method of making pressure under the floor of the frontal sinus. Pressure is often made under the supra-orbital ridge, whereas it should be made much deeper.

Tenderness upon Pressure.—Tenderness over the frontal bone is rarely present in frontal sinuitis except in very acute cases with obstructed drainage. Tenderness is often present, however, when pressure is made against the floor of the affected sinus near the inner angle of the orbital cavity (Fig. 118). The finger tip should be placed well under the roof of the orbit and the pressure directed upward. Pain is thus often elicited even in chronic catarrhal cases. Tenderness in this region does not, however, always indicate frontal sinus disease, as the anterior ethmoidal cells sometimes project beneath the floor of the sinus (Fig. 143).

When such an anatomical deviation is present the surgeon may be led to a wrong conclusion. This difficulty may be obviated by having a skiagraph made, as it will aid in determining the position and condition of the frontal and anterior ethmoidal cells.

The tenderness present in frontal sinuitis is so nearly in the same position as that in ethmoidal sinuitis that a careful distinction should be made. In ethmoidal sinuitis the tenderness is usually located a little above the median palpebral commissure (inner canthus) of the eye and a little deeper in the orbital cavity than the canthus. The pressure should be made inward toward the median line, rather than upward, as in testing the frontal sinus.

Redness and Swelling.—Redness and swelling over the frontal region are only present in severe acute inflammation of the frontal sinus where the bone is affected by an infective osteomyelitis and the skin has yielded to the inflammatory process. There are perhaps a hundred cases of frontal sinuitis in which the redness and swelling are absent to one in which they are present. The day is past when a surgeon should wait for such symptoms before deciding to operate upon the frontal sinus. There are other positive indications of sinus disease to guide him to a diagnosis and to a choice of the mode of treatment.

Mucous Discharge.—While catarrhal inflammation of the sinuses is generally referred to in the text-books, no clear idea of the symptomatology and diagnosis is given. The presence of pus in the nose has been an essential requirement for making a diagnosis. I have found it almost as easy to diagnosticate sinuitis without pus as with it. The symptoms are much the same as those in purulent sinuitis, except that pus is absent. The secretion is mucous or seromucous in character, and might easily escape observation. The patient may or may not complain of burning sensation in the anterior portion of the nasal passages, or of fissures or excoriations at the margin of the nostrils as a result of the acrid catarrhal discharge.

Headache.—Frontal headache limited to, or originating on, the side affected is generally complained of. The headache is often worse during the night, especially upon awaking while in bed, or in the morning. It is often confounded with eyestrain. Headache due to eye-strain is generally relieved upon closing the eyes, especially upon retiring for the night. The headache caused by frontal sinuitis (catarrhal or suppurative) is not aggravated by attendance upon the theatre; whereas if due to eye-strain, it is thereby aggravated.

Dizziness; Vertigo.—Dizziness or vertigo of slight degree is present in most cases, severe in others. It is often present in simple catarrhal inflammation, as well as in suppurative inflammation of the frontal and ethmoidal sinuses. It is especially aggravated by stooping, or, if in a stooping posture, upon assuming the erect posture. Careful inquiry is often necessary to elicit this symptom, as the patient does not consider it of any significance.

Ocular Symptoms.—According to Fish, Zeim, Wood, Stucky, Coffin, and others (Eye in Relation to the Sinuses), inflammation of the frontal or any other sinus may give rise to morbid processes in any of the structures of the eye. This is accounted for by the free anastomosis of the veins of the sinuses with the ophthalmic vein. Congestion in the sinuses causes a like condition in the eye. Infection is thereby favored; papillitis, choroiditis, optic neuritis, iritis, keratitis, etc., thus becoming established.

Intracranial Complications.—Extradural and brain abscess, meningitis, and sinus thrombosis may arise from sinuitis. Inasmuch as the posterior wall of the frontal sinus is thinner than the external or anterior wall, it is curious that intracranial complications are so rare. The superior longitudinal and the cavernous sinus occasionally become thrombosed in frontal sinuitis. Meningitis of sinus origin is more

frequently reported now than formerly, a fact significant of a better understanding of the subject.

The Anterior Ethmoidal Sinuses.—The anterior ethmoidal cells vary in number from two to eight, and are smaller than the posterior cells. They all drain into the middle meatus. According to Logan Turner, the frontonasal canal opened in the infundibulum in about one-half of the specimens examined, and directly into the middle meatus in the remainder. The anterior cells are separated from the posterior cells by a thin transverse bony partition. The attachment of the middle turbinated body to the external wall of the nose also marks the line of division between the anterior and the posterior group of cells. The anterior cells lie in front of and below it, while the posterior cells lie above and behind it. Clinically the two groups of ethmoidal sinuses are, therefore, divided into anterior and posterior cells. The anterior cells belong to Series I, while the posterior cells belong to Series II.

Fig. 119

Fig. 120

Fig. 119.—Empyema of the ethmoidal sinuses with perforation through the lacrymal plate at the inner canthus of the right eye and marked bulging at this point. Both upper eyelids are edematous and purple. The right eye is entirely closed, the left almost. One year previously had a similar attack following scarlet fever. (Author's case.)

Fig. 120.—Same case six days after operation. External wound gradually filled in by granulation and became closed in two months. (Author's case.)

Accessory ethmoidal sinuses are sometimes present in the middle turbinal and in the uncinate process, and when present drain into the middle meatus and belong to the anterior group or Series I.

The upper wall of the ethmoidal cells is a rather dense but thin plate of bone. The cribriform plate is not covered by the cells, but is freely exposed in the attic of the nose. While the bone is dense and not easily fractured by ordinary force exerted during an operation, its numerous openings render it a possible atrium of conveying infection to the meninges. The outer wall of the ethmoidal sinuses is the *os planum* or *lamina papyracea* of the ethmoidal and the lacrymal bones. These plates of bone are extremely thin, and form the inner wall of the orbital cavity. Should this plate of bone be perforated, orbital cellulitis, with protrusion of the eyeball, might result.

In Fig. 119 is shown a case of ethmoidal suppuration in which the lacrymal bone was carious and perforated. When first seen there was a large nipple-like projection of the skin at the inner angle of the orbit,

or lateral wall of the nose, in this region. The right eyelid was swollen and closed, while the left was less swollen and partially closed. The upper and lower lids of both eyes were discolored purple. Protrusion of the eyeballs was absent, as orbital cellulitis was not present. Had the perforation occurred more posteriorly through the os planum, orbital cellulitis would in all probability have occurred.

The patient had a similar attack one year previous to this one. The swelling subsided, but the nasal discharge continued, and the eye was uncomfortable.

Skiagraphs showed marked cloudiness in the ethmoidal region on the right side, while on the left it was less cloudy. The frontal sinuses were absent, or if present were very small. The lower meatus of the nose was quite open. Frontal headache and dizziness were prominent symptoms.

The nipple-like projection was incised at once and discharged a half-ounce of thick yellow pus. On the following day, under general anesthesia, the region was exposed by an external skin incision extending from a point below the nipple-like tumefaction to the middle of the right eyebrow. The lacrymal bone was almost entirely destroyed by necrosis. The frontal process of the maxilla was removed with rongeur forceps, thus fully exposing the anterior ethmoidal cells to operative interference.

Fig. 121

The author's ethmoid curette.

The entire ethmoidal labyrinth, including the middle turbinal, was removed with a curette (Fig. 121). The curette was also used through the anterior nasal opening, to make sure that no remnants of the cells were left. The cranial plate and the os planum were carefully but thoroughly curetted until they were smooth.

The left side was operated through the nose, the middle turbinal and the ethmoidal cells being removed in their entirety, in so far as they could be reached with the curette by this route.

Fig. 120 shows the patient one week after operation. The edema and discoloration of the eyelids have entirely disappeared, and the wound in the lacrymal region on the right side permits of a clear view of the interior of the nose. The marked change in the facial expression is suggestive of the improved condition of the patient. The purulent secretion may penetrate the orbital plate, as shown in Fig. 122, and cause orbital cellulitis.

The Maxillary Sinus (Antrum of Highmore).—The maxillary sinus, the third and last sinus belonging to Series I, is the largest, and, according to the prevailing opinion, is more frequently diseased than either of the other sinuses in both series. Personally, I question this statement, as according to my own observations the ethmoidal and frontal sinuses are more frequently involved. Our knowledge of the

symptomatology of sinus diseases in general has greatly increased during the past five or ten years, with the result that ethmoidal, sphenoidal, and frontal sinuitis are diagnosticated twenty times where they were once ten years ago. While the antrum still holds an important rank as a seat of disease, the ethmoidal and the frontal occupy an equally important place. The diagnosis of antral inflammation has been understood for many years, and this has given rise to the impression that it is much more common than inflammation in the other sinuses. It may be infected from the nose or the teeth, the cases probably being about equally divided between these two sources of infection. On account of the dental origin of so many cases of maxillary sinuitis, it is more often affected singly than either of the other sinuses, in which the infection is almost always of nasal origin. When the infection is of nasal origin quite naturally more than one group of sinuses is simultaneously affected.

Fig. 122

Showing the thin orbito-ethmoidal wall partially destroyed. During ethmoiditis this wall may be broken or perforated, and give rise to orbital cellulitis. (Author's specimen.)

The osteum maxillare is situated in the upper portion of the naso-antral wall as far away from the floor of the sinus as possible. This apparently renders the drainage of the secretions quite difficult or impossible, except as they overflow when the antrum is filled. This is not the case, however, as there is but little secretion in the sinus in health—only enough to keep the mucous membrane moist. The epithelium of the antral mucous membrane is of the modified ciliated columnar variety, though it is but slightly developed and in patches. The wave-like motion of the ciliæ aids in carrying the scanty secretions to the osteum maxillare at the top of the sinus, where it is discharged through the infundibulum into the middle meatus.

In the course of severe or long-continued inflammation of the mucous membrane of the antrum the ciliæ are injured or destroyed altogether, and the secretions are retained in the antrum because they are not carried to the ostium maxillare. The secretions are greatly increased in quantity, a fact that still further tends to promote the accumulation within the sinus.

The second bicuspid and the first and second molar teeth are in close relation to the floor of the sinus. Indeed, they sometimes project into the bony cavity, being only covered by mucous membrane. A suppurative process around the root of either of these teeth might easily affect the mucous membrane of the sinus through the lymphatics and bloodvessels. Indeed, an affection of the crown of the teeth may extend through the lymphatics to the antrum.

The superior wall or roof of the sinus is crossed in its central portion by the infra-orbital nerve, which lies in a groove on the broad inferior side of the plate of bone. It is covered by mucous membrane and may be easily injured during the curettement of the sinus.

As it is a nerve of sensation rather than of motion, it regenerates readily after being injured, even if long portions of it are removed. Motor nerves do not thus readily repair.

SERIES II.

Series II is composed of the posterior ethmoidal and the sphenoidal sinuses, and their ostei open into the superior meatus of the nose.

The Posterior Ethmoidal Sinuses.—The posterior ethmoidal are usually fewer in number and larger in size than the anterior ethmoidal cells. Sometimes they occupy nearly all the ethmoidal labyrinth, extending to the anterior portion of the nose, and sometimes the anterior cells extend backward almost to the sphenoid bone.

The ostei open into the superior meatus and are in relation to the posterior half of the middle nasal concha (turbinated body), upon which the secretions flow. As the middle turbinal slopes slightly downward and backward, the secretion flows toward the posterior choana, though it also flows over the median border of the turbinal through the olfactory fissure, or space between the turbinal and the septum, hence a purulent secretion in the olfactory fissure is usually indicative of posterior ethmoidal suppuration. It may, however, indicate sphenoidal disease, or a combined empyema of the ethmoidal and sphenoidal sinuses. The secretions may also be forced into this position from the middle meatus by snuffing the nose.

The ostei of the posterior cells are not visible by either anterior or posterior rhinoscopy, nor are they accessible to the probe or cannula.

The symptoms of posterior ethmoidal suppuration are not so distinct as those in either of the cells comprising Series I. As the posterior cells are deeply situated, external tenderness is not present. Exophthalmos may result from the retention of the purulent secretion in the cells, the os planum forced outward behind the eyeball, causing it to protrude forward. This also gives rise to diplopia and strabismus and to a circumscribed visual field, especially for colors. The ocular disturbances are extremely rare in proportion to the number of cases in which the posterior ethmoidal cells are diseased. According to my own clinical observations, the ethmoidal sinuses (anterior and posterior) are more often diseased than the maxillary sinus, which is generally regarded as the most frequently affected. The ethmoidal sinuses are so situated in the upper and narrow portion of the nasal chambers, where a moderate deviation of the septum or an enlargement of the middle turbinal closes the olfactory fissure and thus blocks ventilation and drainage of the superior meatus and accessory cells. For these reasons the posterior ethmoidal cells are often the seat of disease.

The secretion in the posterior portion of the olfactory fissure is significant of ethmoidal suppuration, though the pus may come from the sphenoid. Indeed, the posterior ethmoidal and sphenoidal cells are so closely associated that when one is diseased both are often affected. A postrhinoscopic examination showing purulent secretion on top of the middle turbinal is almost certain evidence of disease of the posterior ethmoidal and sphenoidal cells. Crusts and secretions in the vault of the epipharynx are likewise indicative of the same affection.

The Sphenoidal Sinus.—The *ostium sphenoidale* is situated in the anterior wall of the sphenoidal sinus near the top of the cavity, though it is occasionally a little lower down. It is near the septum of the nose and is hidden from view by the close approximation of the middle turbinal to the septum. If there is marked atrophy of the turbinal, or if the septum deviates to the opposite side, it may be seen by anterior rhinoscopy. The opening varies from ½ to 4 mm. in diameter.

The purulent secretion flowing from the ostium either drains directly through the posterior choana into the epipharynx or on to the posterior end of the middle turbinal. Ocular inspection can usually only be made after the removal of the entire middle turbinated body.

The pain or headache occurring in sphenoidal inflammation is usually referred to the occipital region on the affected side, though in some cases it is diffused and ill defined. Catarrhal inflammation causes the same headache as suppurative inflammation, though it may not be so severe.

The ocular symptoms usually ascribed to suppuration of the sphenoidal sinus are those dependent upon the compression of the optic and oculomotor nerves. The optic nerve passes over the roof of the sinus, hence in closed empyema in which the thin bony wall of the roof softens, compression if not actual destruction of the optic nerve may take place. If only optic neuritis occurs, this is followed by atrophy and blindness. If the pressure reaches the sphenoidal fissure, the oculomotor nerves, the third, fourth, and sixth, become involved and strabismus in some form follows. Intense neuralgia may result from a neuritis of the ophthalmic division of the fifth nerve.

Other ocular lesions arising in the course of inflammatory diseases of this and all the other sinuses have already been referred to in the Eye in Relation to the Sinuses.

DIFFERENTIAL DIAGNOSIS.

To illustrate the methods of differential diagnosis, a series of hypothetical cases will be given, assuming the symptoms characteristic of the simple and combined empyemas of the various sinuses in the open, closed, and latent forms.

Simple empyema refers to those cases limited to one group of cells, as the maxillary sinus, frontal, anterior ethmoidal, posterior ethmoidal, or the sphenoidal sinus.

Open empyema refers to an empyema, either simple or combined, in which the ostei are open and permit of drainage and ventilation.

Closed empyema refers to those cases in which the ostei are closed by pathological changes and the secretions are retained and cause pressure.

Latent empyema refers to those cases in which the ostei are open but the secretion is so slight that it is not demonstrable, except by irrigation of the affected sinus.

The ostei of the sinuses are so situated that they drain into either the middle or the superior meatus of the nose. The sinuses situated anteriorly drain into the middle meatus, while those situated posteriorly drain into the superior meatus.

The anterior group, or those draining into the middle meatus, are the antrum, the frontal, and the anterior ethmoidal cells. These have been designated by Hajek as Series I.

The posterior group, or those draining into the superior meatus, are the posterior ethmoidal and the sphenoidal sinuses. These are designated as Series II. For the sake of brevity and clearness these terms will be used. Having defined the terms, we are ready to recite a series of hypothetical cases, illustrative of the symptoms and procedures necessary to arrive at a positive differential diagnosis between empyema of the various sinuses or combinations of them.

Case I.—(*a*) Complains of unilateral discharge from the nose.

(*b*) No pain.

(*c*) Subjective fetid odor.

(*d*) There is an ulcer at the root of the second bicuspid tooth on the side of the nasal discharge.

(*e*) Anterior rhinoscopy shows pus in the middle meatus.

The conclusion, based upon the above data, is that one or more of the anterior group of cells, Series I, is involved. While the ulcerous bicuspid suggests the antrum as the sinus most probably affected, it is by no means proved, nor are the frontal and anterior ethmoidal sinuses known to be free. To still further differentiate the focal centre of infection the following procedures must be instituted:

1. Remove the secretions from the middle meatus with the douche or a cotton-wound probe, and place the patient in Escat's position, *i. e.*, the head thrown forward with the affected side turned upward to favor the flow of pus from the antrum. After remaining in this position for a few minutes the middle meatus should be reëxamined, and if pus is found the antrum is probably involved. This is not absolutely established, however, as it might have come from the frontonasal canal. To still further clear the diagnosis, introduce a cannula and trocar through the naso-antral wall in the inferior meatus (under cocaine anesthesia) (Fig. 123) and irrigate the antrum. If pus is found the antrum is involved. The diagnosis is not yet complete, as it remains to be demonstrated whether the frontal and anterior ethmoidal cells are affected. If after thorough irrigation of the antrum pus does not reappear in the middle meatus, the probabilities are strongly in favor of a simple empyema of the antrum. This is true in view of the fact that the flow of pus from the frontal sinus is nearly constant, as its outlet when the patient is in a sitting posture is in the most dependent portion of the

sinus. In this case pus does not reappear in the middle meatus for several hours, unless the patient assumes Escat's position, hence the condition is probably a simple empyema of the antrum.

To still further strengthen the diagnosis *transillumination* of the antrum and frontal sinus should be performed. If the side involved shows opacity over the lower eyelid, a non-luminous pupil, and the absence of the sense of light with the eyes closed, empyema of the antrum is indicated. If, in addition, transillumination of the frontal sinus is negative, the diagnosis of a simple empyema is fairly well established.

The anterior ethmoidal cells are still to be considered. Transillumination does not help us here. The bulla ethmoidalis belongs to the anterior ethmoidal cells, and if it is enlarged toward the septum, or downward against the uncinate process, it is probable that the anterior ethmoidal cells are involved.

Fig. 123

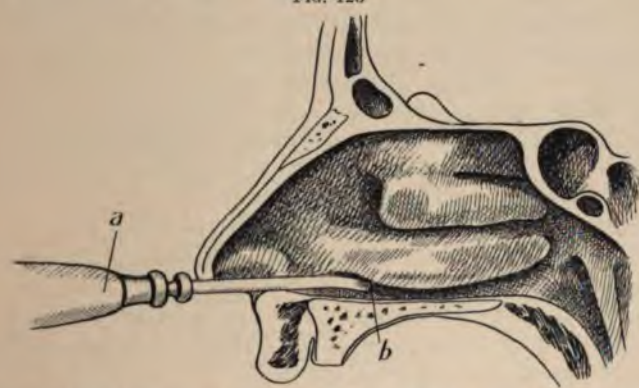

Introducing a trocar and cannula into the maxillary antrum beneath the inferior turbinal for diagnostic purposes.

If pus is removed by irrigation from the anterior ethmoidal cells, the case is one of combined empyema of the antrum and anterior ethmoidal cells. If it is also removed by irrigation from the frontal sinus, the case is one of combined empyema of Series I. Skiagraphy shows the frontal and ethmoidal areas clear.

Case II.—(*a*) Unilateral discharge of pus from the nose.

(*b*) Dull aching pain in the left cheek bone.

(*c*) Pus in the middle meatus.

(*d*) Slight tenderness over the cheek bone on pressure.

(*e*) Case under observation for several days; pus not always found in the middle meatus.

(*f*) Outer nasal wall on left side bulges toward septum.

(*g*) Pus occasionally discharged in great quantities, after which the dull ache in the malar region is relieved.

After performing the procedures described in Case I the purulent secretion is excluded from the frontal and anterior ethmoidal cells, and is localized in the antrum. The diagnosis is a simple closed empyema of

the antrum. The retention of the purulent secretion gives rise to the pain and tenderness over the left cheek bone and to the bulging of the outer nasal wall toward the septum. At times the pressure of the purulent secretion was great enough to force it either through the ostium maxillare or the accessory ostia, which were closed by the swollen mucous membrane. The pain caused by the pressure was relieved after each spontaneous discharge. This was a case of closed empyema of the antrum.

CASE III.—(*a*) No nasal discharge.

(*b*) There is a previous history of nasal discharge from the right side.

(*c*) Frequent attacks of frontal headache on the right side.

(*d*) Mental depression.

(*e*) Aprosexia.

(*f*) Transillumination of antrum and frontal sinus is negative.

(*g*) Pus not present in either the middle meatus or the olfactory slit.

(*h*) Irrigation of the sinus through a puncture in the inferior meatus (Fig. 123) shows a very small amount of pus.

(*i*) Irrigation of the frontal and anterior ethmoidal cells is negative.

(*j*) Irrigation of antrum continued until pus disappears.

(*k*) Supra-orbital pain, mental depression, and aprosexia disappear.

Diagnosis.—Latent empyema of the maxillary sinus.

CASE IV.—(*a*) Unilateral nasal discharge.

(*b*) Supraorbital pain and tenderness on percussion.

(*c*) Pressure on the roof of the orbit (floor of frontal sinus) elicits pain.

(*d*) Pus present in the middle meatus.

(*e*) When wiped away it reappears after a few minutes.

(*f*) Escat's position of the head has no influence on the flow of pus.

(*g*) Lying upon the back checks the flow.

(*h*) Frontal headache beginning on the affected side, more marked in the morning.

(*i*) Dizziness upon stooping

(*j*) Transillumination shows the crescentic light over the lower eyelid, the red pupillary reflex, and the sense of light in both eyes with the lids closed.

(*k*) Transillumination of the frontal sinus seems to show diminished luminosity on the affected side, although the difference between the two might easily be accounted for by anatomical variations.

(*l*) Puncture of maxillary inus through the inferior meatus negative.

(*m*) The cannula is introduced into the frontonasal canal (Fig. 124) and irrigation through it brings pus. Pus reappears in the middle meatus in a few minutes.

(*n*) Skiagraph shows cloudiness of the frontal sinus.

Diagnosis.—Simple open empyema of the frontal sinus.

CASE V.—(*a*) Complains of constant nasal discharge, right side.

(*b*) Supra-orbital headache on right side.

(*c*) Tenderness and swelling over the right eyebrow.

(*d*) Anterior rhinoscopy. Septum deviated to right, in the region of the middle turbinal. Polypi in middle meatus on right side.

(*e*) Probe shows polypi attached to uncinate process and the middle turbinal.

(*f*) Series I involved, probably localized in the frontal or the frontal and anterior ethmoidal sinuses.

(*g*) Transillumination, maxillary sinus, faint crescent and pupillary reflex. Frontal opaque.

(*h*) Polypi removed.

(*i*) Maxillary sinus punctured through inferior meatus and odorless pus is washed out.

(*j*) Frontal irrigated through cannula. Pus abundant.

(*k*) Frontal irrigated daily, maxillary sinus occasionally; absent in maxillary after the first irrigation.

(*l*) At end of six weeks frontal sinus still discharges pus.

(*m*) Radical external operation; caries and polypi found in frontal sinus.

Diagnosis.—Empyema of frontal sinus with secondary involvement of the maxillary sinus, which acts as a reservoir, but is not a focal centre of disease.

Case VI.—(*a*) Complains of purulent crust formations in right nostril and in the epipharynx in mornings. Hawks up crusts from the epipharynx.

Fig. 124

Frontal sinus cannula.

(*b*) Dull headache variously located; sometimes it is frontal, then vertexial, and then occipital.

(*c*) Mental depression and aprosexia.

(*d*) Anterior rhinoscopy: Septum deviated to right in region of middle turbinal. Olfactory slit narrow and filled with pus and crusts. Small polypi springing from the border of middle turbinal.

(*e*) Posterior rhinoscopy shows purulent secretions flowing over the posterior end of the right middle turbinal and the posterior epipharyngeal wall. Crusts not found, as they form at night when the position of the head and the quietness of sleep favor accumulation.

(*f*) Middle meatus free from pus.

(*g*) Provisional diagnosis: Empyema of Series II.

(*h*) A cannula is passed into the sphenoidal sinus through its ostium. Irrigation shows no pus (Fig. 131).

(*i*) A curved silver probe introduced through the olfactory slit shows bare rough bone in the superior meatus.

Diagnosis.—Open empyema of the posterior ethmoidal cells. The irrigation of the sphenoidal sinus eliminates it from consideration, and as Series II is only composed of the sphenoidal and posterior ethmoidal sinuses, the empyema is located by exclusion in the posterior

ethmoidal cells. This is still further substantiated by the presence of rough, bare bone in the superior meatus.

CASE VII.—(*a*) Complains of the formation of crusts in the epipharynx; also of postnasal "dropping."

(*b*) A subjective sense of odor is present, even in the absence of such an odor.

(*c*) Vertexial and occipital headache.

(*d*) Field of vision, especially for colors, diminished.

(*e*) Mental depression.

(*f*) Anterior rhinoscopy; olfactory slit occasionally filled with pus, though it is usually clear.

(*g*) Probing shows the mucous membrane of the superior meatus intact, while probing of the sphenoid sinus shows roughened bone and bleeding.

(*h*) Posterior rhinoscopy; purulent secretions on posterior end of right middle turbinated body and upon the posterior wall of epipharynx.

(*i*) Irrigation of the sphenoidal sinus shows pus in considerable quantities.

(*j*) Transillumination of maxillary and frontal sinuses negative.

(*k*) Examination of the fundus oculi shows slight papillitis.

Diagnosis.—Open empyema of Series II, probably focalized in the sphenoidal sinus. If the treatment of the sphenoid is followed by the disappearance of all symptoms, the diagnosis is positive. If the purulent discharge continues the posterior ethmoidal cells should be removed, and if a cure follows, the diagnosis of combined empyema of the sphenoidal and posterior ethmoidal sinuses is established.

CASE VIII.—(*a*) Complains of intense vertexial and occipital headache.

(*b*) Also of crust formation and postnasal dropping, yellow in color.

(*c*) Subjective sense of odor.

(*d*) Sudden blindness in the right eye.

(*e*) Great mental depression and aprosexia.

(*f*) Dizziness complained of.

(*g*) Anterior rhinoscopy shows pus and crusts in the olfactory fissure.

(*h*) Transillumination of the maxillary and frontal sinuses is negative.

(*i*) Probing of the middle and superior meatuses is negative.

(*j*) Cannot locate the ostium of the sphenoidal on account of the great swelling.

(*k*) Middle turbinal is removed and the ostium sphenoidalis appears to be filled with granulation tissue bathed in pus.

(*l*) The anterior wall of the sphenoid is removed, the cavity curetted, and granulation tissue and pus are found in considerable quantities.

(*m*) After the removal of the middle nasal concha (turbinated body) no pus is seen coming from the region of the posterior ethmoidal cells.

Diagnosis.—Simple closed empyema, granulations, and caries of the walls of the sphenoidal sinuses on the right side.

The sudden blindness is accounted for by pressure upon and inflammation of the optic nerve, or by venous stasis or thrombosis of the ocular veins.

The upper wall of the sinus may be softened and bulging against the optic nerve, thus inhibiting its function.

CASE IX.—(*a*) Complains of supra-orbital, vertexial, and occipital headache.

(*b*) Also of purulent discharge from the right nostril into the epipharynx.

(*c*) Subjective sense of odor.

(*d*) Strabismus of the right eye.

(*e*) Transillumination shows opacity of the right lower eyelid (left negative) and absence of red pupillary reflex, also opacity over the right frontal sinus.

(*f*) The bulla ethmoidalis is enlarged downward and inward.

Provisional diagnosis of empyema of Series I and II is made. It is still a question as to the exact localization of the suppuration. It seems probable that all the sinuses in Series I and II are involved, although not yet proved.

(*g*) The blunt probe is used, and shows bare, rough bone in the superior meatus and in the region of the uncinate process (the inner and inferior lip of the hiatus semilunaris). This makes it quite probable that the posterior ethmoidal, anterior ethmoidal, and the antrum are involved. When the bulla ethmoidalis is enlarged downward the discharge of pus is blocked in the infundibulum and is pent up in the anterior ethmoidal and the frontal sinuses. The pus under these circumstances often breaks through the lateral wall of the nose into the antrum. The enlargement of the bulla (one of the anterior ethmoidal cells) is in itself significant of a diseased process in this group of cells.

(*h*) The anterior end of the middle turbinal and polypi in the middle meatus are removed.

(*i*) The maxillary sinus is irrigated through a puncture in the inferior meatus and much pus removed, but persists in discharging.

(*j*) The frontal sinus is irrigated through a cannula and a copious discharge of pus follows and persists.

(*k*) The bulla is broken down with a curette, and pus wells from its interior. A polypus also protrudes from its cavity. The middle turbinal is resected and the posterior ethmoidal cells are thoroughly removed by curettement. After a time the pus discharge from the region ceases.

Having demonstrated the persistent presence of pus in all the sinuses embraced in Series I and II a positive diagnosis may be made.

Diagnosis.—Combined empyema of all the accessory nasal sinuses of one side of the head. A radical external operation and intranasal operations may or may not be indicated. All the sinuses may be drained by operative procedures through the nose and a cure effected without external operations in many cases.

NOTE.—While the foregoing series of hypothetical cases does not exhaust the list of possible and actual combinations of empyema of the accessory nasal sinuses, it illustrates fairly well the data and methods of procedure necessary to arrive at a diagnosis. Nor should it be understood that the data used in the above series is in strict accord with the clinical aspect of every case having the diagnosis given above. Other symptoms and pathological conditions are found, and great anatomical asymmetry often complicates the diagnosis. What is given above is in the main true. Much that is left unsaid is also true. It is obvious that in a limited number of hypothetical cases all the clinical and pathological data cannot be given.

CHAPTER X.

GENERAL CONSIDERATIONS IN REFERENCE TO THE SINUSES.

THE nasal accessory sinuses are the residual remains of the olfactory organ as found in some of the lower animals whose sense of smell is very acute. In the process of evolution the large distribution of the olfactory nerve has become less and less necessary, hence the sinuses are being gradually closed off from the nasal chambers until only small openings are present in man. Inflammation of the lining mucous membrane of the walled-off spaces becomes, therefore, an important pathological process. If the sinuses were more open to ventilation and drainage, an inflammatory process within them would be of less importance, because the perpetuity and destructiveness of the process depend very largely upon the lack of normal ventilation and drainage. It follows, therefore, that when inflammation of the sinuses is present the first principle of treatment is to establish ventilation and drainage of the involved sinuses. This may only mean that the swollen and inflamed mucous membrane around the cell openings should be depleted by the application of adrenalin, cocaine, or antipyrine, or it may mean that some surgical procedure should be instituted for their relief. However this may be, hold fast to the idea that ventilation and drainage of the sinuses is of prime importance, and that the removal of the morbid material is secondary to this.

Etiology.—The etiology of the inflammatory diseases of the nasal accessory sinuses of the nose, like that in other mucous lined cavities of the body, is largely embraced in those conditions which interfere with the drainage and ventilation of the cavities. (See Etiology of Inflammations of the Nose and Accessory Sinuses, Chapter VI.) When there is good drainage and ventilation, inflammation is rare, except in those cases subjected to a virulent infection or the resistance is lowered by some dyscrasia. The local expression of a constitutional dyscrasia, as syphilis, tuberculosis, etc., or a carious process in some contiguous organ, as a tooth, may cause sinus inflammation, even though the drainage and ventilation of the cells is normal. Aside from these and other local and constitutional diseases which cause sinus inflammation, it may be said that the anatomical configuration of the interior of the nose, whereby the drainage of the secretions and the ventilation of the sinuses are interfered with, plays an important role in the etiology of sinus inflammation.

The constitutional diseases having most to do in the causation of sinuitis are syphilis and tuberculosis. When there is a granulomatous infiltration in the outer wall of the nose, the ulcerative process may

invade the sinuses and give rise to inflammatory symptoms, as pain, tenderness, suppuration, headache, dizziness, etc. Likewise, when tuberculous infiltration and subsequent degeneration is focalized in the outer wall of the nose, the sinuses may participate in the process, or the ostei of the sinuses may become closed from swelling of the mucous membrane, thereby obstructing the drainage and ventilation.

Diseases of the contiguous anatomical structures, as the teeth, hard palate, and outer wall of the nose, may give rise to inflammation of the mucous membrane lining of the sinuses by an extension to these cavities, and by blocking the cell openings so that drainage and ventilation is impaired or altogether lost.

Caries of the root of a tooth located beneath the floor of the maxillary sinus (antrum of Highmore) may cause empyema of the antrum by infection through the carious fistula thus formed, or by way of the vessels and lymphatics. It has been estimated that nearly one-half of all empyemas of the antrum have their origin in diseased teeth, while the remainder are due chiefly to intranasal diseases and anatomical deformities of the nose. Nasal polyp is also regarded as a cause of sinus inflammation, although I believe the polyp is more often the result, rather than the cause, of sinuitis. However this may be, it is certain that the presence of a nasal polyp aggravates an existing sinuitis, and that its removal is often attended by an apparent rather than a real cure of the sinus inflammation.

Foreign bodies in the nasal passages may cause sinuitis by erosion and subsequent infection of the nasal mucosa, by directly blocking the cell openings, or by erosion through the outer nasal wall into the sinuses.

Nasal operations may eventuate in sinus inflammation by reactionary inflammation and infection, which may extend directly through the outer nasal wall or *via* the cell openings into the sinuses. In hospital practice particularly, infection from other patients may give rise to a sinuitis.

Nasal dressings may cause a damming up of the secretions which undergo decomposition and infection, and thus give rise to sinus inflammation. Too much emphasis cannot be laid upon the untoward results of intranasal tamponing, as it is a fruitful source of inflammatory disease of the nasal and sinus mucous membranes. Personally, I have abandoned intranasal dressings except in those cases where there is severe hemorrhage and where a dressing must be introduced to hold the septum in position after certain operations for the correction of deviations. Even then they should not be left in position an hour longer than is absolutely necessary to accomplish their purpose.

Venous stasis from intranasal pressure may cause sinuitis. The pressure may be due to some anatomical or pathological departure from the normal, as a deviation of the septum pressing against the outer wall of the nose, or to gummatous swelling of the septum.

These and other pathological lesions of the adjacent structures may cause sinuitis. All cases should, therefore, be carefully studied in order to determine the predisposing causes of the inflammation.

The Exciting Causes.—The exciting causes of sinus inflammation are the various microörganisms causing the exanthematous and other infectious fevers. It is well known that coryza is often one of the early phenomena of this disease, and that it is due to the microörganisms and their toxins. The inflammation usually extends to the sinuses, where it may remain in a latent or chronic form. In some cases it is only after many years that the sinus involvement becomes obvious enough to attract the attention of either the patient or the physician.

It is probably true that the sinus inflammation thus started is more apt to become chronic in those cases in which the cell openings are more or less blocked by anatomical deviations of the septum or other obstructive lesions of the nose. If, for example, the septum in its upper portion is deviated to one side, so as to approximate to the middle turbinal, the sinus inflammation arising during an attack of one of the infectious fevers is more liable to continue into the chronic form than it would be if no such obstructive deformity of the septum existed.

Pathology.—The pathological changes occurring in the mucous membrane and bony walls of the antrum in the course of suppurative inflammation are what one might expect in a mucous-lined cavity. Much discussion has arisen on this subject between anatomists and clinicians. Anatomists have found less marked changes, probably because they only examined such cases as came to them from the dead-house, while clinicians describe much more extensive changes in living cases, from whom specimens were removed during life, or upon the postmortem table. I prefer to base the pathology upon the clinical rather than upon the anatomical data.

Acute inflammation of the sinuses may be divided into the exudative and the diphtheritic, although the latter is rarely present and is not a true diphtheritic membrane.

The *exudative* inflammation may be serous, fibrinous, seropurulent, or purulent in character, according to the intensity of the inflammatory process.

For didactic purposes the changes occurring in the tissues may be studied in the following order, which represents the usual sequence of the pathological events:

(*a*) The submucous tissue is infiltrated with serum, while the surface is dry. Leukocytes also fill the meshes of the submucous tissue.

(*b*) The capillaries are dilated, and the mucous membrane is red in consequence.

(*c*) After a few hours, or a day or two, the serum and leukocytes escape through the epithelial covering of the mucosa, where they become admixed with bacteria, epithelial debris and mucus. In some instances capillary hemorrhage occurs and blood becomes admixed with the secretions. The secretions, at first thin and watery, later become thicker and tenacious, on account of the coagulation of the fibrin of the serum.

(*d*) In many cases resolution by the absorption of the exudate and the cessation of the discharge of the leukocytes takes place in from ten to fourteen days.

(*e*) In other cases, however, the inflammation passes from the catarrhal to the purulent type, the leukocytes being thrown out in immense numbers. Resolution is still possible, although not so probable, as the tissue changes are not yet of a fixed type. Unless the process is speedily arrested the tissue changes become permanent and chronicity is established.

(*f*) If the ostei of the sinuses are open the discharge of pus may continue indefinitely with little or no pain. If, on the contrary, they are closed, the purulent secretion is retained, and pressure symptoms, as pain, swelling, and tenderness, arise. If the discharge cannot escape through the ostei the point of least resistance bulges before the pressure of confined pus. The points of least resistance vary in different cases, although there is reasonable constancy in their location.

The points of least resistance in the sinuses are as follows, due allowance being allowed for anatomical variations:

(*a*) In *the frontal sinus* the inferior wall is the thinnest, especially three-quarters of an inch from the median line, over the anterior ethmoidal cells, hence the frequent involvement of these cells in frontal empyema. Clinically, we often see cases in which there is a sudden gush of pus into the nasal chamber, after which the pain and other pressure symptoms are relieved. It is probable that in these cases the floor of the frontal sinus yielded to the pressure of the pent-up pus, which may have discharged through the anterior ethmoidal cells, although it may have escaped through the frontonasal canal.

(*b*) In *the antrum* the most vulnerable point in the nasal walls is the pars membranaceæ, the membranous portion of the middle meatus. The anterior and superior walls are sometimes thin, and may bulge, or become perforated by the pressure of the retained pus. One of the characteristic symptoms of antral empyema is the tenderness and swelling over the anterior (canine fossa) wall. Bulging of the upper or orbital wall causes an interference with the external muscular apparatus of the eyeball. Perforation in the orbital wall, or roof of the antrum, gives rise to an abscess of the orbit, or orbital cellulitis.

(*c*) In *the ethmoidal sinuses* the point of least resistance is, perhaps, difficult to define, on account of the complexity of the ethmoidal labyrinth, it being composed of several pneumatic spaces. The lamina papyraceæ (paper plate) separating the cells from the orbital cavity is quite thin, as its name implies, and may be the seat of bulging and perforation. The inner, or nasal, aspect of the ethmoidal cells is more thin, and in empyema is distended until it presses against the septum. The pressure may extend toward the orbit and give rise to an imbalance of the external muscles of the eyeball, strabismus being the commonest expression.

(*d*) In *the sphenoidal sinus* the point of least resistance is in the upper wall, or roof, which is in close relationship to the optic nerve; hence the ocular disturbances often found in empyema of this sinus.

In chronic inflammation by far the greater number of observations have been made on the antrum, because it is more accessible to inspection

through the canine fossa. There is no particular reason, however, why similar changes may not occur in the other sinuses. I will therefore describe in general the pathological changes occurring in the entire sinus labyrinth, pointing out the changes peculiar to each group of cells, in addition to the changes common to them all. In general, it may be said that the pathological changes in the accessory sinuses of the nose correspond with the descriptions in general pathology.

The slighter changes are quite like those in acute suppurative inflammation affecting other mucous membranes and bone tissue. The mucous membrane may present a granular surface, villous and fungoid excrescences, granular, cushion-like thickening, etc. In the older cases there is thickening from hyperplastic and pyogenic membrane deposits, or the membrane may be destroyed in spots by ulceration, exposing smooth, bare bone, or the bone may be soft or rough from caries. In some cases necrosis and bone sequestra are present, or there is an entire loss of the bone. A microscopic examination of sections of the mucous membrane sometimes shows a loss of the epithelium and glands, which are replaced by connective tissue. Ulcerations of the membrane are often surrounded by granulation tissue, especially if there is bone necrosis. Granulation buds may encroach upon the periosteum, and thus unite the bone and mucous membrane. Where this happens the bone is superficially absorbed and somewhat roughened in consequence. Osteophytes, or bony scales or plaques, resulting from plastic exudation sometimes form on the surface of the bone.

Cysts of the mucous membrane of the maxillary sinus are present in a large number of the cases, according to some observers, while they are rather infrequent according to others. Cysts of the middle turbinate are usually located in the anterior end, and appear to be dilated ethmoidal cells filled with air, mucus, or pus, or an admixture of them.

I removed one from this region holding a half-dram of stinking pus. It should be remembered that the middle turbinated body is a portion of the ethmoid bone, and that the pneumatic spaces in it are a part of the ethmoidal labyrinth. Cysts are more rarely found in the walls of the frontal and sphenoidal cells.

Polypi have been found in all of the sinuses, although they are more common in the antrum and ethmoidal cells. They are much more common in the ethmoidal cells than is generally supposed. Their hidden location within the small ethmoidal spaces renders their diagnosis rather difficult. In the antrum, however, they are more easily diagnosticated, as it is quite frequently exposed through the canine fossa. As this sinus is quite large, the polypi are easily seen and diagnosticated. They have been found in the frontal and sphenoidal sinuses, although not so frequently as in the antrum and ethmoidal cells. The polypi in the ethmoidal cells are usually quite small, on account of the limited space within the cells, whereas, in the antrum they are much larger. In one case, in which I exposed the antrum through the canine fossa, the cavity was filled with polypi. In empyema of the ethmoidal cells the thin lamina papyraceæ separating the cells from the orbital cavity may be perforated

or entirely destroyed by the suppurative process. The same is true of the cranial plate separating the cells from the anterior hemisphere of the brain. In the latter case the meninges are exposed to infection, and may be the seat of meningitis or epidural abscess. Such an exposure of the meninges may exist in cases of latent ethmoidal empyema, with no other symptoms than a slight headache and mental irritability. A slight intranasal operation, especially on the middle turbinated body, may light up the slumbering fires and rapidly lead to a dangerous, or even a fatal, meningitis. The cases of meningitis occurring after intranasal operations are probably to be explained in this way, as has been shown by Grünwald in his work on Nasal Suppuration.

Thrombosis of the longitudinal and cavernous sinuses occasionally complicates ethmoidal empyema. Retrobulbar suppuration, or ocular cellulitis, is a comparatively infrequent complication of ethmoidal empyema from narcosis and perforation of the lamina papyraceæ.

In frontal empyema the floor and posterior wall are most often the seat of destructive changes. The floor near the median line is in apposition with the anterior ethmoidal cells and nasal septum, hence the cells and septum are frequently more or less involved in the carious and necrotic retrograde changes. The anterior ethmoidal cells are always filled with pus in frontal empyema.

Symptomatology.—The Objective Symptoms.—The objective symptoms may be extranasal or intranasal.

The extranasal symptoms are those changes in the appearance of the skin of the face, and of the fundus of the eye as shown by ophthalmoscopical examination. In addition to the objective signs the results of transillumination and of skiagraphy afford important objective information.

The intranasal objective signs of sinus disease are those changes in the appearance of the outer walls of the nasal chambers and the location of the secretion as it drains from the affected cells.

The Extranasal Objective Symptoms.—(*a*) When any of the sinuses contiguous to the skin of the face are involved (frontal, anterior ethmoidal, or antrum) there may be redness, swelling, and heat of the skin covering the affected area. If, for instance, the frontal sinus is acutely inflamed there may be swelling, redness, and heat of the skin in the frontal region; likewise in the malar region in antral disease and at the inner angle of the orbit in anterior ethmoidal disease. Tenderness upon pressure (a subjective symptom) is also present when redness and swelling are found.

(*b*) The fundus of the eye sometimes affords very useful and important objective evidence of sinu inflammation. Dr. H. M. Fish has shown this connection more clearly than any other writer, and I am chiefly indebted to his writings and to personal conversations with him for the facts given in reference to the eye symptoms of sinus inflammations. (See Relation of the Eye to Accessory Sinus Disease.)

(*c*) Transillumination of the face affords objective information as to the condition of the maxillary sinus, and sometimes of the frontal sinus,

but none in reference to the other sinuses. In transillumination of the antrum (see Methods of Examination) three points should be noted, namely, the red pupillary reflex, the crescent of light corresponding to the position of the lower eyelid, and the sense of light in the eye when closed. If the red pupillary reflex and the crescent of light are absent the antrum is probably affected. Note both sides at once, and thus determine which one, if either, is affected. A comparison of the lower portion of the field of illumination may be very misleading, as the anterior wall of the antrum varies greatly in density, irrespective of the disease present. The orbital or upper wall of the antrum is, however, more nearly uniform in its density in all cases, and affords a fair opportunity for a comparison of the transilluminated light through the two orbital plates; that is, when both orbital plates of the antrum are healthy the amount of light transmitted through them is about equal; whereas when one is thickened it interferes with the transmission of light, hence the crescent of light is dimmed or altogether absent. Likewise when

Fig. 125

Birkett's transilluminator for the simultaneous illumination of both frontal sinuses.

both orbital plates are healthy (antral disease absent) the light transmitted into the interior of the eyeball is shown in the red pupillary reflex in each eye; whereas if one antrum is involved the pupillary reflex is absent upon that side and present in the other. The sense of light (eyes closed) is present on the healthy side and absent upon the diseased side in maxillary diseases.

Transillumination of the frontal sinuses is an uncertain means of diagnosis, as the anterior wall often varies so much in thickness on the two sides in the same individual. The hooded lamp should be placed under the floor of the frontal sinus at the upper and inner angle of the orbit and the two sides compared. Dr. Birkett has devised a double lamp (Fig. 125), so that both sides can be illuminated at once to facilitate comparison. If the lamp is not placed well under the supra-orbital ridge the skin transmits the light and may thus lead to a false deduction. Taken as a whole, transillumination of the frontal sinuses is not a reliable procedure.

Skiagraphy.—Skiagraphy of the accessory sinuses of the nose should be a routine practice when access is had to a competent radiographer. Prof. Gustav Killian first practised it in diseases of the nasal accessory sinuses. Dr. C. G. Coakley has, perhaps, used it more extensively than anyone else in this field of work. Dr. J. C. Beck and the author have also made skiagraphs of about 200 cases. The great difficulty has been to find a radiographer who understands the technique well enough to produce clear skiagraphic plates. Dr. Caldwell recently published his technique, the essentials of which are herewith given.

Fig 126

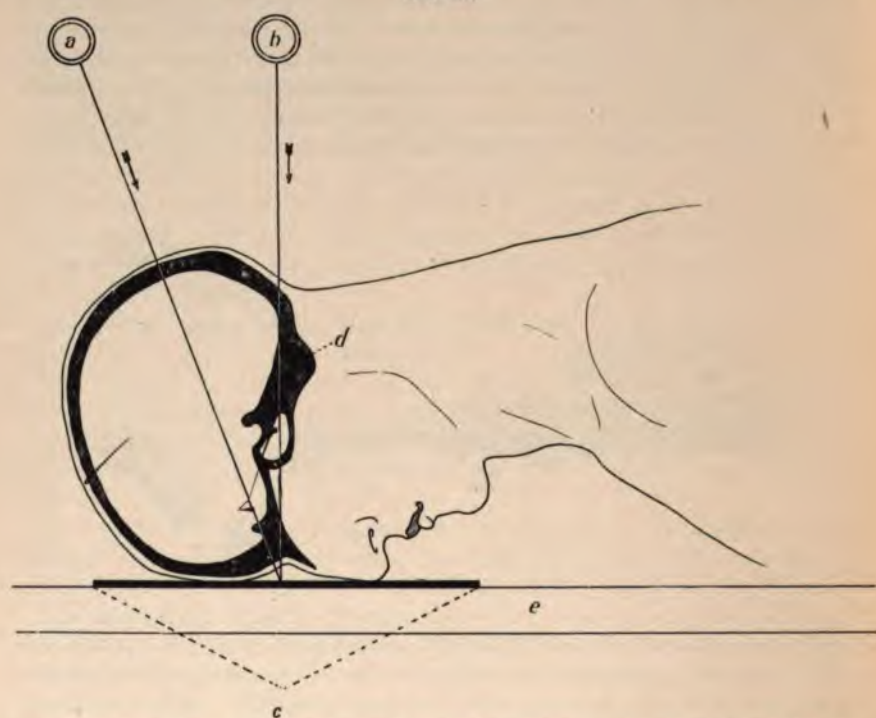

Schema showing the proper and improper angles for making a skiagraph of the frontal and ethmoidal sinuses. *a*, the proper angle for passing the *x*-rays through the head; *b*, the improper angle, as the rays must pass through a great deal of dense bone (*d*) to reach the sinus; (*c*) an 8 x 10 inch photographic plate against which the forehead should rest; *e*, the table upon which the patient lies. The forehead should be placed upon a triangular block with an inclination of twenty-five degrees, as this is more comfortable to the patient and renders the line (*a*) perpendicular to the table.

To get a plate with clearly defined outlines of the sinuses, and with a clear definition of the area of the sinuses, it is necessary to so place the *x*-ray tube as to avoid the heavy bone of the floor of the cranium, as it would interfere with the passage of the rays through the head. The *x*-ray tube should be applied, therefore, to the back of the head at a point above the occiput and floor of the cranium, as shown by the line *a* in Fig. 126. If the tube is applied at *b*, the rays would have to traverse

through the dense bone of the occiput and the long axis of the plate of bone forming the floor of the cranium before it reached the frontal and ethmoidal sinuses, thereby interfering with the formation of a clear shadow of the dense bone forming the walls of the sinuses and the production of a clear definition of the area of the sinus cavities. If, however, the *x*-ray tube is applied at *a*, midway between the occiput and the vertex, the rays have an unimpeded course to the frontal and ethmoidal sinuses, and the outline and area of the sinuses will be clear and well modulated. The delineation of the maxillary sinuses is not so clear, as the rays must pass through more bone tissue to reach it. A clear skiagraph of this sinus is not so essential, however, as this sinus is easily and successfully examined by transillumination with an electric lamp in the mouth.

The advantages derived from skiagraphy of the accessory sinuses are:

(*a*) *Diagnostic.*—If a sinus is healthy its outline on the plate or negative is clear and distinct (light) and its area is clear and dark. If the sinus is diseased its outline is less clear and distinct and its area is cloudy or hazy upon the negative or plate. Prints from the plates are rarely satisfactory for diagnostic purposes.

(*b*) The dimensions of the frontal sinuses is clearly defined, thus affording the surgeon positive information as to the extent of exposure necessary before he begins an external operation. A skiagraph through the lateral dimensions of the head will show the depth of the frontal sinus, thus affording the surgeon additional data as to the probable deformity to be expected should the Killian operation be performed. The wider and deeper the frontal sinus the greater the deformity following the complete removal of the anterior bony wall of the sinus. The information gained from the two views of the frontal sinus may determine the operator to either select or reject a given method of operation. If, for example, the skiagraph shows a small, shallow frontal sinus the Killian operation might be chosen in preference to other methods, as it is a thorough and satisfactory method of operating, and would in such a case be followed by little or no external deformity. If, on the other hand, the plates show a large and deep frontal sinus the surgeon might be influenced to adopt some other method of operating which would not be attended by such marked external deformity.

(*c*) In some instances, when the frontal sinus seems to be involved, the skiagraph will show a total absence of it, information of no small consequence to both the surgeon and the patient.

The Intranasal Objective Symptoms.—(*a*) The contour of the outer nasal wall sometimes affords information as to the condition of the sinuses. In closed empyema of the antrum the inner wall of the antrum may be pushed toward the septum. Likewise in empyema of the bulla ethmoidalis its median wall may be distended so as to close the hiatus semilunaris, or even impinge against the external surface of the middle turbinal.

(*b*) The texture of the mucous membrane of the nose, especially that portion of it covering the middle turbinated body, is sometimes indicative

of sinus disease; that is, when the mucosa of the anterior end of the middle turbinal is boggy and velvety in texture it usually signifies the existence of an ethmoidal sinus inflammation.

(*c*) Polypi are often associated with sinus disease, and are, I believe, usually secondary to the sinus inflammation.

(*d*) Pus within the nasal chambers is usually significant of sinus empyema. The nasal mucosa is rarely the focal centre of suppurative inflammation, whereas the sinuses are commonly the focal centre of such an inflammation. The presence of pus in the nasal chambers should, therefore, excite suspicion of the existence of a sinus inflammation. To determine which of the sinuses is involved, see Diagnosis.

In a general way it may be stated that pus in the middle meatus signifies an involvement of the frontal, anterior ethmoidal, or the maxillary sinus, as these cells drain into the middle meatus. If pus is seen in the olfactory fissure (between the septum and middle turbinal) the posterior ethmoidal or the sphenoidal cells are involved, as these cells drain into the superior meatus (above the middle turbinal).

The Subjective Symptoms.—The subjective symptoms of sinus inflammation have reference to the sensations of pain and of pressure, the equilibrium of the mind, and the impairment of the special senses.

(*a*) Pain referable to the region of the sinus involved may or may not be present. In active antral or frontal inflammation pain is often distinctly referred to the region involved. In the case of the deeper sinuses, as the ethmoidal and sphenoidal, the pain is vaguely deep seated in the head or referred to the periphery of the head without reference to the location of the sinus. For example, sphenoidal inflammation may give rise to pain in the occipital or the frontal region. As a matter of fact, inflammation in any or all of the sinuses usually causes pain in the frontal region. These pains are almost universally called headaches by the patient.

(*b*) Headache is, therefore, one of the commonest and most significant signs of sinuitis. Headache has multitudinous causes, and is not, therefore, pathognomonic of inflammatory or other diseased conditions of the sinuses. Headache may signify eyestrain, but in this case it is usually bilateral, whereas in sinus disease it is more often unilateral, or, if not unilateral, more pronounced on one side, or it begins as a unilateral headache and extends to the other side. The headache of sinus origin is increased upon stooping forward and upon a sudden jar of the body. It may persist upon closing the eyes upon retiring, or in a darkened room; whereas, if it is of ocular origin it disappears under such conditions.

The headache of ocular origin is greatly increased upon prolonged reading and upon attendance at the theatre. The headache caused by attendance at the theatre is so characteristic of ocular disturbance that it may be termed "theatre pain." The theatre pain is not characteristic of sinus disease.

The pains and headache due to disease of the frontal sinus may assume the form of sharp, shooting pains through the eyes and in the orbital region, or they may be dull and heavy, and nearly constant; or they

may consist of a full feeling in the forehead, aggravated by leaning forward, which in females is especially well marked during each menstrual period (H. M. Fish). Pressure under the floor of the sinus at the inner angle of the orbit (Fig. 118) usually elicits pain in these cases.

(*c*) *Tenderness upon Pressure.*—Tenderness and pain upon finger pressure may be present in disease of those sinuses contiguous to the surface of the face, viz., the frontal, anterior ethmoidal, and the maxillary sinuses.

For the examination of the frontal sinus, pressure should be made over the anterior wall above the supra-orbital ridge, and under the floor of the sinus near the inner angle of the orbit.

In the examination of the anterior ethmoidal cells, pressure should be made at the inner angle of the orbit against the orbital plate of the ethmoid.

In the examination of the antrum of Highmore pressure should be made over the canine fossa of the superior maxilla.

(*d*) *Disturbances of Equilibrium.*—Giddiness and vertigo or a momentary sense of blurred or darkened vision and imminent fainting are frequently present in disease of the sinuses. All these symptoms may be aggravated or produced by stooping forward. The patient should be carefully questioned in regard to these symptoms, as otherwise they may be overlooked. When these and the other signs of sinus disease are present the diagnosis is fairly well established.

(*e*) *Disturbances of the Special Senses.*—The olfactory, visual, and auditory senses are frequently disturbed or altogether lost in sinuitis.

The olfactory sense may be perverted (parosmia), the patient apparently perceiving odors that are not in evidence to normal noses. A more common symptom is the loss of olfaction (anosmia). This is accounted for by the blocking of the olfactory fissure by the swollen tissues in the region of the middle turbinal, and by the presence of polypi and a deviation of the septum in this region. The ventilation of the superior meatus of the nose is thereby prevented, hence the loss of the sense of smell. In some cases the loss of the sense of smell may be due to the degeneration of the terminal filaments of the olfactory nerve, although in most cases coming under my observation the sense of smell is regained after opening the olfactory fissure either by reducing the swollen membrane or resorting to some surgical procedures, as the removal of polypi or a portion of the middle turbinal.

The ocular function may be disturbed or altogether lost in the course of sinus disease. The disturbance may be due to either arterial or venous congestion, and to toxins, or to thrombosis of the veins intercommunicating between the sinuses and the eye. The morbid process in the eye may take the form of a papillitis, neuroretinitis, retrobulbar disease, keratitis, errors of refraction or of accommodation, photophobia, epiphora choroiditis, iridocyclitis, marginal blepharitis, conjunctival injection, or restricted field or loss of vision.

The Relation of the Eye to Sinus Diseases.—The intimate relation between the veins of the nose and accessory sinuses and of the eye

(Fig. 127), as pointed out by Dr. H. M. Fish and others, shows how reasonable is the assumption that many of the ocular lesions heretofore attributed to auto-intoxication from the intestines, gonorrhea, syphilis, and rheumatism, may in many instances be due to an extension of the disease from the sinuses to the ocular apparatus *via* the veins and lymphatics. Dr. Fish says: "The ocular symptoms resulting from an affection of the accessory sinuses of the nose have attracted a great deal of attention during the past few years, and various theories have been announced to explain their pathogenesis. According to Ziem, they are manifestations of a passive orbital hyperemia from a faulty oxygenation of the blood, resulting from a hindered nasal respiration, a nasal stenosis from edema, polypi, purulent secretions, etc. As this hypothesis fails to account for a circulatory disturbance limited to the ocular region, as well as the instances in which there is no hindered nasal respiration, the nostril presenting a practically normal appearance, as it does in some cases, the writer has modified the above theory and considers the stasis in the peri-orbital circulation to be the result of a vasodilatation resulting from an irritation of the sympathetic by the secretion pent up in a closed sinus. This theory is based on Gurwitch's demonstration, that the vaso-supra-orbitalia, frontalia, ethmoidalia, and ophthalmofacialia carry the greater portion of the venous blood from the nostril and its sinuses into the ophthalmic vein, and the fact, as shown by Zückerkandl, that the upper walls of the various cavities situated at the base of the brain are pierced by minute openings, through which the lymph and bloodvessels pass, thus affording a direct communication between the circulation in these cavities and to the convolutions of the brain. An intracranial circulatory disturbance results in cerebral symptoms, as vertigo (one of the early and most constant phenomena of sinuitis), epileptoid attacks, or unconsciousness (Lichtwitz, Englemann, Mayer, and the writer), or it may produce meningitis or abscess of the brain. A stasis appearing in the orbital circulation may cause an edema of the lids, or an exudate behind the globe with a resultant protrusion, or it may show itself in any of the eye tissues. If it appears in the cornea, for instance, there may be an elevation of the epithelium, abrasion, infection, and corneal abscess, with perforation, which may necessitate a subsequent enucleation of the eyeball. Should a severe intra-ocular involvement take place, and later the fellow eye show inflammatory symptoms, resulting from a sinuitis of the corresponding side,

Fig. 127

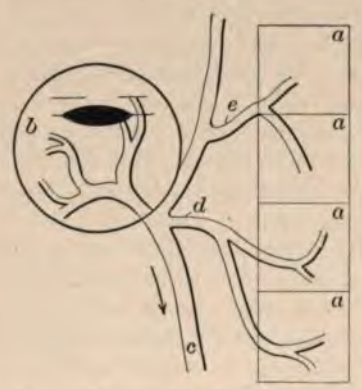

Schema showing the venous connections of the ethmoidal cells with the eyeball. *a a a a*, anterior and posterior ethmoidal cells; *b*, eyeball; *c*, the superior ophthalmic vein; *d*, the posterior ethmoidal vein; *e*, the anterior ethmoidal vein.

the condition could well be mistaken for one of sympathetic ophthalmia. Such an instance with enucleation, the only one in the literature, has been reported by Ziem."

It has been claimed by some writers that partial or complete blindness may arise as the result of pressure on the optic nerve in closed empyema of the sphenoidal sinus. It is quite probable, however, that most cases of blindness occurring in the course of sinuitis are due to venous stasis and thrombosis rather than to direct pressure upon the optic nerve. In the case reported by Dr. Fish, in which the eye symptoms were prominent, the frontal sinus was involved, although eye lesions may arise in the course of an inflammation in any of the sinuses.

In addition to the foregoing eye lesions, the patient may complain of pains shooting through the eyes, and other signs of inflammation of the visual apparatus.

The *auditory functions* may be more or less disturbed by sinus disease. The discharge from the sinuses into the epipharynx may cause infection of the mucous membrane of the Eustachian tube and middle ear. Sinuitis may indirectly be the cause of middle-ear catarrh or of suppurative otitis media and mastoiditis. In addition to the foregoing ear complications, there is another symptom I do not happen to have seen mentioned in the literature, namely, a momentary roaring accompanied by a fulness in the ears and dulness of hearing. These phenomena are especially liable to occur on stooping forward.

The Principles of Treatment.—The cure of sinus inflammation depends upon two propositions, namely, (*a*) the establishment of free drainage and ventilation, and (*b*) the removal of the morbid material.

In those cases in which the interference with drainage and ventilation is due to a simple hyperemia of the mucous membrane the local application of cocaine, antipyrine, or adrenalin may be quite sufficient to establish a cure. In such subjects the morbid material is the secretion, hence drainage removes it. On the other hand, in those cases in which there is marked obstruction due to a deviation of the septum or to hyperplasia of the middle turbinal it is often necessary to resort to surgical measures in order to obtain relief. Furthermore, in those cases in which the sinus is filled with granulation tissue and the bony walls are necrosed the establishment of drainage even by surgical means may not effect a cure; the morbid material (granulations and necrotic bone) must also be removed.

The Indications.—An appreciation of these fundamental principles enables the surgeon to decide upon the method of treatment in each case. In the following discussion of the treatment the foregoing principles will be constantly referred to with a view of enabling the student and practitioner to elect the proper mode of treatment in the cases coming under his observation. Before entering upon a detailed description of the various modes of treatment a general discussion of the varying conditions to be met will be given.

Acute catarrhal sinuitis is usually an extension of a similar inflammation of the nasal mucosa to the sinus, in the course of a coryza or cold

in the head. The mucous membrane of the nose and sinuses is hyperemic and swollen. The cell openings may be closed from swelling of the mucous membrane around them. The obvious indication is to relieve the swelling by the local application of certain drugs, surgical intervention being rarely justifiable.

Acute suppurative sinuitis occurring in the course of coryza is characterized by hyperemia and swelling of the mucous membrane of the nose and sinuses, and the indications are to reduce the swelling by local medicinal applications, as in the acute catarrhal variety.

Chronic catarrhal sinuitis due to pressure in the middle turbinal region demands the removal of the tissue causing the pressure. If the mucous membrane is chronically swollen, temporary relief may come from the application of antiphlogistic drugs, as adrenalin. If the secretions have dried and blocked the cell openings, probing may afford temporary relief. In most cases the middle turbinal is enlarged from hyperplasia or from cystic formation, and blocks the infundibulum. In some cases, therefore, it is necessary to either straighten the septum or remove a portion of the middle turbinal in order to give permanent relief from the symptoms. The bulla ethmoidalis may also block the infundibulum and prevent drainage and ventilation of the sinuses in Series I.

Chronic suppurative sinuitis, with obstructive lesions, demands the removal of the obstructive lesions, whether they be of septal, turbinal, or of other origin. As there is simple obstruction and no morbid material other than pus, the removal of the obstructive lesions permits of drainage and of the removal of the morbid material (pus). The foregoing statement does not apply, however, to all cases, as the drainage of pus from the cells is not altogether dependent upon free cell openings, as in most of the cells the opening is near their upper limit. The ciliated columnar epithelium lining the cells, though limited in distribution, carries the secretions up to the cell openings, where it is discharged into the nasal cavity. If, therefore, the ciliæ are destroyed by the inflammatory process, the removal of the obstructive lesions does not necessarily establish free drainage. In such cases it may be necessary to institute operative procedures to open the cells at their most dependent portion, or to exenterate them in their entirety (ethmoidal). In some cases the mucous membrane and the ciliated epithelium can be restored to their normal integrity and functional activity by lavage, or by negative air pressure, as recommended by Bier.

Chronic suppurative sinuitis without obstructive lesions of the septum or the middle turbinated body implies a degeneration of the mucous membrane with a loss of the columnar ciliated epithelium of the sinuses, at least in certain areas. The treatment should, therefore, either be directed toward the regeneration of the mucous membrane by negative pressure, and the resultant hyperemia and increased nutrition, or by opening the cells and establishing free drainage by some operative procedure.

Chronic suppurative sinuitis with granulations, polypi, or bone necrosis

is only amenable to surgical treatment. No treatment other than this will establish drainage and ventilation and remove the morbid material.

Treatment.—The principles of treatment having been given, only the technique of the treatment will be described in this section.

Treatment of Acute Catarrhal Sinuitis.—Acute catarrhal sinuitis usually involves all the accessory sinuses, and the indications call for the reduction of the swelling of the mucous membrane for the purpose of opening the ostei of the sinuses. The following technique is usually successful:

(*a*) Apply adrenalin, 1 to 2000, on thin pledgets of cotton, to the swollen middle and inferior turbinals to reduce the swelling.

(*b*) Apply a 4 per cent. solution of cocaine to reduce the swelling and to relieve the hypersensitiveness of the mucous membrane.

(*c*) Apply a 10 per cent. solution of antipyrine over the same area to prolong the ischemic effects of the adrenalin and cocaine.

(*d*) Use a 0.5 per cent. solution of menthol or other bland aromatic oily solution with a nebulizer every two or three hours.

The solutions of adrenalin, cocaine, and antipyrine should be used as often as the nasal chambers become stuffy, or the headache and sense of pressure returns.

In addition to the foregoing local remedies the internal administration of the usual remedies given in acute coryza may be given, but they are only of value in the early stage. (See Treatment of Coryza.)

Heat applied with a 500 candle-power lamp (Fig. 19) over the face sometimes affords immediate relief. The lamp should be passed back and forth before the closed eyes, at a distance of from twelve to eighteen inches, for twenty to thirty minutes. The good effects are due to the increased hyperemia and leukocytosis, and to the improvement of the nutritional processes. While germicidal properties are claimed for the light of this lamp, the effects may be explained by the increased leukocytosis and nutrition of the tissues. I have treated old chronic cases with the light in which the purulent discharge and pain disappeared, but returned after a few weeks. Whether persistent use of the light will cure these cases I am not prepared to state.

Treatment of Chronic Catarrhal Sinuitis.—This is more difficult to successfully treat on account of its chronicity, which of itself may imply that anatomical barriers existed during the acute stage to prevent resolution. These barriers, if present, must be overcome before a cure can be permanently established. The anatomical barriers to resolution may consist of hypertrophic or hyperplastic changes in the mucous membrane of the nose, especially in the region of the cell openings and the olfactory fissure, or they may be due to cystic formations in the middle turbinal or to deviations of the upper portion of the nasal septum.

The swelling of the mucosa may be somewhat reduced by the local applications of adrenalin, cocaine, and antipyrine. In addition to this, the hypertrophic or hyperplastic rhinitis should be treated after the manner described under these diseases.

If these measures fail, more radical surgical procedures, such as are used in obstinate cases of suppurative sinuitis, may become necessary.

Probing the frontonasal canal sometimes affords relief, although the removal of the anterior end of the middle turbinal and the curettement of the ethmoidal cells may be necessary.

Treatment of Chronic Suppurative Sinuitis.—In the simpler form of sinuitis, that is, where there are no granulations and carious bone, the lavage of the affected sinus with antiseptic, alkaline, or stimulating solutions is sometimes followed by a cure. The lavage of the frontal sinus may be performed through the frontonasal canal, except in those cases in which it is absolutely closed by an enlarged bulla or by an enlarged middle turbinated body.

Lavage of the Frontal Sinus.—An understanding of certain anatomical peculiarities of the region of the infundibulum and the frontonasal canal will materially aid in the lavage of the sinuses. The hiatus semilunaris, the infundibulum, and the frontonasal canal will be clearly defined, as much confusion appears in the literature concerning them. The terms are often used as synonymous, whereas they are distinct anatomical entities.

The hiatus semilunaris is a slit-like crescentic-shaped opening in the outer wall of the nose. It is the opening of the infundibulum into the middle meatus of the nose. Its inner lip is the upper margin of the uncinate process of the ethmoid bone.

The infundibulum is a deep, narrow groove or gutter in the outer wall of the nose (Fig. 129 *f*), the inner wall of which is the uncinate process. The frontonasal canal drains into the infundibulum in about one-half of the subjects, whereas in the remainder it drains a little anterior to it directly into the middle meatus (Turner).

The frontonasal canal is a closed tubular duct extending upward and forward from the middle meatus or the infundibulum, as the case may be, to the frontal sinus. Its opening into the floor of the frontal sinus is known as the ostium frontale.

Having defined the parts concerned in probing or irrigating the frontal sinus, certain anatomical peculiarities which influence the procedure will be given brief notice.

The hiatus semilunaris is the key to the probing, as it is the opening into the infundibulum, which must be entered to reach the frontonasal canal in about one-half of the cases. The bulla ethmoidalis is situated just above the hiatus, and when large it encroaches upon the slit-like opening and partially or completely closes it. Occasionally there is an accessory cell in the uncinate process, which also obstructs the hiatus. In other cases the middle turbinal closely hugs the outer wall of the nose and blocks the hiatus (Sluder). When either of these anatomical peculiarities is present the introduction of the probe or the cannula is rendered difficult or impossible. If the frontonasal canal opens in front of the infundibulum the probe or cannula may be passed into it even though the hiatus is closed.

Another difficulty sometimes encountered in probing is, that the probe may enter the ostium of one of the anterior ethmoidal cells instead of the frontal sinus. Some of the anterior cells may open into the infun-

dibulum on its outer wall, while others open into the frontonasal canal. The anterior cells are usually located external to the infundibulum and the frontonasal canal and their ostei open into the infundibulum and frontonasal canal, through the outer wall. In probing, therefore, the point of the probe should be kept against the inner or mesial wall of the frontonasal canal in order to avoid the ostei on its outer wall.

Probing is generally more difficult in those subjects in which the frontonasal canal empties into the infundibulum than when it empties directly into the middle meatus. In the former case the canal is often tortuous and narrow, while in the latter it is usually straighter and of larger caliber.

The middle turbinal is sometimes so close to the hiatus, especially when the turbinal contains an accessory cell, that it is difficult to enter it with a probe or cannula. In this event the removal of the anterior third of the turbinal overcomes the difficulty.

The Technique of Probing the Frontal Nasal Canal.—First cocainize the parts. Then introduce a fine silver probe (Fig. 128), bent at its distal end to an angle of about 135 degrees, between the anterior third of the middle turbinal and the outer wall of the nose. Keep the tip of

Fig. 128

Holmes' malleable frontal sinus probe.

the probe against the outer surface of the turbinal and pass it forward and upward through the hiatus into the infundibulum, where it readily enters the frontonasal canal even to the osteum frontale (Fig. 129). After engaging in the middle meatus it should be passed into the infundibulum and canal for about 6 to 8 cm. to reach the frontal sinus.

The irrigation of the frontal sinus is accomplished through a silver cannula, which is introduced in the same manner as described for the introduction of the probe. The syringe is attached to the cannula (Fig. 130) and the sinus gently irrigated with warm normal salt or boric acid solution.

Lavage of the sphenoidal sinus is possible when the middle turbinal, or a deflection of the septum, does not prevent the introduction of the sphenoidal cannula into its opening. When such an obstruction is present it may become necessary to first remove it by some surgical procedure before the irrigations can be practised. Personally, I am in the habit of using a silver Eustachian catheter in place of a sphenoidal cannula, and find the curve used for the inflation of the ear the correct one for irrigation of the sphenoidal sinus. Myles' cannula (Fig. 130) may be bent to reach any sinus, and is smaller than the Eustachian catheter.

Lavage of the Maxillary Sinus.—This can rarely be effected through the cell opening on account of its hidden position in the infundibulum, and on account of the forward and downward direction of the antral opening from the infundibulum to the antrum. The opening into the

Fig. 129

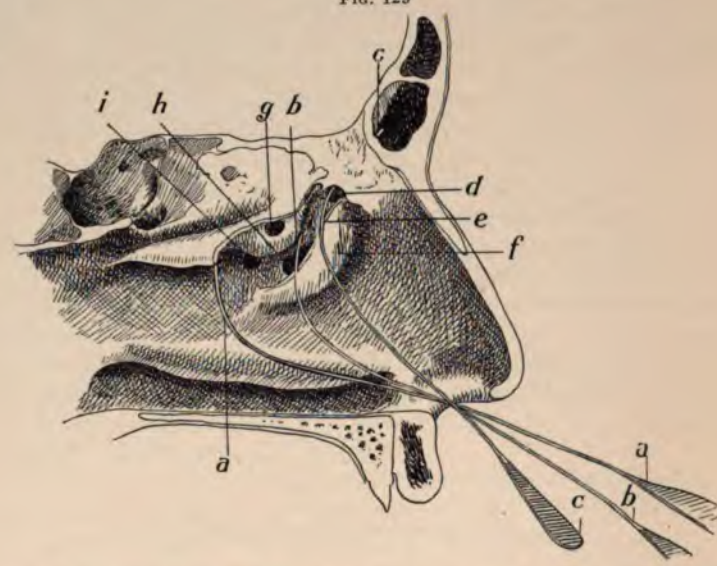

Probing the frontal sinus. The anterior half of the middle turbinated body is removed to show the anatomical landmarks. *a a*, the probe in the first position beneath the middle turbinal and posterior to the bulla ethmoidalis; *b*, the probe in the second position beneath the middle turbinal and in front of the bulla ethmoidalis; *c c*, the probe in the third position introduced through the frontonasal canal into the frontal sinus; *d*, the nasal end of the frontonasal canal; *e*, the lip of the uncinate process; *f*, the inner wall of the infundibulum; *g*, the osteum bulla ethmoidalis; *h*, the osteum maxillare; *i*, an accessory opening into the maxillary sinus. (Drawing from a specimen loaned by Dr. Ira Frank.)

antrum is not directly through the lateral wall of the nose, but it is more like a canal extending obliquely downward and forward through the thickness of the wall. The canal or opening is furthermore somewhat hidden by the unciform process, or lip, of the hiatus semilunaris. Some writers have claimed that they could irrigate the antrum through its

Fig. 130



Myles' sinus cannula.

normal opening, but a casual study of the anatomical peculiarities of the region will convince anyone that it is a physical impossibility, except in rare instances. In a certain number of cases there are accessory openings into the antrum (Fig. 129 *i*), which when present may be utilized

for irrigation purposes. Then, too, the lamina membranacea of the naso-antral wall may be perforated with the tip of the cannula and irrigation performed through it. In view of the foregoing facts it is rarely possible to irrigate the antrum through the normal osteum, hence an artificial route should be chosen, the most available one being beneath the inferior turbinated body, a curved trocar and cannula being used for the purpose.

The technique is as follows:

(*a*) Anesthetize the mucous membrane of the inferior meatus with a 5 per cent. solution of cocaine.

(*b*) Introduce the trocar and cannula beneath the inferior turbinal posterior to the anterior antral wall, and direct it upward and outward, a little above the floor of the nose, in order to avoid the thick wall of bone at this point (Fig. 123).

(*c*) After penetrating the naso-antral wall remove the trocar, leaving the cannula in position.

(*d*) Attach the rubber hose of the syringe to the cannula and irrigate with normal salt or other solution chosen for the purpose.

(*e*) By cocainizing the area daily the irrigations may be continued through the artificial opening indefinitely.

Lavage of the Antrum through the Alveolar Process.—This may be done after having performed the Cooper operation, so named after Sir Astley Cooper, who introduced it to the profession.

The technique is as follows: (*a*) Select a place where a tooth has been extracted, or if a tooth is decayed beyond repair, extract it for the purpose, and drill a canal into the floor of the sinus. This is Cooper's operation.

(*b*) Through this opening a cannula is introduced and the antrum irrigated with normal salt or any solution desired.

(*c*) The canal thus made should be kept open by wearing a hard or soft rubber or gold tube made for the purpose. The tube should be flanged on the alveolar end to prevent it slipping upward into the antrum

(*d*) A plug should be introduced into the tube to prevent food entering the antrum.

Lavage through a canal external to the teeth.

(*a*) Cocainize the gums.

(*b*) Drill a canal through the upper and external part of the alveolar process at a point between the first and second bicuspids, avoiding the roots of the teeth.

(*c*) Proceed thereafter as in the Cooper operation.

This procedure is generally chosen rather than the Cooper operation, as the teeth are usually present, and, even if diseased, are amenable to dental treatment. Neither method is recommended.

Lavage of the Ethmoidal Cells.—This is often impossible except in the case of the anterior cells which drain into the frontonasal canal. The bulla ethmoidalis, one of the anterior cells, does not drain into the frontonasal canal, but drains directly into the middle meatus, and its ostium is situated at its upper median wall.

The technique for the lavage of the anterior cells opening into the frontonasal canal is the same as for the frontal sinus; indeed, both sets of cells are often irrigated at the same time. Their ostei are bathed with the irrigating fluid and the accumulated pus in the canal is removed, thus facilitating the drainage of the cells.

Fig. 131

Andrews' sphenoidal probe cannula and knives.

Andrews' Lavage of the Sphenoidal Sinus.—A. H. Andrews has devised a curved cannula (Fig. 131), which can be introduced into the sphenoidal sinus without the preliminary removal of the middle turbinated body. This is a decided advantage, as it renders the treatment of empyema of these sinuses a very simple procedure. Should granulations be abundant it may be necessary to first remove the middle turbinal and then the anterior wall of the sphenoidel sinus and curette its anterior.

Fig. 132

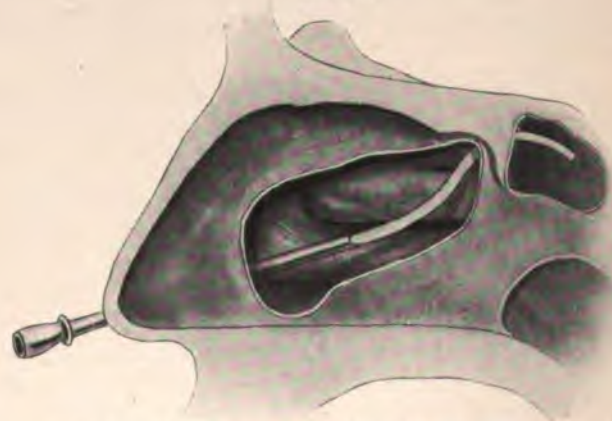

Irrigation of the sphenoidal sinus with Andrews' curved cannula.

The special curve of Andrews' cannula enables the operator to insinuate it through the olfactory fissure into the spheno-ethmoid fossa, and

by rotating it to engage the tip in the ostium sphenoidale (Fig. 132). When thus introduced, have the patient lean forward and open his mouth, then attach the hose of the syringe to the cannula and irrigate the sinus. With the head inclined forward and the mouth open the fluid will not enter the Eustachian tube.

General Remarks Concerning Lavage or Irrigation of the Sinuses.—Lavage of the sinuses in suppurative inflammations is, upon the whole, an unsatisfactory therapeutic measure. Formerly it was in vogue with dentists and surgeons for the treatment of antral empyema. Many cases were treated daily, for weeks and months, and some were cured, or apparently cured, while others continued to suppurate uninterruptedly. All the cases were treated alike except as to the solution used in individual cases.

If lavage is useful at all it is in the simple suppurative cases uncomplicated by granulations and necrosis. The removal of the purulent secretions gives the ciliated epithelium a chance to regenerate. It should also be borne in mind that the mucous membrane does not tolerate lavage indefinitely, as it is not accustomed to the presence of a large quantity of aqueous solution, hence irrigation is a doubtful procedure. If after a few days or weeks' trial the case does not greatly improve the irrigation should be discontinued and some other method of treatment, probably surgical in character, instituted.

Treatment by Negative Air Pressure.—Bier has demonstrated the therapeutic value of this method of treatment in inflammations. Sondermann, Brawley, and others have also reported favorably upon the use of negative pressure by means of an exhaust pump. The *rationale* of this method of treatment consists chiefly in the increased hyperemia of the mucous membrane lining the cells. The local nutrition is thereby improved, the cell resistance and leukocytosis increased, and the infective process checked. That such changes do take place in some cases thus treated is probably true. It is not claimed that all cases are amenable to this treatment. Let it be well understood, therefore, that negative air pressure should be used only as a tentative measure, and if a cure does not follow within a few weeks it should be abandoned and some other treatment substituted for it.

Technique.—(*a*) The apparatus necessary for producing negative pressure in the sinuses consists of either a hand pump or other device for exhausting the air in the nasal chambers. Brawley's apparatus is operated by attaching it to a faucet of the washbasin, the negative pressure being regulated by the amount of water turned on.

(*b*) Insert the nasal tips into the nostrils and bring the soft palate into apposition with the pharyngeal wall by swallowing. With practice the patient soon learns to maintain this condition for several minutes.

(*c*) While the air is thus exhausted the pus is drawn from the sinus into the rubber tubing, from whence it flows into the reservoir bottle. In this way several drams or ounces of pus may be removed in the course of a half-hour.

(*d*) Daily seances should be maintained until improvement appears,

or until the surgeon is convinced that this method of treatment is inadequate for the case.

Drs. Dabney and Pynchon have devised exhaust apparatus having the appearance of a spray tube (Fig. 18), which is operated with a compressed-air tank. They are ingenious and practical instruments.

With either apparatus the patient is instructed to swallow, thus closing off the pharynx from the epipharynx and nose. The suction, after a little practice on the part of the patient, maintains the palate muscles in this position for an indefinite period of time. The patient during this process breathes through the mouth.

CHAPTER XI.

THE SURGERY OF THE ACCESSORY SINUSES.

THE KEY TO SINUS DISEASE, OR THE "VICIOUS CIRCLE" OF THE NOSE.

In the chapter on the Etiology of the Inflammatory Diseases of the Nose and Accessory Sinuses it was shown that the chief predisposing cause of sinus inflammation is an obstruction in the region of the middle turbinated body and the hiatus semilunaris. The obstructive lesion may be a deflection of the nasal septum, an enlarged or cystic middle turbinal, an enlarged bulla ethmoidalis, or cells in the uncinate process (the median wall of the infundibulum). (Figs. 133 to 139.) As the frontal, anterior ethmoidal, and the maxillary sinuses drain into the infundibulum (exceptions noted, p. 167), an obstruction in this region may occlude either or all of these sinuses. When either of them is the seat of inflammation it is always advisable to make a careful examination of this region. The area to be thus examined is shown in Fig. 140 within the circle. These structures may be designated the "key" to sinus inflammation, or the "vicious circle" of the nose. Being the key to the etiology of sinus infection, it is also the key to the treatment of the infection; that is, if the obstruction predisposing the sinuses to infection is located within the area of the circle, it is obvious that if this area is freed from obstruction the chief etological factor will have been removed, and having been removed, the infectious process tends to subside.

The following principle may, therefore, be given as a working basis in the treatment of inflammatory diseases of the sinuses composing Series I. (See Chapter IX.)

Remove the obstruction within the "key," or vicious circle," before attempting more radical measures.

By so doing the drainage of the sinuses may be established and a cure result. This principle is of so nearly universal application that it forms a good working basis, and, if observed, will prove of inestimable value, as it will often obviate the necessity of resorting to the more radical operations in the treatment of these sinuses. Should the recommendations given above fail to relieve the disease, the more radical operative procedures may be performed in due time.

Various writers have made the clinical observation that meningitis is more liable to follow the radical external operation if an intranasal operation is performed a few days prior to the radical operation. The following deduction is, therefore, obvious:

Fig. 133

Fig. 134

Fig. 133.—A high deviation of the septum, causing closure of the infundibulum. *a*, high deviation of the septum; *b*, inner wall of the bulla ethmoidalis; *c*, middle turbinal crowded against the outer wall of the nose, and blocking the drainage of the infundibulum.

Fig. 134.—Cross-section through the nose. *a*, hyperplasia of the middle turbinated body, which crowds upon the uncinate process (*c*) and closes the infundibulum.

Fig. 135

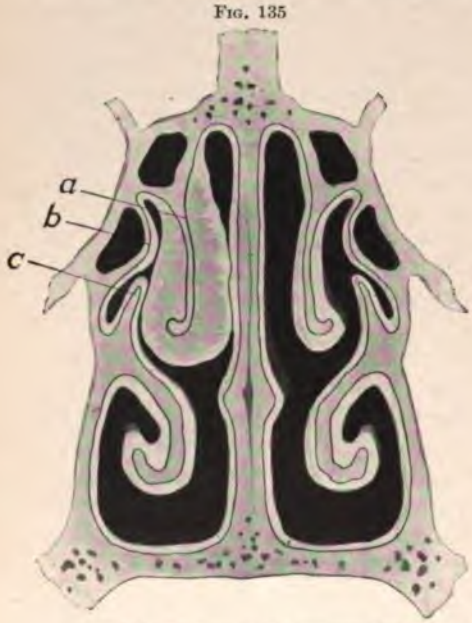

Fig. 136

Fig. 135.—Edema of the mucous membrane of the middle turbinal, blocking the infundibulum. *a*, edematous middle turbinal; *b*, bulla ethmoidalis; *c*, uncinate process or inner wall of the infundibulum.

Fig. 136.—A large cyst of the middle turbinated body, occluding the infundibulum. *a*, cystic middle turbinal; *b*, the inner wall of the bulla ethmoidalis; *c*, the uncinate process or inner wall of the infundibulum or gutter.

Fig. 137

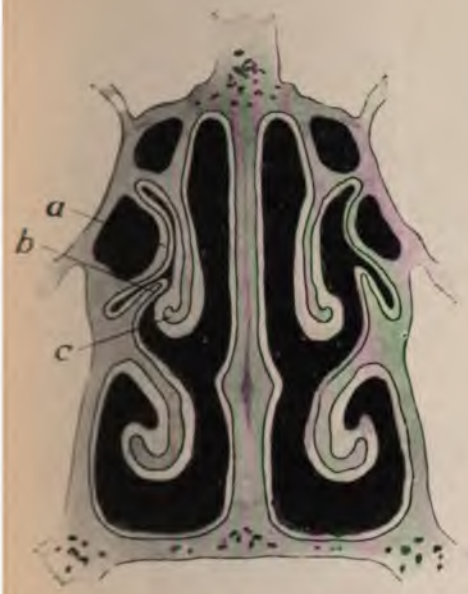

Fig. 138

Fig. 137.—Enlargement of the bulla ethmoidalis, blocking the infundibulum. *a*, the inner and distended wall of the bulla ethmoidalis, crowding inward and downward against the uncinate process and blocking the infundibulum; *b*, the uncinate process; *c*, the middle turbinal, which, on account of the bulging bulla, appears to be the cause of the blockage.

Fig. 138.—The middle turbinated body (*a*) clinging to the outer wall of the nose and blocking the infundibulum; *b*, inner wall of the bulla ethmoidalis; *c*, uncinate process or inner wall of the infundibulum.

Fig. 139

Cyst of the uncinate process (*b*) blocking the infundibulum; *a*, bulla ethmoidalis; *c*, middle turbinated body.

Never do a preliminary intranasal operation a few days before a radical sinus operation.

Several days or a few weeks should elapse between a preliminary intranasal operation and a radical sinus operation, to allow a wall of protecting granulation tissue to be formed. An additional reason for delaying the radical operation is, to allow sufficient time to elapse to determine whether the intranasal operation is adequate to cure the disease. I have seen serious cases get well most unexpectedly under such

FIG. 140

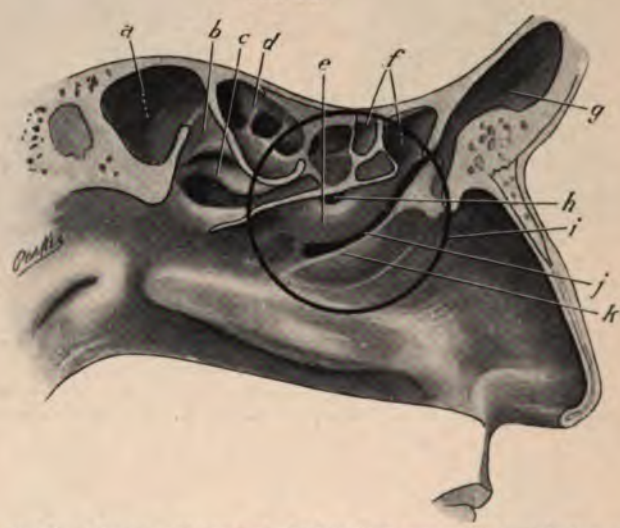

The "vicious circle" of the nose, the area of which is often responsible for infection and inflammation of the frontal anterior ethmoidal and the maxillary sinus. *b*, the spheno-ethmoidal fossa; *c*, the superior turbinated body; *d*, posterior ethmoidal cells; *f*, anterior ethmoidal cells draining into the frontonasal canal; *g*, frontal sinus; *h*, the ostium of the bulla ethmoidalis; *i*, hiatus semilunaris; *k*, the uncinate process or outer wall of the infundibulum or gutter on the outer wall of the nose into which the frontal, anterior ethmoidal, and maxillary sinuses usually drain. The high light below and anterior to *j* and *k* indicates the inferior boundary of the infundibulum or gutter into which the sinuses drain. The middle turbinated body is removed to exhibit the anatomical details beneath it.

treatment. I wish to state most emphatically, however, that, having found the simple intranasal operation ineffective, the surgeon should unhesitatingly perform a more radical operation. My plea is for rationalism rather than against radicalism. I do not plead for so-called "conservation," a term which has been used to justify timidity and surgical inefficiency. The true conservative is a rationalist who dares to refrain from radical procedures, and yet who dares to undertake them when indicated.

THE SURGERY OF THE FRONTAL SINUS.

The surgical treatment of frontal sinuitis may be divided into (*a*) intranasal, and (*b*) extranasal operations.

The intranasal operations consist in the removal of obstructions within the "key," or "vicious circle," and in the more extensive operation of Halle.

Intranasal Operations for Frontal, Anterior, Ethmoidal, and Maxillary Sinuitis.—Operations within the "Vicious Circle."—(*a*) Local cocaine anesthesia should generally be depended upon, though general anesthesia is preferable in certain cases.

(*b*) Remove the middle turbinated body or such part of it as obstructs the area within the circle shown in Fig. 140. Even though the middle turbinal does not actually obstruct the hiatus and infundibulum, it may be necessary to remove a portion of it to expose the field to surgical intervention. Physiologically there is little objection to the removal of

Fig. 141

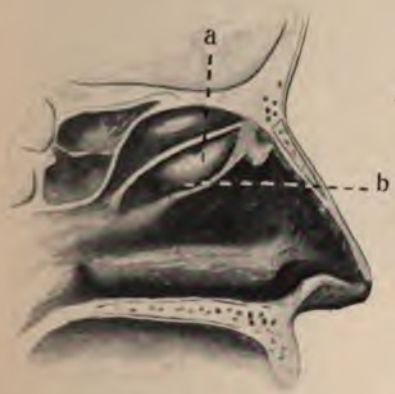

Fig. 142

Fig. 141.—Showing a large bulla ethmoidalis (*a*) encroaching upon the hiatus semilunaris; (*b*) the hiatus semilunaris. The middle turbinal has been removed. (Dr. W. A. Fisher's specimen.)

Fig. 142.—The anterior cell is the frontal sinus; the posterior one is one of the anterior ethmoidal cells extending half-way across the orbital cavity, and is inaccessible to operation except by bent curettes through the nasal chambers. The author recently operated three such cases. (Dr. W. A. Fisher's specimen.)

this structure. The olfactory nerve is not distributed to its mucous membrane, and the swell bodies are rudimentary. The method of removal should be selected with reference to the anatomical conformation present and the individual preference of the surgeon. The author's turbinal knife (Fig. 172) is usually well adapted to the purpose. (The various methods of performing turbinectomy and turbinotomy are described on pages 152 to 155 and 231 and 232.)

(*c*) Remove all of the anterior ethmoidal cells that can be reached with the curette, Grünwald forceps, or other instruments. Owing to the wide variation in the distribution of the anterior ethmoidal cells, the area of curettement varies in each case. In some subjects all the cells are not accessible to the curette. Occasionally one of the cells extends over the orbital roof posterior to the frontal sinus, as shown

in Fig. 142. In other cases a cell encroaches upon the floor of the frontal sinus and forms the so-called bulla frontalis, as shown in Fig. 143. The dense bone of the frontonasal spine of the superior maxillary bone often shields some of the most anterior of the cells from the curette. For these reasons the total exenteration of the anterior ethmoidal cells with the curette is not always possible by the intranasal route. As a consequence the frontonasal canal and the infundibulum cannot always be cleared of obstructive lesions. Drainage of the frontal sinus is not, therefore, always possible by this method of operating.

Should the subsequent course of the frontal sinuitis prove the inadequacy of the operation, either the Halle or one of the external operations is recommended. After an experience in more than two hundred cases operated *via* the "vicious circle" of the nose, I am convinced that but few cases of frontal and ethmoidal sinuitis require more radial surgical

FIG. 143

Showing the nasal sinuses of the right side of the head. The naso-antral wall, inferior turbinal and the middle turbinal are removed. One of the anterior ethmoidal cells (*a*) projects into the floor of the frontal sinus and forms the so-called bulla frontalis. (Author's specimen.)

interference. In only 3 per cent. of the cases was it necessary to perform an external operation. As the infundibulum is the outlet of the drainage system of the sinuses comprised in Series I, and as the anatomical deformities of the septum, middle turbinal, and bulla ethmoidalis often obstruct the drainage and ventilation of the infundibulum, it is a rational conclusion that, if the obstructive anatomical lesion is removed, drainage will be restored and the infection and inflammation cured.

Hemorrhage is the most troublesome complication attending this operation. The parts are chiefly supplied by the anterior and posterior ethmoidal and a branch of the sphenopalatine artery (Fig. 3). They are of considerable size and may bleed freely, though in my experience they rarely do so. The hemorrhage, though not profuse, usually continues for about twenty-four hours. A firm tampon of gauze in the

upper portion of the nasal cavity readily checks it. Fortunately it is rarely necessary to introduce a tampon for this purpose. The presence of the tampon may prove as serious as the operation, as it may fracture the orbital plate and expose the orbital contents to infection. A tampon should not, therefore, be introduced except in case of severe hemorrhage. Drainage is of more importance than the control of a slight hemorrhage. Place the patient in a hospital if possible, as the hemorrhage can be kept under better control than it can if the patient is at home.

After-treatment.—Instruct the patient to introduce a pledget of cotton in the vestibule of the nose and to remove and renew it as often as it becomes soiled with blood and secretions. This protects the denuded surfaces from being irritated by the inspiratory current of air and prevents the blood trickling over the upper lip. A dusting powder of bismuth-iodine should be insufflated once or twice daily. Healing usually occurs in about fourteen days, and if the exenteration is complete the space in the ethmoid region should be free and roomy. For a few days after the operation small pledgets of cotton, saturated with a 10 per cent. glycerin solution of ichthyol, should be introduced every four hours into the attic of the nose to promote osmosis and asepsis of the surgical field.

HALLE'S FRONTAL SINUS OPERATION.

Max Halle, of Berlin, enters the frontal sinus by the intranasal route by means of burrs and a protector to the internal plate of the frontal bone. The chief source of danger attending this operation is the injury of the internal plate of the frontal bone, thereby opening an avenue of infection to the meninges and brain. The grooved protector is intended to prevent the injury of this plate, and it should always be used.

The anatomical barrier to the removal of the floor of the frontal sinus is the backward projection of the spina nasofrontalis of the superior maxillary bone, as shown in Fig. 145. This dense, heavy bone was regarded as an insurmountable barrier to the floor of the frontal sinus by the intranasal route, until Halle recently called attention to this method of operating.

Indications.—The Halle operation is indicated in those cases of frontal and anterior ethmoidal sinuitis which have resisted the removal of the anatomical obstructive lesions within the "vicious circle" of the nose, and in which there are no fulminating symptoms, as meningitis, orbital abscess, and external perforation. When these symptoms are present an external operation should be performed.

Technique.—(*a*) Induce local anesthesia with cocaine.

(*b*) Introduce a probe into the frontal nasal canal for a distance of 2½ to 3 cm. after it enters the infundibulum or hiatus semilunaris, as when it is passed upward and forward this distance it has entered the frontal sinus.

(*c*) Introduce the protector alongside the probe for the same distance.

(*d*) Next engage the pointed drill (Figs. 144 and 145) against the

under and posterior border of the spina nasofrontalis, just in front of the protector. Direct the drill forward and upward and remove enough of the bone to allow the blunt-pointed drill (Fig. 144) to be introduced. The sharp-pointed drill should only be used to make an opening large enough to permit the introduction of the blunt-pointed one, as to use it further might lead to injury of the internal plate of the frontal bone. The blunt drill will not do this.

(*c*) With the blunt drill remove enough of the bone to permit the introduction of the pear-shaped drill (Fig. 146), the thickened portion of which is rounded and polished. Halle says: "With this instrument no dangerous injuries can be caused, provided the least care is taken. The

Fig. 144

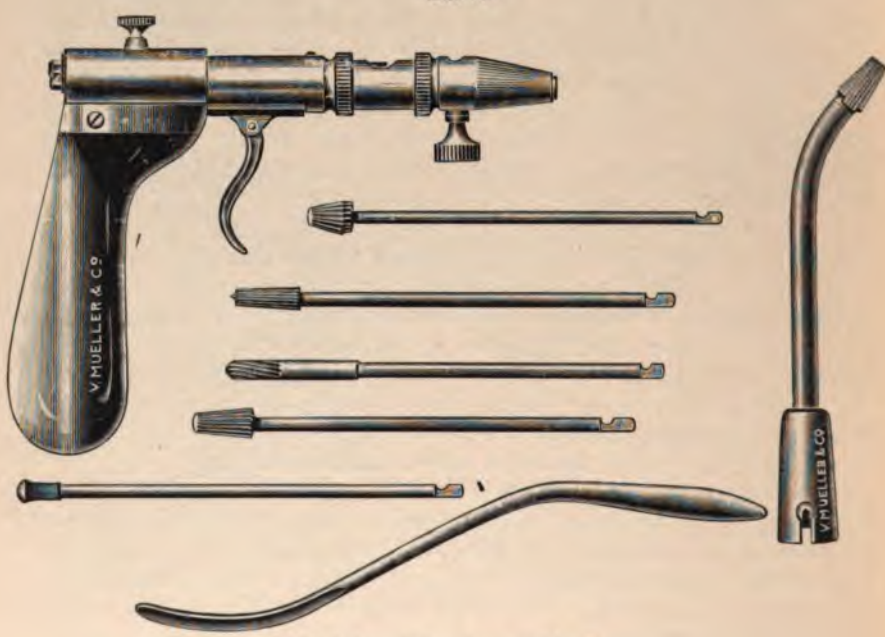

Halle's frontal sinus burrs and handle.

entire floor can be drilled away with it, and so large a part of the external plate of the frontal bone in a downward direction that the instrument can be felt from without. It is necessary that the assistant take the precaution to push his finger well into the orbit, so that he can control the head of the instrument (drill) and prevent it going too far to the front or the sides."

The mucous membrane of the frontal sinus may thus be exposed to ocular inspection and treatment through the nose if the bone is thoroughly removed, as shown in Fig. 147.

(*d*) The after-treatment consists in first packing the sinus with iodoform gauze, and the subsequent use of alcohol, protargol, or the nitrate

of silver to retard granulations and to promote the formation of epithelium. At a later period Halle has the patient introduce a large cannula several times a day to prevent the formation of granulations and adhesions, though this should preferably be done by the removal of the granulations, caustic applications, etc., by the surgeon.

(*e*) The anterior ethmoidal cells and middle turbinated body of the "vicious circle" are also removed in this operation. The posterior cells may also be removed at the same time by either of the methods described elsewhere in this chapter.

Fig. 145

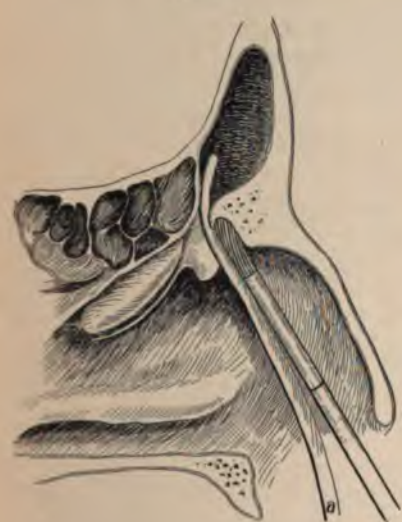

Fig. 146

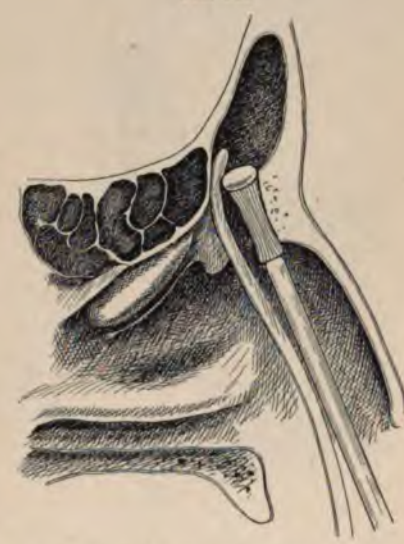

Fig. 145.—The first step in removing the nasal process which forms the floor of the frontal sinus at its inner extremity. A metal protector (*a*) is introduced into the frontonasal canal to prevent injury to the inner or cranial wall of the frontal sinus. The pointed burr is only used to begin the operation, after which blunt, smooth-tipped burrs are used, as they will not penetrate the inner or cranial bony wall of the sinus if they should accidentally come in contact with it.

Fig. 146.—The round-tipped burr removing the floor of the frontal sinus by the intranasal route. The protector is in position and the rounded, polished tip of the burr renders injury to the cranial wall of the sinus improbable.

External Surgery of the Frontal Sinus.—On account of its location, the frontal sinus is sometimes less successfully treated by the intranasal route than either of the other sinuses. We are, therefore, compelled to resort to external methods of operating in a considerable number of chronic cases. The method of Hajek Luc, or Ogston-Luc, as it is sometimes called, is one of the most efficient in uncomplicated cases of chronic empyema of the frontal sinus. This method is not adapted, however, to those cases in which the anterior ethmoidal cells are to be exenterated. In such cases it is necessary to remove the floor of the frontal sinus and the processus frontalis of the superior maxillary bone to give access to the anterior ethmoidal cells. The posterior ethmoidal and sphenoidal cells are accessible by the intranasal route.

The Hajek-Luc Operation.—(*a*) The skin of the forehead and around the eye should be thoroughly cleansed twenty-four hours previous to the operation and covered with a moist dressing.

(*b*) Twenty four hours later the patient is placed upon the operating table and anesthetized.

(*c*) The dressing is then removed and the parts re-scrubbed. It is not necessary to shave the eyebrow, as it can be easily cleansed and is useful as a landmark. Personally, I prefer to shave the eyebrow, as it interferes with the removal of the stitches.

Fig. 147

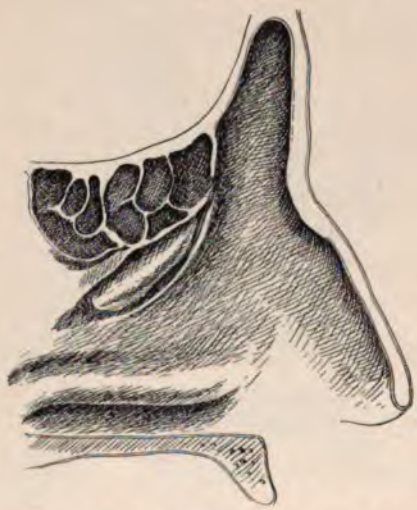

Fig. 148

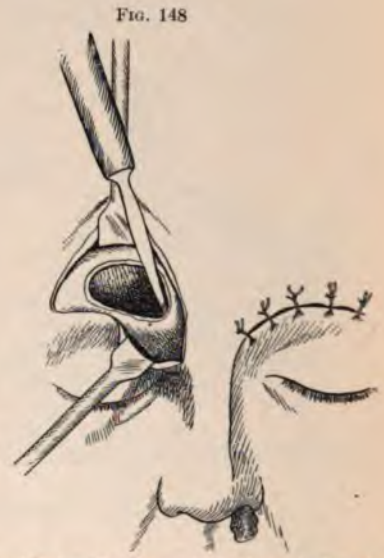

Fig. 147.—The intranasal operation of Halle completed. The floor of the frontal sinus is widely opened and permits curettage and free drainage of the sinus.

Fig. 148.—The Hajek-Luc operation. The anterior wall of the frontal sinus is removed, and the anterior ethmoidal cells are being removed through the floor of the frontal sinus with a curette. The left side has been operated, a gauze wick introduced through the anterior ethmoidal wound and drawn out through the nostril.

(*d*) An incision is made, beginning at the temporal end of the eyebrow and extending to the median line of the head. The second incision is begun where the first leaves off, and extends upward as far as the upper limit of the frontal sinus, a fact which should be determined beforehand by skiagraphy.

(*e*) The skin and periosteum within this triangular incision are turned upward, thus exposing the outer plate of the frontal bone.

(*f*) A liberal portion of the bone is then chiselled away, thus exposing the frontal sinus to inspection and probe examination.

(*g*) After determining the outline of the sinus and the degree and location of pathological lesions, the morbid material is removed with a curette, and if bony septa are present they are broken down (Fig. 148).

(*h*) The frontonasal canal must be enlarged as much as possible, to establish free drainage into the nose. This is done by breaking down

the anterior ethmoidal cells with a curette, through the floor of the frontal sinus (Fig. 148).

(*i*) A large rubber tube is inserted into the frontonasal wound and left in position for several weeks, or until all discharge ceases. The nasal end of the rubber tube is seized with forceps from time to time, and moved up and down, to prevent adhesions. When all discharge ceases the tube is withdrawn through the nose.

(*j*) After inserting the rubber tube into the frontonasal opening the external wound is closed and left to heal by primary intention.

Advantages of the Operation.—The advantages of this method of operating are: (1) It avoids disfigurement, as the wound heals by primary intention; (2) the frontonasal canal is enlarged, the anterior ethmoidal cells eradicated; and (3) as they are invariably involved in frontal sinuitis, this operation is advantageous, because they are opened and drained in its performance.

Disadvantages of the Operation.—Relapse occurs in about 50 per cent. of the cases, because the curettement cannot be done thoroughly on account of the incomplete removal of the anterior wall. Suppuration of the scalp has been reported, and the operation has been followed by sinuitis on the opposite side. Severe intracranial complications have also been reported, Tilley citing one death in 5 cases.

Lermoyez reports 9 cases with 8 relapses; 5 of the cases were subsequently cured by Kuhnt's operation, 1 by the repetition of the Hajek-Luc operation, while 2 died of meningitis (slow septicemia). It appears, therefore, that this method, while apparently very simple, is sometimes followed by very serious sequels. In view of these facts, it is usually better to adopt Kuhnt's operation, or at least a combination of the two. Personally, I believe this operation fails in such a large percentage of cases because the obstruction in the "vicious circle" of the nose is not removed; indeed, it is probable that this latter procedure alone would have given far better results than that given in the above statistics for the Hajek-Luc operation.

Kuhnt's Operation.—The object of Kuhnt's operation is to obliterate the frontal sinus by granulation from the bottom of the cavity. He resects the entire anterior wall (Hajek-Luc removes only a portion of it) and a portion of the floor or orbital wall. Curettement is thoroughly performed, but the frontonasal canal is not disturbed, as to do so may lead to reinfection of the sinus from the nasal fossa. Kuhnt does not close the external wound, but leaves it open for the introduction of the dressings and for drainage. A cure takes place in from three to six weeks. Relapse and sequels are rare, and recovery is the rule.

Disadvantages. (1) External drainage and dressings must be continued for several weeks. (2) When a cure is accomplished the patient is more or less disfigured. (3) The anterior ethmoidal cells are unopened, though they are always simultaneously involved. (4) Diplopia has frequently followed, from injury of the pulley of the superior oblique muscle, or from inflammatory infiltration about the pulley or within the muscle.

In America there are few patients who would tolerate the disfigurement attending the operation. Suits for malpractice would likely follow in a small percentage of the cases. The method is surgically correct, but unless the life of the patient is in immediate danger the surgeon is not justified in performing it. If this method of operating is elected the patient should be plainly informed as to the probable disfigurement, and his consent obtained before operating.

The Kuhnt-Luc Operation.—This operation is a combination of the method of Kuhnt and Hajek-Luc and consists in the free removal of the anterior wall of the frontal sinus, the enlargement of the frontonasal canal, and the introduction of the funnel-shaped rubber tube, together with a closure of the primary skin incision. This gives a fairly good cosmetic result and frontonasal drainage and ablation of the anterior ethmoidal cells, as in the Hajek-Luc operation, while it avoids, in a measure, the disfigurement attending external drainage, as practised by Kuhnt. There is more or less depression of the skin caused by the removal of the bone, but this can be corrected, in a measure, by subsequent paraffin injections.

The Osteoplastic Operation.—A modification of the operation just detailed consists in making an osteoplastic flap instead of chiselling away the outer bony wall. The bony flap is formed by making a narrow incision with a V-shaped chisel along the upper border of the supraorbital ridge, for the whole length of the sinus. This incision may also be made with a narrow-bladed rongeur forceps, or the De Vilbiss bone-cutting forceps. After the bony incision is made it is enlarged somewhat at either extremity to admit two rongeur forceps, by means of which the bony plate is broken off and left attached to the soft tissue. Considerable care must be exercised in handling the bony flap and soft tissues while they are being retracted, lest they be separated. The next step in the operation consists in the incision of the membranous lining of the sinus and the removal of the floor of the sinus. This is followed by a very thorough curettement of the anterior ethmoidal sinuses through the floor of the frontal sinus. After carefully cleansing the sinuses the wound is packed with gauze moistened with the compound tincture of benzoin. The external wound is closed with sutures, and on the fifth or sixth day one or two of the centre stitches is removed and the dressing taken out.

The object of this method of operating is the same as that of Kuhnt's operation. The eye symptoms are also the same. As Canfield has pointed out, there may be some deformity on account of the osteoplastic flap being lifted outward at its lower border by adhesions at the upper border of the bone flap to the posterior wall of the sinus, and subsequent contraction of the same. Again, the lower border of the osteoplastic flap is lifted outward somewhat by the removal of the gauze dressing. The lower border of the osteoplastic flap thus dislocated sometimes forms a ridge, which may be removed or corrected by a secondary operation. I see no reason why the wound should be packed as described. A better plan would be to pass a small wick of gauze through the enlarged

frontonasal opening, retaining it in position for a few days, and then withdrawn altogether. This would obviate opening the external incision, as recommended, and would give a better cosmetic effect. A thorough exenteration of the anterior ethmoidal cells and the establishment of good drainage will nearly always be followed by a cure of the disease. (See "Vicious Circle.")

The Killian Operation.—*Technique.*—After having prepared the field of operation, and having administered a general anesthetic, an incision is made through the eyebrow (previously shaved), beginning at its temporal end and extending to the median line at the root of the nose, then curving downward and outward below the base of the nasal bone

FIG. 149

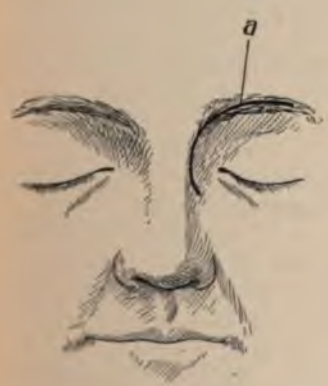

FIG. 150

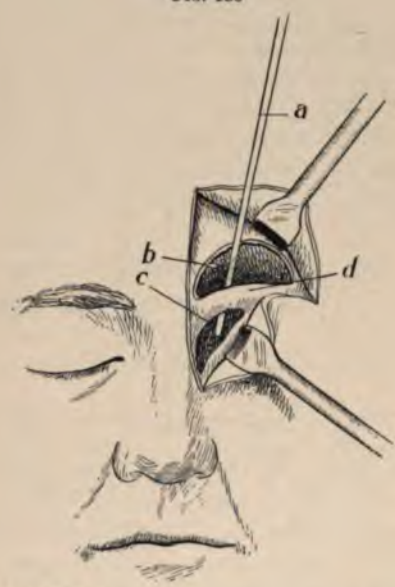

FIG. 149.—The incision for the Killian frontal sinus operation.

FIG. 150.—The Killian frontal sinus operation. *a*, probe introduced into the *b* frontal sinus and through the surgical opening in its floor; *c*, the tip of the probe showing through the surgical opening on the lateral wall of the bridge of the nose.

(Fig. 149). A second incision may be made if the frontal sinus is very large, extending upward from the median line at the root of the nose, as far as the upper limit of the frontal sinus, as shown by the skiagraph or by transillumination (Fig. 150).

The periosteal incisions are two in number. The upper one is made parallel with the supra-orbital margin and 5 mm. above it, extending from the temporal end of the skin incision to the median line of the nasal bones. It may be extended upward to the median line as far as the secondary skin incision. The second periosteal incision begins internal to the attachment of the pulley of the superior oblique muscle (Fig. 150 *d*), passes inward, then curves downward and outward, following the direction

of the skin incision around the inner canthus of the eye. This incision passes over the processus frontalis of the maxillary bone.

The soft parts, including the periosteum, are lifted from the bone, thus forming the skin and periosteal flaps, with the exception of the periosteum covering the superciliary ridge, where it is left intact to prevent the dislodgement of the pulley of the superior oblique muscle.

The frontonasal process and neighboring bone are chiselled away, thus leaving the bridge of bone, the superciliary ridge of the orbit. The entire anterior wall of the frontal sinus is removed with a chisel and rongeur forceps (Fig. 150).

The cavity of the sinus thus exposed should be thoroughly inspected and curetted in all its ramifications. Killian insists that when the anterior bony wall is removed the mucous membrane should not at once be disturbed, but that it should be left intact as long as possible, so as to avoid unnecessary infection of the wound. He makes a small preliminary opening through the bone, and then with a probe, introduced between the bone and mucoperiosteum, determines the limitations of the frontal sinus. Having done this, he proceeds to remove all the bone necessary for its complete exposure. He then opens the membranous sinus and proceeds to inspect and curette it according to the conditions present.

Fig. 151

Ostrum's localizer for the pulley of the superior oblique muscle.

The next step in the operation consists in the removal of the floor of the sinus, leaving a bridge of bone 5 or 6 mm. wide above the supraorbital margin. This bridge is shown in Fig. 150 *d*. As the operation is one wherein there is some danger of injurying the pulley of the superior oblique muscle, great care should be exercised to avoid it. As the pulley is variously located, this is not an easy matter. Dr. Ostrum has devised a pulley marker (Fig. 151), which may be applied to the tissues marking the location of the pulley, so that in the event of its detachment it may be sutured to the marked point, and thus prevent strabismus.

The opening around the processus frontalis may be enlarged upward and backward, to afford a better field for the curettement of the other sinuses, especially the ethmoidal and sphenoidal. Still having regard for the nasal mucous membrane, the curette is introduced through the opening made by the removal of the processus frontalis (Fig. 150), and the curettement of the ethmoidal and sphenoidal cells is performed. The limits of the ethmoidal cells are not difficult to make out with the curette, as the septa between the cells are usually very thin and easily broken down. The bone of the os planum and of the cranial plates is of greater density and resistance, and need not be mistaken for the septa between the cells.

As the hemorrhage is considerable, the operator must depend upon his knowledge of the anatomical relations, the conditions of the diseased parts, and his sense of touch, rather than upon sight in exenterating the ethmoidal and sphenoidal cells. Thoroughly cleanse the wound by irrigations with normal salt or boracic acid solution, then dust with iodoform powder, and close the skin and periosteal incisions with sutures.

A point in the after-treatment insisted upon by Killian is, that the patient should be placed upon his healthy side and forbidden to blow his nose. He must aspirate the secretions from the nose, and the nasal cavity should be inspected daily, carefully dressed, and exuberant granulations touched with the nit ate of silver.

A few days after the operation, if secretions still come from the sinus, gentle pressure over the skin should be made to force it into the nasal cavity. The patient should be made to sniff or aspirate it into his throat. He should not be allowed to blow his nose, as to do so might force infected matter into the frontal cavity The deformity following the operation is usually of moderate degree, and often becomes less conspicuous after a few months. The frontal sinus becomes more and more filled with granulation tissue, and the orbital fat pushes upward through the open floor of the sinus. In this way the depression becomes fairly well filled, except when the sinus is very large and deep. When the sinus is large and deep the disfigurement may be very great

This radical method of procedure is less liable to injure the pulley of the superior oblique muscle than the Kuhnt-Luc operation, or the Kuhnt operation, on account of the manner in which the periosteal incision was made, the periosteum over the superciliary ridge serving to hold the pulley in its place.

Taking all the facts into consideration, if the case is complicated by ethmoidal and sphenoidal disease and an external operation is deemed necessary, the Killian operation is the safest and least disfiguring of the external operations.

Of seventy-five cases of frontal sinuitis in which the clinical diagnosis was confirmed by skiagraphy, in only three (4 per cent.) did I find it necessary to perform the Killian operation, the others being cured by giving surgical attention to the structures within the "vicious circle" of the nose. Of the seven Killian operations performed by me six were cured, one not benefited. The deformity was almost nil except in one case.

THE SURGERY OF THE MAXILLARY SINUS.

Intranasal Operations.—The intranasal surgery of the antrum may include (*a*) the structures within the "key," or "vicious circle," and (*b*) the inferior turbinated body and the naso-antral wall. If the infundibulum is blocked by morbid tissue or by anatomical peculiarities, the same intranasal operation as described for frontal sinuitis may be performed (p. 205). In exceptional cases this will be sufficient to establish a healthy condition of the mucous membrane of the sinus. If, however, the mucous

membrane has undergone marked degenerative changes, it is usually necessary to remove the anterior end of the inferior turbinated body and the naso-antral wall, or to perform an extranasal operation, as the Caldwell-Luc or the Denker operation.

FIG. 152

Krause's antrum trocar with obturator.

Removal of the Naso-antral Wall.—This operation was first performed by Rethi, and has had many advocates since then. Clinical experience has shown that a small opening in the naso-antral wall quickly closes, whereas, a large one remains open permanently. Puncture and irrigation through a Krause cannula (Fig. 152) are often sufficient to effect a cure in acute and subacute inflammations of the sinus. The puncture should be made beneath the inferior turbinated body, as shown in Fig. 123. The cannula may be introduced daily under cocaine anesthesia, with little

FIG. 153

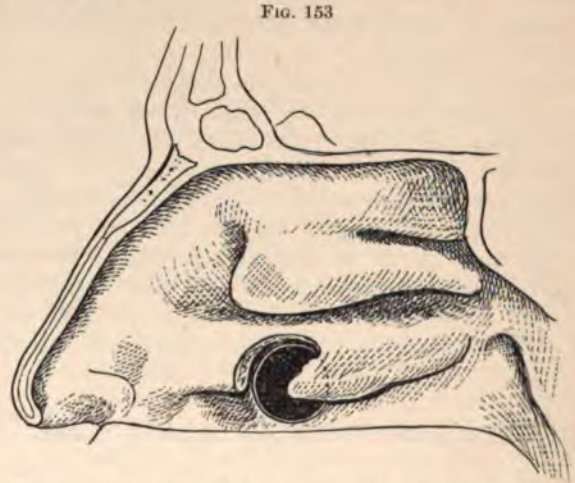

Vail's maxillary antrum operation. The fragment of the turbinal extending over the naso-antral opening should be removed with biting forceps. Vail prefers this method wherein a portion of the inferior turbinal is removed with the saw as it conserves the inferior turbinal function.

discomfort to the patient. The irrigating solution may range all the way from normal salt and boric acid solutions to the more irritating solutions of zinc and iodine. The usefulness of this procedure is largely limited to diagnosis, though it has some therapeutic value as well.

Many instruments have been devised for the removal of the naso-antral wall, some of which enable the operator to do the work with ease and precision. The instruments which have given the best satisfaction are Vail's saw, Ostrum's forward cutting forceps, Wells' trocar and cannula rasp, and Corwin's chisels.

Fig. 154

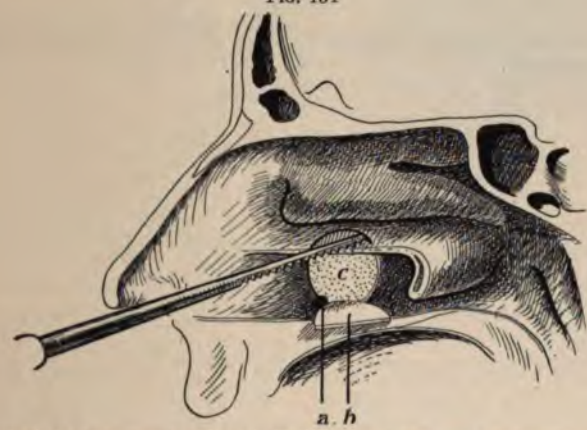

The removal of the naso-antral wall with Vail's convex saw. *a*, mucous membrane flap dissected from the naso-antral wall to be turned on to the floor of the antrum; *b*, puncture through which the saw is introduced; *c*, the bony naso-antral wall removed with Vail's saw.

Vail's Operation.—Vail's is perhaps the most ingenious and practical method for the removal of the naso-antral wall. His saw is slightly curved on the flat, and when introduced obliquely through the naso-antral wall makes a circular or oval incision, thus removing a large portion of the wall (Fig. 154), separating the nasal chamber from the antrum.

Technique.—(*a*) Local anesthesia of the inferior turbinal and of the inferior and middle meatuses.

(*b*) Remove the anterior half of the inferior turbinated body with the swivel knife or with scissors, or with the saw as it removes the naso-antral wall (Fig. 153).

Fig. 155

Vail's antrum saw.

(*c*) Puncture the naso-antral wall near the floor of the nose with Vail's perforator.

(*d*) Introduce the saw (Fig. 155) through the puncture and then make the circular or oval incision shown in Figs. 153 and 154. While the saw has a tendency to describe a circle, the size of the opening may be

regulated by the operator, as the bone is thin. The opening should be made as large as possible, to overcome the tendency to closure.

(*e*) If a mucous membrane flap is to be turned into the antrum to cover its floor, its anterior and posterior boundaries should be incised with a right angle knife or with the author's specially devised

Fig. 156

The author's right-angle knife.

swivel knife (Fig. 83). The upper boundary of the flap is made when the inferior turbinal is removed (Fig. 154). The mucoperiosteal flap should be separated from its bony attachment with a small periosteal elevator. Having separated the flap, the saw is introduced and the button of bone removed as described in the preceding paragraph, after which the flap is turned on to the floor of the antrum, which has been previously curetted to remove the granulation tissue. The flap hastens the process of regeneration and epidermization.

(*f*) The first dressing consists of iodoform gauze loosely packed in the maxillary sinus. It should be removed in from twenty-four to forty-eight hours.

Fig. 157

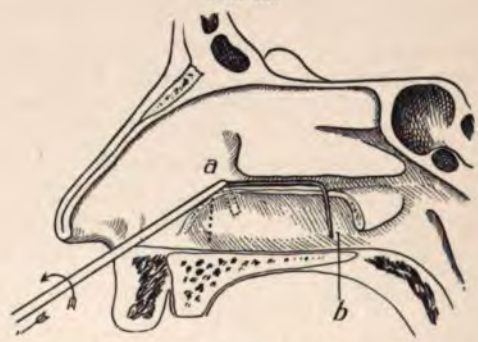

The author's method of removing the naso-antral wall with the turbinitome, after the removal of the anterior portion of the inferior turbinated body. The turbinitome is introduced through the naso-antral wall at *b*, cuts upward and then forward to *a*, with the right angle blade turned horizontally into the maxillary antrum. When the anterior wall of the antrum is reached at *a* the blade is rotated downward as shown in the illustration and pulled forward, making the cut indicated by the perpendicular dotted line.

(*g*) In the after-treatment gauze dressings should not be used. The cavity should be left open for drainage and ventilation. Every time the patient blows his nose he blows the antrum. The case should be watched, and if exuberant granulations form, they should be promptly reduced by the application of dehydrated chromic acid crystals or with some other caustic.

The Author's Operation.—(*a*) Local anesthesia.

(*b*) Remove the anterior half of the inferior turbinal with the author's right-angle turbinal knife (Fig. 156). The knife should engage the turbinal at about its middle, and then be drawn forward to its anterior extremity, thus removing the anterior half with one cut of the instrument.

Fig. 158

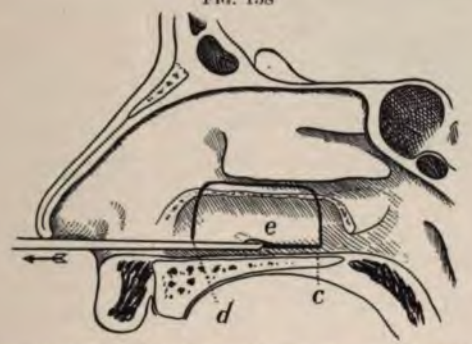

Completing the removal of the naso-antral wall *e* with the author's turbinotome. The right-angle blade is introduced at the inferior portion of the posterior perpendicular incision *c*, and drawn forward along the floor of the nose to *d*.

(*c*) Introduce the same knife through the naso-antral wall at the posterior limit of the antrum near the floor of the nose. Then make an upward cut, a forward and a downward cut, as shown in Fig. 157. The upward and forward cuts are made with the blade of the instrument at right angles to the naso-antral wall. When the forward cut is made the blade should be turned downward parallel with the naso-antral wall and pulled through it. The inferior incision remains to be made, and is done with the reverse knife, the knives coming in pairs. The knife is introduced into the posterior perpendicular incision (Fig. 158) at the floor of the nose, and drawn forward along the floor of the nose to the anterior perpendicular incision, thus completing the removal of the naso-antral wall. Should the knife fail to remove the thickened lower portion of the wall, it may be removed with the Grünwald or other bone forceps.

Fig. 159



Myles' reverse chisels.

(*d*) Loosely pack the antrum with iodoform gauze for from twenty-four to forty-eight hours.

(*e*) The after-treatment consists in the reduction of exuberant granulation tissue with caustics.

Other Methods.—Myles' barbed cannulas (Fig. 159) are well adapted to the removal of the naso-antral wall. The cannulas are pointed, and

may be pushed through the wall and pulled back again, the barbs cutting or tearing the thin bony partition away. This procedure is repeated until the whole or any part of the wall is removed.

Fig. 160



Corwin's antrum chisel.

Fig. 161



Corwin's antrum chisel.

Corwin's chisels (Figs. 160 and 161) are also admirable instruments for the removal of the wall. The projecting points enable the operator to engage them at an acute angle in the bony wall. Chisels without these points are not easily engaged, as they would glide over the surface of the mucous membrane.

Ostrum's forward cutting forceps (Fig. 162) may be used after puncturing the naso-antral wall. It posseses the advantage of the forward cut, a point of no inconsiderable importance in view of the fact that the anterior angle of the antrum is usually the seat of the greatest morbid lesion.

Fig. 162

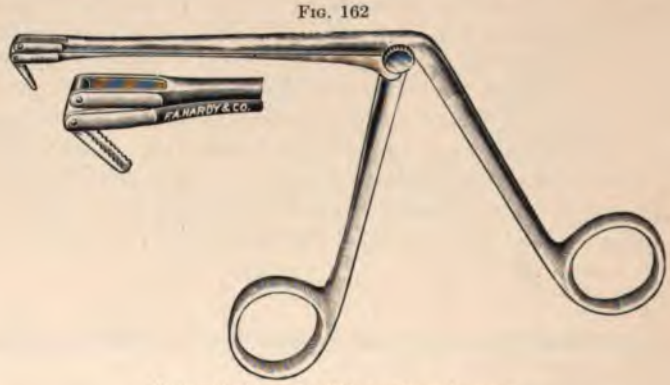

Ostrum's forward cutting antrum forceps.

Wells' combination antrum perforator and rasp file answers an admirable purpose for making an opening in the naso-antral wall. After perforating the wall the sharp obturator is removed and the rasp is used to remove the remaining portion of the wall, which it does with throughness. The fragments of mucous membrane remaining are removed with sharp biting forceps (Fig. 163).

The author's antrum swivel knife may be used to remove the naso-antral wall, as shown in Fig. 164.

Extranasal Operations.—(1) Alveolar; (2) Kuster; (3) Palatal; (4) Caldwell-Luc; (5) Denker; (6) Jansen.

1. **The Alveolar or Cooper Operation.**—The alveolar operation was for a long time a popular procedure. Tilley, of London, reports that of 300 cases of antral disease seen during ten years, only one had sound teeth.

Fig. 163



Wells' trocar cannula rasp for removing the naso-antral wall.

Fig. 164

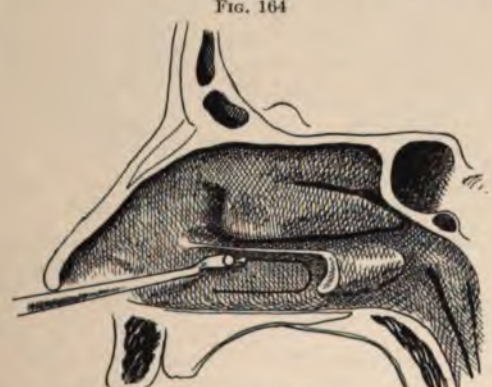

Showing the removal of the naso-antral wall with the author's antrum swivel knife, the anterior two-thirds of the inferior turbinal being previously removed. The removal is inadequate for old, chronic cases.

He reports that of 27 cases drained by the alveolar route, 15 persisted in the use of tube and irrigation for from six months to ten years. Of these, 5 afterward elected the radical operation, which was followed by complete cure. Of 37 cases operated by the radical method, 34 were successful. He also says that the alveolar route is indicated in recent cases (of a few months' standing) and in chronic cases as a preliminary measure.

Of the alveolar methods, the removal of a carious tooth, usually the second bicuspid or the first or second molar, is attended by the most happy results. It is obvious, however, that this method is only applicable when there is positive evidence that the tooth is diseased beyond hope of repair. The conditions are rare, indeed, that justify the removal of a tooth that could be successfully treated by a dentist. Even should it be admitted that more perfect drainage can be obtained by the removal of a tooth, there are still other methods of establishing good drainage which do not require the interference with an important physiological organ, or other essential structure of the head. Drainage by the removal of a tooth should, therefore, be limited to those cases in which a competent dentist states that the tooth cannot be saved, or it can be demonstrated that there is a carious fistula extending from it to the antral cavity. In such cases the tooth may be removed, and the opening thus made enlarged and its walls rendered smooth. Daily irrigations with warm boric acid solution may be used until the discharge ceases. The alveolar opening should be closed with a strip of gauze, saturated with the compound tincture of benzoin, until healing occurs, or with a tube made for the purpose.

2. **The Kuster Operation.**—This operation has been in much favor, as the interior of the antrum of Highmore is thereby exposed, permitting inspection and curettement of its cavity. The operation consists in the removal of a major portion of the anterior wall of the antrum, as shown by Fig. 168 *a* and *b*. The opening is usually limited to the area of thin bone of the canine fossa, and should be large enough to admit the introduction of the index finger. With the head mirror, light is reflected into the cavity and its walls examined. The portion of the cavity which cannot be inspected should be thoroughly explored with a curved probe.

If necrotic areas and granulation tissue are found they should be removed by thorough curettement. The preliminary step of the operation consists in the elevation of the upper lip and an incision at the labiogingival junction (Fig. 165). The incision is carried through the periosteum, and should be one and one-half inches in length. The periosteum is then dissected upward over the canine fossa and the upper lip pulled toward the eye with a retractor, after which the anterior wall should be removed with a chisel and rongeur bone forceps. The cavity should then be explored with a probe and the diseased mucous membrane and necrotic bone removed with the curette. If the antrum is divided by septa they should be broken down to convert it into one large cavity.

Having thoroughly removed the morbid tissue the sinus is firmly packed with gauze saturated with the compound tincture of benzoin, which may be left in position for six or eight days if the granulations are excessive. The end of the gauze should protrude through the labiogingival incision to prevent closure of the wound. If there is marked suppuration the cavity should be irrigated daily and loosely packed to promote drainage. When complete healing has taken place the dressings are discontinued and the labiogingival opening allowed to close.

3. **The Palatal Operation.**—The palatal route may be dismissed without detailed description, as it is the most objectionable of all, being indirect and easily invaded by food and bacteria. It should be considered only when perforation is already present in this region as a result of a malignant or other disease.

4. **The Caldwell-Luc Operation.**—This operation is, in most cases, preferable to the Kuster operation. By it the antrum is exposed as in the Kuster operation, and a large opening made through the naso-antral wall. The opening may be made with forceps, Vail's saw, Corwin's chisels or Myles' barbed cannulas through the nasal orifice. Preliminary to this, however, the anterior two-thirds of the inferior turbinal should be removed. In making the naso-antral opening shown in

Fig. 165

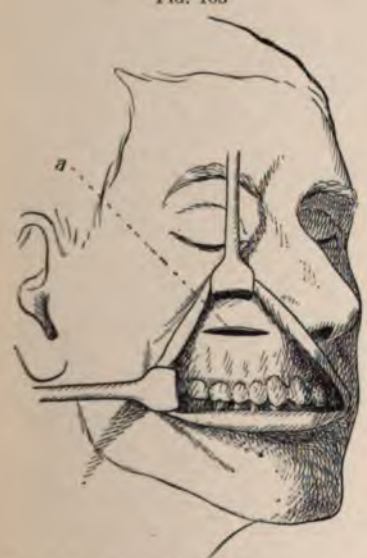

Fig. 166

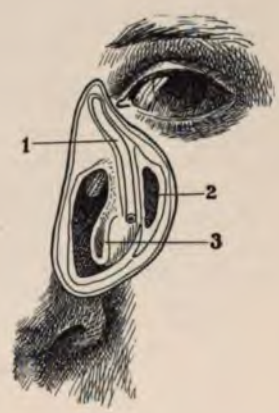

Fig. 165.—The Caldwell-Luc operation. *a*, the incision at the labiogingival junction.

Fig. 166.—Showing the relation of the ductus lacrymalis to the inferior turbinated body. 1, the ductus lacrymalis; 2, the maxillary sinus; 3, the inferior turbinated body. (After Bardeleben.)

Fig. 167, care should be exercised to avoid injuring the lacrymal canal, which opens beneath and near the anterior end of the inferior turbinated body and passes forward and upward to the inner canthus of the eye (Fig. 166). In other words, the naso-antral opening should not be extended too far forward.

Having completed the removal of the canine and noso-antral walls, and having removed all diseased tissue from the antrum, the cavity should be lightly packed with a strip of gauze, the end of which is brought out through the nose. The labiogingival incision should be sutured (Fig. 167) and allowed to heal by first intention. After the first dressing is removed it is usually unnecessary to repack the antrum, drainage being very successfully accomplished through the naso-antral wound. At the

end of the second day the gauze dressing should be removed through the nose. The secretions may be removed by forcibly blowing the nose.

It has been claimed that it is unnecessary to do either the Kuster or the Caldwell-Luc operation, the simple opening through the naso-antral wall being quite sufficient. That the naso-antral opening is sufficient in a number of cases is true. In other cases, in which there is a pronounced degeneration of the mucous membrane and caries of the bony walls of the antrum it is necessary to do the Kuster operation first, and to explore the antrum by ocular inspection and curettement, a procedure which cannot be successfully done through the nose. The

Fig. 167

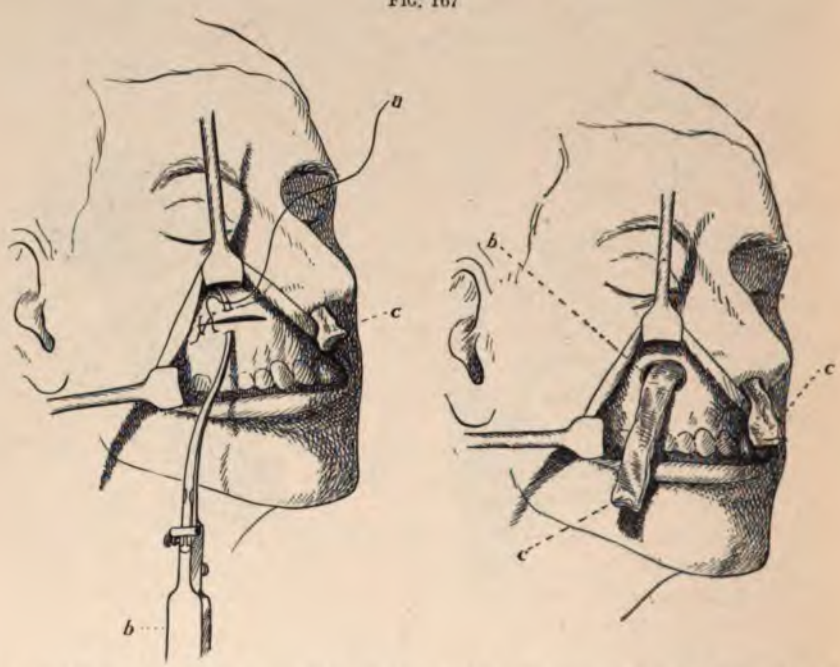

The Caldwell-Luc operation. *a b*, closing the labiogingival incision with the Reverden needle (*b*); *b*, the anterior wall (canine fossa) of the maxillary antrum removed; *c c*, a strip of gauze extending through the maxillary antrum into the nasal chamber, the naso-antral wall being removed.

Caldwell-Luc operation (a combination of the two) should, therefore, be elected in those cases in which there is pronounced suppuration with granulation tissue or polypi in the middle meatus of the nose. If these procedures are carried out properly and the suppuration continues, it is probable that the ethmoidal and possibly the frontal sinuses are also involved, and that some of the secretions from them drain into the antrum. In that event proper attention should be given to the other sinuses.

5. **The Denker Operation.**—*Indications.*—This operation is indicated in obstinate inflammatory disease of the maxillary sinus, which does not

yield either to the intranasal or to the Caldwell-Luc operation. In such a case the mucous membrane of the sinus may be very edematous and the seat of extensive granulations.

The anterior angle of the sinus adjacent to the nose is often inaccessible to the curette, either through the nasal or the canine fossa wound, hence the failure of the intranasal and the Caldwell-Luc operations. As the edematous membrane and the granulations must be thoroughly removed to effect a cure, an operation should be adopted that will thoroughly expose the entire cavity to curettement. The Denker operation does it, and it accordingly has a place in the treatment of selected obstinate cases.

Fig. 168

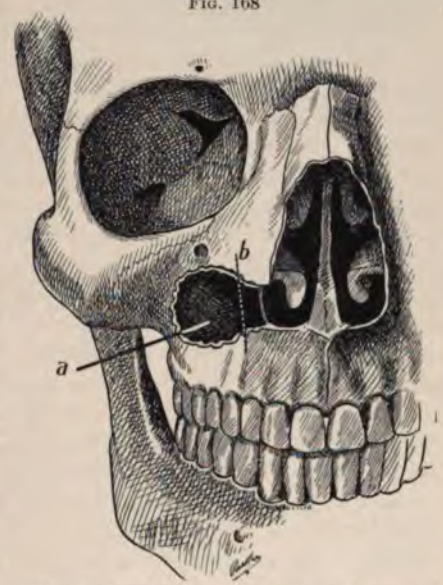

The Denker-Antrum operation. *a*, the area of bone removed in the Kuster and the Caldwell-Luc operations. In the Denker operation additional bone at the right of the dotted line (*b*) is removed, from *b* to the pyriform aperture.

Technique. — (*a*) A general anesthetic should be given.

(*b*) The patient should be placed in Rose's position, with the head hanging over the end of the table.

(*c*) Postnasal tampons should be introduced to keep the blood from the throat and trachea.

(*d*) Make the labiogingival incision as in the Caldwell-Luc operation, extending it to the median line (Fig. 167).

(*e*) Elevate the soft tissues and periosteum over the canine fossa.

(*f*) Remove the anterior wall (canine fossa) of the maxillary sinus as in the Kuster and Caldwell-Luc operations, and then remove the bridge of bone between the canine fossa and the lower portion of the pyriform opening of the nose, as shown in Fig. 168. By thus extending the bony wound the anterior angle of the sinus is exposed to operative interference.

(*g*) Through the opening thus made remove the edematous membrane and granulation tissue wherever they may be found.

(*h*) Elevate the mucoperiosteum of the inferior meatus of the nose, and of the inferior turbinated body, with a small flat elevator so curved as to adapt it to the anatomical configuration of the parts.

(*i*) Incise the mucoperiosteum thus elevated and convert it into a rectangular flap to be turned outward on the floor of the sinus.

(*j*) Remove the bony wall and the anterior portion of the denuded inferior turbinated bone with bone-cutting forceps, the mucoperiosteal flap being turned into the nasal chamber to prevent injuring it with the bone forceps. The opening through the naso-antral wall should be

quite large, as in the Caldwell-Luc operation. Otherwise it will soon become closed and defeat the purpose of the operation.

(*k*) Turn the mucoperiosteal flap on to the sinus floor and hold it in position for twenty-four to forty-eight hours with an iodoform gauze dressing.

(*l*) The after treatment, as in the Caldwell-Luc operation, consists in watching the case and reducing exuberant granulations with caustics as soon as they appear.

6. **The Jansen Operation.**—Jansen claims that if one of the sinuses is affected, all on that side of the head are affected; he therefore directs his attention to the entire labyrinth rather than to a particular subdivision of it. His position is probably extreme, although all the sinuses in many cases are more or less involved. The maxillary sinus may act as a reservoir, receiving the secretions from the anterior ethmoidal and frontal sinuses; or the sphenoidal sinus may be the primary seat of the disease, and the secretions from it discharging upon the upper surface of the middle turbinated body may excite a secondary sinuitis in the other sinuses. A more rational explanation is that an obstructive lesion in the region of the middle turbinated body and the infundibulum often results in an interference with the drainage and ventilation of all the sinuses. The middle turbinal and the infundibulum often form the "key" to the etiology of sinus inflammations.

In complicated cases, where all, or nearly all, of the sinuses are involved, either primarily or secondarily, an effort should be made to determine in which group of cells the lesion has its focal centre, and whether the obstruction is within the "vicious circle" of the nose. The operative procedure should then be directed to the particular group of cells involved, or to the hiatus and infundibulum if they are obstructed. Having established ventilation and drainage, the cells will often clear up with little or no other treatment. In other cases it is necessary to exenterate the entire labyrinth before a cure is effected. It is in these cases that Jansen's operation, or some modification of it, may be employed. This operation is a modification or an elaboration of the Caldwell-Luc operation, and consists of the following steps:

(*a*) The mouth and teeth should be carefully scrubbed, and the labiogingival fossa packed with strips of gauze to keep the secretions away from the operative field and from the trachea.

(*b*) General anesthesia.

(*c* The head of the patient should hang over the table to keep the blood from entering the trachea.

(*d*) The incision is made as in the Kuster and Caldwell-Luc operations, and the periosteum and soft tissues are elevated over the canine fossa.

(*e*) The bony wall (canine fossa) of the sinus is removed with a chisel and rongeur forceps, thus exposing the cavity of the antrum to view. Palpation with the finger and exploration with the probe should also be practised. The diseased areas should be curetted, leaving as much as possible of the healthy mucous membrane, as it will be needed in the final regenerative process following the operation.

(*f*) A mucous membrane flap may be made by an incision corresponding to the attachment of the inferior turbinated body, and one along the floor of the sinus, the two incisions uniting posteriorly, thus forming a long tongue-shaped flap. The tip of the flap is drawn forward and stitched to the buccal mucous membrane at the median extremity of the labiogingival incision. The bone of the middle and inferior turbinated bodies should be shelled out, leaving the mucous membrane of the nose as nearly intact as possible, to form a mucous membrane covering for the floor and anterior wall of the antrum. The little finger should be inserted into the nose for counterpressure while performing this step of the operation.

The ethmoidal cells are curetted through the naso-antral wall *via* the canine fossa. The sphenoidal sinus is likewise curetted through the same route. The posterior ethmoidal and sphenoidal sinuses may, however, be more easily curetted by the intranasal route.

Having curetted the posterior ethmoidal cells and the sphenoidal sinus through the naso-antral wall, and having made the mucous membrane flap referred to in the preceding paragraph, and having stitched it into place, the case is ready for the first dressing. A strip of gauze moistened with the compound tincture of benzoin should be loosely but carefully packed in the operated sinuses. If it is desired to leave the labiogingival incision open the gauze should be folded and left in the opening, as in the Kuster operation. If, on the other hand, the labiogingival incision is to be closed the end of the strip of gauze is placed in the naso-antral opening, a small suture attached to it, and brought out through the nostril. If this precaution is not taken it may be difficult to remove the dressing. The first dressing is left in position about five days. The wound is re-dressed every one or two days.

The case should be carefully inspected at frequent intervals, all exuberant granulations reduced by the application of caustics or the actual cautery, and everything done to promote a clean, healthy, regenerative process. The time required for complete healing varies from a few weeks to several months.

The operation seems to be a very radical one, attended by much danger, and to require great skill. The anatomical relations should be studied on the cadaver before attempting to operate on the living subject. Some writers, notably Onodi, oppose Jansen in his claims as to the accessibility of the sphenoid by this route. Onodi says that in twenty-five skulls he was only able to reach the sphenoidal sinus by the antral route in three. One of Jansen's former assistants told me that he was able to do so in all of the 200 skulls examined by him (Canfield).

A possible source of danger is the internal carotid artery which runs along the outer wall of the sphenoidal sinus. If there is necrosis at this point the curette might pass through and wound the artery and cause a fatal hemorrhage. Such an accident is a remote possibility. After a limited experience with this operation, my impression is that it would be better and safer to exenterate the ethmoidal and sphenoidal sinuses and do a Caldwell-Luc operation a few weeks subsequently.

As mentioned elsewhere, there is less liability to meningitis if the intranasal surgery is performed a few weeks prior to an external sinus operation. Furthermore, the intranasal route affords a more natural and a safer route to the posterior ethmoidal and sphenoidal sinuses.

The operation is needlessly crude, and the risk out of proportion to the good to be accomplished by it. A Caldwell-Luc and the intranasal operation upon the ethmoidal and sphenoidal sinuses is a more commendable mode of procedure in pansinuitis.

THE PARTIAL REMOVAL OF THE ETHMOIDAL CELLS.

In some cases a single ethmoidal cell may be the seat of infection and inflammation, and it alone may require surgical interference. The bulla ethmoidalis is sometimes affected while all the other cells are apparently healthy. Less frequently one of the other ethmoidal cells is involved, or the anterior cells may be the seat of infection while the posterior cells are free from infection, or the posterior cells may be affected and the anterior cells be normal. After locating the cell or cells involved, the middle turbinated body (middle concha), or a portion of it, may be removed and the exposed wall of the diseased cells broken down with a curette or a Grünwald biting forceps. The cell thus opened may close by granulation in the process of repair, thus necessitating repeated curettements before a cure is established.

If after repeated attempts a cure is not effected, it may become necessary to perform a more complete operation.

THE EXENTERATION OF THE ETHMOID CELLS VIA THE INTRANASAL ROUTE.

The complete removal of the anterior and posterior ethmoidal cells, while practically feasible, is often physically impossible, on account of the anatomical location of some of the cells. Some are inaccessible on account of the frontonasal process of the maxillary bone, and in some instances one of the anterior ethmoidal cells extends over the orbital cavity (Fig. 142) and is surgically inaccessible. I have occasionally operated upon cases in which the posterior cells extended backward along the side of the sphenoidal cells, and have seen anatomical specimens in which they extended behind the sphenoidal cells. For these and other reasons the total exenteration of the ethmoidal cells is not always practicable. Hence, when the term total exenteration is used in reference to these cells, the idea I wish to convey is that they are removed as completely as possible.

The indications for the complete exenteration of the ethmoidal cells is the presence of a persistent infection and inflammation of the mucous membrane of the entire group, which obstinately resists simpler methods of treatment.

Technique.—(*a*) First induce complete local anesthesia by the local application of a 10 per cent. solution of cocaine

(*b*) Remove the middle turbinated body as elsewhere described.

(*c*) Next sever the posterior and superior attachments of the ethmoidal cells with the author's right-angle knife (Fig. 156), as shown in Fig. 176. The knife should be introduced into the middle meatus of the nose with the blade pointing downward (Fig. 169), and when the anterior wall of the sphenoid is reached the blade should be turned directly outward and forced upward along the anterior wall of the sphenoid, severing the ethmoid cells from it. The blade is then drawn forward along the roof of the nose (Fig. 176), severing the cells from the plate of bone to which they are attached. The blade of the author's right-angle knife has a blunt end, and is of such length that it will not injure the orbital plate in making the incision just described, provided the operator exercises ordinary judgment and mechanical skill in using it.

Fig. 169

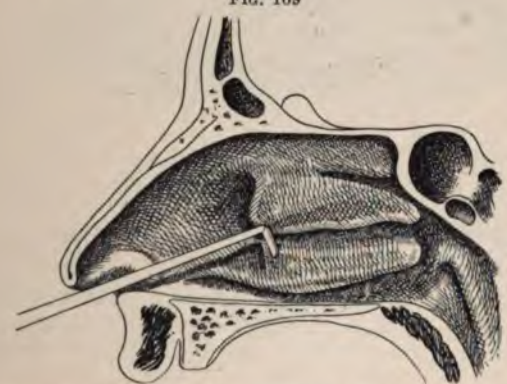

The author's right-angle turbinal knife introduced into the nasal chamber with its blade hanging downward.

(*d*) The orbital attachment of the cells remains to be overcome. This is, perhaps, most easily and safely accomplished with a curette. The intercellular walls are very thin and friable, and break down under the gentle application of the curette. The scraping or cutting surface of the curette should be directed outward against the orbital wall (Figs. 170 and 171) and drawn forward with short movements until the entire surface is comparatively smooth. The curettage should be so gently done that the mucous membrane and periosteum of the orbital wall are not injured or the orbital plate broken. This can be accomplished with comparative safety to the orbital contents by an experienced and skilful operator. An inexperienced or bungling operator might fracture or perforate the orbital plate and admit infectious microörganisms into the orbital cavity, with disastrous results. In an experience covering two hundred operations I have seen but one orbital involvement, and that was an emphysema of the eyelid, a condition which disappeared in forty-eight hours.

(*e*) The after-treatment is important, as the final success or failure of the operation will largely depend upon it. If the patient is operated on in a hospital, as, indeed, he should be, it may not be necessary to pack

the nose with gauze, provided the house surgeon is competent to pack it if hemorrhage occurs. If profuse and persistent hemorrhage follows the operation the upper portion of the nasal chamber should be packed at once, the packing being removed in from twelve to thirty-six hours. If the primary hemorrhage is profuse, but ceases after a half-hour, or

Fig. 170

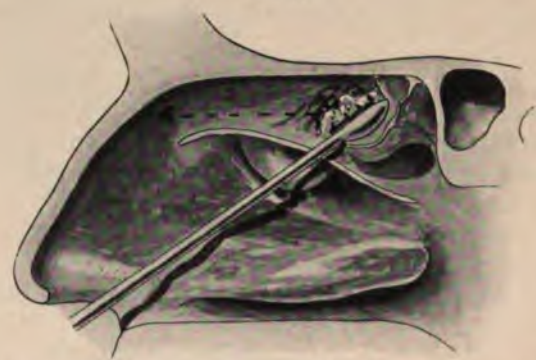

Curettage of the ethmoidal cells after the removal of the middle turbinated body. The cutting edge of the curette is directed upward and removes the cells from the cranial plate as far forward as the dotted line.

in less time, the nose should not be packed. Indeed, avoid placing a firmly packed dressing in the upper portion of the nasal chamber when the circumstances warrant it, as the packing may be a greater danger than the operation. A firm packing may fracture the orbital plate,

Fig. 171

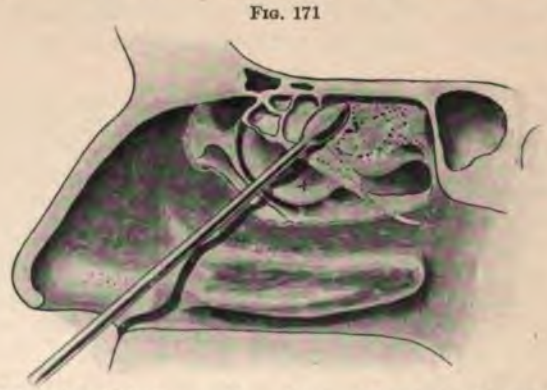

Curettage of the ethmoidal sinuses. Second step. The curette is turned outward against the orbital plate and breaks down the intercellular walls of the ethmoid cells, including the bulla ethmoidalis x and the line of attachment of the middle turbinated body.

cause a retention of the secretions which may be forced into the orbital cavity, or the secretions may undergo rapid retrograde changes, become absorbed, and cause toxemia. Drainage and ventilation of the operated area are prime requisites, and should be maintained if possible.

The area of operation should be loosely packed with cotton saturated

with a 10 per cent. aqueous or glycerin solution of ichthyol for thirty minutes daily for one to two weeks. If granulations form they should be touched with carbolic acid. If foci of suppuration persist the areas

Fig. 172

The author's middle turbinal knives.

should be probed to discover if there is a hidden cell from which the granulations spring. If such a cell is found its ostium of discharge should be enlarged and free drainage and ventilation established. The case should be watched several weeks, and in exceptional cases for months, or until all foci of infection are eradicated.

Turbinectomy with the Author's Knife.—Inasmuch as the partial or complete removal of the middle turbinated body is frequently necessary to relieve muscular asthenopia (imbalance of the extra-ocular or intra-ocular

Fig. 173

The first step of the removal of the middle turbinal with the author's turbinal knife.

muscles), and to establish drainage and ventilation of the nasal accessory sinuses, I have endeavored to devise some simple means to accomplish it. The turbinotome (Fig. 172), herewith presented, in a measure, solves the problem.

Technique of Turbinectomy.—(*a*) Cocaine anesthesia.

(*b*) Introduce the curved blade of the knife between the middle turbinal and the septum at the posterior extremity of the turbinated body (Fig. 173).

(*c*) Then draw it forward along the line of attachment to the anterior end of the middle turbinal, thus removing it in its entirety (Fig. 174).

(*d*) Remove the severed portion of the turbinal with dressing forceps.

(*e*) As the anterior and posterior ethmoidal arteries supply the middle turbinal, hemorrhage may be free and persistent. If the patient is in a hospital, no dressing other than a dusting powder of bismuth or bismuth-iodine need be applied. If, however, the patient is sent home, and is not easily accessible to the operating surgeon or his assistant, the space between the line of attachment of the turbinal and the septum should

Fig. 174

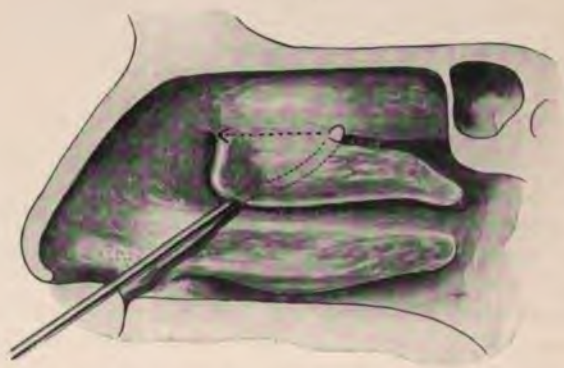

The removal of the middle turbinal with the author's turbinal knife.

be firmly packed with a strip of sterile gauze dusted with bismuth. This may be left in position for forty-eight hours. The nasal chamber should subsequently be kept free from secretions by daily irrigations with sterile normal salt solution or by packing the nose lightly with a 10 per cent. aqueous solution of ichthyol, which should be removed in twenty to thirty minutes.

The Author's Method of Removing the Ethmoidal Cells and Middle Turbinal En Masse.—As the ethmoidal cells have their chief fixed attachments on their outer (orbital) and upper (cranial) walls (Fig. 175) it is possible to remove them and the middle turbinal *en masse*. The advantage of this procedure consists in the availability of the removed specimen for inspection. When thus removed the mucous membrane and bony walls of the cells may be examined microscopically and macroscopically for pathological lesions. When the cells are exenterated with a biting forceps or curette, such examinations are impossible or greatly hindered. Inasmuch as our present knowledge of the diseased processes in this region is very imperfect, the value of a method whereby the tissues

may be removed *en masse* is obvious. With the knowledge thus obtained the surgeon will more quickly mature his judgment as to the morbid processes and the best methods of treatment.

I have removed the ethmoidal labyrinth by curettage (Fig. 170) in more than two hundred cases, and the clinical results have been uniformly satisfactory. The chief question involved is, Would a less radical exenteration have been equally satisfactory? Judging by the reports of other surgeons, I infer that they have been fairly successful with less radical work. Judging by my own experience, I have not had as good results with partial exenteration of the cells as I have by the more radical operation. Thus far I have seen no unfavorable results following two hundred radical exenterations of the ethmoidal sinuses. I feel justified therefore, in presenting this method of removing the ethmoidal cells and middle turbinated body *en masse*.

FIG. 175

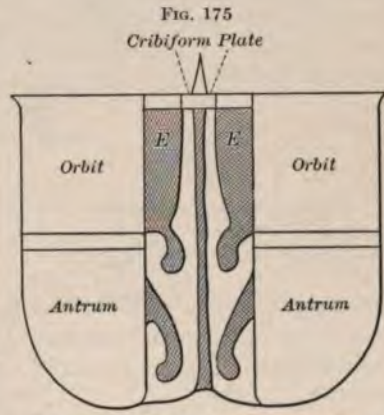

Schema showing the chief attachments of the ethmoidal cells *E E* to the cranial plate of the frontal above and to the inner orbital walls on the outer aspect. The ethmoid is not attached to the cribiform plate. It is obvious that if these two planes of attachment are severed that the ethmoid cells and the middle turbinals will be entirely detached.

Indications. — The total removal of the ethmoidal cells and middle turbinal seems to be indicated in chronic suppuration complicated by polypi, or a narrow or occluded olfactory fissure. When it is possible to widen the olfactory fissure sufficiently by the submucous resection of the septum, one indication for the radical exenteration of the ethmoidal labyrinth is removed. If, however, the suppuration and polypi continue in spite of the repeated incomplete operations with forceps or other instruments, the radical operation herewith given may be adopted. Another indication for the total removal of the ethmoidal cells consists in the persistent formation of plastic adhesions between the septum and outer wall of the nose after the incomplete operations. I have often seen such formations after the partial removal of the cells, and it was only after a complete exenteration that they ceased to form.

Caution.—It should be said that this operation should never be attempted by an inexperienced and unskilled surgeon. While an experienced and skilled surgeon may remove the ethmoidal cells from the cranial and orbital plates of bone with safety, one less experienced and skilled might break through either plate of bone and expose the cranial or orbital cavity to infection. I wish to state, however, that after a somewhat extended experience, I have had no difficulty in limiting the operation within the bounds of the cranial and orbital plates. I am guided by sight, the mental picture of the anatomical relations, and the sense of touch. The sense of touch is a very important guide, as the

resistance offered by the cranial and orbital plates is distinctly different from that offered by the intercellular walls. The cell walls are very friable, whereas the cranial (in particular) and the orbital plates are

Fig. 176

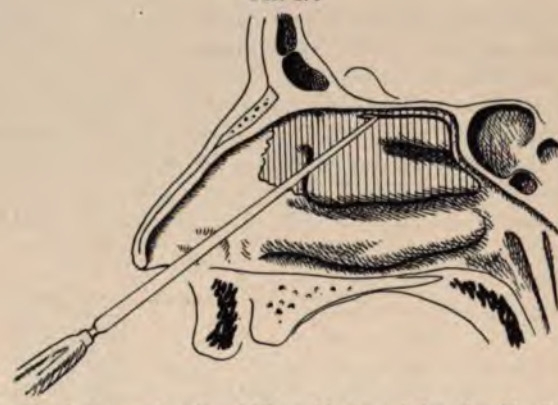

The author's method of removing the middle turbinate and the ethmoid cells en masse. The shaded lines indicate the area of the ethmoid cells, the author's right-angle ethmoid knife making the incision along the cranial plate.

firm and resisting. The orbital plate is quite thin, however, and should be attacked with great care and moderation.

Technique.—(*a*) Secure anesthesia with a freshly prepared 20 per cent. solution of cocaine.

Fig. 177

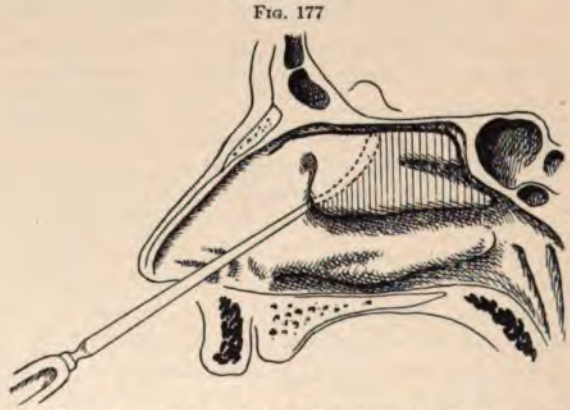

The incision along the orbital plate with the author's curved ethmoid or turbinal knife. The shaded lines indicate the area incised with the knife. The heavy black line beneath the roof of the nose is the line of incision previously made with the right-angle knife.

(*b*) Introduce the right-angle knife (Fig. 156) into the nasal chamber, with its blade pointing toward the floor of the nose (Fig. 169). When the posterior end of the middle turbinal is reached turn the blade outward until it stands horizontally.

(*c*) Then engage the blade at the posterior attachment of the middle turbinal and cut upward along the anterior wall of the sphenoid, thus severing the ethmoidal cells from it. When it has reached the cranial plate draw it forward, shaving the ethmoid cells from it until near the anterior end of the middle turbinal (Fig. 176).

At this point the tip of the blade should begin to lag behind the shank of the instrument, and finally slide from the tissues into the anterior space of the nasal chamber.

By this procedure the ethmoidal cells are severed from the cranial plate and from the anterior wall of the sphenoidal sinus.

(*d*) Next introduce the orbital plate knife beneath the posterior attachment of the middle turbinal (Fig. 177) and dissect upward along the anterior wall of the sphenoid to the cranial plate above, then dissect forward and sever the cells from the orbital plate until the whole outer attachment of the ethmoidal cells is separated, as shown by the area

FIG. 178

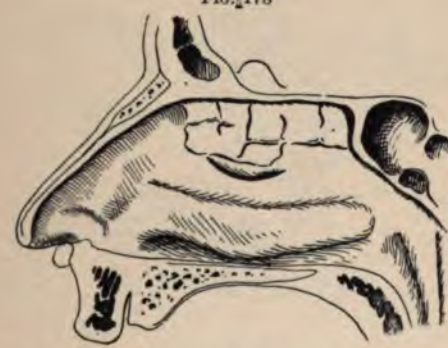

Schema showing the outlines of the ethmoid cells after their removal by the author's method.

covered by the shaded lines in Fig. 176). The major portion of the ethmoidal cells and middle turbinal are thereby completely severed from their attachments.

(*e*) Seize the anterior end of the middle turbinal with forceps and remove the severed mass from the nose. Fig. 178 shows the outline of the cells on the orbital wall after the removal of the mass. This area may be gently curetted to remove edematous or diseased membrane, and the remains of the bony intercellular walls. The cell walls are so friable that great delicacy of manipulation is necessary to remove them without breaking them in the operative procedure and in removing the mass from the nose.

After-treatment.—The patient should remain in bed for from one to three days, having the operated area gently mopped every four hours with a 10 per cent. aqueous solution of ichthyol to prevent infection and promote the outward osmotic flow of serum. At the end of three days a 10 per cent. glycerin solution of ichthyol may be used, as the tissues will then tolerate the more active osmotic action of the glycerin. By the

osmotic action of the glycerin and the antiseptic action of the ichthyol the wound may be kept clean and free from infection. Watch for granulations and adhesive processes, and check them by the cautious application of dehydrated crystals of chromic acid.

EXTERNAL OPERATIONS UPON THE ETHMOID SINUSES.

Moure's External Ethmoid Operation.—This operation may be performed in those cases in which extensive necrosis and polypi are present in the ethmoidal region, as it exposes the field of operation better than any other method of operation. It may also be used to expose large tumors in this region.

Technique.—(*a*) The operation should be performed under general anesthesia, though it may be done under local injections of Schleich's mixture combined with local cocaine anesthesia of the nasal mucous membrane.

Fig. 179

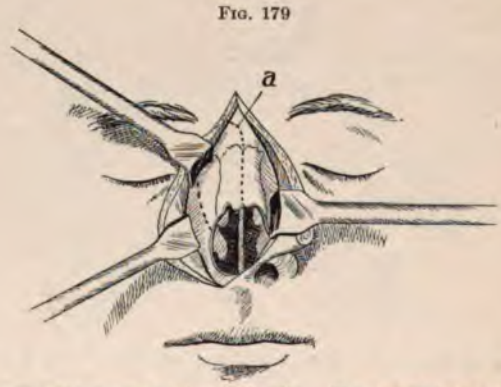

Moure's operation upon the anterior ethmoidal cells. The dotted line *a* indicates the area of bone removed from the lateral wall of the nose to expose the cells.

(*b*) Insert postnasal tampons, one in either nostril, to prevent the blood entering the trachea.

(*c*) Make an incision along the ridge of the nose from a point midway between the eyebrows, and extending it downward to the nasal opening on the side to be operated, at the junction of the cutaneous septum with the ala or wing of the nose.

(*d*) Elevate the soft tissues, including the periosteum, as shown in Fig. 179.

(*e*) Resect the nasal bone and the frontal process of the maxilla, as shown in the area encircled by the dotted line (*a*) in Fig. 179.

(*f*) Having thus exposed the ethmoidal labyrinth, the entire ethmoid region may be thoroughly exenterated with a curette.

If the disease is well advanced, that is to say, if there are polypi and granulations, every vestige of the cells should be removed. The cranial plate, the os planum (paper plate of ethmoid) or orbital wall,

and the lacrymal bone which is adjacent to the anterior cells should be gently but thoroughly curetted until they are smooth. In addition to these surfaces the ethmosphenoidal wall (posterior limit of the ethmoidal cells) should also be thoroughly curetted. If all these surfaces are cleared with the curette and the anterior and posterior ethmoidal labyrinths are separated from their attachments, the cells and the middle turbinated body may be removed through the nasal wound or through the anterior naris.

(*g*) The exenterated space should be packed with a strip of gauze in front of the postnasal tampon on the operated side, and the postnasal tampon removed from the other side.

(*h*) Close the skin and periosteal incision with fine silkworm sutures.

Fig. 180

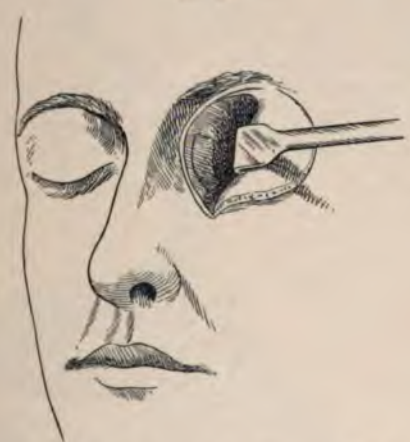

Exposure of the anterior ethmoidal cells through the inner wall of the orbit. This method of procedure is adapted to those cases complicated by orbital cellulitis.

(*i*) Watch the case, and should granulations spring up at any point touch them lightly with carbolic or chromic acid. Should points of suppuration be located, probing should be done with a view to tracing them to their sources. If it is found to be an overlooked or inaccessible cell, as an anterior ethmoidal extending over the orbital cavity or a posterior ethmoidal extending to the lateral side of or behind the sphenoidal sinus, steps should be taken to maintain a patulous opening for drainage purposes. All granulations should be removed from the point of suppuration as rapidly as they appear. Persistent after-treatment along this line will often be rewarded by a cure of the case.

Orbito-ethmoid Operation.—(*a*) Make the Killian incision and elevate the tissues and periosteum at the inner aspect of the orbit, as shown in Fig. 180. (*b*) Remove the nasoörbital plate of bone and curette the ethmoidal cells through the opening. The orbital cellular tissue should also be explored and the pus evacuated if present. Maintain external

drainage until the discharge ceases, and allow the wound to heal by granulation from the bottom.

FIG. 181

The Smithuison sphenoid forceps.

FIG. 182

Removing the anterior wall of the sphenoidal sinus with the Smithuison forceps. The distal blade of the forceps is introduced through the osteum sphenoidale and the bony wall removed by successive bites.

FIG. 183

Myles' reverse sphenoidal chisels.

SPHENOIDAL OPERATIONS.

The preliminary operative procedure for reaching the sphenoidal sinus consists of the complete ablation of the middle turbinated body, thus exposing the ostium sphenoidale to view.

The anterior wall of the sinus may be removed with biting forceps (Figs. 181 and 182) or with Myles' reverse chisels (Fig. 183). The ostium sphenoidale is situated in the upper portion of the anterior wall near the septum and appears as a round or oval fenestrum. The sinus should be explored through it with a blunt probe, to determine the condition of its mucous membrane. If it is thickened, soft or spongy, or covered with granulation tissue it should be carefully but thoroughly scraped with a dull curette. The operator should bear in mind that the walls of the sphenoidal cavity are very thin, and that there is danger of perforating them and transmitting infection to the dura mater, the optic nerve and vessels, and the sheath of the internal carotid artery. These accidents will not occur if ordinary care is exercised in carrying out the details of the operation. Should severe hemorrhage occur the sinus should be packed with iodoform gauze for twenty-four to forty-eight hours (T. Passmore Bereus).

CHAPTER XII.

NASAL NEUROSES. NASAL HYDRORRHEA. CEROBROSPINAL RHINORRHEA.

NEUROSES OF OLFACTION.

THE neuroses of olfaction are characterized by either (*a*) a perverted sense of smell (parosmia), (*b*) oversensitiveness to olfactory stimuli (hyperosmia), (*c*) a partial loss of the sense of smell (hyposmia), or (*d*) total loss of the sense of smell (anosmia).

Parosmia.—Parosmia is characterized by a perception of imaginary odors. The perversion of the sense of smell may be due to pathological changes in the olfactory brain centre. Inflammatory disease of the mucous membrane in the attic of the nose may also produce parosmia by overstimulating the nerve endings. It is usually found in central brain lesions, although it occasionally occurs in hysteria, hypochondria, epilepsy, insanity, and syphilis.

Hyperosmia.—Hyperosmia is characterized by an oversensitiveness to olfactory stimuli—that is, the perception of odors is exaggerated. The most delicate perfumes or odors not ordinarily perceived are recognized even to the point of unpleasantness. In some cases the perception of odors persists after the source of the odor is removed, and in this respect the condition approaches parosmia.

It may be due to an irritation of the olfactory lobes, hysteria, neurasthenia, hypochondria, sexual disorders in women (especially at the menstrual period), and to the lowered nervous forces accompanying wasting diseases.

Hyposmia.—Hyposmia is characterized by a partial loss of smell, either from an impairment of the mucous membrane of the attic of the nose, the nerve endings, the bulb, or the brain centre. The impairment is only great enough to obtund the perception of odors without totally destroying it.

Anosmia.—Anosmia is characterized by a total loss of the sense of smell, the pathological lesion being more extensive than that found in hyposmia.

I have often seen cases in which there was a total loss of smell due to a blocking of the olfactory fissure by an enlarged middle turbinal, which was relieved by the removal of the middle turbinal. These cases were also complicated by ethmoiditis and sphenoiditis, but the loss of the sense of smell was not due to the inflammatory disease, as the ability to perceive odors was immediately restored by the removal of the middle turbinate. If it had been due to disease of the mucous membrane, considerable

time would have elapsed before regeneration could have taken lace. A cold in the head is a frequent cause of transient anosmia.

Odors reach the attic of the nose by either the anterior or the posterior nares, hence any condition of the septum or of the tissues of the outer wall of the nose which blocks the anterior or posterior nares produces anosmia. The lesion may be in the nerve endings, as in atrophic rhinitis, in the nerve, or in the olfactory brain centre. Anosmia of intranasal origin may be unilateral or bilateral according to the location of the obstructive lesion. In such cases the sense of smell may be restored by the proper surgical procedure within the nose. If, however, the lesion is in the olfactory nerve or brain centre a cure is scarcely possible.

SENSORY, VASOMOTOR AND REFLEX NEUROSES.

Hyperesthetic Rhinitis; Hay Fever.—Hyperesthetic rhinitis, or hay fever, is characterized by annual paroxysms of sneezing accompanied by a severe and prolonged coryza and asthma.

Etiology.—The Predisposing Causes.—The predisposing causes of hyperesthetic rhinitis are constitutional, local, climatic, geographical, racial, and altitudinal.

(*a*) The *constitutional causes* are a neurotic temperament, chemical changes in the mucus secreting glands (D. Braden Kyle), gout, and rheumatism.

The *neurotic temperament* is difficult to define, but seems to consist in an unstable condition of the nervous system, wherein there is either an excess or a decrease in the nervous energy. Some claim that the nervous disturbance is due to a faulty metabolism whereby certain toxic substances are liberated in the blood current. Thus a gouty or a rheumatic diathesis is held to be the basic cause. It is obvious, however, that there must be a cause back of the gouty or rheumatic expression. It appears impossible in the present state of our knowledge to clearly define the conditions back of a nervous temperament. That hay fever subjects are neurotic is generally accepted. As to why they are neurotic is a much mooted question, concerning which many ingenious theories have been advanced, but none of which are convincing.

(*b*) The *local causes* of hyperesthetic rhinitis are various. A perfectly healthy nasal mucous membrane on a normally placed bony framework is not often affected by hay fever. On the other hand an apparently healthy mucous membrane on a normally placed bony framework may be affected by hay fever. I have seen cases in which there was no obstructive septal deformity and no absolute occlusion of the olfactory fissure by turbinal enlargement. The only noticeable morbid lesion was a slight redness of the mucous membrane over the anterior end of the middle turbinated bone. These cases were also subject to occasional attacks of severe coryza with copious purulent discharge. During the interim between the attacks of coryza no symptoms were complained of, but an examination of the nose showed the reddened and slightly boggy

condition of the anterior portion of the middle turbinal. While I do not care to promulgate a new theory as to the etiology of hay fever, I have been impressed with the possible relationship of catarrhal sinuitis, particularly ethmoidal and frontal, to hay fever. In some cases the surgical treatment of the sinuitis was followed by a relief of the hay fever. It is possible that the catarrhal discharge so irritates the nasal mucous membrane as to make it susceptible to the irritation of the pollen of certain plants and grasses. The difficulties in the way of diagnosticating catarrhal sinuitis have been so great that its presence has usually been overlooked. With our present knowledge its detection should be more often made. It is now possible, therefore, to study the relationship existing between sinuitis and hay fever, and I have some confidence that such a relationship will be satisfactorily established.

Deflection of the septum, especially in the region of the middle turbinal, or enlargement of the middle turbinal, causing contact between the two, is another local factor in hyperesthetic rhinitis.

The "sneezing area" of the nose is at the points of contact between the middle turbinal and the septum, hence the sneezing so characteristic of this disease. As a rule the moment the pressure is relieved the sneezing ceases.

Sensitive areas on the nasal mucous membrane of the septum and the outer walls of the nose, reddened and slightly elevated above the surface of the mucous membrane, predispose to the hyperesthetic paroxysms. Whether they are due to some concurrent inflammatory disease of the nasal and accessory sinus mucosa, or to some change in the sensitive nasal branches of the sphenopalatine ganglion, is not established. It seems reasonable to suppose that an inflammatory disease of the nose, attended by an irritating secretion, so characteristic of catarrhal sinuitis, might affect the terminal sensitive nerve filaments, rendering them extremely hypersensitive. The local vasomotor disturbance in the same areas would cause their elevation above the gurface of the mucous membrane.

Dr. Schadle, of St. Paul, recently called attention to the possible relationship existing between maxillary sinuitis and hay fever. Whether or not such a relationship actually exists, we must recognize the fact that the local hyperesthesia probably has an anatomical or inflammatory origin. The hypersensitiveness does not "happen;" it has a definite cause. Inasmuch as sinuitis, either catarrhal or suppurative, is often associated with hay fever, it seems plausible to conclude that the irritation attending the discharge of the secretions over the nasal mucous membrane may be the cause. The hypothesis is still further supported by the clinical fact that some cases of hay fever are cured by curing the sinuitis.

While the above hypothesis is based upon clinical observations, they are too meagre to warrant final conclusions. They are sufficient, however, to justify the closest scrutiny of the sinuses in every case of hyperesthetic rhinitis (hay fever). Such a scrutiny should include the examination of the middle turbinal, the olfactory fissure, the septum, the trans-

illumination of the sinuses, and a skiagraph of the sinuses. In addition the patient should be closely questioned concerning the presence of headache (chiefly frontal), dizziness, especially upon stooping forward, and unilateral disturbances of the ocular apparatus. The ocular disturbances may include errors of refraction, ulcer of the cornea, or lesions of the retina or other portions of the optic tract, and of any other of the structures of the eyeball. The composite picture thus elicited should show conclusively either the presence or absence of an associated sinus disease.

Polypi have long been referred to as a local predisposing cause of hay fever. As these morbid growths are often secondary expressions of sinuitis, the possible causative relationship of this disease is thereby strengthened. The polypi usually arise from the region of the hiatus semilunaris, the border of the middle turbinal, or the posterior ethmoidal cells.

In the latter event they protrude through the olfactory fissure into the middle meatus or are lodged above the middle turbinal in the superior meatus. The pressure due to their presence may be sufficient to irritate the sensitive mucosa, or the accumulated secretions from the sinus may be the exciting cause. It is evident that the mere removal of the polypi may not be sufficient to completely remove the irritation. The diseased sinuses should also receive appropriate treatment.

(*c*) The *climatic influence* upon hay fever is well recognized as being confined to the neighborhood of the forty-fifth parallel of the northern hemisphere. The territory a few degrees either north or south of this latitude is comparatively free from this disease. This probably is due to the absence of the flora the pollen of which is the chief exciting cause. If a map of the United States were divided into four belts by lines drawn through it from east to west the majority of the cases of hay fever would be included within the third belt from the bottom, although many cases would be found in the other belts.

(*d*) The *geographical distribution* of hay fever is instructive. It exists in greater abundance in the United States than in any other country, while England takes the second place. It is also present in Germany and France, although in lesser numbers.

(*e*) The *racial influence* in the predisposition to hay fever is marked. It is more common in the English-speaking races of the northern hemisphere, although it is more or less prevalent among the German and French people.

(*f*) *Altitude* exerts considerable influence in the causation of hay fever, it being more prevalent in the low portions of the countries, while the higher altitudes are comparatively free from it. The annual pilgrimages made into the mountains in the northern portion of the Eastern States and into the cold, bracing atmosphere along the shores of Lake Superior and the northern shores of Lake Michigan are eloquent with the benefits derived from altitudinal and climatic migrations.

(*g*) *Age* is an important factor in the causation of hay fever, it being most common between the twentieth and fortieth years of life.

The Exciting Causes.—It is generally accepted that the exciting cause of hay fever or hyperesthetic rhinitis is the emanations from certain plants and animals. It was at one time thought that all cases were of vegetable origin in the haying season, hence the name hay fever. Subsequent observations have shown that the exciting cause may emanate from various plants and animals, chiefly the following: Graminaceæ, solidago virgo aurea (goldenrod), ambrosia artemisiæfolia (rag-weed), cats, dogs, horses, and cows. The emanations from grasses and other plants, causing the paroxysmal symptoms, is probably the pollen. In 1873, Blackley conducted a series of experiments with glycerin-covered glass plates and observed the rise and fall of the intensity of the symptoms with the increase and decrease in the number of pollen within a given area on the plates. From these observations he established the pollen of certain plants as an exciting cause of the disease. Since then many observers have reported the emanations from animals as exciting causes.

The season exerts a characteristic influence upon the occurrence of the paroxysmal attacks of hyperesthesia. This is due to the fact that the emanations from the plants can only occur during the time they throw off their pollen. It occurs more frequently in August and September and less frequently in June, when the roses are in bloom.

An analysis of the causes of hyperesthetic rhinitis resolves the etiology into three groups, as follows: (1) A constitutional or neurotic habit. (2) Local morbid lesions of the nose and accessory sinuses. (3) The pollen of certain plants and emanations from certain animals.

Pathology.—The structural changes in the affected nasal mucous membrane consist in a hyperemia, edema, and after repeated attacks of hyperplasia of the turbinated bodies. The presence of nasal polypi in a hay fever case is scarcely to be considered a pathological lesion of this disease, but rather a result of sinus inflammation. The elevated hypersensitive areas are chiefly found at the terminal endings of the sensitive branches of the sphenopalatine ganglion, and are due to the increased hyperemia in these areas, while the hypersensitiveness is due to the irritation of the sensitive endings of the nerve fibers.

If the disease were a pure neurosis there would be other nervous phenomena somewhat proportional to the intense paroxysms of the hay fever, whereas if it were a true inflammatory disease there would be greater structural changes. The disease is more probably a combination of a moderate neurosis, with local morbid changes which give rise to the local irritation of the nerve endings of the sensitive branches of the sphenopalatine ganglion, upon which, at favorable seasons of the year, the pollen of certain plants and the emanations from certain animals impinge upon and give rise to the phenomena characteristic of hyperesthetic rhinitis.

Symptoms.—The symptoms of hay fever are those of an acute coryza, as malaise, elevation of temperature, sneezing, serous discharge, headache, etc., to which are added an itching in the region of the soft palate and the median palpebral commissures (inner canthi) of the eyes, and

asthma. The sneezing is paroxysmal, and may be excited by slight draughts of air, bright sunlight, dust particles, and psychical impressions, as the consciousness of being observed by another person, or by the thought of his own condition. The sneezing is accompanied by profuse lacrymation and serous nasal secretion and by suffusion of the conjunctiva. The profuse serous discharge from the nasal mucosa is followed by a contraction of the swollen mucous membrane, which brings temporary relief.

The serous secretion from the nose is acrid, and excoriates the alæ of the nose and the upper lip. (I have observed the same phenomena in some sinus inflammations when pus was absent.) The secretions become seromucous and in some cases purulent in character.

Intermittent or even alternate stenosis of the nose is present. During the continuance of the nasal stenosis the patient suffers from the paroxysmal sneezing and asthma, and from headache, lacrymation, and diffidence. The diffidence is pronounced, the patient dreading the approach of another person, especially if he is a stranger or someone with whom he is ill at ease.

The pharynx is often dry and painful upon deglutition. The tonsils are not usually inflamed, although they may be.

Tinnitus aurium due to a swelling of the mucous membrane of the Eustachian tube is frequently present.

The appetite is impaired and there is a corresponding loss of weight.

Prognosis.—A guarded prognosis should always be given. So many methods of treatment have been promulgated, with the assurance of success, that have proved wholly inadequate, that I have become skeptical in reference to nearly all of them. Upon theoretical grounds it appears that if either one of the three major causes of the disease is removed a cure must follow. If, for instance, the local morbid lesions of the nose are overcome, the patient should be freed from the hay fever; if the neurotic habit is overcome, the hay fever should be cured; and if the patient is removed from the influence of the pollen, or is rendered immune by serums or antitoxins, he should be cured. Many a patient has been treated and operated upon with a view to the total removal of the local morbid lesions, but the hay fever paroxysms continued from year to year without abatement. Many a hay fever sufferer has been persistently treated for the neurosis, and the various dyscrasias causing it, without effect upon the hay fever; and many a patient has been sent year after year to the mountains or to the northern lakes without preventing the recurrence of the paroxysms the following year. On the contrary, a few patients have been cured permanently by recourse to one or more of the foregoing methods of treatment. The same is true of other methods of treatment; a few are cured while many are not benefited at all. A remedy that is efficacious in one subject is totally inert when applied in another.

Either the existing ideas concerning the etiology or our methods of diagnosis of the local morbid lesions are wrong—probably both. Notwithstanding all this, we can only act upon the knowledge now in

hand. We must, therefore, continue to remove the local morbid lesions from the nose as the most hopeful line of treatment, except the removal of the patient to a place where the pollen or other irritant peculiar to his case is absent; or we must administer a serum that is an antidote to the pollen in question. In the meantime our knowledge of the morbid processes in the nose and accessory sinuses is rapidly advancing, and it may be that after a time we will be able to cure this elusive and distressing disease.

Treatment.—The treatment may be divided into five groups: namely, (*a*) the treatment of the dyscrasias, (*b*) the removal of the local morbid processes in the nose and the accessory sinuses, (*c*) the removal of the patient from the influence of the pollen or other emanations acting as the exciting cause of the disease; (*d*) the immunization of the patient; and (*e*) the relief of acute symptoms.

The Treatment of the Neuroses and Dyscrasias.—The treatment of neuroses and the dyscrasias of modern civilization is an undertaking calculated to bewilder all but the veriest enthusiast. We are in a domain of pathological entities whose forms are shadowy and whose definitions are obscure. We are dealing with unknown quantities upon hypotheses not yet proved. Failure is the almost inevitable result. While all this is true, something may still be done to improve rheumatic and gouty diatheses and the ill-defined neurotic manifestations. The intestines and stomach can be flushed by lavage and by saline cathartics. The kidneys and skin can be made to eliminate more freely, and the hemoglobin of the blood can be raised so as to attract more oxygen. These and other processes may be stimulated or modified so that the neurotic state of the nervous system and the various constitutional disorders are in a degree improved. Indeed, the treatment should include some of these measures, although a cure may never be effected by them.

Treatment of the Local Morbid Lesions.—(*a*) The circumscribed sensitive areas should be cauterized with a flat electrode raised to a white heat, without the use of a local anesthetic. The use of an anesthetic would make it impossible to locate the sensitive areas, and, furthermore, the cauterization is superficial and lasts only a fraction of a second. The current should be turned on until the point of the electrode is almost instantly brought to a white heat. It should then be introduced cold into the nose, a sensitive area located with it, and the current turned on by pressing the button on the electrode handle. The moment the white heat is seen in the nose the button should be released and the electrode removed. Another sensitive area should be located and cauterized in like manner. From four to five sensitive areas may be cauterized at a sitting. The treatment may be repeated in from five to seven days.

(*b*) Nasal catarrh, if present, should be treated during the period of quiescence, that is, when the hyperesthetic rhinitis is not active. (See Various Forms of Chronic Rhinitis.)

(*c*) Nasal polypi should be removed in the period of quiescence,

although they may be removed during the acute paroxysms. (See Nasal Polypi or Myxoma.)

(*d*) Deviations of the septum causing any type of rhinitis, or that contribute to the causation of sinuitis, should be corrected during the period of quiescence, according to the methods described under Deviations of the Septum.

(*e*) Sinuitis, either catarrhal or suppurative, should be treated during the period of quiescence, according to the methods described under the Inflammatory Diseases of the Nasal Accessory Sinuses.

Dr. Schadle, of St. Paul, has reported very favorable results from irrigating the maxillary sinus. A saponaceous substance is washed away, the fluid finally coming away perfectly clear. Dr. Schadle suspects that the ostium maxillare is large and admits the irritating substances which excite the paroxysmal attacks, and that when washed from the antrum the symptoms are relieved.

I have had equally good results follow the total exenteration of the ethmoidal labyrinth *via* the nose with a curette. One patient was compelled for three months each year to sleep in a sitting posture with her head upon a table. Since the radical removal of her ethmoidal sinuses the only manifestation of the old trouble is a mild asthma, which appears for short intervals at any season of the year. I have since performed a double Killian frontal sinus operation upon this patient with complete success. This operation has apparently had no influence on the slight asthma remaining.

It is obvious that it is inadvisable to treat the local morbid lesions by surgical measures during the acute exacerbations, as to do so might subject the nasal tissues to violent reactionary inflammation and to septic infection.

The Protection of the Patient from the Pollen or Other Emanations Exciting the Acute Paroxysms.—(*a*) Small, soft sponges may be worn in the vestibule of the nose to filter the pollen and other irritating substances from the inspired air. They are sometimes effective, but, on the whole, are unsatisfactory. A moistened handkerchief may also be utilized for the same purpose by holding it close to the nasal openings. At best, these devices afford temporary relief, and cannot be depended upon throughout the paroxysmal period.

(*b*) The geographical treatment consists in the removal of the patient to a place where the exciting emanations are absent. The Lake Superior, or the Muskoka region in Canada, and the Adirondack Mountains are favorite resorts for many patients in the United States and Canada. An extended ocean or lake trip is also a satisfactory method of escaping from the emanations of the irritant pollen, etc.

While the geographical treatment is not always effective, it is nearly always so if protracted over the entire period of the acute exacerbations. Some cases may return before the expiration of this period without experiencing a recrudescence of the acute symptoms, although this is rarely so. Others are not relieved by a change of geographical location; at least, all cases are not relieved by a change to the same locality. Each

case must learn by experience the place best suited for him. On the other hand, he may find relief for a number of seasons in one locality, and upon returning the following year may experience but little or no relief. Under these circumstances he should try another locality. If, for instance, he has been going to the Lake Superior region or the Muskoka Lake region, he should be sent to a higher altitude as the Adirondacks or the Rocky Mountains.

The Palliative Treatment.—Various local and internal remedies have been advocated, but none of them are of universal value. They may be tried in series in individual cases until one is found that gives relief.

(*a*) The extract of the suprarenal gland is often successfully used. It should be prepared, according to Dr. H. L. Swain, by adding 10 to 20 grains of the powdered gland to one-half dram of cold, sterile water. After stirring thoroughly, it should be filtered and a few drops of alcohol added to prevent early decomposition. Boric acid, cinnamon-water, and camphor-water may also be used to prevent decomposition. When thus prepared it should be applied to the nasal mucous membrane with a spray tube, or with thin pledgets of cotton pasted over the surface of the mucous membrane. It is harmless, except in those occasional cases in which it excites irritation and sneezing. S. Solis Cohen has used it internally with success.

(*b*) The powdered sulphate of quinine insufflated into the nose has been recommended. I have used it in a few cases with complete success, and in many others without result. When it is effective the nasal mucous membrane becomes dry and the turgescence disappears. The ears ring from the absorption of the drug. In one case two insufflations of 5 grains each were followed by complete relief lasting throughout the paroxysmal season. This case was a mild one, beginning in the latter part of August.

(*c*) Alkaline and oleaginous solutions may be sprayed into the nose, with transient relief. In some cases a postnasal douche of boric acid solution is grateful. Oil with menthol in 0.5 per cent. solution, or with 0.1 per cent. of formaldehyde, is sometimes grateful to the inflamed membrane. The formaldehyde burns for a few seconds and is followed by a grateful sense of relief.

(*d*) The itching at the inner canthi of the eyes may be relieved by irrigating with boric acid or normal salt solution.

(*e*) The rays of the 500 candle-power incandescent lamp (Fig. 19) applied for ten to twenty-five minutes over the face with the eyes closed, at a distance of from twelve to eighteen inches, increase the speed of the arterial venous currents. The passive congestion and edema are thereby reduced and the relief is considerable. (See Leukodescent Light and the Technique of Application.) The light should be applied from one to four times daily. In those cases in which its use is attended by marked relief a lamp may be installed in the patient's home. A lower power than 500 candle-power is not recommended, nor is a cluster of 50 candle-power lamps as efficacious as a single 500 candle-power lamp. The

therapeutic value of the light is chiefly determined by the candle-power of a single lamp, no matter how many are connected in a series or in a group.

(*f*) Powdered diphtheria antitoxin has been used locally with gratifying results (Pierce). Numerous other local remedies have been recommended from time to time, but have proved of little value after more extensive trial.

(*g*) Antilithemic remedies, as the salicylate of soda, have been extensively employed to counteract the uric acidemia with indifferent success except in occasional cases.

Serum Treatment.—The serum treatment recently introduced by Dunbar, while not perfected, affords relief in selected cases. Sir Felix Seman, Liebreich, and Lobe endorse Dunbar's serum treatment, with the proviso that all the conditions recommended by him be observed. The serum is prepared in liquid and powdered form, the powdered being the most stable and reliable. The solution may be applied to the conjunctiva or the nasal mucous membrane. The object of the serum is to afford immediate relief and ultimately to establish immunity. The conditions attending its use are so complex that it is at present a rather unsatisfactory remedy.

In my opinion, serum treatment will not prove to be the solution of the management of hay fever or its kindred types of hyperesthetic rhinitis. The predisposing factors are ignored in this method of treatment. There are conditions which render the mucous membrane of the nose susceptible to irritation by the toxins of the pollen which excite hay fever. Heretofore we have regarded the neuroses and constitutional dyscrasias, the various obstructive lesions of the septum, and the catarrhal affections of the nasal mucous membrane as the predisposing causes. The treatment applied in accordance with these ideas has generally been disappointing. In my opinion we must look beyond the nasal chambers to the accessory sinuses for the real conditions which predispose the mucous membrane of the nose to the irritation by the pollen of certain grasses, flowers, etc. The irritation caused by the more or less constant discharge from the sinuses is, to my mind, a rather common cause of hay fever. Schadle has called attention to the relief afforded by the irrigation of the maxillary sinuses. According to my observations the exenteration of the ethmoidal sinuses (including the removal of the middle turbinal) has given an apparent cure extending over two years. The sinuitis may or may not be purulent. Indeed, the catarrhal type is often more irritating than the purulent, as shown by the excoriations and fissures at the margin of the vestibule of the nose.

In view of these facts I am inclined to the opinion that the ultimate cure of hyperesthetic rhinitis and asthma will not be found in the serum treatment, but will be found in the proper comprehension and treatment of catarrhal and suppurative sinuitis. This will include the obstructive lesions of the septum and the structures within the "vicious circle" of the nose. The neurotic element is often so marked in these cases that any method of treatment may fail.

According to O. J. Stein the injection of a few drops of alcohol into

the mucous membrane of the nose at the points where the sensitive nerves enter the nasal chambers (Fig. 1) controls the acute symptoms in hay fever subjects. From three to four injections a few days apart is sufficient to control the attack throughout the season.

ACUTE CIRCUMSCRIBED EDEMA OF THE NOSE. CORYZA EDEMATOSA. ACUTE CIRCUMSCRIBED EDEMA.

This affection may also involve the pharynx and larynx in the same case. It is not an inflammatory infection, but is an edema of neurotic origin, probably from some disturbance of the digestive tract. It is quite like urticaria, though it involves the mucous membrane. It is usually associated with other symptoms or diseases, as hay fever, urticaria of the skin, headache, gastro-intestinal disturbances (as watery vomiting and colicky pains), and itching. In Matas' case a distinct periodicity was present, the edema recurring regularly between 11 and 12 A.M. daily. In this case the toxin was probably the malaria plasmodium.

I reported a case in 1896 in which the angioneurotic edema came on during an attack of hay fever. There was also a gastro-intestinal disturbance. The edema involved the nose, soft palate, and hypopharynx. The mucous membrane was swollen, gray, and semitranslucent. The suffocative symptoms were pronounced, although at no time was there imminent danger from this source.

Numerous punctures of the edematous membrane were made and cocaine applied, after which the edema gradually disappeared.

NASAL HYDRORRHEA. RHINAL HYDRORRHEA.

Nasal hydrorrhea is a symptom of some other nasal lesion rather than a disease, and is characterized by thick, viscid, and slightly opalescent secretion more or less rich in mucin. The amount of discharge varies from a few ounces to a pint or more in twenty-four hours. According to St. Clair Thompson, the secretion contains amorphous matter and mucous corpuscles. "The addition of either alcohol or acetic acid throws down a stringy precipitate like mucin. On boiling the precipitate with dilute sulphuric acid, a reducing, sugar-like material is formed; this is also characteristic of mucin. The fluid contains a small amount of proteid coagulable by heat; it does not reduce Fehlin's solution. Proteoses and peptones are absent. The alcohol extract of the fluid contains no reducing substance. The presence of mucin and the absence of the reducing substance are quite sufficient to distinguish this fluid from normal cerebrospinal fluid."

Symptoms.—The clinical picture of nasal hydrorrhea shades off in one direction into cases of what are generally called hay fever, with symptoms of intense local irritation, while in the other direction they may consist of a passive and almost painless, watery discharge from the

nose. It appears to be an affection of adult life affecting males and females indifferently. Although it may be more marked on one side than on the other, the flow usually takes place from both nostrils. When handkerchiefs are soaked with it they generally dry stiff. In cerebrospinal rhinorrhea, on the other hand, the discharge is so watery that handkerchiefs dry quite soft, and can be used again without washing; and in this affection the discharge is limited entirely to one nostril, unless there happens to be some obstruction on the affected side, when it may make its way round to the opposite nasal fossa. When the fluid is of arachnoid origin there is frequently headache or other mental symptoms which are relieved by the discharge. It is not accompanied with lacrymation or suffusion of the conjunctiva, and photophobia; and although it may occasionally give rise to a little sneezing, especially in the morning, or on rising, this is a rare and infrequent accompaniment.

In nasal hydrorrhea, feelings of malaise set in with the discharge and only disappear with its cessation. It is frequently ushered in with sneezing, photophobia, and lacrymation. It rarely continues in sleep, while cerebrospinal rhinorrhea continues day and night. It is very erratic in its onset and in its intermission, and it is very dependent on external influences and on conditions of health. Moritz Schmidt states that some cases have been observed which were dependent on ulcer of the stomach or biliary lithiasis and while using the term which forms the title to this paper, he defines the disease as a vasomotor rhinitis. McBride recognizes the diversity of the conditions of which nasal hydrorrhea may be but a symptom.

Treatment.—The treatment should be addressed to the morbid nasal lesions, such as are found in hay fever or other forms of hyperesthetic rhinitis, or to any other pathological condition present in the nose.

CEREBROSPINAL RHINORRHEA.

St. Clair Thompson, in 1899, made a notable contribution to rhinological literature when he described for the first time the escape of cerebrospinal fluid from the nose. Such cases had been previously regarded as nasal hydrorrhea. Thompson's analysis of his and other cases recorded in the literature under various names made the differential diagnosis between cerebrospinal rhinorrhea and nasal hydrorrhea quite clear. The subarachnoid fluid may, under conditions not yet clearly demonstrated, escape from the cranial cavity through the nose without apparent harm to the patient. The fluid is clear and watery in contrast to the slightly opalescent and viscid fluid of nasal hydrorrhea. The dripping is constant and is free from taste, sediment, and smell, and it is free from albumin and mucin. It reduces Fehling's solution.

Etiology.—The etiology is as yet but little understood, although Thompson is inclined to the belief that there is some pathological change in the contents of the skull leading to increased intracranial pressure. In 17 out of 21 cases recorded there were cerebral symptoms,

while 8 showed retinal changes. The following table prepared by St. Clair Thompson gives the essential tests for cerebrospinal fluid:

1. The fluid is perfectly transparent like water, and contains no sediment.
2. It is faintly alkaline in reaction, and either tasteless or slightly salt.
3. The specific gravity is between 1005 and 1010.
4. It is not viscid, and gives no precipitate (mucin) on adding acetic acid.
5. On boiling there is not more than a trace of coagulum of serum globulin and serum albumin.
6. Cold nitric acid gives a precipitate which disappears on heating, and separates again on cooling.
7. Saturation with magnesium sulphate should give a precipitate. Saturation with sodium chloride should also produce a precipitate. Ammonium sulphate should be tried if the above salts fail.
8. The liquid should give a pink or rosebud color with a trace of copper sulphate and excess of caustic potash.
9. When boiled with Fehling's solution there should be a reduction of the copper (due to pyrocatechin or some similar body).
10. The reducing substance may be obtained by evaporating to dryness an alcoholic extract of the fluid. It is then found in the form of needle-like crystals.
11. The aqueous solution of this residue does not ferment with yeast.

If applied to suspected cases, these tests will in future avoid any question as to the true nature of cerebrospinal fluid when it escapes from the nose.

Treatment.—The treatment of cerebrospinal rhinorrhea is obviously next to impossible. Whatever is done, extreme care should be exercised to avoid infection of the nose, as it might be communicated to the meninges or to the cerebrospinal fluid of the brain and spinal cord.

ASTHMA.

Asthma may or may not be of nasal origin. The bulbar nuclei of the fifth nerve has an anatomical connection with the vagus, hence it is possible for an irritation in the nose to excite reflex phenomena in the lower respiratory tract. The most common cause of asthma of nasal origin is polypi; at least, larger numbers of cases cured by intranasal treatments are cured by removing polypi. In other cases hypertrophy, hyperplasia, and other morbid lesions appear to cause asthma. On the other hand, they are more often present without exciting asthma.

Treatment.—The treatment of asthma of nasal origin consists in the correction of the nasal morbid lesions, more especially if they are polypi or hypertrophy of the turbinated bodies. (See Ethmoid Operations.)

A useful test as to the curability of the case is to apply a solution of

cocaine to the mucous membrane of the nose, and if the asthma is greatly relieved or altogether checked, it is probable that the removal of the morbid lesions will result in a cure, though this cannot be positively promised, nor can it be stated how long the relief will continue.

EPILEPSY OF NASAL ORIGIN.

Epilepsy of nasal origin has been reported by various authors. Watson Williams refers to a case of an epileptic attack brought on by cauterizing the nose for nasal polypi. He also cites two cases reported by Baron, one in a case of nasal polypi, the removal of which was followed by marked alleviation of the epileptic seizures; the other a young unmarried woman who had epileptic fits at her menstrual periods from the time menstruation began. Her inferior turbinated bodies were greatly hypertrophied, and she was always more troubled with nasal stenosis during the menstrual periods, and it was at these times only that the fits occurred. Removal of the hypertrophied tissue was followed by a cessation of the fits for seven or eight months, and when they reappeared the turbinal hypertrophy was found to have returned.

I have a case of sarcoma of the nose, upon which I operated in April, 1903, that has had repeated epileptic fits since the operation. In each instance I have found a sequestrum of bone in the ethmoid region near the cribriform plate, after the removal of which the fits failed to return for several weeks or a few months.

Nasal Tachycardia.—Watson Williams, in his well-known treatise on *Diseases of the Upper Respiratory Tract*, cites the experiments of Gruber, and the reports of several cases as follows:

"The effect of irritation of the nasal mucosa upon the movements of the heart and pulse have been studied by Gruber. He tested in all 43 subjects, 13 with normal noses and 30 with nasal disease, and repeated his tests on several occasions in each. He found that irritation of the nasal mucosa was entirely negative.

"I have never seen any instance of reflex influence on the heart from nasal disease, but Spencer Watson records a case of tachycardia which was associated with, and apparently due to, nasal polypi. Charsley observed temporary exophthalmos with tachycardia, the pulse ranging as high as 110 per minute, coming on and lasting for a period of three months after the galvanocauterization of one of the inferior turbinals. Symptoms of Graves' disease have been attributed to nasal disease; thus Hack, in a case associated with chronic rhinitis, found that the goitre and tachycardia vanished after treatment of the rhinitis, and B. Fränkel and Hopmann report similar cases cured by nasal treatment."

CHAPTER XIII.

NEOPLASMS OF THE NOSE.

MYXOMA; NASAL POLYPUS.

MYXOMA, or nasal polypus of the nose, is usually a pedunculated connective-tissue tumor most often growing from the middle turbinated body, the uncinate process of the ethmoid bone or the ethmoidal cells. It is usually significant of a preëxisting catarrhal or suppurative inflammation of the sinuses. Some writers believe the tumor is primary and the inflammation of the sinuses secondary. Such a belief probably arose on account of the hazy conception of the symptoms of catarrhal sinuitis. Fortunately, catarrhal inflammation of the sinuses is now well understood, and I believe that clinical experience will show that the inflammation exists prior to the formation of the myxomatous tumors.

Etiology.—While it has not been definitely proved that nasal polypi are directly due to sinuitis, it nevertheless often appears to be secondary to such an inflammation. If the cases are carefully studied, it will often be found that the patients complain of a vague frontal headache, pressure between the eyes, dizziness, especially upon stooping forward, irritability of the eyes upon prolonged reading, or a difficulty in the proper refraction of the eyes. Some or all of these and other symptoms are present in catarrhal as well as in suppurative sinuitis. It is claimed that repeated attacks of coryza may cause polypi. This is practically equivalent to saying they are due to sinuitis, as the distressing symptoms of coryza are usually due to the associated inflammation of the accessory sinuses. Clinically we know that polypi are often associated with suppurative sinuitis and with caries of the bone in the immediate neighborhood of the tumors. Some writers cite the fact, or apparent fact, that polypi are found in the less obstructed nasal cavity, as an argument against the previous existence of the sinuitis I believe that a careful examination of the nose will show that the polypi are usually present on the side of the nose in which there is the *greatest obstruction in the region of the middle turbinated body*, or "vicious circle." A casual examination of these cases often shows a concavity on the side of the polypus, but the concavity is in the lower portion of the nasal chamber. A common type of septal deformity is shown in Fig. 184, in which there is a ridge on the inferior portion of the left side of the septum, while there is a convexity high up on the right side of the septum. It is easy to understand how the examination might show an open nostril on the right side in this instance, if only the lower portion of the nose were taken into consideration. If, however, the upper portion is considered the obstructive lesion is readily discovered on the side where polypi are present.

One of the commonest causes of nasal polypi is a preëxisting inflammation of the membrane of the nasal sinuses and of the nasal mucosa in the region of the cell openings. The irritation and pressure give rise to a passive congestion and a proliferation of cells. A serous or edematous infiltration is a later manifestation. The connective-tissue cells subsequently become filled with the serum, thus leading to a hydropic degenerative change in some cells, and a myxomatous or gelatinous change in others (Kyle).

The tissue thus degenerated becomes pendulous and in most instances pedunculated. Such a tumor is known as a polypus.

Other causes of hype plastic inflammation of the nasal mucous membrane, especially in the region of the middle turbinal, may eventuate in nasal polypi. If, for instance, a foreign body is lodged in the nasal chamber for a long time, or any other continued source of irritation is present, it may result in nasal polypi. Some writers claim that the suction of the inspiratory current of air produces the tumors. Kyle has pointed out that the ingoing current of air exerts as much pressure as it does suction. As a matter of fact, the presence or absence of suction depends largely upon the location of the obstructive lesion of the septum in relation to the polypi. If the polypus is posterior to the obstructive lesion, it is subject to suction from the rarefied or negative air pressure posterior to the obstruction. If there is no anterior nasal obstruction, the polypi are subjected to pressure rather than to suction. Suction may have something to do with the formation of polypi in some cases, but it is not probable that it is often or ever the sole cause.

Fig. 184

(*a*) The apparently open nostril, only open in its inferior portion. (*b*) The obstruction in the upper portion interfering with drainage and ventilation of the sinuses, hence it gives rise to sinuitis, and later to polypi. (*c*) Nasal passage obstructed in its lower portion. (*d*) Open in the upper portion, hence drainage and ventilation of the sinuses are good; sinuitis and polypi absent. (*f*) Polypus on the apparently open side, but in reality on the side where there is an obstruction in upper or sinus portion of the nose.

Pathology.—While polypi are usually called myxomata, they are, as a rule, fibromyxomata. Pure myxoma is rare, and when found consists of an epithelium-covered connective-tissue sac, which contains a mucoid fluid, some bipolar spindle cells, and a fine network of connective tissue. The fibromyxoma, the usual type, is much richer in connective tissue, and less so in mucoid fluid. The tumors are supplied with bloodvessels and nerve filaments which do not penetrate the substance of the tumor, but are limited to the mucous membrane covering the tumor. They contain plasma cells, which stain with polydrome,

methylene blue, and eosin. Robert Levy reports a case of multiple cystic polypus richly supplied with bloodvessels, as shown in Fig. 185

Symptoms.—The symptoms of nasal polypi are often complex on account of the nasal obstruction (middle turbinal region) and the associated nasal and sinus inflammation which usually co-exist.

The symptoms referable to the polypi are largely dependent upon its location, size, and the amount of obstruction it produces. If it is pedunculated, and hangs into the lower portion of the nose, it gives rise to the sensation of a movable foreign body in the nose. The patient can sniff and blow it back and forth in the nose at will. If it is sessile, it cannot be thus moved, but causes a feeling of tightness or of fulness across the bridge of the nose. The voice has the nasal twang in proportion to the obstruction produced by it. The voice is often muffled, owing to the almost total loss of nasal resonance.

Fig. 185

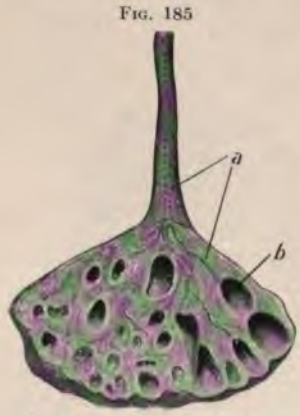

A polypus of the cyst adenoma type removed from the nose. Four cm. long, 2.5 cm. wide, 1.25 cm. thick, weight 8 grams, color pinkish white, solid and elastic. The section shows numerous cavities filled with colloid and caseous material. Some of the cysts are lined with ciliated epithelium; others have a degenerated columnar cubical or flattened epithelium, and in some the epithelium is entirely lost. Some areas are infiltrated with inflammatory round cells. (Robert Levy's specimen.)

Upon examination a grayish semitranslucent tumor is seen hanging in the middle meatus of the nose. If it is pedunculated, it may move with the inspiratory and expiratory currents of air. Probe pressure shows a soft and yielding mass freely movable in the nasal chamber. They may be single or multiple, but are more often multiple. H. W. Loeb reports a case from which he removed 308 polypi at one sitting. They vary in size from a pinpoint to such proportions as to extrude from the nose.

Various reflex symptoms, as cough and asthma, may be caused by polypi. I have seen cases in which the cough or asthma was so persistent as to compel the patient to sleep all night with the head on the table for three months at a time, who were relieved by the removal of the polypi and the total exenteration of the ethmoidal cells. The external signs of nasal polypi are not always present excepting the inclination to keep the lips parted, so as to complement the nasal with the mouth breathing. In other cases the tumors are of such aggregate magnitude as to broaden the bridge of the nose.

The sense of smell may be impaired or lost, owing to the closure of the olfactory fissure. The pharynx may be dry on account of the loss of the nasal respiratory functions, or from the thick, tenacious mucopus discharging into it.

Caries and necrosis of the bone of the middle turbinal and of the ethmoidal cells may be demonstrated in some cases by the use of a heavy blunt-pointed probe. A small probe should not be used, as it might

readily pass through the degenerated mucosa and lead to a mistaken conclusion as to the condition present. The probe should be gently passed over the mucous membrane of the middle turbinal and along the lip of the hiatus semilunaris (uncinate process), as these are the most common sites of nasal polypi. They also grow from above the middle turbinal from the ostei of the posterior ethmoidal cells.

The symptoms arising from the associated sinus disease are headache, dizziness, especially upon stooping or sudden jarring, irritability of the eyes upon prolonged reading, or even of unilateral blindness. (See Sinus Diseases.)

Prognosis.—The prognosis of nasal polypi is good if they are removed, and the preëxisting sinus and nasal disease causing them is also remedied. In those cases in which the cause is a slight nasal inflammation the removal of the polypi followed by cauterization of their points of attachment will effect a cure. If the polypi are removed and the cauterization is neglected they are liable to recur. In those cases due to marked catarrhal or suppurative sinus inflammation a cure may necessitate not only the removal of the polypi, but the exenteration of the ethmoidal sinuses also. If caries of the bone is present the operative procedure should include it as well as the polypi.

Treatment.—In view of the marked tendency to recurrence the treatment is not as simple as is ordinarily supposed. The average practitioner regards his duty as being performed when he removes the growth, or growths, and establishes a fair degree of nasal respiration. The aim should be, however, to not only remove the growths, but to remove the tissue from which it springs, and to remove the diseased process (sinuitis), which is often the cause of it. Whether or not bony necrosis is always present, clinical experience teaches that polypi are much less apt to return if a portion of the periosteum and bone from which they spring is removed with the snare, curette, or biting forceps. The use of the galvanocautery or fused chromic acid upon the stumps of the polypi effectually prevents their recurrence in some subjects.

The surgeon should ascertain as nearly as possible the points from which they spring, so that he may determine the difficulties likely to be encountered in the operation, and to enable him to formulate a correct prognosis if the extension of the operation is refused by the patient.

I. **Surgical Classification.**—If polypi spring from the free border of the middle turbinated body their removal and after-treatment are comparatively simple. In this location it is not difficult to engage the snare around the growth in such a way as to also include a portion of the middle turbinal from which it springs, though it may be removed with Holmes' scissors. Thus in a single operation it is sometimes possible to eradicate both the growth and its point of attachment.

II. If they have their origin from above the middle turbinated body there is a strong probability that they come from the posterior ethmoidal cells. Here the treatment is much more complicated. It may become necessary to remove all, or a large part, of the middle turbinated body,

(Figs. 170 and 171), and to exenterate the ethmoidal cells. After this is done the case may require occasional attention for several weeks.

III. When they have their origin in and around the hiatus semilunaris, either the maxillary, anterior ethmoidal, or the frontal sinus may be the seat of infection, and it may be necessary to perform a radical operation upon them to effect a cure.

IV. In other cases they spring from the anterior ethmoidal cells, in which event the anterior ethmoidal cells and frontal sinus may be seriously involved.

It is evident, therefore, that the simple removal of the polypi, or myxomatous growths, does not constitute the whole duty of the attending surgeon. Such treatment is usually only palliative and temporary. The presence of polypi should be regarded as an indication that hyperplasia of the mucous membrane and bone, and suppurative sinuitis are present. The same principles of treatment outlined for suppurations of the middle ear apply with equal force here. They are, briefly, (1) to establish free drainage; (2) to remove the morbid material; and (3) to maintain asepsis of the parts while healing is in progress.

Operative Technique.—I. *Polypi springing from the free border of the middle turbinated body* are perhaps the most easily and successfully treated of the types enumerated above. They are accessible and are attended by less involvement of the deeper tissues than in either of the other locations. The method of procedure is as follows:

(*a*) Wash the nasal cavity with a warm antiseptic spray and apply adrenalin and a 4 per cent. solution of cocaine. This is best applied on a thin pledget of cotton saturated with the solution and introduced with an applicator and adjusted over the operative field. The cocaine should be left in position for about seven minutes.

(*b*) Carefully inspect the polypus by the aid of reflected light, and determine as nearly as possible its point of attachment. Having determined that it springs from the free border of the middle turbinated body, the next step is to examine for evidences of other diseased processes.

(*c*) With a large blunt probe the point of attachment and neighboring parts should be examined for bare, rough bone. If a small probe is used, it may penetrate the unbroken tissue and thus come into contact with bony tissue. It is quite important, therefore, that a large one be used. It is not always possible to detect denuded bone, but if the examination is made in every case it will often be found where it is not otherwise suspected.

(*d*) The wire loop of the snare should now be introduced, so as to encircle the pendant tumor. It should be introduced so that both sides of it are against the septum, the lower portion of the loop being on a level with or lower than the inferior portion of the polypus. It should then be turned so that its inferior part passes outward under the polypus, and then in an upward direction until the polypus is encircled. The procedure is often facilitated if the loop is also moved slightly in a forward and backward direction while engaging the polypus.

(*e*) Care should be exercised to carry the loop so as to include the

point of attachment and a portion of the middle turbinated body if possible. If the growth is on the anterior portion of the turbinal it is usually easy to include the anterior third of it. The loop passes backward under and on either side of the turbinal, while the cannula (Fig. 186) is firmly placed in the notch formed by the anterior attachment of the turbinal and the anterior wall of the nose.

(*f*) Firm pressure of the cannula into the notch being maintained, the loop is tightened until the tissues are engaged. It is still further tightened until the anterior portion of the turbinal, to which the growth is attached, is severed.

(*g*) With a blunt probe the wounded surface is examined for evidences of carious or necrotic bone.

(*h*) If softened or necrotic bone is found it should be removed by curettement.

(*i*) If none of the middle turbinated body is removed the fibrous base of the polypus should be cauterized at the next sitting, or three or four days later.

Fig. 186

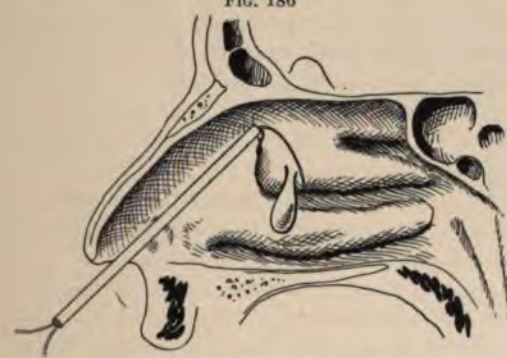

Removing a polypus and anterior end of the middle turbinal with a snare.

(*j*) The after-treatment should consist of the use of warm antiseptic douches or sprays and the insufflation of bismuth-iodine powder. If the douche is used, the Birmingham nasal douche is preferable to any of the pressure or fountain douches, as they are apt to force the solution into the middle ear and excite severe inflammation. The douche should be used twice daily.

II. When the polypi have their attachment *above the middle turbinated body* they usually spring from the ethmoidal cells, and the treatment is correspondingly more difficult. One may be able to remove a portion of the growths, but it is difficult to reach their points of attachment. It therefore becomes necessary to remove the anterior half or all of the turbinated body. This is not objectionable, as the ethmoid cells contained therein and those in the body of the ethmoid bone are probably more or less diseased. If necrotic bone is present it should be removed by curettement. In cases of this class my method of procedure is somewhat as follows:

(*a*) The preliminary preparations are the same as in the preceding paragraph I.

(*b*) The polypi are removed as completely as possible with the snare, so as to clear the view of the operative field.

The operation may stop here and the case be watched for further developments before adopting other surgical procedures in the middle turbinal and ethmoid regions.

(*c*) The stump of the polypus may be cauterized with chromic acid fused on the point of an applicator or with the electrocautery. The applicator may be curved so as to pass above the middle turbinated body. The curve should be made in the probe before the acid is fused on its point, as it should be used at once before the water of crystallization is reabsorbed.

(*d*) If after repeated removals the polypi persist, it will be necessary to remove a portion or all of the middle turbinated body in order to establish free drainage of the affected ethmoidal cells and to remove the polypi springing from them (Figs. 170 and 171).

(*e*) The subsequent treatment consists of cleansing lotions and such other procedures as may become necessary in the course of the case. It may be necessary to perform repeated operations in order to eradicate the diseased process in the ethmoidal cells, or to secure the complete exenteration of the cells. The complete exenteration of the ethmoidal cells may be done at once if the surgeon is sure they are extensively involved.

III. If the polypi *spring from the hiatus semilunaris or infundibulum* it may become necessary to open the maxillary antrum, as it may also be the seat of similar growths.

The mode of procedure is somewhat the same as in the first type in so far as the nasal operations are concerned; that is, the growths should be removed with the cold-wire snare and their *bases* cauterized. If upon further observation the antrum is found to be affected, the Caldwell-Luc or Denker operation should be performed. (See pp. 223 to 225.)

IV. When the *polypus arises from the border of the hiatus semilunaris* or mouth of the infundibulum, there is probably an involvement of the anterior ethmoidal and the frontal sinuses in addition to the anterior disease. The treatment required is much like that described in I, in so far as the removal of the polypus is concerned. Subsequently it may become necessary to remove the anterior third of the middle turbinated body by the method described in II, or this portion of the turbinal may be successfully removed with the snare by keeping the cannula firmly fixed in the notch formed by the anterior attachment of the middle turbinated body and the outer wall of the nose, the loop being on either side of and beneath the turbinated body.

After this is done the diseased area is exposed to further examination, and, if need be, to more extensive operation by curettement. In other words, the obstructions within the "vicious circle" should be obliterated.

V. When the polypi spring from the superior meatus, the problem

involved is sometimes quite complex and perplexing. The posterior ethmoidal and sphenoidal cells may be involved, necessitating their complete exposure by anterior rhinoscopy. To do this it is ordinarily necessary to remove the entire middle turbinated body, as described on pages 231 and 232.

No arbitrary rules can be laid down in a text-book for the guidance of the surgeon. He must study the facts in each case, and arrive at a conclusion as to the best course to pursue. The foregoing operations are sometimes advisable if it is hoped to effect a permanent cure of the nasal polypi. These operations are usually only described in connection with the subject of empyema of the nasal accessory sinuses. I have described them in connection with polypi in order to emphasize the significance and importance of these growths, as pointing to conditions much more important than the polypi themselves. While in some cases it may not be shown that the polypi have much significance, nevertheless, in my experience, the more nearly I have treated polypi as though necrosis and suppuration were associated with them, the more satisfactory have been my results.

For timid patients non-surgical treatment may be recommended, as the injection of a saturated solution of the sulphate of zinc, or a solution of tannic acid into the substance of the polypi. I have occasionally used tannic acid with satisfactory results. A few minims should be injected with a hypodermic syringe into the body of the tumor. Within two or three days it shrinks and sloughs away. In the aged or the infirm it is usually inadvisable to recommend measures more radical than the simple removal of the polypi, as the danger from shock and acute infection is greatly increased in these subjects.

Papilloma.—Papilloma of the nose is rare, but when it occurs it appears as a corrugated red tumorous mass growing either from the inner or inferior surface of the inferior turbinated body, the septum, or the posterior end of the inferior turbinated body. The subjective symptoms are those of a partial nasal stenosis, the patient often only consulting the physician on account of nasal "catarrh."

Treatment.—The treatment consists in the thorough removal of the growth with a snare or nasal scissors. The growth of the surrounding tissues should be anesthetized by the local application of a 5 to 10 per cent. solution of cocaine, after which the tumor is excised. After the bleeding has ceased the wounded surface should be mopped dry and cauterized with the galvanocautery. This is done to prevent a recurrence of the growth. When papilloma recurs in a patient forty or more years of age, the possibility of carcinoma should be suspected.

Fibroma.—Fibroma of the nose is characterized by the presence of a dense fibrous growth containing bloodvessels and no mucous glands, with slowly increasing nasal obstruction. The growths vary in size, are smooth and pale pink in color. They are firm to the touch or probe pressure, though not so dense as bone or cartilage. They may be sessile or pedunculated (Fig. 187). If pedunculated, they are movable like a polypus, though their consistency is quite different.

They are usually attached to the septum, floor of the nose, or to the turbinated bodies. They sometimes have multiple attachments, owing to the inflammatory reaction excited by their presence.

Treatment.—The treatment consists in their complete removal with a snare, cutting forceps, or, in extreme cases, the resection of the superior maxilla may be necessary. In those cases wherein the tumor is pedunculated and comparatively small the removal with the cold-wire snare or the author's turbinotome is the easiest and best method to pursue.

When the growth is sessile and large it may be removed piecemeal with cutting forceps, or at least so much of it that the snare can be passed over the balance. This procedure may be done under cocaine anesthesia. When the growth is so large that it invades the surrounding structures of the nose, and extensive adhesions are present, it may become necessary to resort to a temporary resection of the superior maxilla to eradicate it.

Fig. 187

Fibromyxoma removed from the epipharynx. Actual size. (Specimen kindly loaned by A. G. Wippern.)

The operation as given in *Surgical Technique*, by Drs. von Esmarch and E. Kowalzig, is as follows: Osteoplastic, or temporary, resection of the upper jaw (von Langenbeck, 1861) is performed for the removal of non-malignant fibrous or cavernous tumors which originate from the base of the skull, fill the nasal part of the pharynx (nasopharyngeal space) and force themselves into the maxillary sinus, or through the sphenomaxillary fossa into the temporal fossa (retromaxillary tumors).

By reflecting a portion of the upper jaw upward, which has been sawed through, but which remains in connection with the soft parts, the tumor is completely exposed, so that it can be cut off from the base of the skull with a knife or scissors; this portion of the upper jaw is then replaced and the skin is sutured over it.

Von Langenbeck proceeds as follows: 1. An external incision is made down to the bone in the form of a curve from the external angle of the nostril to the middle of the zygomatic arch (Fig. 188).

2. Separation of the insertion of the masseter muscle from the lower margin of the malar bone division of the buccal fascia.

3. After the lower jaw has been pressed downward by a gag inserted at the angle of the mouth on the healthy side the right index finger is forced into the sphenomaxillary fossa between the tumor and the upper jaw and then through the distended sphenopalatine foramen as far as the nares; along the finger an elevator is carried, and on it a fine metacarpal saw is introduced into the pharynx. The left index finger, introduced from the mouth into the pharynx, catches the point of the saw.

4. Horizontal division (by sawing) of the upper jaw above the alveolar process as far as and into the pyriform aperture (Fig. 188). In operations on the right upper jaw, the left index finger is forced into the maxillary fossa, and the operator saws toward it from the nasal passage.

5. Make the external incision down to the bone in the form of a curve from the root of the nose along the lower orbital margin, meeting the first skin incision at the zygomatic arch (Fig. 188).

6. After the external lower angle of the orbit and the angle between the temporal and the frontal process of the malar bone have been freed from the soft parts the zygomatic arch is sawed through in the middle from within outward (Fig. 188); next, the frontal process of the malar

Fig. 188

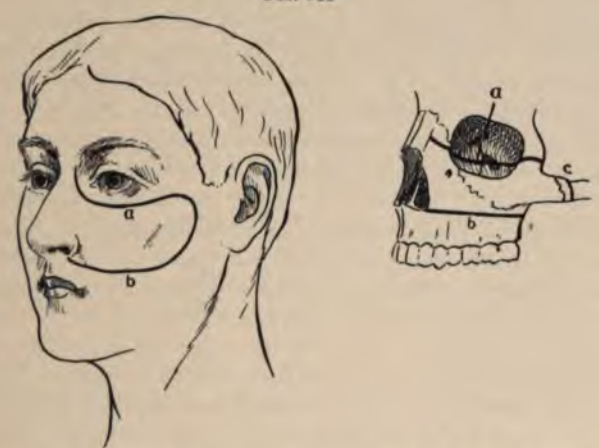

Von Langenbeck's operation for the temporary excision of the superior maxilla. *a b* (large figure), the external skin incision; *c*, the zygomatic arch is first sawed through within outward; *a*, next, the frontal process of the malar bone is sawed with a metacarpal saw as far as and into the inferior orbital fissure, the orbital plate of the inferior maxilla as far as the lacrymal bone closely below the lacrymal fossa, and, finally, the middle of the nasal process of the superior maxilla as far as the nasal bones are divided. The contents of the lacrymal canal should be carefully guarded from injury. *b* (small figure), horizontal division, with a saw, of the superior maxilla above the alveolar process as far as and into the pyriform aperture.

bone as far as and into the inferior orbital fissure, the orbital plate of the upper jaw as far as the lacrymal bone closely below the lacrymal fossa, and, finally, the middle of the nasal process of the upper jaw as far as the nasal bone are divided with a metacarpal saw, protecting the organs which constitute the lacrymal duct.

7. By means of an elevator inserted under the malar bone the excised piece of the upper jaw is lifted up toward the medium line, like the lid of a box. The sutural connection between the nasal bone and the upper jaw, in most cases, breaks during the maneuver.

8. With a broad elevator the tumor, now laid bare, is lifted out of the sphenomaxillary fossa, and the base is detached from the under surface of the skull with a knife, scissors, or thermocautery. Finally, the

resected portion of the upper jaw is replaced in its former position and the wound of the skin is closed by means of careful suturing.

For the better protection of the branches of the facial nerve, O. Weber placed the nutritive bridge of the upper jaw, which must be turned up, externally upon the zygomatic arch, and by nicking it on the line of its suture with the zygomatic process of the temporal bone, he turns the zygomatic arch over in an outward direction. The external incision has already been described. The saw incisions are in other respects the same as in the preceding method (Fig. 188).

Adenoma.—Adenoma bleeds so readily upon examination with a probe that sarcoma is at once suggested. A microscopic examination, however, reveals the true character of the growth. They grow from the septum or the ethmoidal region and produce rapidly increasing nasal stenosis. Adenoma, like polypi and papilloma, has a strong tendency to recur unless thoroughly removed. It consists of a simple hyperplasia of gland structure having its type in the acinous or tubular glands. It also has a tendency to malignant degeneration.

Treatment.—The treatment should consist in the total removal of the tumor. In order to ensure this, its base should be cauterized or curetted. The bleeding attending the removal of adenomata is considerable, but may be readily controlled by a nasal tampon of sterile gauze. It is bad practice to tampon the nose, as it is a septic field, and when it becomes necessary to do so, it is advantageous to moisten the gauze with the compound tincture of benzoin to prevent decomposition of the secretions and saprophytic absorption.

Lymphoma.—Lymphoma of the nose is characterized by a smooth tumorous mass, pinkish red in color, and less dense in consistency than fibroma. It is not common and requires a microscopic examination to make a positive diagnosis. The treatment is the same as for polypus and fibroma.

Angioma.—Angioma of the nose is rare (Kahn), and consists of a distention of existing bloodvessels rather than of new-formed ones. According to D. Braden Kyle the distention is due to changes in the bloodvessel walls from deficient nutrition rather than to mere congestion.

Symptoms.—The symptoms are those of more or less nasal obstruction, epistaxis, and a reducible and pulsating tumor. The nasal obstruction is proportionate to the size of the growth. Pressure upon the growth materially reduces its size. The pulsation is more pronounced when the tumor is attached to a large artery. If the tumor is attached to a vein, the pulsation is much less and the color is blue, whereas if it is connected with both vein and artery the color will be a dark red.

Treatment.—The treatment consists in the strangulation at the base of the tumor. The object of the strangulation is to cause closure of the bloodvessels supplying the tumor. If the strangulation is performed too quickly the vessels are not closed and hemorrhage from their severed ends results; by gradually tightening the wire loop the vessels close and bleeding does not follow.

The galvanocautery loop is also well adapted for the removal of these

growths, when easily accessible and pedunculated, as it sears over the ends of the vessels and prevents subsequent hemorrhage. When the growth is sessile silk ligatures may be passed through it and tied, thus strangulating a portion with each ligature. Cocaine anesthesia is all that is necessary for either of the procedures.

Osteoma.—Osteoma[1] of the nose and the accessory sinuses is rare. It may occur in any of the accessory sinuses, but is more common in the frontal. It may invade the nasal and orbital cavities when growing from the sinuses. It sometimes springs from the inferior turbinated bone and occludes the nasal chambers. Cases have been reported having their origin from the nasal process of the superior maxilla.

Pathology.—Osteoma is usually composed of dense, compact, cancellous, horny tissue of congenital or postnatal matrix of osteoclasts, and usually arises from the periosteum, though it may arise from the medullary portion of the bone. Some are soft and spongy, with a dense capsule of bone, while others are dense throughout their substance. The spongy type occurs most frequently. They are in some instances pedunculated, the pedicle being composed of either spongy bone or soft connective tissue and mucous membrane. The cases seen clinically vary in size from a small walnut to a goose egg.

Symptoms.—As the nasal chambers are usually invaded, nasal obstruction is a prominent symptom The growth of the tumor externally produces more or less marked deformity, and in some instances the resemblance to horns is so great that the cases are referred to as "horned men." In some instances they present the "frog-face" type of countenance, especially when both sides of the nose are involved in the region of the infra-orbital ridge, as in Dr. Stein's case. Palpation of the tumor, whether intra- or extranasally, yields a sense of bony hardness. The lacrymal duct may be occluded. The mucous membrane covering the tumor is usually pale, thin, and not eroded. Transillumination of the maxillary sinus may show obstruction to the rays of light. If constant mouth breathing is present it gives rise to epipharyngeal catarrh. In Stein's case there was inability to rotate the left eye inward. There was external divergence of two lines, pupil widely dilated and fixed, not responding to either light or accommodation. The fundus was normal.

Diagnosis.—The diagnosis is largely based upon the microscopic examination of the tissue.

Treatment.—In those cases of syphilitic origin the iodides are of value. The removal of the bony growths is usually the best treatment. The technique of the operation varies with each case. In the 23 cases growing from the frontal sinus reported by Boenhaupt, 11 communicated with the cranial cavity. It is obvious, therefore, that osteoma of this region is most serious from a clinical and surgical point of view.

In the removal of osteoma attempt to find a pedicle, or, failing in this, enucleate the tumor rather than attempt to chisel or drill into its substance, as it is often so dense as to resist these instruments.

[1] I am indebted to Dr. Otto Stein's paper on "Symmetrical Osteoma of the Nose" for most of the data on this subject.

Lipoma.—Lipoma of the nose may be external or internal, and is usually pendulous. When external it usually affects the alæ of the nose. The case illustrated involves the tip of the nose (Fig. 189).

Fig. 189

Lipoma of the tip of the nose. (Pynchon's case.)

MALIGNANT NEOPLASMS OF THE NOSE.

Carcinoma.—Carcinoma of the nose is more rare than sarcoma, and usually begins in the anterior portion of the nasal structures, as the greatest irritation occurs at this point.

Diagnosis.—The diagnosis is based upon (*a*) the presence of an intense irregular lancinating pain; (*b*) a mucopurulent secretion, which if ulceration is present is admixed with blood; (*c*) the characteristic ozena or stench of cancer; (*d*) nasal stenosis more or less marked according to the stage in which the disease is observed; (*e*) impairment of vision if the ethmoid cells are involved; (*f*) ulceration of the growth if in an advanced stage; and (*g*) cachexia. (*h*) In addition to the foregoing

clinical symptoms it is usually necessary to remove a portion of the growth for microscopic examination. D. Braden Kyle properly calls attention to the necessity of observing two precautions in securing the specimen, namely: "(1) That there should be as little laceration and irritation of the parts as possible; (2) that the portion removed should not involve directly the ulcerated area, which will contain inflammatory embryonic connective tissue. As pointed out by J. Bland Sutton, this cannot be differentiated from sarcoma or from a simple inflammatory process with ulceration. If, however, the specimen is taken early, before ulceration has occurred, this source of error may be obviated."

Prognosis.—The prognosis is always grave.

Treatment.—The surgical treatment of carcinoma of the nose, except in the very early stage, is contra-indicated.

The palliative treatment consists in the local application of orthoform powder to ease pain, and local applications of dilute hydrochloric acid and formalin to the ulcerated areas.

Sarcoma.—Sarcoma of the nose is of slow growth, and is less malignant than sarcoma in other parts of the body. Unlike carcinoma it occurs most often before the fortieth year of life, and is not uncommon in infancy and childhood.

Diagnosis.—The diagnosis is based upon (*a*) progressive nasal stenosis; (*b*) a mucopurulent nasal secretion, which, in the advanced stage, becomes sanguinolent; (*c*) more or less slight pain in strong contrast to the intense pain in carcinoma. (*d*) The age of the patient, if below forty years, is also of diagnostic significance, though carcinoma occasionally occurs before this age; (*e*) finally, the diagnosis must be made by submitting a specimen of the growth to microscopic examination.

Prognosis.—The prognosis is grave, though not so grave as carcinoma. When operated early there is a fair chance of recovery. In one of my cases operated by Ollier's method (Fig. 190) there has been no recurrence of the sarcoma after five years.

Treatment.—The treatment in the early stage is surgical, especially in view of the slighter malignancy of nasal sarcoma. The growth may be removed with a curette, or galvanocautery through the nasal orifices, or, if extensive, an external operation may be required.

Ollier's Operation. This operation is performed under general anesthesia, with the head of the patient hanging over the end of the table in Rose's position. Postnasal tampons should be introduced to prevent the blood escaping into the epipharynx and larynx. An incision extending from the left ala of the nose, upward over the bridge of the nose, and thence downward to the right ala of the nose, should be made through the cutaneous tissue (Fig. 190). A Gigli saw should then be placed at the bridge of the nose and all the bony structures along the cutaneous incision severed.

The nose, thus temporarily resected, is then turned downward over the mouth. This having been done, the growth should be enucleated by blunt dissection, if possible, or if this cannot be done it should be removed by dull curettage. A sharp curette should not be used, as it

leaves the lymphatic vessels open and favors extension by metastasis and septic infection. The hemorrhage may be considerable, hence the postnasal tampons introduced before beginning the operation serve as bases against which strips of gauze may be packed to check it.

In my case, illustrated in Fig. 190, the hemorrhage was very profuse and necessitated the use of normal salt enemata. The transfusion of normal salt solution would have been better, but as arrangements had not been made for it the enemata were substituted. This patient was thirteen years old when I first saw her, and was fourteen when I performed the Ollier operation. She is now nineteen years of age, and is

Fig. 190

Ollier's incision for exposing the nasal cavities for operative purposes.

free from the growth. Bony sequestra have been removed from time to time, and but little ozena is present. The cure is apparently permanent.

Having removed the tumor the incision should be closed by sutures, and the tip of the nose raised into position and fixed with adhesive strips. The stitches should be removed on the fifth day. The nasal wound should be packed with gauze impregnated with bismuth or the compound tincture of benzoin, to prevent decomposition and saprophytic infection. The intranasal dressing should be removed and renewed daily.

CHAPTER XIV.

EPISTAXIS (NASAL HEMORRHAGE). RHINOSCLEROMA. FURUNCULOSIS. SCREW-WORMS.

EPISTAXIS (NASAL HEMORRHAGE).

EPISTAXIS is a nasal hemorrhage, that is, a bleeding from the interior of the nose. While the hemorrhage is usually from the anterior portion of the septum (90 per cent. according to Casselberry), it may occur from any portion of the nasal mucosa. The bleeding is not often serious in character, though several deaths have occurred therefrom. It is most serious in bleeders, or hemophiliacs, arteriosclerosis, valvular heart lesion (right side), sarcoma, and pressure on the veins of the neck by aneurysm, bronchocele, and intrathoracic tumors.

Etiology.—(*a*) Anterior deflection of the septum is the predisposing cause of hemorrhage in a large majority of the cases. This portion of the septum is richly supplied with blood from the septal artery, a branch of the superior coronary, and is exposed to the ingoing current of air, which is often loaded with foreign particles. The air, furthermore, dries the secretions on the anterior portion of the septum, especially if it is deflected in this location. The membrane is quite thin in this area, as anyone who has done a submucous resection of the septum can testify. Slight erosion of the mucosa readily gives rise, therefore, to nasal hemorrhage.

(*b*) Catarrhal inflammation causes chronic hyperemia of the mucous membrane, hence the increased blood in the parts contributes to the epistaxis.

(*c*) A number of febrile diseases are often attended by epistaxis. The diseases most commonly thus characterized are typhoid and diphtheria, though other infectious fevers are sometimes attended by nasal bleeding. "Black diphtheria," or hemorrhagic nasal diphtheria, is attended by a destructive degeneration of the nasal mucosa, submucous hemorrhage, and epistaxis.

(*d*) The veins on the anterior portion of the septum are sometimes varicosed and give rise to hemorrhage.

(*e*) Obstruction to the portal circulation may be attended by nasal hemorrhage.

(*f*) Suppression of the menstrual flow and of a severe hemorrhoidal hemorrhage is sometimes attended by a vicarious nasal hemorrhage.

(*g*) Traumatic epistaxis may result from picking the nose with the finger nail or violently blowing it with a handkerchief. Intranasal surgery is frequently followed by severe nasal hemorrhage. This is especially true after operations upon the middle turbinal, the ethmoidal

cells, and the swell bodies or erectile tissue of the inferior turbinated body. The middle turbinated and the ethmoidal cells receive a generous blood supply from the anterior and posterior ethmoid arteries (Fig. 3). External violence to the nose is often followed by epistaxis or the so-called "bloody nose."

(*h*) A perforating ulcer of the septum frequently gives rise to epistaxis. The vessel walls are broken down in the destructive process, and the granulation tissue upon the border of the perforation bleeds easily upon slight provocation.

(*i*) Certain constitutional diseases, as hemophilia, Bright's disease, purpura, scorbutus, chloremia, leukemia, and arteriosclerosis are characterized by nasal hemorrhage, for obvious reasons. Syphilis and tuberculosis of the nose also give rise to epistaxis.

(*j*) Sarcoma of the nose, like sarcoma elsewhere, is often attended by hemorrhage.

Treatment The treatment of nasal hemorrhage in most cases is simple enough, as the local application of cocaine or of adrenalin readily stops it. In other cases, however, when the cause is a constitutional disease, a growth pressing on the veins of the neck, or when the trunk of one of the larger septal arteries, as the anterior ethmoidal, is severed in an intranasal operation, the bleeding is not so easily checked.

The hemorrhage may usually be checked by one of the following procedures:

1. Hot nasal irrigation is quite effective in many of the cases when the epistaxis is not due to some grave disease. The temperature of the water or normal salt solution should be as high as can be tolerated, or about 130°.

2. Ice-water may also be injected into the nose with advantage in operative hemorrhage while the patient is under an anesthetic. Only two or three injections of four ounces each should be used, as to use more might produce serious shock to the brain by sudden or excessive chilling. I have frequently resorted to this method of treatment at the close of nasal operations when the hemorrhage was profuse, with the most gratifying results.

3. The local application of cocaine or adrenalin often checks the hemorrhage when it is of capillary origin. If blood clots are present, the nose should first be cleared. The adrenalin extract may be given internally for its hemostatic effects.

4. Blood clots are sometimes allowed to remain in the nose, with the idea that they will finally check the hemorrhage. This procedure is based upon an erroneous idea. The blood clots only serve to shield the bleeding area from such local medicaments as may be used, thus hiding the bleeding point from view The bleeding usually continues beneath the clots, hence they should be thoroughly removed at once to expose the bleeding area to inspection and to make it possible to apply such local remedies as may be deemed necessary.

5. Astringent remedies, as the nitrate of silver in 5 to 20 per cent. solutions, may be made from time to time in persistent oozing.

6. The application of the actual cautery has sometimes proved a speedy and efficient means of controlling the bleeding; a flat-pointed electrode should be used at a cherry-red heat for this purpose.

7. Local pressure over the bleeding point for a few minutes will sometimes control the bleeding.

8. Tampons in the nose should only be resorted to in those cases in which the bleeding persists in spite of all other measures. Tampons in the nose as a general proposition should be avoided, as they are apt to give rise to conditions favorable to sepsis. The more completely the nasal chambers are packed with gauze the greater the danger Hence, a postnasal tampon followed by an anterior one is the most dangerous of all. Resort to this method of packing the nose in epistaxis should be avoided except in an extreme emergency.

When the bleeding is from the anterior portion of the septum, and it becomes necessary to introduce a tampon, I would advise a Bernay tampon cut into the form of a nasal splint, as recommended by Simpson. It absorbs less of the secretions, and is easily introduced and removed without further injury to the diseased mucous membrane (Fig. 70).

RHINOSCLEROMA.

Synonyms.—The evidence seems to be almost convincing that a rare lesion described as chorditis, chronic hypertrophica inferior, and what is known as Stoerk's blennorrhea are identical with rhinoscleroma.

Definition.—Rhinoscleroma is characterized by a cartilage-like hardness and nodular enlargement of the nose and other portions of the upper air passages. The affected tissues have no tendency to ulcerate or to inflammatory reaction, either in the growth or in the contiguous parts, although it frequently affects the other divisions of the respiratory tract.

Etiology.—But little is known of the etiology of the disease beyond the fact that it is due to a specific microörganism, the bacillus of rhinoscleroma, and that it is chiefly confined to Austria and southwestern Europe. About 800 cases have been reported, and of these, about 20 occurred in America, but the large majority of them were from Poland and Austria. It usually begins in youth, the greater number being observed between the ages of fourteen and forty-five. Sex seems to have no influence. Heredity seems to be a negative factor, though there is apparently a family predisposition to the disease. It is now generally regarded as a contagious disease.

Bacteriology.—The hard, cartilage-like nodules affect the skin and the mucous membrane of the nose, pharynx, larynx, and trachea. It spreads with greater freedom in the mucosa than in the skin. The hard, nodular masses, or plaques, contain the encapsulated bacillus of rhinoscleroma, which is similar to Friedlander's bacillus, though the latter is not always encapsulated. The bacillus of rhinoscleroma is more rod-shaped, and stains by Gram's method, is motile, non-spore bearing,

and aërobic. It always has a capsule in culture, as well as in the tissues. It occurs singly and in pairs. Gelatin plates show yellowish-white granular bodies in two or three days. In gelatin tubes the growth appears along the needle track as a whitish granular line, with an almost hemispherical elevation on the surface. The growth in the tube has the appearance of a round-headed nail. When grown upon agar it appears as a dirty whitish moist layer on either side of the needle track. On potato the growth is creamy white. It grows rather rapidly at a temperature of 37° C. It is pathogenic for mice, guinea pigs, and rabbits.

Pathology.—The histological changes are inflammatory in character and usually begin on the nasal septum, trachea, or larynx. In rare instances the reverse course is pursued. The skin and mucous membrane of the nose assume a smooth nodular appearance of cartilage-like consistency, which pits little or none upon probe pressure. The parts are sensitive to the touch, but are otherwise free from pain. Kaposi has likened the external appearance of the nose to keloid. Goodale (Posey and Wright) gives the following description of the pathological changes:

"In the nose and larynx the affected tissues are seen histologically to consist of certain typical elementary lesions. The substance of the swelling is composed of large plasma cells, irregularly distributed in all layers of the mucous membrane, and in the submucous tissue. They accompany the bloodvessels in the new portions of the growth. The plasma cells do not contribute directly to the hypertrophy, but it is possible that they become changed partly into spindle cells, and then give rise to the formation of new fibrillary tissue. Two forms of retrograde metamorphosis occur in the plasma cells. These may be transformed into swollen, hydropic, so-called Mikulicz cells, or into hyaline degenerated cells, probably identical with the so-called Russell's fuchsinophiles, described under Colloid Degeneration. The hydropic cells lie close together, have a distinct contour and spongy cytoplasm dilated into large masses, in which there is a smaller mass within a faceted nucleus. In this stage one often sees from six to eight bacilli in the cells near the nucleus which lie always at regular distances.

"This stage appears, however, to be rapidly finished, and when the cell membrane breaks, the fluid contents, together with some of the bacilli, find an exit and fill some of the nearest lymph spaces. These cells are, however, intimately related to the direct action of the bacilli."

Symptoms.—The changes in the external appearance of the nose, while presenting many of the characteristics of keloid, are, nevertheless, rather easily differentiated from it by the whole symptom complex. The tissues at the tip of the nose become infiltrated, hard, and nodular. The nose broadens and becomes firmly fixed to the face. The tissues become more and more thickened, until the breathing is more or less occluded. The color of the skin varies from a red to a bluish or brownish red. The skin is traversed by small bloodvessels, and is usually slimy, though it may be finely wrinkled. The extension of the growth is rather slow, requiring several months to reach the epipharynx. The

infiltration often interferes with the movement of the lips, the fauces, and the larynx, and very rarely of the eyes and ears. There is no tendency to ulceration and discharge, or to edema and inflammation of contiguous parts.

Laryngeal stenosis may give rise to serious or even fatal dyspnea, otherwise the disease does not materially affect the general health.

Diagnosis.—Rhinoscleroma should be differentiated from syphilis, epithelioma, and keloid. The disease is exceedingly rare in this country, hence it is natural to infer that a suspected case is probably not rhinoscleroma, but that it is either syphilis, epithelioma, or keloid. This is not necessarily true, however, as 20 authentic cases have been reported. Rhinoscleroma presents a hard, nodular growth, usually beginning at the anterior end of the nose, spreading gradually to the deeper recesses of the respiratory tract, without pain, but some tenderness upon pressure, and without tendency to ulceration or inflammation of the surrounding tissues. In syphilis there is inflammation, while in epithelioma there is pain, ulceration, and discharge. In keloid the similarity is often so striking that it may be necessary to demonstrate the absence or presence of the germ of rhinoscleroma in order to make a differential diagnosis.

Treatment.—Thus far the extirpation of the diseased tissue has been tried with a negative result as to the cure of the disease. The surgical extirpation of the diseased tissue has almost invariably been followed by recurrence. Tracheotomy should be performed when suffocation is imminent. Thiosinamin affords a ray of hope, as it appears (Glass) to soften the tissue, as it does in keloid. A reliable method of treatment has not been discovered. Freudenthal suggests the injection of Coley's fluid, as in sarcoma. The iodides and mercury have been tried with but little success. The *x*-rays have been used by Emil Mayer with some apparent success, though it is probable that this mode of treatment will prove disappointing, as have all other methods of treatment.

FURUNCULOSIS OF THE NOSE.

Definition.—Furunculosis of the nose is a superficial abscess formation in any part of the nose, and does not differ materially from the same process in other parts of the body.

Etiology.—The abscess is usually located on the anterior portion of the septum, *i. e.*, that portion covered by skin, and is usually due to an injury, as from picking the nose. One or more may be present at a time or quickly succeed one another. The hair follicles of the vestibule offer favorable sites for their formation. If they recur frequently the cartilaginous septum becomes involved. Recurrences most commonly take place in the young or the middle aged, and especially in those with an impoverished state of the blood. The infectious fevers are often attended by nasal furunculosis.

Symptoms.—There is more or less throbbing pain, swelling, redness, and tenderness. The elevated areas characteristic of boils may be seen

upon inspection. When they are well advanced, or, to use a vulgar expression, "ripe," the centre of the elevation is yellowish from the contained pus. The pain is often intense, on account of the closely attached and unyielding nature of the tissue composing the parts

Treatment.—If seen early, before pus formation, the application of a 50 per cent. solution of ichthyol or a 10 per cent. glycerin solution of carbolic acid on a pledget of cotton will often abort the process. If they have gone on to pus formation they should be incised from within the nasal cavity with a sharp bistoury to avoid an external scar. After incision their cavities should be irrigated with warm boric acid solution and the tincture of iodine applied.

PHLEGMONOUS RHINITIS.

This is somewhat different from furunculosis, in that it is an abscess formation affecting the nasal mucous membrane. The condition is rare except as the result of an operation or other traumatism. (See Abscess of the Septum.)

SCREW-WORMS IN THE NOSE.

Screw-worms in the nose have been reported by M. A. Goldstein, Hal Foster, and J. S. Steele in most interesting and instructive articles, wherein it is shown that their invasion of the human being is not as rare as might be supposed. (See Foreign Bodies in the Ear.)

The screw-worm fly is attracted by a foul-smelling discharge from the nose or the ear, and its presence in the nose need be but a moment for it to deposit its eggs. Dr. Steele narrates a case illustrative of this point. A railway engineer, while walking across the plaza of a Mexican city, inhaled a fly into one nostril, which he immediately blew out through the other. Twenty-four hours later fulness and pain between the eyes was noted, which increased for three days, when he came under observation. He was affected by specific rhinitis with necrosis of the nasal septum, which accounted for the fly being attracted to his nose. About one hundred worms were removed with the douche and forceps. Calomel was used by inhalation, which seemed to exterminate all that remained, as they gave rise to no further symptoms.

Foster removed two hundred and seven worms from the nose of an old Irish woman who was subject to epileptic fits, during which she would fall to the ground. Following one of these seizures she noted an itching of the nasal mucosa, which was accompanied by headache and sneezing. She was told that she had hay fever, and large doses of quinine were administered. Two days later the nose began to bleed and to give forth a very offensive discharge. The eyes were closed from swelling of the subcutaneous tissue of the face, and she was in such discomfort that she was unable to sleep.

Upon examination the nostrils were found to be entirely filled with

worms. Inhalations of chloroform were administered, which rapidly rendered them lifeless, after which they were readily removed with forceps. The live worms clung with tenacity to the tissues when force was applied for their removal. There was great destruction of tissue, and the temperature was 102°. There was a bulging on the anterior part of the nose as a result of the penetration of the worms at this point.

Goldstein's case was that of a farm laborer who slept outdoors in a hammock. He was affected with syphilitic rhinitis, which offered an ideal attraction to the Texas screw-worm fly. When examined the nose was found to be filled with the eggs of the fly, five hundred being removed with the curette. The curettage was thoroughly done, considerable tissue being removed along with the eggs. Forty-eight hours later there was excruciating pain in the nostrils, which were completely occluded. The skin over the frontal sinus was red and tightly drawn. On the sixth day there was swelling over the dorsum of the nose near its centre. This was incised and considerable pus was discharged. Several worms were subsequently removed through this opening.

Chloroform is the most effective remedy, and may be administered by inhalation or in diluted solution with a syringe. Calomel fumigation is also of value, but does not act as quickly as chloroform. Steele's case shows that its effects were apparent after about four hours, whereas chloroform is effective within a few seconds or minutes.

FOREIGN BODIES IN THE NOSE.

Foreign bodies in the nose may be animate or inanimate.

Animate or live objects, as the larvæ of certain flies, commonly called maggots, are deposited in the nose in the form of eggs by the fly, and after a short period are hatched as larvæ. They may burrow into the tissues, even to the point of making their exit through the skin. They may penetrate the wall of the nose in any direction, hence may enter the cranial cavity or the sinuses.

The treatment of animate foreign bodies or larvæ in the nose may be either medical or surgical. If the larvæ are confined to the nasal chambers they may be removed by injecting a solution composed of equal parts of chloroform and water into the nose. While the solution causes pain it is nevertheless necessary to use it, as the larvæ cannot be removed until they are killed, and chloroform accomplishes this end. If necessary the patient may be given a general anesthetic before injecting chloroform into the nose. After the injection of the chloroform into the nasal chambers the larvæ may be easily removed with forceps or curette. (See Screw-worms in the Nose.)

Inanimate foreign bodies include almost every kind of inert substance small enough to be introduced into the nose, and some that are too large to be introduced into the nose, at least through the nasal openings. One such case was under my care and gave the history of having received a

wound thirty years previously from the explosion of a musket. The left eye was destroyed at the time. Upon removal of the foreign body it proved to be the breech pin of the musket which exploded thirty years previously. The mass of iron, as large as the first joint of the thumb, still preserved its mechanical form, as the screw threads and the tubular space for the flash powder. The cap pin was also intact. In most instances the foreign body is voluntarily introduced by the patient. Young children have an inordinate desire to introduce such substances into their noses, hence most cases occur in young children. Idiots and the insane also delight in putting foreign substances into their noses.

The treatment is generally easily accomplished through the anterior nasal opening without the use of a general anesthetic, though in many cases it will be necessary to administer a general anesthetic. Forceps with good, grasping tips should be used to seize the foreign body and, after dislodging it, to remove it.

CHAPTER XV.

THE SURGICAL CORRECTION OF EXTERNAL NASAL DEFORMITY.

As each case is of necessity a law unto itself, it is impossible to describe operative procedures applicable to all types of deformed noses. Then, too, the patient's idea of nasal beauty varies to such an extent that his opinions, as to the cosmetic results, must be taken into consideration. I shall, therefore, only present a few suggestions as to the more common nasal deformities.

The Aquiline or Hump Nose.—Occasionally the possessor of an aquiline nose, especially if the "hump" is quite prominent, is anxious to have the "hump" removed or reduced. This may be done by external incision, or subcutaneously through the nose. Preference should be given to the intranasal route, as it is not attended by a visible scar. I cannot conceive of a deformity of this kind that may not be removed *via* the nasal chambers.

Fig. 191

External operation for the removal of the "hump" from the nose.

External Operation.—If, however, an external incision is preferred, it should be made in the median line of the nose, over the area of deformity. The skin and periosteum should then be raised on either side, exposing the prominent nasal bones (Fig. 191). The elevated flaps should be pulled aside by retractors in the hands of an assistant. The surgeon should then carefully remove enough of the projecting nasal bones to reduce the deformity to the degree suggested by the patient. The skin and periosteal flaps should then be coaptated by adhesive strips and allowed to heal by first intention. Stitches should be avoided if possible, as they add to the prominence of the linear scar in the median line of the nose. The adhesive strips may be removed at the end of from three to five days.

Intranasal Operation by the Author's Method.—This method of operating should usually be chosen, as it is not attended by an external scar.

Technique.—(*a*) General anesthesia.

(*b*) Thoroughly irrigate the nasal chambers with warm salt or boric acid solution, or otherwise clear the nose of the crusts, secretions, and bacteria.

(*c*) Introduce a scalpel into one nasal chamber until its point reaches the lower border of the nasal bone, then make an incision through the mucous membrane and pass the blade of the knife between the nasal bone and the skin covering it.

Fig. 192

The author's reverse chisel for subcutaneous correction of nasal deformities.

Fig. 193

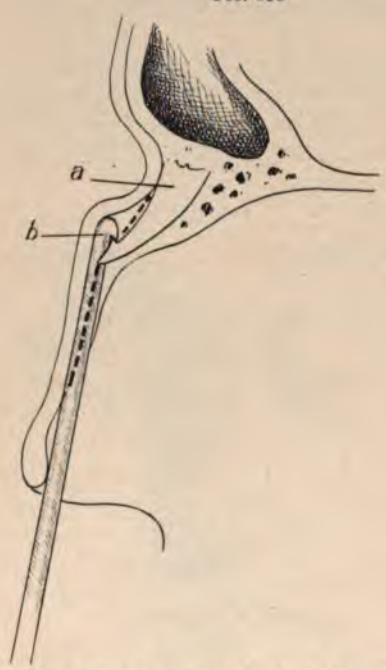

Fig. 194

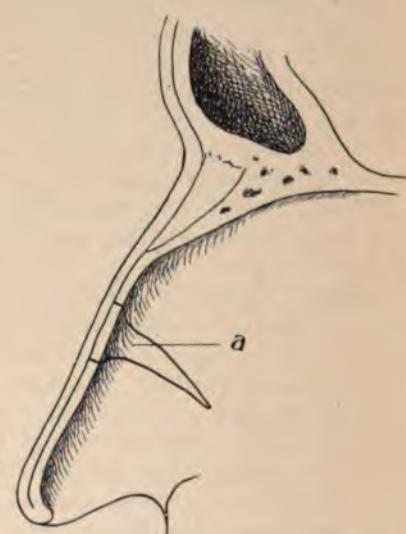

Fig. 193.—The author's method of removing the "hump" from an excessively aquiline nose. *a*, the deformed nasal bone; *b*, the author's reverse chisel reducing the "hump."

Fig. 194.—The author's method of shortening a long, overhanging nose. The triangular piece of cartilage *a* is removed *via* the nostril and the gap closed by lifting the tip of the nose upward and securing it in place with adhesive straps applied externally. At the end of a week or ten days the straps are removed and union is complete.

(*d*) Withdraw the knife and introduce a small elevator of the Freer type and separate the skin from the anterior portions of both nasal bones.

(*e*) Withdraw the elevator and introduce the author's draw chisel (Fig. 192), and with a downward and forward pull (parallel with the ridge of the nose) shave the anterior borders of the nasal bones until the hump is sufficiently reduced (Fig. 193).

(*f*) Have the skin over the operative field gently massaged every three hours to prevent the deposit and organization of a plastic exudate over the bones previously reduced. Heat, or the leukodescent light applied over the nose, will also control the amount of inflammatory deposit.

(*g*) Compression with a nasal pad and a roller bandage may be used instead of massage, heat, etc., if these modalities of treatment are not available.

The Long or Drooping Nose.—This type of nose is occasionally seen. I have twice corrected the deformity. The method pursued by me has been the resection of a wedge-shaped piece of the nasal septum through the nasal orifice.

Fig. 195

Congenital saddle nose due to cretinism.

Technique.—(*a*) Cocaine anesthesia as for the submucous resection of the septum.

(*b*) Make two incisions through the entire thickness of the septum, as shown in Fig. 194. Connect the divergent ends of the incisions at the ridge of the nose by an intersecting incision, which should separate the cartilage from the skin of the nasal ridge.

(*c*) Remove the triangular piece of cartilage with forceps.

(*d*) Draw the whole end of the nose upward with strips of adhesive plaster.

(*e*) At the end of from four to eight days remove the adhesive strips.

After-treatment.—To prevent local infection and assure firm union of the septal wound, introduce pledgets of cotton saturated with a 10 per cent. solution of ichthyol in glycerin every four hours for three days. The ichthyol is antiseptic and the glycerin promotes osmosis of serum from the bloodvessels and washes away any bacteria that chance to invade the region of the wound.

Remarks.—When the nose is shortened in this way there is no redundancy of skin as it contracts until the normal tension is established.

Paraffin Injection.—The use of paraffin is at the present time past the stage of experimentation, and is, in fact, a well-established procedure in surgery, especially in nasal work The principal use of paraffin is for the correction of congenital and acquired deformities. One of the principal locations for its use is the bridge of the nose for cosmetic purposes, that is, the characteristic saddle nose. The various locations and conditions where paraffin has been used about the ear, nose, and throat are as follows:

1. Saddle noses, following trauma, syphilis, and cretinism. The case

shown in Fig. 195 was due to cretinism The patient is a graduate of the High School of Chicago, and is an intelligent young woman, twenty-four years old.

2. Following operations on the frontal sinus to correct the frontal deformity.

3. To overcome the collapse of the alæ nasi.

4. Intranasal injections into the inferior turbinated body in atrophic rhinitis.

5. Following resection of the superior maxillæ to fill up the defect.

6. Partial reconstruction of the inferior maxillæ following necroses and resection for malignancy.

7. Secondary repair of harelip, where there is great absence of the premaxillary bone.

8. In the region of the postnasal space in cases of speech defect (rhinolalia pata) attending the cleft palate operation or immovable palate.

9. Following mastoid operations to fill up large retro-articular deformities.

The paraffin may be injected either hot or cold, depending upon the firmness of the paraffin required. The hot becomes the firmer after cooling, hence for the correction of a saddle nose the hot paraffin should be used. Cold paraffin should be used intranasally to build up the inferior turbinated body.

The instrument required for this procedure is the paraffin syringe, (Fig. 196), which may be used for either the hot or cold paraffin.

The paraffin which is to be injected hot is kept in an ounce bottle, the cold in tubes, and is especially prepared to fit in the syringe

Technique.—In case hot paraffin is to be used, place the bottle in boiling water until it liquefies, then fill the syringe with it. Turn the screw head from left to right until the paraffin comes out of the needle in the shape of a thread. Then introduce the needle into the cavity to be injected and continue to turn the piston slowly until the desired amount has been injected. In case the cold paraffin is used it is not necessary to first heat the paraffin, but simply use it in the semisolid form in which it comes, by the same process of turning the screw head until the desired amount has been injected.

The opening caused by the introduction of the needle is sealed up by a small pledget of cotton moistened with collodion. Considerable bleeding from this point sometimes occurs, and pressure should be applied for a few minutes or until bleeding ceases. It should then be sealed up.

In submucous injections it is best to insert an antiseptic gauze pad for a few hours to control the slight oozing and prevent possible infection. To prevent the paraffin spreading into the neighboring tissues, especially when a great deal of loose areolar tissue is present, as in the eyelid, in injecting the bridge of the nose, it is good practice to have an assistant hold his fingers firmly against the underlying bone on each side of the area to be injected. Before complete hardening of the paraffin takes place it should be molded to a certain extent. In regard to the operation, it may be performed in one or more sittings according to the discretion of the surgeon. It is safer to inject at several sittings, because one can

always add to the amount of paraffin, but if too much is injected it is very difficult to remove it.

The complications following injection are:

1. Infection.
2. Hematoma.
3. Embolism.

Fig. 196

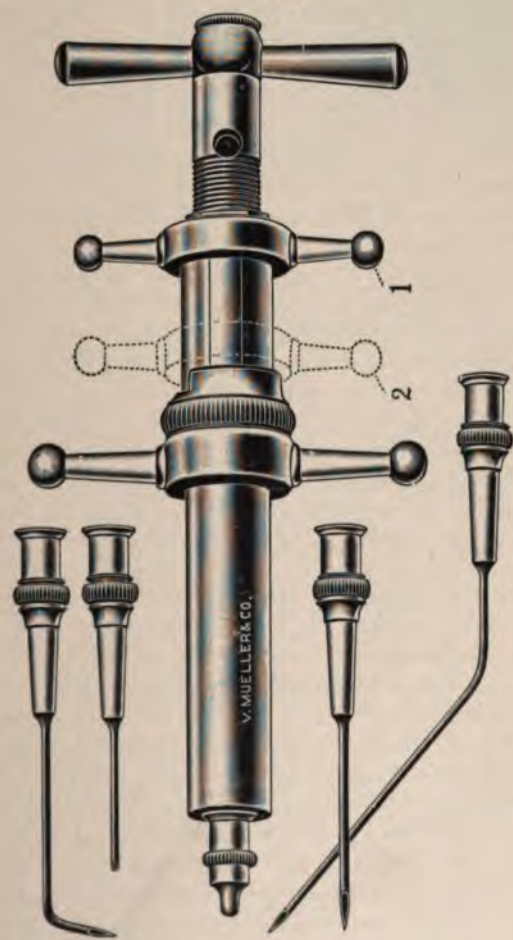

Beck's paraffin syringe.

Each is comparatively rare. The first complication should be guarded against by observing the strictest antiseptic precautions in sterilizing the paraffin, the syringe, the field of operation, and the hands of the operator and assistants.

Hematoma is controlled by pressure, and if it is very large it may require evacuation, followed by the application of ice and afterward warm applications to cause absorption.

Embolism has been reported twice in the literature, and in both cases ether injected hypodermically in dram doses was successful.

The change that takes place in the injected mass is at first a reactive inflammation forming a fibrous capsule, which soon fills with a new trabeculæ, which ramifies the paraffin mass in all directions, until the latter is held in a meshwork of fibrous tissue. It has been found that after a period of six months to a year considerable paraffin has been absorbed, the connective tissue having taken its place. Cases injected several years ago have remained about the same size as when first injected. Such a mass after organization is known as paraffinoma. Exposure to excessive heat, as in foundries and following high long-continued fevers, as typhoid and pneumonia, has very little effect on the injected mass, while traumatism, as a blow on the nose, has changed the contour of an injected nose somewhat.

Special Technique.—Saddle nose and other malformations of the nose.

1. To fill up a defect: Thoroughly prepare the field of operation and place the patient in a recumbent position. Introduce the needle of the syringe beneath the skin and fill up the defect either at one or in several sittings. Do not dissect the skin loose from the underlying bone, as a hematoma will form and become infected.

Stop oozing by compression and close the puncture with collodion-cotton. No after-treatment is required (Fig. 197).

2. To stiffen collapse of the alæ of the nose: The needle point is introduced between the cartilage and the skin along the whole alar area; inject a very small particle of paraffin to bring about the desired effect.

3. Reconstruction of the inferior turbinated body following atrophic rhinitis: Thoroughly cleanse the mucous membrane of pus and crusts. Anesthetize that portion of the turbinated body which is to be penetrated by the needle with a 5 per cent. solution of cocaine. If a stronger solution is used, too much contraction will follow. Use the angular needle (Fig. 197) and introduce the same below the mucous membrane close to the bone, and pass it back as far as the posterior end, guarding against perforating the same. Inject slowly by turning the screw head from left to right, and as the needle is withdrawn a track of paraffin is left along the course of the needle. Apply an intranasal tampon for a few hours. Keep the parts thoroughly clean. It is at times necessary to re-inject the different areas. The mucous membrane may be too thin to retain the paraffin. (See page 161 for a further description.)

4. Correction of the deformity following the frontal sinus operation: Cleanse the skin and introduce the needle point in different directions and insert the paraffin, as the scars are usually very firm and do not easily elevate. Extreme care must be taken not to pass the needle too deep, as the posterior table may be injured.

5. Correction of the defects after the mastoid operation requires a preliminary dissection of the skin, which is usually firmly adherent to the bone. This may be done by making a small incision through which

a small elevator is introduced. Squeeze out all the blood and fill up with the paraffin. Close the opening caused by the elevator by one or two horsehair sutures.

Fig. 197

Schema showing the injection of paraffin to correct "saddle nose."

6. Correction of defects caused by excision or disease of the upper or lower jaw.

One must be guided by the disease present and apply the principles mentioned above. One of the most common defects is caused by necroses following decayed teeth, and secondary periostitis.

COLLAPSE OF THE ALÆ NASI.

Etiology.—Collapse of the wings of the nose is sometimes associated with prolonged nasal obstruction and mouth breathing. Lambert Lack suggests that the open mouth, with the resultant drag on the sides of the nose, and the atrophy of the dilator muscles of the alæ from prolonged disuse are the chief factors in producing the condition. The condition may also be due to senile changes.

Symptoms.—The nasal orifices are greatly narrowed, often mere slits, and the alæ are flaccid and collapse upon inspiration. Under normal conditions the alæ dilate and are firm and resilient.

Treatment.—If the collapse is due to unilateral nasal obstruction the cause of the nasal obstruction should be removed. In some instances this is followed by a cessation of the collapse, especially if the condition is of comparatively recent occurrence. In older cases the collapse of the alæ persists. Lack advises having the patient practise dilating the nostrils against resistance. He has them stand before the mirror for five to ten minutes twice a day and lightly compress the alæ with the thumb and

finger, and dilate the nostrils to their fullest extent. This method gives results in recent cases, whereas in old standing cases in which there is complete paralysis of the dilator muscles it is ineffective. (See Paraffin Injections.)

Soft- and hard-rubber rings (Guye) have been worn to keep the nostrils patulous, but the discomfort attending their use is quite objectionable. Walsham recommends elevating a narrow strip of mucous membrane from the anterior portion of the septum with an attachment above, and then rolling it into a mass at the upper angle of the nostril (Fig. 198), stitching it in position where it mechanically prevents the collapse of the ala. Lambert Lack suggests the most ingenious and apparently the best method in obstinate and troublesome cases. "The operation consists

Fig. 198

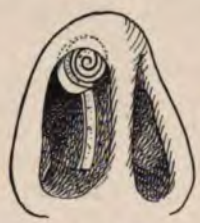

Fig. 199

Fig. 198.—Collapse of the ala nasi connected by a roll of mucous membrane from the septum.

Fig. 199.—Schema showing Lambert Lack's method of overcoming collapse of the alæ nasi. The flaps *a* and *b* are made from the septum, and are about one-eighth of an inch wide. The upper surface of each flap is denuded of mucous membrane, and the nasal walls against which they are reflected is curetted to encourage adhesion. The flaps are held in position by a single suture in each flap.

in turning up a piece of cartilage as well as mucous membrane from the septum and stitching it across the top of the nostril at right angles to the septum, so as to push the ala forcibly outward. An L-shaped incision is made through the mucous membrane on one side of the nasal septum and the mucous membrane detached from the cartilage. A small piece of mucous membrane at the top, and extending a little on to the outer wall of the nostril, is then cut away so as to leave a bare surface, to which the cartilaginous flap becomes adherent. The knife is then passed completely through the septum, and a small quadrilateral piece of the septum, with the mucous membrane on the opposite side left intact, is cut. This flap should be about one-half inch long and one-eighth inch broad. It is fixed to the roof and outer wall of the nostril with a single stitch. A similar piece is then turned up on the other side (Fig. 199)."

CHAPTER XVI.

CHRONIC GRANULOMATA OF THE NOSE, THROAT, AND EAR.

LUPUS OF THE NOSE.

Definition.—"Lupus vulgaris; a chronic disease of the skin and mucous membrane, characterized by the formation of nodules of granulation tissue. It passes through a number of phases, and terminates by ulceration or atrophy with scar formation. The cause of the disease is the tubercle bacillus." (Gould's *Student's Medical Dictionary.*)

Etiology.—Lupus of the nose and upper air passages is practically always associated with, or is secondary to, a lupoid condition of the skin of the face. Rare instances of primary lupus of the pharynx and larynx have been reported by Emil Mayer, Rubenstein, and others.

Females are more often affected than males, and it is more common in the country than in the city. It is more common in middle life, though it occurs at all ages. An abraded or diseased mucous membrane predisposes to its development. While lupus is due to the tubercle bacillus, there is a clinical distinction between it and tuberculous ulceration. Lupus is slow and insidious in its development, and is not necessarily associated with pulmonary tuberculosis. It has a tendency to heal, cicatrize, and recur, and does not often result in death from pulmonary involvement.

Symptoms.—Lupus of the nose generally begins on the anterior portion of the cartilaginous septum or upon the skin around the nasal orifice. It may spread from the septum to the inner wall of the ala. It appears as small nodules which coalesce and ulcerate, and it may disappear by absorption. The reparative process takes place but feebly at the margins of the ulcer, thus forming a pale-bluish, smooth cicatrix. The ulcers reappear and then disappear. This process may continue for years without spreading to other regions. The nodules are firm and well marked. The disease rarely attacks the cartilage and never the bones. One or both nostrils may be affected, and there may or may not be stenosis. The discharge varies with the stage of ulceration. At the onset it is thin and watery, and later becomes thick and even fetid, especially after crusts appear. Pain and tenderne s may be present, though I have seen cases in which they were absent. Itching is sometimes complained of.

Deformity may be present if the alæ are involved; when limited to the septum it is rarely present.

Treatment.—Spontaneous recovery may take place, though this is exceptional. It does not readily yield to treatment. Local escharotics,

curettage, the galvanocautery, serumtherapy, surgical removal, and radiotherapy have all been tried with more or less success.

The escharotics used have been lactic acid, carbolic acid, chromic acid, the Vienna paste, and other destructive chemical agents. Curettage has also been tried, usually with indifferent results. Curettage followed by the local application of an escharotic affords somewhat better results, though even this is far from satisfactory. The local cauterization with the galvanocautery is a procedure often resorted to, though usually with negative results. Serumtherapy has been attended by some success, but its limited use, thus far, does not afford a sufficient basis for a fair conclusion as to its efficacy. Surgical removal by excision of the diseased area is also as ineffectual as the measures just mentioned. It is possible that radiotherapy may prove to be of some value in these cases.

Radiotherapy.—Radiotherapy consists in the local application of heat and light rays endowed with a biochemical energy. Generally speaking, the blue-violet rays are the most potent, though the ultra-violet and *x*-rays are also effective. The energy may be applied by the *x*-ray tube, the Finsen apparatus, the leukodescent lamp, and radium.

I have only had personal experience with the leukodescent lamp shown in Fig. 19. The source of energy is an incandescent lamp of 500 candle-power with a specially designed reflector to concentrate the rays upon the diseased tissue. A treatment consists in concentrating the rays upon the diseased area for a period varying from fifteen to thirty minutes. The heat incidental to the applications renders it necessary to interrupt the applications every few seconds, during which intervals the skin should be gently stroked with the hand to diminish the sensitiveness present. If the treatments are to be extended over a period of twenty minutes, the lamp should be about eighteen inches distant from the face. If they are to be extended only over a period of five minutes, the lamp should be passed within three inches of the face for about two seconds at a time; that is, two seconds on and two seconds off. The face should be gently stroked with the hand during the intervals between the exposures and the application repeated. From five to eight such applications, followed by fifteen minutes' application at eighteen inches, constitutes a treatment.

The seances should be repeated daily or every second day until the disease disappears. From three to twenty treatments are usually given before success or failure is demonstrated. If no impression is made by this number of treatments they should be discontinued.

LUPUS OF THE PHARYNX AND LARYNX.

Posey and Wright quote H. Myngid's report of 20 patients with lupus of the skin in which the larynx was affected in 10 to 20 per cent. of the cases. Fifteen of the cases were females and 5 were males. Hunt in 411 cases of external lupus found either the pharynx, larynx, or the nose involved in 20 per cent. of the number. In 173 cases of lupus of the mucous membranes in Doutrelpont's clinic, only 6 cases were free

from cutaneous lesion. The nose was affected in 75 cases, the palate in 31 cases, and the larynx in 13 cases. The lesion often appears before puberty. (See Lupus of the Nose for a more general discussion of lupus.)

LUPUS OF THE AURICLE.

Lupus of the auricle manifests itself in all the forms found on other parts of the body, namely, hypertrophic, macular, papillary, and ulcerous, and is usually an extension from the face.

It begins with tubercles the size of a pinhead or larger, which are brownish in color, and slightly scaly on their surface. They are arranged in groups, and are surrounded by a slight efflorescence. The skin is contracted around the diseased areas. The scarred appearance is due to the deep penetration of the tubercles. Keloid formations are quite common.

The ulcerous type is rare and is characterized by ulcerations covered with thick crusts beneath which there is a spongy base. The edges of the ulcers are undermined and pale, with an occasional typical lupus nodule.

Treatment.—The treatment of lupus has been so uniformly successful under the Finsen phototherapy, the Röntgen-ray, and the leukodescent light that the older methods of treatment have become almost obsolete.

Hollander reports excellent results following the application of hot air to the diseased surfaces. The method is worthy of trial, especially if the Finsen, Röntgen-ray, and leukodescent light treatments are not available. The hot air may be applied with Beck's hot-air apparatus, hoping thereby to stimulate regeneration of the tissues and to relieve the subcutaneous edema which accompanies lupus.

If simpler methods of treatment fail the lupus areas may be excised and a subsequent plastic operation performed to overcome the deformity resulting from the primary operation. Another form of treatment, much in vogue in Europe, is to first curette the granulating areas and then apply a paste, the base of which is arsenic. This same mode of treatment has been much vaunted in this country by charlatans as a means of curing cancer. Most of the cancerous cases being, however, one or the other of the types of lupus heretofore mentioned. The actual cautery may be used instead of the curette and arsenic paste.

TUBERCULOSIS OF THE NOSE.

Tuberculous infection of the nose is characterized by either a low-grade, slightly depressed ulcer on the anterior portion of the septum or floor of the nose, or a sessile, wart-like tumor in which the tubercle bacillus is present.

Tuberculous lesions of the nose may be primary, or secondary to a

similar process in the lungs. It is generally secondary, though cases are not rare in which the process is limited to the nose. I reported a case which was under the care of the late Dr. Max Thorner, of Cincinnati, for about four years. It was subsequently under my care for about the same time, and is now under the care of a confrere, who informs me that the ulcerous condition has yielded to applications of the high-frequency currents of electricity. It should be noted, however, that the patient spent the winter in the South, and that while under my care the ulcer disappeared spontaneously each summer.

Fig. 200

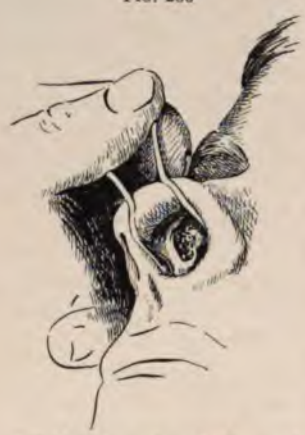

Tuberculous ulcer of the cartilaginous portion of the septum. The case was under the author's observation five years, and under Dr. Max Thomer's observation four years previously. It is now under the observation of Dr. J. C. Beck. The author injected a guinea-pig with tissue removed from the ulcer, under strict aseptic precautions, and found tuberculosis upon postmortem examination. The ulcer healed regularly every summer while under the author's care, and recurred regularly each November.

The case has thus been under nearly constant observation for about eighteen years. The patient is about forty-five years of age, and is in robust health, never having had any pulmonary symptoms. She says her brother has a similar condition in his nose. I inoculated a guinea pig with he tissue removed by curettage, and in six weeks the postmortem showed extensive tuberculous lesions in the neighboring glands and in the mesentry. The tubercular ulcer (Fig. 200) was superficial, irregular in outline, and had a somewhat nodular surface covered with crusts. It bled easily upon probing, was painless, and disappeared during the summer months, leaving a whitened, rather smooth cicatricial surface. It reappeared in the autumn of each year, only to disappear the following summer. This case seems to be primary in the nose, and shows little or no tendency to spread. There is no lupus lesion of the skin.

Varieties: (*a*) Superficial ulceration. (*b*) Wart-like or sessile tumors.

The superficial ulcers are the most common.

The wart-like growths are hyperplastic, and, like the ulcerous variety, bleed easily. The removal of either variety is followed by rather slow healing and by subsequent recurrence.

The complications are perforation of the septum and extension to the skin of the upper lip, and in extremely rare instances to the nasal accessory sinuses. Kyle suggests that the low resistance of the tissues affords a suitable soil for all forms of chronic granuloma microörganisms. The treatment consists in curettage and the application of Vienna paste. The ulcer or tumor should be anesthetized with a 5 to 10 per cent. solution of cocaine, after which the diseased area should be thoroughly curetted. A light application of Vienna paste may then be made to ensure the destruction of remaining fragments of tuberculous tissue. The radiant

energy of the leukodescent lamp, Finsen light, or some other source of radiant energy may be tried, although I am not informed as to their beneficial effects in this condition.

In spite of all forms of treatment there is a strong tendency for the tuberculous lesion to persist, and if it disappears, to return.

TUBERCULOSIS OF THE PHARYNX AND THE FAUCES.

Tuberculosis of the pharynx and fauces is rare and is probably always secondary to pulmonary or laryngeal tuberculosis. It is usually associated with, and is probably an extension from, tuberculous laryngitis. It has no point of attack, but may begin in the soft palate, uvula, tonsils, lingual tonsils, or the pharyngeal mucosa. Unlike nasal tuberculosis, it tends to spread rapidly to adjacent parts.

The part affected presents a wormeaten appearance, the ulcers being surrounded by an area of congestion. The ulcers are superficial and covered with a dirty grayish secretion. They bleed easily upon probe pressure. There is little or no induration except at the borders of old chronic ulcers. When the lingual or faucial tonsils are the seat of ulceration the depth of the ulcer is greater; even the whole tonsil may be destroyed. Cases are reported in which the faucial tonsils were the seat of primary infection and infiltration. It is, perhaps, impossible to estimate the proportion of cases that are primary in the tonsils, though it is perhaps larger than is generally supposed. In other portions of the pharynx and fauces it is rarely primary. The infection occurs either through the lymph channels or by the contact of the infected sputum with the mucous membrane.

Symptoms.—The symptoms vary with the anatomical location and extent of the lesion. If the soft palate is involved the proper approximation of the palatal muscles to the posterior wall of the pharynx is interfered with, and fluids and solid food may enter the nose upon deglutition. The same condition allows the secretions to accumulate and dry in this portion of the pharynx. This leads to hawking the nausea in the effort to dislodge it. An infiltration of the uvula may cause pain and a tickling cough. As the secretions are thick and the parts often exceedingly painful the secretions are often allowed to accumulate. The voice is muffled and hoarse, or aphonic.

Diagnosis.—Syphilis is about the only disease with which tuberculosis of the pharynx may be confounded. The following tables adapted from Lennox Browne will aid in the diagnosis.

Tuberculous Ulcers.	*Syphilitic Ulcers.*
1. Superficial motheaten surface.	1. Deep red and angry surface.
2. Mildly red areola.	2. Angry red areola.
3. Ragged, ill-defined edges.	3. Sharply cut edges.
4. Indistinct demarcations.	4. Distinct demarcations.
5. Grayish ropy secretion.	5. Purulent yellow secretion.
6. Scanty secretion.	6. Profuse secretion.

Prognosis.—The prognosis is grave. In those cases in which it is primary in the tonsils it is not so serious. When we remember that tuberculosis of the pharynx is nearly always secondary to pulmonary involvement the gravity of the disease is apparent. Kanasugi regards pharyngeal tuberculosis as being more grave than any other localized type, and the primary more than the secondary.

Treatment.—Curettage followed by the application of pure lactic acid is a common form of treatment. It is doubtful if climatic or outdoor treatment is as effective, as the pulmonary involvement is usually well advanced. Forced feeding on raw eggs and milk should be a part of the treatment of all tuberculous diseases when there is loss of weight and strength. The local application of a 2 to 10 per cent. solution of formaldehyde should be tried as in laryngeal tuberculosis. The pain should be controlled by the local application of cocaine, the administration of opiates, or the leukodescent light or other radiant energy. Painful deglutition is relieved by the application of cocaine immediately before meals.

TUBERCULOSIS OF THE LARYNX.

Synonyms.—Consumption of the larynx; consumption of the throat; laryngeal phthisis; tuberculous laryngitis.

Definition.—Tuberculosis of the larynx may be primary or secondary, and is characterized by an infiltration of the glands and connective tissue of the larynx. It gives rise to dysphagia, aphonia, and dyspnea.

Etiology.—The view that laryngeal tuberculosis is always secondary is held by almost all observers, and is proved by the findings of autopsies, there being very few recorded cases of death by laryngeal tuberculosis in which either a healed or active pulmonary involvement has not been found. The opponents of this view are very few in number, the most prominent of them being Dr. Gleitsmann, whose researches have been extensive, and who reports two cases of primary laryngeal and pharyngeal tuberculosis in his own practice which were cured. In the report of his cases he quotes Demme, E. Fraenkel, Prof. Rebinski, Orth, Coghill, J. S. Cohen, Dehio, and Lancereaux in support of his view.

Goodale has seen many cases of tuberculous laryngitis which he thought were primary, and which for a time seemed to yield to treatment; but the subsequent progress of the disease always proved fatal through the associated pulmonary tuberculosis. It is possible in a suspected instance of tuberculous laryngitis, where the pulmonary signs are negative, that a radiograph may disprove or substantiate the presence of pulmonary tuberculosis. Demme, in 1883, reported the case of a boy, aged four and one-half years, who died of tuberculous meningitis; the necropsy showed the presence of laryngeal ulceration with tubercle bacilli, the thorax and abdominal organs being at the same time free of tuberculous disease. He says many other cases in which such a condition was suspected have also been recorded; and it may now be considered as an accepted fact that tuberculous disease may not only attack the larynx primarily, but even cause death without the lungs being affected.

The disease is more common in men than in women, and occurs especially between the ages of twenty and forty years.

Knight also quotes Heinze's statistics, and adds that of the laryngeal lesions more than one-half were ulcerative, a proportion confirmed by the Brompton Consumption Hospital, nearly twice as large a percentage as that given by many other investigators. The mode of invasion of the larynx is either by direct infection through the inspired air or by the expectorated sputum, or indirectly by conveyance of bacilli from the tuberculous foci in the lungs through the blood current or lymph channels. The latter route is doubtless more frequent. If the contrary were true, tuberculous laryngitis would be much less rare than it is. The apparent immunity of the larynx against primary infection is difficult to explain. There is no essential difference between the mucous membrane of the larynx and the nose and other portions of the upper respiratory tract, excepting the pharynx. The mucosa of the nose is more exposed to the irritating influence of the atmosphere, and to trauma from picking crusts from the vestibule, and in this respect the abrasions offer a favorable site for the infection; the larynx is also subject to abrasions in the course of chronic laryngitis and in excessive use of the voice, and it yet remains to be proved that under these conditions it becomes the seat of primary tuberculosis. Shurley contends that the ventricles of the larynx afford a sheltered, quiet place for the development of the tubercle bacilli, and that in spite of this fact they do not readily develop here. The hidden recesses of the crypts of the tonsils also afford an ideal place for the growth of the bacilli, and, according to Mayo, 8 per cent. of all tonsils removed by him are tuberculous. Robertson's statistics support Mayo's. There is the necessary temperature, quiet, and protection from the currents of air to favor such a process. The tonsils are undoubtedly a common source of infection. Having gained entrance to the lymphatic circulation by this route, they travel downward to the lymphatic glands of the anterior triangle of the neck, thence to the lymphatic glands of bronchial tubes, and from there to the substance of the lung. I believe that the explanation of the apparent infrequent primary involvement of the larynx is to be found in inherent resistance of all mucous membranes to the invasion of the tuberculous germs, and that the exceptions to the rule are in the nasal mucous membrane of the anterior portion of the cartilaginous septum and the mucosa of the tonsil crypts, where the abrasions are so often present, and where the conditions are exceptionally favorable for the growth of the bacilli. The site for the tuberculous infection of the nose is at the point where it is or may be daily denuded of its epithelial covering, and where the deposit of tubercle bacilli is abundant. It would be strange, indeed, if tuberculous infection did not occur under these circumstances. The tonsillar crypts form ideal sites for the growth of the bacilli, being warm, practically without motion, and plugged with secretion, food, and desquamated epithelium. In these hidden recesses the bacilli flourish and remain constantly in contact with the mucous membrane. The crypts are also the site of frequent inflammations, during which the epithelium may be impaired,

thus affording a favorable condition for the invasion of the tubercle bacilli into deeper lymphatic tissue. Indeed, during inflammations the intercellular spaces become larger and permit the bacilli to pass through. It is more than probable that when the bacilli are indefinitely lodged on a mucous membrane they may penetrate through these spaces without an abrasion being present. The favorable conditions existing in the nose and tonsils are not present in the larynx, hence the tubercle bacilli rarely primarily infect the larynx. When, however, pulmonary tuberculosis is established, and the expectorated sputum constantly bathes the laryngeal mucous membrane, the conditions for infection are much more favorable. The constant presence of the bacilli, the mechanical irritation, the abrasions produced by coughing, and the lowered resistance of the cellular structures in general combine to favor such an infection. It is probable, therefore, that infection is usually secondary to the pulmonary involvement, and not primary.

Pathology.—The first apparent change in the larynx may be an ischemia of the mucous membrane. This is usually referred to as an "ashen-gray" color, which is said to be pathognomonic of tuberculosis. It is not always so, however, as it may occur in any general anemia. I have in several instances been enabled to make a diagnosis of tuberculosis by the "ashen-gray" color before the stethoscope showed positive evidences of the disease in the lungs. I referred these cases back to their physician with the suggestion that he apply the tuberculin test, and in each instance a typical reaction occurred. I contend, therefore, that while the "ashen-gray" color is not pathognomonic of tuberculosis, it is, nevertheless, a valuable early sign in many cases, especially when there is a pulse of 100 or more and a daily rise of temperature. It should be stated that the mucous membrane of the larynx is not always of an "ashen-gray" color in tuberculosis, but, on the contrary, it may be quite red, inflamed, and indurated. The vocal cords may be hyperemic and swollen until their indentity is lost in the reddened mucous membrane, or they may be lax, flabby, and nodular.

The histological changes occur chiefly in the aryteno-epiglottidean folds, the interarytenoid space, and the epiglottis. The cartilages may become involved, thus giving rise to perichondritis and chondritis. Cicatricial contraction takes place as the healing process progresses. This may give rise to more or less dyspnea.

When the arytenoid cartilage is affected the clubbed-shaped infiltration tumor is present (Fig. 201). When the infiltration extends to the aryteno-epiglottic ligament the picture is quite characteristic of tuberculosis of the larynx.

The epiglottis is often involved in the process, and when infiltrated presents the turban shape so often referred to. The infiltration may extend to both sides of the larynx or be limited to one. When both are affected the view of the deeper portions of the larynx is hidden. The tendency to ulceration is quite constant. It is rare for a well-advanced case of laryngeal tuberculosis to be free from it. The ulcers may be of any size within the limits of the area involved, and may be superficial

or extend to the cartilages. They may be discrete or confluent, single or multiple, and on one or both sides. When the cartilage is involved by ulceration there is a purulent discharge from the mixed infection present. Tuberculous ulcers develop more slowly than syphilitic ulcers and are less destructive, and are followed by less cicatricial contraction.

Symptoms.—The symptoms of an ordinary case of laryngeal tuberculosis are so characteristic there is little difficulty in making a correct diagnosis. As the laryngeal involvemen is usually secondary to a pulmonary involvement the preced ng history may afford an excellent index. There is more or less cough, often without expectoration, and there may be a sense of prickling or dryness in the throat. The voice may be hoarse or aphonic. When the infiltration is extensive the voice is often aphonic. The dyspnea is in proportion to the degree of infiltration and the cicatricial contraction present. Pain may or may not be present. In some cases it is quite severe, requiring the local applications of cocaine and orthoform, or injections of morphine to control it. In one of the author's cases, illustrated in Fig. 201, though the patient is aphonic, and has been for several years, there is no pain. Dyspnea is a constant factor though not alarming in severity. During the past six years the patient has gained twenty-six pounds in weight. Difficult or painful deglutition has been a more or less prominent symptom. The laryngoscopic examination shows the lesions described under pathology.

Fig. 201



Tuberculosis of the larynx. There is a bilateral pyriform infiltration of the arytenoids and of the right half of the epiglottis. The surface of both arytenoids is ulcerated, and the vocal cords are ragged. The patient is aphonic, is still living, and has increased several pounds in weight. (Author's case.)

Diagnosis.—Laryngeal tuberculosis must be differentiated from syphilis, carcinoma, and lupus.

Syphilis of the larynx presents a "punched-out" ulcer with a yellowish exudate. It spreads rapidly. The voice is low pitched and hoarse, or raucous, rarely aphonic. Pain is present upon phonation. The tuberculous ulcer is superficial and its base covered with a grayish exudate. It spreads rather slowly, is painful upon deglutition, and the voice is weak and softly hoarse or aphonic.

In carcinoma the base of the ulcer is raised by the crowding of the deeper infiltration; it is red and constantly painful, and the voice is continuously loose.

In lupus there is usually no pain, ulceration, edema, or discharge; dyspnea is slight or absent, the general health good, and a lupoid lesion is usually present upon the skin.

Prognosis.—The prognosis in laryngeal tuberculosis is grave, though not necessarily fatal. According to Harpy there were 14 spontaneous recoveries in 3000 cases. Under appropriate treatment the percentage of recoveries is increased. As a rule, however, the patient or his friends should only be encouraged to expect the patient to live for a comparatively short time—a few months or years. Death may occur from inanition, suffocation, or hemorrhage.

Treatment.—The treatment of laryngeal tuberculosis, excepting the local symptoms, is the same as in pulmonary tuberculosis. At present the "outdoor" treatment, especially in the earlier stages, is enthusiastically recommended. The tent colony at Ottawa, Illinois, under the supervision of Dr. J. W. Pettit, is doing good work. The buildings are so arranged that the patients practically live outdoors the year round. While this at first thought seems impossible during the winter months, it is, nevertheless, being done with comparative comfort. The house or tent protects from the severe cold and from the winds, while fires make life not only tolerable, but cheerful and comfortable. The object is to keep the patients in a pure circulating atmosphere, and sunshine as nearly all the time as possible. The whole system is thus invigorated and the lungs supplied with fresh oxygen. The vital forces are augmented and the reparative processes are often quickly and permanently restored. In mild cases, and in the incipient stage, little or no medicinal treatment is required, the "outdoor" treatment being quite sufficient. In well advanced cases where there is great infiltration and ulceration of the laryngeal tissues the "outdoor" treatment is as ineffectual as any other form of treatment. Innumerable remedies are recommended for the cure and relief of laryngeal tuberculosis, among them being the following:

For the relief of cough: codeine, $\frac{1}{8}$ to $\frac{1}{2}$ grain every three hours. Morphine sulphate, $\frac{1}{30}$ to $\frac{1}{16}$ grain every three hours.

For the relief of pain: Spraying the larynx with a 0.5 per cent. solution of cocaine. If there is painful deglutition, cocaine may be applied locally, just before eating, in a strength of 2 to 8 per cent. Insufflations of orthoform powder may be made to relieve the pain. It is non-poisonous, and its effects last longer than those of cocaine.

For curative effects, Gallagher, Levy, Lockard, and Johnson make local applications of formaldehyde to the larynx, with beneficial results. Gallagher was the first to prove its beneficial action in tuberculosis of the larynx. It should be used in increasing strength, beginning with a 0.5 per cent. solution and gradually increasing it to 10 per cent. The patient may be entrusted with a 1 to 500 solution for home treatment, greater strengths being applied by the attending physician.

Gallagher has had excellent results with the following method of treatment:

1. Anesthesia slight.
2. Cleanse, spray with 1 to 3 % formaldehyde solution.
3. Local application, 5 to 10 % formaldehyde.
4. ℞.—Orthoform . . . . . 7 parts } insufflation.
   Aristol . . . . . 1 part }
5. Deep intratracheal injection of
   ℞.—Menthol . . . . . gr. x–gr. l
   Ol. eucalyptus . . . . . ʒj–ʒij
   Ol. cinnamon . . . . . gtt. j–gtt. x
   Glycerol . . . . . q. s. ad ℥j

The above daily. Curettage is used when deemed necessary.

Menthol is another remedy of positive value. It may be used in combination with camphor and orthoform. Freudenthal uses it in emulsion in the following proportions:

℞.—Menthol . . . . . 1 to 15 parts.
Ol. amyg. dulc. . . . . 30 parts.
Vitelli ovarum . . . . . 25 parts.
Orthoform . . . . . 12½ parts.
Aquæ des. . . . . q. s. ad 100 parts.
Ft. emulsio.

The above is injected intratracheally and often yields excellent results.

Lactic acid has had and still has its advocates. Begin with a 10 per cent. solution and increase to 75 per cent., or even full strength. It should only be used when there are ulcerations or after curettement. It should be rubbed into the ulcerated or raw surface with a cotton-wound applicator at intervals of five to ten days. The pain is severe and continuous for four or five hours.

Radiotherapy.—According to Gleitsmann the Finsen light and the ultraviolet rays are less penetrating than the Röntgen rays, and yet the great expectations from the latter in laryngeal diseases have not been fulfilled. The bacilli are at first increased, and only after a prolonged use of a low vacuum tube is improvement noticeable. The Cooper Hewitt light, or mercurial waves, the search light, the actinolight, and the leukodescent lamp may be used to relieve the pain, and in some instances actual improvement follows. It is too early to predict marked curative power from these sources. I have used the leukodescent lamp, but my experience in laryngeal tuberculosis is too limited to state that it does more than relieve the pain. The chief value of the leukodescent lamp is in the blue-violet rays and the radiant heat. These in combination exert a favorable influence in acute catarrhal and suppurative inflammations, hence are of service in combating the mixed infection usually present in tuberculosis. The use of radium as reported by J. C. Beck relieves the pain just as other forms of radiant rays do. The direct rays of the sun act in much the same way.

Curettage should be limited to the ulcerated areas, carefully avoiding the parts which are simply infiltrated and have an unbroken surface. It has been conclusively shown that the infiltrated areas may remain quiescent indefinitely. Having curetted the tuberculous ulcer, stimulating the sluggish process, and removing the overlying necrotic tissue, the local treatment given in the preceding paragraphs should be continued.

TUBERCULOUS LARYNGITIS IN PREGNANT WOMEN.

Lohnberg observed 5 cases in two years. In 2 there was no evidence of tuberculosis elsewhere, and in the others the laryngitis overshadowed the other lesions. The latter was true in the cases reported by Türck. Lohnberg has collected 21 similar cases from the literature. The evidence is in favor of the assumption that pregnancy affords a predisposition to this affection and whips the latent process to a gallop. Furthermore, he says that every pregnant woman with diffused laryngeal tuberculosis is immediately doomed, and possibly also those with only a single tubercle. The only treatment is the palliative use of menthol-orthoform emulsion, formaldehyde, etc., but these lose their efficacy after a time, and relief is only obtained from morphine and tablets of cocaine.

Pregnant women should be carefully examined at the slightest suspicion of trouble in the throat, and should be placed upon the treatment outlined above, and especially the outdoor treatment. Every woman should be warned that the tuberculous process may be aggravated by pregnancy. It therefore follows that an unmarried woman suffering from tuberculosis should not marry until a cure has been effected.

TUBERCULOSIS OF THE MIDDLE EAR AND MASTOID PROCESS.

Tuberculosis of the middle ear may be primary or secondary. A. W. Milligan believes the primary form, especially in young children, is more common than is generally supposed. Secondary tuberculosis of the middle ear is usually a complication of a tuberculous process in some other part of the upper respiratory tract, rather than a complication of a similar disease of the bones, glands, or abdominal viscera. In a series of cases reported some years ago Milligan found 16 per cent. of all adenoid cases to be tuberculous. This is a possible explanation of the frequent involvement of the middle ear.

Symptoms.—The symptoms of tuberculosis of the middle ear vary with the acuity, intensity, or the chronicity of the process; also with a simple or a mixed infection.

The acute variety is characterized by some redness of the drum membrane, slight pain, and multiple perforations. The hearing is considerably impaired. The facial nerve may be paralyzed. If the infection becomes mixed, the nature of the disease is obscured by the greater intensity and destructive character of the inflammatory process.

Diagnosis.—The chronic variety and more usual form is readily diagnosticated, as it runs a slower course and is characterized by less impairment of hearing (though this is variable), tinnitus, a sense of fulness in the affected ear or ears, and an almost or quite complete absence of pain. In the early stage there are multiple perforations, each perforation being the site of a tubercle which has broken down.

Later these coalesce and form larger perforations, often resulting in a most complete destruction of the membrana tympani.

To confirm the diagnosis, the secretions and the granulation tissue should be examined for the tubercle bacilli and giant cells. Should they not be found, a guinea-pig should be inoculated with some of the tissue and at the end of five to eight weeks examined for the results of the test In one of my cases the microscopic findings were negative, but the inoculation experiment was decidedly positive. Climatic treatment in Colorado and permanent residence there resulted in an apparent cure.

Milligan draws the following conclusions:

(*a*) A final and exact diagnosis is imperative both from the point of view of prognosis and of treatment.

(*b*) The disease is most frequently found as secondary to a tuberculous process in other regions of the body.

(*c*) Primary tuberculous disease of the middle ear is probably of more frequent occurrence than is usually supposed.

(*d*) The prognosis is always grave, but in a certain proportion of cases suitably planned surgical intervention will eradicate the disease.

(*e*) In many cases it is advisable to conduct the treatment in stages.

(*f*) When less than 10 per cent. of the hearing power remains no attempt should be made to preserve the ear as an organ of sense.

(*g*) When more than 10 per cent. of the hearing power remains in a patient otherwise in apparent health a definite attempt should be made to preserve the remaining hearing power.

(*h*) When the tuberculous origin of the ear disease has been scientifically demonstrated the case should be regarded as infectious and precautions taken accordingly.

Robert Levy has had exceptional opportunities to study middle-ear diseases in tuberculous patients as seen in Colorado. He summarizes as follows:

Any of the usual affections may affect the tuberculous as well as the non-tuberculous.

The usual modifications of an acute otitis in a tuberculous subject is manifested in the course the disease pursues.

It is doubtful whether the Bacillus tuberculosis is present as a distinctly etiological factor or as an accident.

Clinical tuberculous otitis occurs with moderate frequency in Colorado, being secondary to lesions of the respiratory organs.

Tuberculous otitis may develop when the general symptoms of tuberculosis have been arrested and the patient's condition is unusually good.

Tubercle bacilli may find their way into the middle ear through the Eustachian tube, through the lymph channels, or the blood currents.

Unusual care must be exercised in the application of the nasal douche in tuberculous patients.

The discharge may be arrested, but not permanently, as a rule.

It must be exceedingly rare for miliary tuberculosis to develop from an otitis as the focus of infection.

Treatment.—General and climatic treatment must be conscientiously carried out.

Goldstein reports four cases which he considers were primary tuberculous infections. All of these cases, he says, were seen more than three years previous to his report; three are still living, and careful physical examination fails to show any tuberculous infection. There were no evidences in the histories of these cases or in their clinical development either of an acquired or hereditary tuberculosis. Of the 4 cases, 3 involved the mastoid cells extensively and showed an unusually active and rapid invasion. All of the cases developed from a preëxisting otitis media suppurativa chronica, and appeared to him as direct infection by the Bacillus tuberculosis. In the 3 cases where the mastoid operation was performed the wounds healed by firm granulations, and all evidence of tuberculous trouble ceased with the removal of the local process. This is in direct contrast to the healing of wounds in patients in whom the systemic tuberculous invasion is present. The data which has been furnished in the cases herein reported point to a definitely localized specific infection of the cavum tympani and mastoid cells, with the characteristic development of a tuberculous process as it occurs in bone tissue, and with the definite demonstration of the Bacillus tuberculosis in one case.

Prognosis.—Generally speaking the prognosis is unfavorable. There are, however, numerous exceptions to the rule.

Unfavorable.—(*a*) It is especially unfavorable in those cases running an acute course.

(*b*) Rapid destruction of bony tissue of the labyrinth and mastoid process is another unfavorable sign.

(*c*) Mixed infection adds to the destructive nature of the process.

(*d*) Well-advanced pulmonary tuberculosis renders the prognosis unfavorable.

(*e*) Marked general debility from any cause is an unfavorable sign.

More Favorable.—(*a*) In children the disease is often local or secondary to diseased cervical glands. The removal of the cervical glands and of the diseased centre in the mastoid process is usually followed by complete recovery.

(*b*) In adults otherwise healthy the prognosis under simple treatment is good.

Treatment.—The treatment should be selected with reference to the type of manifestation the age and general health of the patient.

(*a*) Primary tuberculosis of the mastoid process yields good results under the mastoid operation, especially in children. It children it may be necessary to remove the cervical glands, as a failure to do so subjects the patient to the liability of a return of the process.

(*b*) When the *pulmonary tuberculosis is not advanced* the mastoid operation is indicated, and may be followed by very satisfactory results. These cases also do well in a suitably selected climate or in tent colonies, with adequate nourishment and local treatment. The tuberculin

treatment is of value if Koch's new tuberculin is given under opsonic control.

(*c*) When the *pulmonary tuberculosis is well advanced*, operative treatment is useless. Even in more favorable cases the operation may be only followed by a temporary improvement. If the patient is greatly debilitated from any cause, operative treatment is contra-indicated. In such cases the necrotic process usually continues, the bony walls remaining denuded and covered with pus.

(*d*) When there is *mastoid swelling or redness* an early operation for the relief of the abscess is indicated, regardless of the general character of the disease.

(*e*) *Climatic or open-air treatment* and reconstructive remedies should be used in those cases in which there is little or no lung involvement, outdoor air and sunshine being especially recommended.

O. J. Stein recommends the use of formaldehyde, a few minims of which are dropped on a gauze dressing placed in the meatus and auricle. This should be covered with a thin layer of cotton and sealed with collodion to prevent external evaporation. The fumes of the formaldehyde penetrate to the diseased area and exert a favorable influence upon it. (See Treatment of Laryngeal Tuberculosis).

SYPHILIS OF THE NOSE, PHARYNX, FAUCES AND TONSILS.

The fauces and pharynx are second only to the skin as sites for the manifestation of constitutional syphilis, particularly in the secondary stage. This may be accounted for in part by the presence of a large number of lymphoid glands, the excessive friction, and the complex embryological union of tissues in this region.

Congenital syphilis is more common in the pharynx than it is in the nose. The cases shown in Figs. 202 and 203 involved the pharynx and nose. John Mackenzie says 50 per cent. of the congenital cases occur in the first year of life, while 33⅓ per cent. were within the first six months.

Primary lesion of the pharynx and tonsils is second in frequency to the genitalia, owing to the numerous syphilitic nurses, sexual perverts, and the use of unsterilized surgical instruments in office practice. In one of my cases the primary lesion occurred on the left tonsil, which was incised for quinsy by a practitioner who was affected by syphilis.

When I first saw him there was an ugly superficial ulcer with indurated edges on the upper portion of the tonsil. Within a few days the typical secondary rash appeared, thus confirming the diagnosis.

Females are more often affected than males, and one or both tonsils may be the seat of the primary lesion.

The primary lesion is usually of short duration, though when on the tonsils the inflammation may be so great as to extend the period of ulceration to the second stage. This has been true in some of my cases.

The secondary lesion consists of the usual erythema of the face and body and mucous membranes. They may appear from six to eight

weeks after the initial lesion or even as late as several months. The erythematous patches in the throat have been described as ulcerations, though Lennox Browne claims they are not true ulcers, but simple abrasions of the surface epithelium.

The tertiary lesions appear from three to twenty-five years after the primary manifestation, and may be ulcerative, gangrenous, and gummatous and very destructive to both soft and bony tissues.

Symptoms.—The symptoms of the primary stage are ulceration with indurated edges, attended by pain in the ear if the arch of the fauces is affected. If the inflammation extends to the pharyngeal orifice of the Eustachian tube there is some deafness and tinnitus. The lymphatic glands of the neck are usually enlarged.

Fig. 202

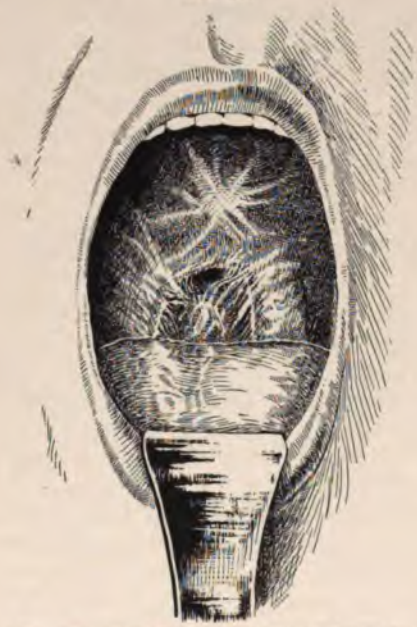

Fig. 203

Fig. 202.—Syphilitic stenosis of the fauces and pharynx. (Author's case.)

Fig. 203.—Author's case of syphilitic ozena and ulceration of the margins of the right wing of the nose and of the upper lip in a child four years of age. Inherited syphilis.

In the secondary stage there may be cough or a tickling sensation in the throat. In some cases pain or a dull aching is complained of. Dysphagia and a pseudomembranous angina, accompanied by a slight elevation of temperature, may be present. Erythematous patches on the skin and in the throat may be present, those in the throat often being mistaken for superficial ulcerations. Upon close examination they are found to be mere abrasions or elevations of the superficial epithelium.

In the tertiary stage the odor is characteristic, and is known as syphilitic ozena. There is some pain, but it is not as severe as the lesion seems to warrant. The pain is increased upon deglutition.

SYPHILIS OF THE LARYNX.

The primary, secondary, and tertiary manifestations of syphilis may appear in the larynx, though the primary lesion is extremely rare. Syphilis of the larynx is estimated as comprising all the way from 1 to 15 per cent. of all cases of syphilis. Its occurrence in the pharynx is given as about 10 per cent., and in the nose as nearly 3 per cent. of all cases. About one-fifth of all the cases of syphilis appear, therefore, to affect some portion of the upper respiratory tract.

It occurs most frequently between the twentieth and fiftieth years of life. In the congenital form it appears either in the first few months of life or at about the age of puberty. When it occurs soon after birth the lesions are usually secondary. If the second stage is completed in utero the disease may only become manifest in the third stage after the lapse of several years, usually from two to fifteen years.

Secondary erythema of the larynx usually occurs as an accompaniment of the same process in the pharynx. Practically the only phase of the congenital type of the disease that concerns us is the tertiary type. The secondary stage, if present, usually excites but little attention. Whether hereditary or acquired it is in the tertiary stage that relief usually is sought. Males are more often affected than females. It may occur at any age, though it is more common between the twentieth and fiftieth years of life.

Gross Pathology.—The lesion is usually bilateral and appears upon the true and false cords as a catarrhal inflammation with hyperemic spots and abraded epithelial areas. Condylomata may occur on the epiglottis or upon the laryngeal mucous membrane, and cause considerable stenosis.

Symptoms.—Though the ulceration takes place very rapidly the pain is usually slight. It first appears in the form of a clear-cut, deep ulcer. Induration is not always present, though there may be slight thickening at the edges of the ulcer. Edema is not a marked feature. At the bottom of the ulcer the cartilage may be necrosed and the seat of suppuration; that is, perichondritis and chondritis of the laryngeal cartilages may be present. The mucous membrane is hyperemic and darkly congested. The condition improves under the iodides, though it may be temporary. Hemorrhages sometimes occur, and in rare instances endanger life.

The vocal changes are unilateral paralysis (though it may be bilateral), with a raucous hoarseness or aphonia. Cough is in some subjects an early symptom. Dysphagia may or may not be present. If the syphilitic lesion is located on the posterior aspect of the larynx, dysphagia is usually a marked symptom.

Prognosis.—Syphilis of the larynx usually yields to treatment, though it may leave the vocal apparatus somewhat impaired as to its anatomical and physiological integrity. Life is not usually in any great danger, except in those cases in which the hemorrhage is unusually severe, or in

those cases in which the stenosis causes suffocation. When on account of the suffocation it becomes necessary to perform tracheotomy the patient should be warned that in all probability he will have to wear a tracheal tube the balance of his life.

Treatment.—The general treatment should be as for syphilis elsewhere in the body. Local treatment to relieve the cough or pain may become necessary. In case perichondritis and necrosis of the laryngeal cartilages is present it is best to first push the iodides vigorously to diminish the acute pathological process, and then, if necessary, to remove the fragments of diseased cartilage. This may be done by direct laryngoscopy, or by laryngofissure (see Laryngoscopy and Laryngofissure), preferably by the former, as it may become necessary to repeat the operation a number of times.

In case of extreme stenosis, tracheotomy should be performed and a tracheal cannula introduced.

SYPHILIS OF THE EXTERNAL EAR.

Primary chancre of the external ear is so rare that less than half a dozen cases have been reported in the literature.

The secondary manifestations may be papular, pustular, macular, ulcerous, or condylomatous. The entire auricle may be destroyed by extensive ulcerations, or it may be greatly deformed. The ear manifestations are usually secondary to a similar affection of the adjacent skin.

Condyloma of the meatus is rare, occurring in the proportion of about 1 to every 240 cases of general syphilis (Deprès and Buck).

The course of condyloma in the external meatus is as follows:

(*a*) In the beginning there is a red efflorescence of the skin, other symptoms being absent.

(*b*) At a little later period diffuse swelling of the walls of the meatus occurs.

(*c*) The skin begins to be slightly broken and secretion is thrown upon the surface.

(*d*) Finally, warty growths, of a grayish-red color, form in the cartilaginous portion of the auditory meatus, and, more rarely, in the osseous portion. They may be so large as to entirely block the meatus.

(*e*) Pain usually develops with the appearance of the condyloma, especially if the skin is ulcerated. The pain is intensified by movements of the lower jaw, as the glenoid fossa is in very close relation to the antero-inferior wall of the meatus. Deafness and tinnitus develop in proportion to the degree of the meatal obstruction. Fever is exceptional.

(*f*) Resolution may take place either with extensive destruction of the tissue or with little or no changes whatsoever. In some cases exuberant ulceration continues for many months. Under general treatment resolution takes place quickly, and little or no scar tissue forms. Stricture of the meatus is rare.

Diagnosis.—The diagnosis should be based upon the history of specific disease elsewhere in the body, the characteristic glandular swelling, and the appearance of the lesion of the ear.

Prognosis.—The prognosis of condyloma and the other secondary forms of syphilitic manifestation is favorable under the internal administration of mercury and iodides.

Gummatous formations of the external ear are usually simultaneous in their appearance with the same process in the middle ear. They may appear later as deep ulcers with elevated margins.

Treatment.—The local treatment of the primary chancre should consist in cleansing the parts with black wash and then applying the following ointment:

℞—Unguent. hydrargyri,
Lanolin . . . . . āā ℥iv—M.
Sig.—To be applied with cotton pads held in place with a light bandage.

Mercury should be given internally at the same time or it may be rubbed into the skin in the form of blue ointment.

Condylomata and other secondary syphilitic manifestations should be treated by the internal administration of mercury and the local application of a powder composed of equal parts of calomel and the oxide of zinc, which should be applied once or twice daily.

To reduce the exuberant granulations, use a strong solution of the nitrate of silver.

Gumma should be treated by the internal administration of mercury and the iodide of potash or iodonucleoid to the point of toleration.

LEPROSY.

Synonyms.—Elephantiasis græcorum; leontiasis; satyriasis; French, la petæ; German, der Aussatz; Norwegian, spedalskhed.

Leprosy is a chronic infectious disease caused by the bacillus lepræ, and is characterized by the presence of tuberculous nodules in the skin and mucous membranes (tuberculous leprosy), or by changes in the nerves (anesthetic leprosy). At first these forms may be separate, but ultimately they exist in combination. In the characteristic tuberculous form there are disturbances of sensation.

It is customary to divide leprosy into two general forms, the tuberculous and the anesthetic, lepra tuberosa or tuberculous leprosy, and lepra anesthetica seu nervosa. It is also sometimes subdivided into:

(*a*) Tuberculous nodular.
(*b*) Non-tuberculous.
(*c*) Mixed tuberculous.

Etiology.—Geography.—In Europe it is most common in Norway, the Swedish, Finnish, and Russian Coasts, the East sea; then in Asia, India, China, Africa, Eygpt, Abyssinia, Morocco; and in America (California and Mexico). It is also found in Australia and the Sandwich Islands.

The Bacillus lepræ was discovered by Hansen, of Bergen, in 1871, and is universally recognized as the cause of the disease.

Modes of Infection.—There are three possible modes of infection, viz.:

(*a*) *Inoculation.*—It has not been proved that leprosy is contracted by accidental inoculation, though it is highly probable.

(*b*) *Heredity.*—For years it was thought to be transmitted, though it is probably not.

(*c*) *By Contagion.*—The disease is contagious. The bacilli are given off from the nasal secretions, open sores, and the excretions of the body. Osler says it is probable that the bacilli may enter the body in many ways through the mucous membranes and through the skin. Sticker believes that the initial lesion is in the ulcer upon the cartilaginous part of the nasal septum. If this is true the disease assumes greater importance to the rhinologist and suggests the advisability of maintaining thorough cleanliness of the nose on the part of those associated with leprous patients.

Pathology.—The Bacillus lepræ has many points of resemblance to the tubercle bacillus, but can be readily differentiated from it. It is cultivated with extreme difficulty, and, in fact, there is some doubt as to whether it is capable of growth on artificial media (Osler). Lepra tuberosa, or tuberculous leprosy, attacks chiefly the integument and the mucous membrane of the nose, palate, roof of the mouth, larynx, and pharynx. On the skin the first changes show themselves in the form of infiltration; the skin in one or more places over areas of several centimeters becomes elevated and assumes a brownish-red or dull red color. In the region of the infiltration the sensibility disappears, partly or completely, and on hairy parts the hair of the affected area falls out. On mucous membranes the lesions show themselves either as small patches or tubercles, or as round flat infiltrations, which become ulcerated and heal with cicatricial contraction. The results are often conspicuous disturbances of the affected part, disappearances of the cartilaginous nasal septum, the soft palate, and the epiglottis. Stenosis of the larynx is one of the most common occurrences. Characteristic tubercles also often develop on the conjunctiva bulbi, especially at the corneal borders. The disease has a remarkably regular and progressive course, inasmuch as new lesions are always presenting themselves. The outbreaks arise with the initial eruptions. Under febrile action the erythematous reddening of the affected parts develops, and is soon followed by the formation of tubercles and nodules. At the site of the older lesions, usually at the time of the fresh outbreaks, changes take place, miliary abscesses or blebs arising, either of which may end in ulceration. It is deserving of mention, that at the time of these fresh outbreaks the lepra bacillus may be demonstrated in the blood, in which, at other times, it is wanting.

Lepra Anesthetica seu Nervosa.—Anesthetic leprosy is characterized by sensibility and trophic disturbances of the skin and muscles. The new tissue formation, which produces the nodular growths of the tuberculous form, remain in the background or are entirely wanting. The

disease begins as a leprous polyneuritis. Anesthetic leprosy, in typical cases, has no resemblance to tuberculous leprosy. It usually begins with pains in the limbs, and areas of hyperesthesia, or of numbness. Very early bullæ may form, maculæ appear on the trunk and extremities, and, after resisting for a variable time, disappear, leaving areas of anesthesia, though anesthesia may come on independent of the maculæ. Superficial nerve trunks may be large and nodular. The bullæ, change to destructive ulcers. The fingers and toes are liable to contracture and necrosis. It runs a very chronic course and may not be severe in its results (Osler).

Mixed tuberculated lepra is the least common form, constituting about one-sixth of all cases; about one-half are apparently hereditary and often each parent has had a different form. It begins sometimes with tuberculated and sometimes with non-tuberculous symptoms, but most frequently the latter take the lead for a few months, and then fever and the usual phenomena of tuberculation occur. Destruction of the cartilage of the nose sometimes ensues; the soft palate also may be destroyed by ulcerations. The balance of the symptoms are a compound of the other varieties.

Prognosis.—The disease is very chronic, progressive, and probably incurable. The tuberculous form is destructive. The nervous form may not greatly impair the patient's usefulness, as in the case of the clergyman who continued his career for thirty years after contracting the disease.

There are no specific remedies for the disease. General tonics combined with local treatment to meet the indications is all that can be done.

GLANDERS.

Synonyms.—Equinia maliasmus; malleus; malleus humidus; farcy; morve; farcin; rotz.

"A contagious disease of horses and asses, but communicable to man, and due to the bacillus of glanders, or Bacillus mallei. It appears in two forms, as glanders proper, when affecting the mucous membrane, and as farcy when limited to the skin and lymphatic glands." (Gould's *Dictionary.*)

Etiology.—Originating in horses and asses, it is communicable to man, and from man to man. It is naturally more often found in men engaged in occupations throwing them in contact with beasts of burden. While the bacillus may gain entrance through the follicles of the skin, it more often does so through an abraded or a wounded surface. Cases are reported where surgeons were infected while operating upon patients affected with the disease.

Pathology.—There are numerous closely associated nodules of low grade embryonal or granulation tissue, which readily breaks down and suppurates. The ulcers thus formed have undermined edges, the

remnants of the preceding abscess wall. The process spreads by continuation, though later the process may be carried to distant parts. It usually appears first in the skin, and then extends to the mucous membrane of the nose, though it may have its origin in the mucosa. Baumgarten says it is a disease standing midway between abscess and tuberculosis.

The nasal lesions are usually in the form of numerous closely grouped granulation nodules in the submucous tissue. There is a profuse proliferation of leukocytes and connective-tissue cells, with which are admixed numerous bacilli of glanders. The proliferation continues until the pressure diminishes the nutrition of the mass, especially at its centre. Liquefaction necrosis ensues, and the nodules become abscesses. The outer wall soon breaks down and the contents are discharged into the nasal cavities. The abscesses are thus converted into open ulcers with undetermined edges. Cross-sections of the masses before breaking down show them to be composed almost entirely of leukocytes, connective-tissue cells, and some fibrous tissue. Many Bacilli mallei are embedded in the masses of proliferated cells. In the acute form there are numerous multinuclear leukocytes in the adjoining tissue. In the chronic form the bone and deeper structures may be destroyed. Gangrene of the softer tissues may occur.

Symptoms.—In the acute form the period of incubation is from three to four days. The acute symptoms often simulate rheumatism or typhoid fever in its initial stage. A little later the nodules appear either upon the skin or the nasal mucosa, according to the point of infection. They rapidly increase in size, as described under pathology, until (in nasal glanders) the purulent contents empty into the nose. The upper air passages are not often involved primarily in man. The progress of the disease is rapid, and usually leads to a fatal issue in a few days, or in two or three weeks.

The chronic form is fatal in about 50 per cent. of the cases after two months or two years. The chronic form bears a close resemblance to syphilis and tuberculosis. The lymph glands of the neck are often much enlarged in the acute form. Chronic glanders often presents the symptoms of a persistent coryza. The diagnosis is difficult. It may be necessary to inoculate a male guinea-pig with the nasal secretions to clear the diagnosis. At the end of two days, in a positive case, the testicles of the pig are swollen and the skin of the scrotum reddened. The testicles continue to increase in size and finally suppurate. After two or three weeks death occurs, and the postmortem shows glanders nodules in the viscera. The use of "mallein" is highly recommended for diagnostic purposes. It is used in the same manner as the tuberculin test in tuberculosis. In all suspected cases remove a piece of the tissue and examine sections with the microscope; make agar cultures and inject into the peritoneal cavity of a guinea-pig, and watch the reactions. Also use injections of mallein, and watch the results. Above all, study the clinical phenomena, and from all the evidence obtainable arrive at a diagnosis.

Prognosis.—The prognosis in the acute form is grave, nearly all cases dying in a few days. In the chronic form the mortality is about 50 per cent., death occurring in from two months to one or more years.

Treatment.—In acute cases there is little hope. If seen early the tissue around the point of original infection should be either extensively cauterized or removed *en masse*. The wound thus created should be frequently bathed in a solution of the chloride of zinc (one to eight). All animals and horses suspected of being infected should be killed and their bodies burned. In chronic cases, tonics and the iodide of potash should be given, though no specific remedies are known.

Glanders of the pharynx is usually an extension of the same process from the nose, though it may be primary in the pharynx. The nodules form here, as in the nose, and are attended by about the same general symptoms. The cervical and sublingual glands are early involved, and break down and suppurate, discharging externally.

The chronic form is not attended by the same distinct phenomena, and is often mistaken for granular pharyngitis. The nodules are mistaken for the lymphoid masses observed in chronic follicular pharyngitis, though, if watched long enough, they will be seen to gradually grow larger and larger, until serious mechanical obstruction occurs. Such a process in the pharynx should arouse a suspicion of glanders, and lead to the mallein test, or guinea-pig experiment as given under Symptoms.

Glanders of the larynx is rare, and when present is associated with the same process higher up in the respiratory tract.

ACTINOMYCOSIS OF THE NOSE.

Synonyms.—Lumpy jaw; holdfast or wooden tongue.

Definition.—Actinomycosis is a parasitic, infectious, and incurable disease, first observed in cattle and later in man. It is characterized by the manifestations of chronic inflammation, with or without suppuration. It often results in the formation of granulation tumors, especially about the jaw and neck. The disease is due to the presence of the ray fungus or actinomyces.

Etiology.—The exciting cause is the ray fungus or actinomyces. The predisposing causes are an abraded mucous surface, or a diseased membrane. The infectious material may be carried by water or food, and by straws, chaff, grain, needles, etc. The fungus probably grows upon wheat and oats, hence, farmers should be cautioned against chewing wheat and oat straws, as they seem to be a prolific source of infection. Shoemakers occasionally contract the disease from the habit of holding a needle or awl in the mouth. Kissing may be the means of transmission from one person to another. It occurs chiefly in young adults.

Pathology.—The actinomyces were formerly thought to be mold fungi, but Bostroem, in 1885, proved by cultivation that they are a variety of cladothrix, belonging to the schizomycetes. The diseased mass is

made up of granulation tissue, which, except for the ray fungus, would be mistaken for a round-cell sarcoma. Epithelioid elements and giant cells are also sometimes present. In the granular mass, or in the pus, the fungus itself appears under the form of small, yellow, brown, or even green masses, about the size of a pinhead, which, upon microscopic examination, are found to be composed of a central interwoven mass of threads, from which radiate club-shaped ended rays. In man the clubbed bodies are frequently absent (Senn.) The histological lesions are alike in the actinomycotic nodule, and in the tuberculous follicle, only the germ body differs. Water, or a weak solution of sodium chloride, causes the rays to swell enormously and lose their shape; ether and chloroform have no action upon them. The gross pathological anatomy of the disease is everywhere associated with chronic indurations, with softening and liquefaction, and with resulting sinuses and cysts. The head, neck, and especially the jaw, and the cervical fascia are the sites of the disease. In the cervical fascia, the disease gives the neck a brawny hardness. The lymphatic glands are not, as a rule, extensively affected. In the ox the tongue is often affected.

The lesion may be self-limited, as in tuberculosis, by cicatricial envelopment.

The kernel-like nodules are usually multiple. They may coalesce, and the resulting masses may "heal out." When bone tissue is affected, there is central destruction, while peripherally there is hyperplasia.

ACTINOMYCOSIS OF THE PHARYNX AND TONSILS.

Pathology.—Implantation of the ray fungus leads to the development of granulation tumors, similar to localized tuberculous inflammation. Nodules of small round cells, containing giant and epithelioid cells, are sometimes found. Differential stains help to show them. Following this there is considerable reaction and proliferation of the tissue elements, somewhat resembling sarcoma. The proliferation is followed by a chronic and intractable suppuration and sinus formation. It is questioned as to whether ray fungus is pyogenic, or whether the pus present is due to mixed infection. Infection may be transferred by both the lymphatics and bloodvessels, probably more frequently by the latter.

Symptoms.—The symptoms vary according to the part affected. The affection is chronic, but occasionally runs a rapid course. The granulation tissue is abundant and the mass resembles a tumor. Previous to suppuration it is quite firm, and if progressing rapidly it is surrounded by diffuse edema. Pain and tenderness are rarely present. When suppuration occurs the mass increases rapidly in size.

The frequency of occurrence in different parts of the body in 500 cases, as collected by Poucet and Berard, is as follows: Head and lungs, 55 per cent.; thorax and lungs, 20 per cent.; abdomen, 20 per cent.; other parts, 5 per cent. In France the face and neck were affected in 85 per cent. of the 66 cases reported.

The symptoms may be grouped in two classes: (*a*) Those referable to local tumefaction and purulent discharge, and (*b*) those referable to the general intoxication of the system by the suppurative products, or their metastatic spread, and which do not differ from those of chronic suppuration. The local symptoms are of slow development, and are largely those of gradual mechanical interference of the pharyngeal function. At the site, or sites, of inoculation a small rounded and reddish elevation appears, attended by the usual subjective annoyances of an attending pharyngitis. The adjacent tissues become swollen and tumefied, and the evidences of an acute inflammation soon change to the more permanent engorgement and solidity of a chronic condition. The swelling is irregular, but well outlined, firm to probe palpation, and not oversensitive, and slowly increases in size. Suppuration and the formation of angry-looking sinuses follow, from which issues a purulent discharge, in which are the small yellowish pellets, or masses, composed largely of the typical ray fungus. The discharge is persistent, and the sinuses extend deeply and produce extensive tissue destruction. The spread of the process does not, as a rule, occur, and it shows a tendency, if it occurs elsewhere, to do so as an isolated swelling rather than as a connected overgrowth from the original pharyngeal focus. Pain is a variable quantity, and depends largely upon the seat and extent of the peculiar swelling. Usually there is more or less continuous, heavy aching felt locally, and this may, at times, be eased or intensified into acute distress. Fetor of the breath and gastric disturbances from the purulent discharge are often present. The appearance of the disease elsewhere by metastasis is to be expected, especially in the lungs or the alimentary tract, though no portion of the body is free from possible invasion. The systemic symptoms may be severe or slight, according to the degree of involvement and the exit of the suppurative products, and do not differ in their character from those usually observed in any other suppurative condition. Death occurs from slow exhaustion, or through some intercurrent affection or complication (Kyle).

Diagnosis.—Actinomycosis should be differentiated from:

(*a*) Sarcoma.
(*b*) Tuberculous infection.
(*c*) Carcinoma (of the tongue).
(*d*) Syphilis.
(*e*) Epulis (in jaw).
(*f*) Lupus.

It is, perhaps, impossible to make a positive clinical diagnosis of actinomycosis. A microscopic examination showing the ray fungus, or a guinea-pig inoculation, may be necessary to establish it. The presence of the yellowish particles in the pus discharge is quite characteristic, though not conclusive. Actinomycosis is probably not as rare as is generally supposed, as it is occasionally mistakenly diagnosticated as sarcoma, carcinoma, osteomyelitis, syphilis, etc.

(*a*) *Sarcoma* is histologically quite similar to actinomycosis. A careful microscopic examination will, however, in actinomycosis show

the presence of the ray fungus and some giant cells. Sarcoma does not break down and suppurate so early. Both occur quite frequently in the young.

(*b*) *Tuberculous disease* is attended by an enlargement of the regional lymphatics. In actinomycosis the regional glands are not enlarged. An examination of the sputum or a guinea-pig inoculation will show the tubercle bacilli if present.

(*c*) *Carcinoma* of the tongue is usually found nearer the base, whereas actinomycosis affects the tip. Then, too, in carcinoma there are lancinating pains, ulceration, and cachexia.

(*d*) *Syphilis*, in the gummatous stage, is more amenable to the iodides. The general history of the case is also an aid in the differential diagnosis. Acute progressive actinomycosis may very strikingly resemble acute phlegmonous inflammation and osteomyelitis.

Treatment.—The iodides are excellent in recent cases. In old cases in which there is a mixed infection, it is less efficient. The remedy should be pushed to pronounced iodism. The injection of a 5 per cent. solution of the permanganate of potash into the cysts, when present, has proved of advantage. Cauterization of the skin and soft parts with the solid stick of silver nitrate is a valuable aid in those cases in which there is a fistula and suppuration. Gautier reports excellent results from the injection of a 10 per cent. solution of the iodide of potash into the mass. Needles connected with both the positive and negative poles may be inserted into the tumor, and 50 milliamperes of current are passed through it. Every minute a few drops of the iodide of potash solution should be injected until a total of 20 minims is used. The electric current decomposes the iodide solution into nascent iodine and potash. The chemicals thus liberated in the actinomycotic tissue exert a favorable influence upon the further progress of the disease. A general anesthestic should be administered for the injections. Repeat the injection and electric current in eight days.

The surgical treatment of actinomycosis consists in anything from simple incision to the complete removal of the entire mass. The disease is best suited to surgical treatment before the stage of suppuration and extension to the regional glands. When it has progressed thus far it is no longer simple actinomycosis, as it is now complicated by a mixed or streptococcal and staphylococcal infection. A simple incision is sometimes effectual, as is, indeed, spontaneous rupture. Should excision be resorted to, it should be complete, and followed by the thermocautery, to prevent the spread of infection to the exposed lymph spaces. After suppuration is established, treat as for tuberculosis, *i. e.*, curette and pack with iodoform gauze.

The disease seems to be self-limited by the formation of a capsule of connective tissue, and by spontaneous rupture.

Iodide of potash or iodonucleoid are probably the most reliable internal remedies.

ACTINOMYCOSIS OF THE MIDDLE EAR.

Actinomycosis of the middle ear is very rare, and the only literature on the subject is the clinical report of a case by Zaufal, of Prague, and a more extended report of the same case, with the postmortem findings, by J. C. Beck, of Chicago, and a second case of Mojocchi, of Italy. The clinical aspect of Beck's case was as follows: Carl J., fifty-four years old, a farmer, always healthy, with a negative history of aural, nasal, and pharyngeal disease, until six months previous to the examination. At that time there was a swelling back of the left ear and left side of the neck. The swelling, at first hard, soon softened, and was never painful. Later a third swelling appeared on the left side of the neck, which opened and discharged pus through a fistula. At this time the hearing became defective. The functional tests of hearing showed a negative Rinné, and Weber lateralizing to the left side, thus showing middle-ear disease. There was no secretion from the external auditory meatus, but the post-superior wall, at the fundus, sagged as in mastoiditis. A swelling the size of the palm of the hand was situated over the mastoid and the region posterior and inferior to it. It did not fluctuate. A smaller swelling, more anteriorly, had a fistulous opening in the region of the tip of the mastoid process. Compression expelled a greenish pus, containing small granules. The subsequent microscopic findings showed the ray fungus of actinomycosis in abundance. A radical mastoid operation was performed, but the healing process was unsatisfactory. Five weeks later the patient died from an intracranial hemorrhage, due to the ulceration of a large bloodvessel in the region of the actinomycotic process. The postmortem was held by Chiari, who found the muscles of the neck on the left side and the upper cervical vertebra infiltrated with pus containing yellowish particles. There was no suppurative process in the cavum tympani. A fistulous tract was traced with a fine probe from the cavum tympani toward the exposed incisure mastoidei. The left sigmoid sinus was filled with a substance of a light yellow color, and was adherent. The cervical glands on the left side were enlarged, and cross-sections showed whitish discolorations. Sections of the tonsils and the contents of the lacunæ were negative as to actinomycosis. The ulcerated artery causing the fatal hemorrhage was examined microscopically by Beck, who found the ray fungi in its walls. This is the first reported case in which the ray fungus has been found in the wall of a bloodvessel.

The only other case of actinomycosis of the middle ear on record is reported by Majocchi, of Italy. In his case, the primary infection was of the lung, the infection of the ear probably occurring during a fit of coughing.

PART II.

THE PHARYNX AND FAUCES.

CHAPTER XVII.

DISEASES OF THE EPIPHARYNX AND BASE OF THE TONGUE.

ACUTE LACUNAR INFLAMMATION OF THE PHARYNGEAL TONSIL.

According to Felix Peltesohn, the "pharyngeal tonsil consists of six fairly symmetrical folds separated by deep furrows running in a sagittal direction, which may be separated from each other like the leaves of a book. Posteriorly and sometimes anteriorly there is a curved fold connecting all of them. In the middle there is a deep fissure—the recessus medius—to which, in some instances, a blind canal leads, and which was formerly erroneously described as an independent structure, the bursa pharyngea, known as Thornwaldt's disease."

Bickel, in defining a tonsil, says it is characterized (*a*) by its well-defined shape, (*b*) by a diffused infiltration of lymph cells and follicles, (*c*) by crypts or lacunæ, that is, mucous pockets lined with epithelium, around which the lymphatic tissue is arranged.

If we take his definition literally only the pharyngeal and faucial tonsils are real tonsils, as the lymphoid tissue in the other parts of the so-called "tonsillar ring" do not have crypts or lacunea.

Symptoms.—Angina lacunaris of the pharyngeal tonsil, like that of the faucial tonsils, is an infectious disease. It is rarely recognized as such by physicians on account of its hidden location back of the postnares and the soft palate. It may be seen, however, with a postnasal mirror. The crypts or lacunæ will be seen filled with a yellowish-white exudate, composed of epithelium, inflammatory exudate, and pus cocci. An inexperienced physician might easily arrive at the erroneous conclusion that the spots were "ulcers;" indeed, the same error has often been made concerning the faucial tonsils. During the acute stage the pharyngeal tonsils are red and swollen.

That the disease is infectious is shown by the clinical data—namely, the initial chill, the rise of temperature, the prostration, swelling of the spleen and cervical glands, and the prolonged convalescence. Microscopic examination reveals a great variety of infectious germs.

The secretion is often so fluid as to ooze out of the crypts and coalesce with that of an adjoining crypt.

Acute lacunar inflammation of the pharyngeal tonsil does not occur as often as acute lacunar inflammation of the faucial tonsils. This is probably due, in part, to the filtering function of the vibrissæ and moist mucous membrane of the nose.

It occurs most often during the first twenty years of life, because the lymphoid (adenoid) tissue is more developed and more sensitive during this period of life. It has a strong tendency to recurrence. The nose becomes obstructed and there is pain upon swallowing, but it is not definitely located as in diseased faucial tonsils. The voice becomes nasal, or void of resonance, as in hypertrophy of adenoids. The glands at the angle of the jaw and in the deep cervical region are swollen and painful upon pressure.

The fever is cyclical, being less in mornings and greater at night. It continues for several days and leaves the patient quite exhausted. The pharyngeal tonsils continue swollen for some time, perhaps permanently after the fever subsides, and causes more or less nasal obstruction.

To one not accustomed to examining the epipharynx the following suggestion by Peltesohn is of great value in making a diagnosis: "If the tongue is drawn so far forward that one can look behind the palatine arch, then one can see the salpingopharyngeal fold, the so-called 'lateral column,' deeply reddened and studded with yellow follicles." This condition is characteristic of angina lacunaris of the pharyngeal tonsil. The tongue should be held with a tongue depressor and pulled forward as in the examination of the larynx. As the space between the soft palate and the posterior pharyngeal wall is still quite wide in young people, the postrhinoscopic examination is easily made.

Patients frequently complain of a feeling of fulness and pressure in the ears, but do not often have active inflammation of the middle ear. The nasal secretions are acrid, and often cause nasolabial excoriations.

Diagnosis.—(*a*) Initial infective fever, chill, and cyclical fever.

(*b*) Obstructed nasal passages and non-resonant voice.

(*c*) Most important of all, the red and swollen follicles of the "lateral column" (follicles just back of the posterior faucial pillars), from which a yellowish secretion is exuding.

These signs, together with the postrhinoscopic examination, will lead to a correct diagnosis.

Treatment.—Experience teaches that during the course of the acute or febrile stage local applications irritate and should not be attempted; even gargles should not be used. The patient should be put in bed and kept there until the disappearance of the fever, or even a few days longer, as the prostration is pronounced. He may be given pieces of ice to hold in the mouth, as it seems to afford some relief. Only a bedridden diet should be allowed.

After complete recovery the adenoid masses, be they large or small, should be thoroughly removed with a curette, otherwise recurrence will likely take place. In adults these recurrences are characterized

by the formation of crusts in the epipharynx. These crusts, therefore, indicate the need of an adenoid operation.

ADENOIDS.

Synonyms.—Adenoid vegetations; pharyngeal adenoids; pharyngeal tonsils; epipharyngeal tonsils.

Definition.—Adenoids are hypertrophied lymph glands which normally exist in the epipharyngeal space. They are chiefly located on the superior and posterior walls of the epipharynx, though they may extend into the fossæ of Rosenmüller and to the mouth of the Eustachian tubes (tuba auditiva Eustachii). Trautmann divides the adenoid pads into two groups, an anterior and a posterior one.

The edges of the walls of the recessus medius sometimes become agglutinated during acute inflammatory processes, and thus convert the groove into a sinus, which becomes infected and continually discharges its secretions into the pharynx (Thornwaldt's Disease).

Etiology.—The chief cause of adenoids is the irritation and inflammation occurring in the epipharynx during attacks of one of the exanthematous fevers. It is a well-known pathological law that the lymphatic structures of children become enlarged or hypertrophied in response to bacterial stimulation, whereas the same stimulation in adults does not cause lymphoid hypertrophy to a corresponding degree.

As the exanthematous fevers occur chiefly n early childhood while the special susceptibility exists, it is but natural to find adenoids most frequently during this period of life.

According to the statistics on this subject by McBride and Turner, adenoids are most frequently found *between the sixth and the fifteenth years of life*, though they may occur at any period. In children who were otherwise normal it has been variously estimated that they were present in from 1 to 9 per cent. of all cases examined. In deaf-mutes they are present in from 50 to 73 per cent. of all cases examined.

While it cannot be said that adenoids are hereditary, they are, nevertheless, in many instances a *family characteristic*, perhaps on account of a similar environment and similar anatomical conformations predisposing to infection of the epipharyngeal tissues.

Climate probably plays but a small part in the causation of adenoids, though it should be said that a cold, damp, changeable climate subjects the mucosa, as well as the general system, to repeated shocks which lower the vital energy of the body and render it an easy prey to microbic irritations within the epipharynx.

Pathology.—The distribution of adenoid tissue in the epipharynx is chiefly on the upper and posterior walls, though it may extend to the fossæ of Rosenmüller and to the orifices of the Eustachian tubes. They are composed of lymphoid tissue enmeshed in a definite though comparatively delicate reticulum of fibrous connective tissue. The essential pathology of adenoids consists in the hypertrophy of the lymphoid tissue

of the epipharynx, which is normally present there. There are other pathological changes which are best described by McBride and Turner in their classical paper on "Nasopharyngeal Adenoids; A Clinical and Pathological Study," from which I quote as follows:

"We may assume the pharyngeal tonsil to be a peripherally placed lymphatic gland, from which efferent ducts pass to the nearest glands in the cervical chain. Like similar glands elsewhere, the pharyngeal adenoid tissue consists of a fibrous connective-tissue framework, supporting masses of lymphoid cells, but owing to its peripheral position it differs from the more deeply placed lymphatic glands in having an epithelial covering upon its free surface. The supporting framework consists of fibrous septa passing through the substance of the gland, from which a very delicate connective-tissue network ramifies in all directions toward the surface. It carries in it the bloodvessels and the lymphatics, while here and there, lying in clusters in the septa, may be seen many mucous glands whose ducts open on the surface. In the meshes of the delicate network lie masses of leukocytes or lymphoid cells, constituting the lymphoid tissue which forms the main bulk of this tonsil. Groups of these cells are specially differentiated in the form of more or less rounded or oval-shaped areas, having centres of a pale appearance, while their margins are more darkly colored. These areas are the follicles or germ centres of Goodsir. Covering the free surface of this tonsil, and dipping down into its recesses and crypts, is a layer of ciliated epithelium, continuous with that lining the respiratory part of the interior of the nose and the adjacent mucous membrane of the epipharynx. The epithelium consists of more than one layer of cells, the superficial ciliated cells being columnar in type, while the deeper cells forming two or three layers are smaller, and rest upon a well-defined basement membrane.

The Epithelium.—"The normal epithelial covering undergoes a certain amount of variation, as might be expected when a growth of this kind, itself subject to variations in size, fills to a varying extent a cavity like the epipharynx, more or less completely surrounded by firmly resisting bony walls, and whose size is intermittently changing through the movements of the soft palate which constitutes its floor. The epithelium is not found to be always of a uniform thickness. While preserving its ciliated columnar type its thickness is seen to vary in parts, so that the lining of some of the crypts presents an irregular outline. In a certain number, however, of the preparations examined there is a marked change in the character of the epithelium, becoming of the stratified squamous variety and of a very considerable thickness. This change and thickness is not general, but is confined to certain areas on the surface of the hypertrophy. It is not normal to this part of the upper respiratory tract, because the whole of the mucous membrane of the pharynx as low as the level of the lower border of the soft palate is covered with ciliated epithelium, and it is from within the area so covered that the epithelium thus altered and thickened shows that these changes occur among the youngest of the patients examined. With two exceptions

at the age of twelve, all were under ten years of age, and in two cases where the thickening was most marked the patients were only four years old. On the other hand, in the sections of the growths removed from patients of fifteen years and upward, with one exception no thickening of the epithelium was observed, so that we are naturally led to the conclusion that this change in the epithelial covering is not one necessarily dependent upon the prolonged existence of the hypertrophy. Occurring, as the examination shows that it does, in the younger patients, it is more reasonable to conclude that it is due to pressure of the growth upon the walls in the smaller epipharynx of the young child. Its presence on the surface and in patches only and less frequently in the crypts are further points in favor of such a view being held. Unfortunately, we are unable to say whether, in those cases in which the epithelium has changed to the pavement type, the adenoid masses were large and more or less completely filled the epipharynx. Such a change in the type of the epithelium as noted here has been observed before, as the result of pressure, and is a point of some histological interest. The pressure to which these growths is subject is intermittent, and is caused chiefly by the elevation of the soft palate in the act of deglutition, pressing the soft, pliant mass upward against the walls of the space, and releasing it again when the act is completed.

The Fibrous and Lymphoid Tissues.—"A considerable variation was found to exist in the relative proportion of lymphoid and fibrous tissue in the growths examined; and we have endeavored, by a comparison of the appearances observed in patients of different ages, to seek some explanation of the gradual disappearance or shrinking which takes place in the hypertrophied adenoid tissue in course of time. An overgrowth of the fibrous tissue takes place. This appears to commence around the bloodvessels by a process of perivascular sclerosis; at any rate, it is in the neighborhood of these vessels that the fibrous thickening is most evident. If an area be examined in which this change is taking place, some of the bloodvessels present a normal appearance, others again show distinct thickening of their walls in concentric rings, with diminution in the size of the lumen. One specimen shows, in a remarkable manner, many of the bloodvessels completely obliterated, partly owing to the great thickening of the walls and partly due in all probability to the contraction of the fibrous tissue outside. Round the vessels there is fibrous tissue formation, varying both in amount and in density, according to the stage of development that has been reached; in this way the lymphoid tissue becomes gradually invaded and areas of cells are isolated by the process. There can be no doubt that it is by fibrous-tissue formation that the gradual shrinking of the adenoid mass occurs. In order to ascertain what relation such a process might bear to the age of the patient, a comparative study of the various growths was made with this end in view.

"From such an analysis it would appear that a development of fibrous tissue takes place in the substance of the adenoid hypertrophy, commencing round the bloodvessels invading the lymphoid tissue, and replacing

it. This process, however, is independent of the age of the patient, and is not one that necessarily commences at or after puberty, but may occur at all ages, and be even more marked in the very young child than in the adult. Here again our experience coincides with that of M. Brindel. The practical deduction to be drawn from these facts is, that we cannot say in any given case that a growth may be satisfactorily left to disappear *per se*. It may or it may not do so at some early period, but because a patient is approaching puberty or adult life it does not follow that the adenoid hypertrophy will in a short time cease to exist. As we have already stated, such growths do, in certain cases, disappear at puberty, but it is quite possible that here a purely physical, as opposed to purely histological, explanation may be called to our aid. Obviously, in the small epipharynx of the child the growth may entirely fill the space, while, as adult life is approached, a free space will be left between the adenoid hypertrophy and the palate. In the former case, each respiration will exercise suction upon the mass, while in the latter this physical effect will be much diminished, if not quite absent."

Fig. 204

An adenoid face.

The foregoing findings should be given wide circulation among the medical profession, as physicians too often advise their patients "to wait for puberty," as the adenoids will "shrink" at that time. "Waiting" for adenoids to "shrink" is always a foolish and dangerous thing. While waiting, the attending inflammation is ever progressing, and may, and actually does in 66 per cent. of all cases, invade the Eustachian tubes and middle ear. Furthermore, it is shown that the atrophy does not occur more after puberty than at a younger age; indeed, that the atrophy is independent of the age of the adenoid patient. Why wait, therefore, for a process of shrinking which has no definite period of occurrence.

Symptoms.—The symptoms of adenoids may be divided into:

(*a*) Objective.
(*b*) Subjective.
(*c*) Collateral.

Objective Symptoms.—The objective symptoms are those appreciated through the special senses of the attending surgeon.

By inspection he notes the open mouth, thick, short upper lip (Fig. 204), the comparatively expressionless countenance, and with the laryngeal mirror he finds the epipharynx to be more or less filled with the adenoid masses.

By *the sense of touch* he distinguishes a gelatinous, worm-like mass in the epipharynx. The finger should be anointed with vaseline before it is introduced into the epipharynx, so as to reduce its frictional qualities to the minimum. Even then great care should be exercised lest the delicate mucous membrane of the epipharynx be injured. In spite of these precautions the finger is often streaked with blood upon its removal. I find the digital examination of more value than the one with the mirror in a majority of the cases. It need occupy but a few moments for its performance.

The examining surgeon should stand in front of and to the right of his patient, encircling his head with the left hand and arm to steady it, while the index finger of the right hand is introduced into the

Fig. 205

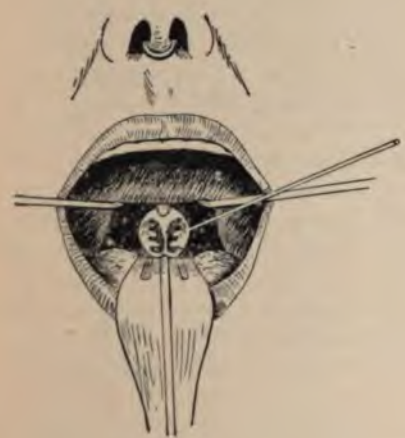

Fig. 206

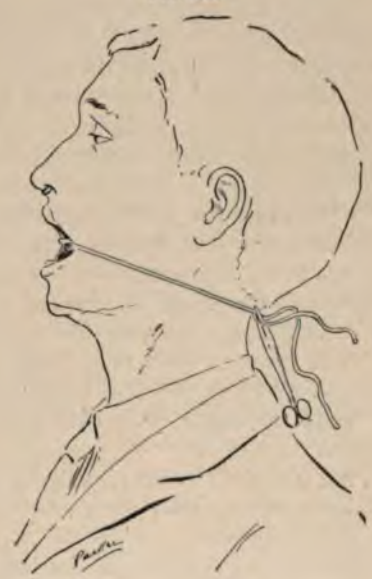

Pynchon's rubber-cord palate retractor.

epipharynx. McBride and Turner have suggested that if the thumb of the examiner is just outside the patient's right cheek, he can prevent biting by pressing the thumb against his cheek wall. The soft tissues being thus forced between the patient's teeth, he cannot bite the examiner's finger.

The faulty development of the chest walls is also characteristic of mouth breathing in children (Figs. 219 and 220).

The sense of smell should also be utilized in the examination for adenoids, as a fetid breath is sometimes present.

The auditory sense should also be utilized in the diagnosis, as the patient's voice is often characteristic. The articulation is muffled and the resonance of the voice is diminished.

The Subjective Symptoms.—Night-time restlessness is a prominent symptom, the patient often throwing the covers off during the unconscious rolling and tossing which is so characteristic of mouth breathers. Night terrors are also frequently complained of, especially if the child is troubled with enuresis. I have often noted that night terrors or horrible dreams immediately precede nocturnal urination.

Night terrors are not present in all cases, perhaps not in more than one-third of them, and is in all probability due to reflex causes and to an excess of the half-way products of metabolism. These dreams are often of the most terrible nature, and are often indelibly impressed upon the memory.

Daytime restlessness is also a characteristic sign of adenoids. The child is fretful and peevish, or is inclined to turn from one amusement to another, or from an imposed duty to play.

Aprosexia or difficult attention, first described by Guye, of Amsterdam, is very often present. The child has difficulty in applying himself continuously to his studies or other tasks set before him. He has fits of abstraction. I once knew a boy in school who was afflicted with ideal abstraction, though he had a fairly good mind. During one of these "spells" his teacher shook him vigorously by the shoulders, and the boy said, "I ain't doin' nothin'." Whereupon his teacher replied, "That's just the trouble; get busy and do something."

Taste and smell are sometimes impaired, which is not strange, in view of the fact that the sense of smell and of taste are so intimately associated, and the epipharynx is blocked with adenoids, thus compelling the child to breath through its mouth.

The breath is often fetid, from the decomposition of the retained secretions and from the disordered stomach so often complained of.

Bilious attacks or a disordered stomach sometimes complicate the case.

An elevated temperature is not an uncommon symptom, as the adenoid growth is frequently the seat of a lacunar or catarrhal inflammation.

Epipharyngeal catarrh is an almost constant accompaniment of adenoids. Indeed, it is doubtful if adenoids of any considerable size are present without a concomitant chronic epipharyngitis, or what is commonly spoken of as a pharyngeal catarrh. This symptom or complication is one of the strongest arguments in favor of the removal of adenoids, as the catarrhal inflammation has a tendency to extend by continuity of tissue into the Eustachian tube and middle ear. In case of an acute infectious exacerbation the middle ear and even the mastoid cells are liable to become involved.

Collateral Symptoms.—*Defective speech* is a symptom of considerable diagnostic and economic importance. The voice is muffled and articulation is imperfect. The resonance, or timbre, of the voice is greatly impaired.

Ear complications are present in a majority of the cases. According to McBride and Turner, who analyzed 307 cases, 255 had ear involvement of one kind or another. Of the 255 cases, 144 were suppurative

and 111 were more or less deaf with non-suppurative ear disease. They say: "We have more than once noticed in children (affected with adenoids) suffering from non-suppurating otitis media that in those in whom the membrana tympani had assumed an appearance which can but be likened to that of ground glass, especially when there was a permanent pinkish tinge, the prognosis as to improvement by subsequent treatment was not good, sometimes positively bad."

It appears, therefore, that the ear complications, whether of the suppurative or non-suppurative type, may be serious.

Diagnosis.—The diagnosis in most cases is so obvious that it scarcely warrants special mention. There are exceptional cases, however, in which an error in this regard may be made. It may be stated as an almost universal rule that *when the tonsils are hypertrophied adenoids are also present.* Conversely, it cannot be said that when adenoids are present the tonsils are also hypertrophied, as statistics show that only 30 per cent. of the cases with adenoids had enlargement of the tonsils. It appears that the adenoids most easily undergo enlargement, the tonsils next, and the lingual less than either of the other lymphatic structures composing Waldeyer's ring.

The *fringe of the adenoids* seen on the posterior wall of the pharynx, just below the line of the soft palate, is quite characteristic of adenoids. When these nodules are present in a child, I am quite certain of the diagnosis, even without further examination, though I do not recommend that the examination should stop here.

The epipharyngeal mirror should be used, when possible, to enable the surgeon to see the adenoids and their distribution. In many cases this method of examination cannot be adopted on account of the reflex closure of the palatal muscles against the posterior pharyngeal wall.

When the mirror cannot be used the index finger of the right hand should be introduced through the mouth into the epipharynx for the purpose of detecting the gelatinous worm-like mass of adenoid tissue.

It is not sufficient to merely determine the presence of a large adenoid cushion in the vault, or on the superior posterior wall of the epipharynx, but the examiner should determine whether the fossæ of Rosenmüller or the tubal orifices are covered by the growths. Adenoids are not removed merely because they are enlarged, but because of the epipharyngitis which almost always attends them and on account of their presence in the fossæ of Rosenmüller and the Eustachian orifices, even though they be small.

Fibrous tumors of the epipharynx are sharply defined and are dense in texture, whereas adenoids are not sharply defined and are soft in texture, hence there need be no difficulty in making a differential diagnosis.

Malignant tumors of the epipharynx can scarcely be mistaken for adenoids if an ordinarily careful examination is made. The hemorrhage, cachexia, and other symptoms readily distinguish the cancerous growths.

Tuberculous and *syphilitic* granulomata rarely simulate adenoid growths. Carel has reported two cases of tertiary syphilis, and

Lermoyez a case of tuberculosis of the epipharynx, which closely resembled, in general symptomatology, adenoid growths.

Prognosis.—The prognosis from the standpoint of the mentality of the patient varies from slight retardation of mental development to an almost complete arrest of it. The improvement in the mental growth after operation is often marvellous, provided the operation is performed during the natural period for such development, *e. g.*, during infancy and childhood.

Fig. 207

Brandegee's adenoid forceps.

If the removal of the growth is delayed until the individual has practically attained full growth, the mind will rarely develop to any considerable degree.

The general health rarely improves during infancy and childhood so long as marked adenoids remain. If, however, they are removed, the blood becomes red from free oxygenation and all the vital energies are quickened and increased.

The "facial or adenoid expression" improves somewhat with advancing years, though it often remains as a permanent disfigurement through life. If the adenoids are removed sufficiently early in life the "adenoid expression" often disappears, or its further development is prevented.

The removal of adenoids often prevents serious ear complications, improves the general health, and beautifies the face.

Fig. 208

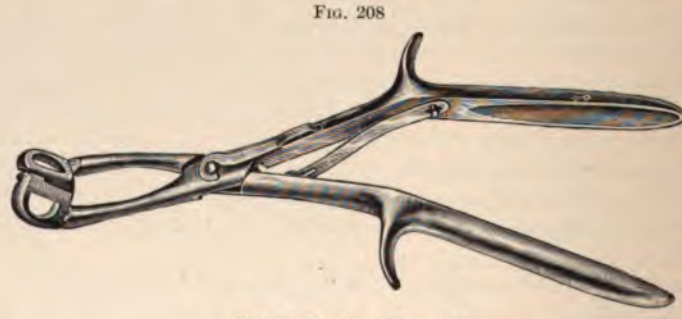

McAuliff's adenoid forceps.

Treatment.—There is but one treatment worthy of the name, and that is the surgical removal of the growths. Astringent applications have been and are still advocated by some writers, but in my opinion their use is but a means to postpone the day when their removal must take place. I can conceive how a congestion and inflammation of the lymphoid masses might be relieved and greatly improved by the local use of alkaline and

astringent washes, but when true hypertrophy has occurred the curette or forceps offer the best means of treatment.

Adenoids may be removed with the Meyer ring curette through the nose, though this is an almost obsolete method. A more rational and effective method is with a Gottstein curette or some modification of it. During the last few years I have depended more and more upon an adenoid forceps of the Brandegee pattern.

Fig. 209

The correct position of the patient under general anesthesia for the removal of adenoids and tonsils.

Technique.—The following technique may be employed for simple adenectomy, while in combined adenectomy and tonsillectomy ether anesthesia is preferable (Figs. 209 and 210).

(*a*) Nitrous oxide anesthesia.

(*b*) The removal of the adenoids with the Brandegee forceps: The instrument is introduced, closed, through the mouth in much the same manner as is used in introducing the curette; that is, the curved tips are turned behind the posterior pillar of the patient's right side and then passed upward behind the soft palate and rotated toward the median line as they engage behind the soft palate. The biting tips are then opened and forced upward against the vault of the epipharynx, the handles meanwhile being held against the upper teeth. Having forced the tip against the vault, they should be pushed backward against the posterior wall of the epipharynx. The blades should then be closed, care being taken to hold the

Fig. 210

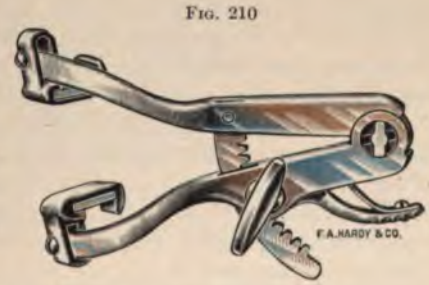

Furguson-Pynchon mouth gag.

handles against the upper teeth. The rocking motion used with the curette is to be studiously avoided when using the forceps. Should the handle of the instrument be lowered while the blades are open in the epipharynx, they will engage the posterior end of the septum and injure it.

Having closed the forceps, it should be removed with a downward pull, bringing the adenoid mass out between the cutting blades. The instrument may be introduced more than once if necessary.

(*c*) Introduce the curette (Fig. 211) in the same manner. When introduced use pressure in an upward and backward direction, and move the handle of the instrument up and down between the upper and lower teeth. The soft palate should be the imaginary fulcrum during these movements. By thus manipulating of the curette both the superior and posterior walls are scraped free of the adenoid pads. The instrument should be introduced between the Eustachian prominences, so as to include the entire width of the growth.

(*d*) Introduce the right index finger into the epipharynx and rub away any shreds and remnants of adenoid tissue which may remain. Also explore Rosenmüller's fossæ with the finger tip and remove the adenoid cushion from them should it be present.

Fig. 211

Boeckmann's adenoid curette.

(*e*) The patient's head should then be held over the fountain cuspidor until bleeding stops or consciousness is restored.

The operation is done with the patient in the sitting posture, preferably in the lap of an assistant. He is wrapped with a sheet, which is pinned tightly about him to prevent his arms getting in the way during anesthesia.

I sometimes do the operation without a general anesthetic if the patient is old enough to submit without resistance. The pain is not great and the danger from an anesthetic is obviated. It should be said, however, that the danger from nitrous oxide gas is practically nil, whereas several cases are on record that died under chloroform.

J. F. Barnhill claims that by the use of a Boeckmann curette (Fig. 221) as wide as can be introduced through the isthmus of the pharnyx the entire adenoid mass may be removed with one sweep of the instrument. This method precludes the accidental injury of the Eustachian pads, as often occurs with narrower instruments in the attempt to remove the lateral portions of the growth.

According to Moure the epipharyngeal space varies greatly in shape, a fact which largely determines the completeness with which adenoids may be removed with the usual form of curette and forceps. If the epipharyngeal space is normal in shape (Fig. 212), the curette and

forceps will completely remove the adenoids. If there is a recess in the vault (Fig. 213) these instruments will fail to remove all the tissue. If there is a recess in the posterior wall of the epipharynx (Figs. 214 and 215), the forceps and curette of the usual type will fail to remove all the

FIG. 212

1, normal vault of the epipharynx from which adenoids may be removed with Boeckmann's curette; 2, posterior wall of the pharynx; 3, posterior end of vomer in its normal relation to the hard palate; 4, uvula; 5, hard palate; 6, sphenoid sinus.

FIG. 213

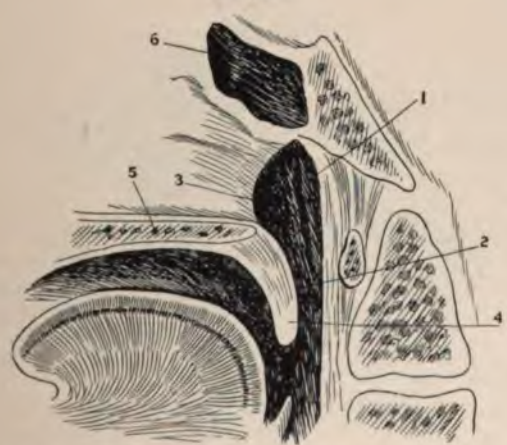

An epipharynx with an angular superior pouch, from which adenoids could be removed with a Boeckmann curette, excepting, possibly, the upper angle of the pouch. This region might necessitate the use of a special curette. 1, 2, 3, 4, 5 and 6 refer to anatomical points (Fig. 212).

tissue. These facts may account for many failures following adenoid operations. If there is a recess in the upper wall of the epipharynx, a specially designed curette (Fig. 216) should be used to complete the operation. If there is a recess in the posterior wall of the epipharynx,

the Meyer ring curette (Fig. 217) introduced through the nose, or the curette shown in Fig. 218 should be used to complete the operation.

Sequelæ.—The Face.—The development of the face is often materially modified by the presence of adenoids. The open mouth, the absence of the

Fig. 214

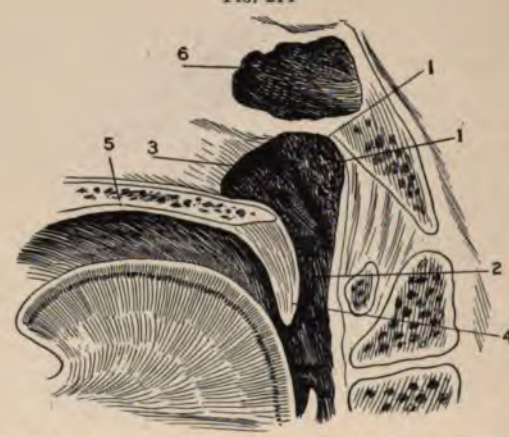

An epipharynx with a shallow posterior pouch from which the adenoids could be removed with Boeckmann curette, except in the posterior portion of the pouch. 1, a slight recess in the posterior wall of the vault of the epipharynx in which adenoids are inaccessible to the Boeckmann curette; 2, 3, 4, 5, and 6 refer to anatomical points. (After Moure.)

Fig. 215

An epipharynx with a deep pouch in the posterior wall, from which adenoids could not be removed with the Boeckmann curette. Such cases should be operated through the nose with Wilhelm Meyer's ring curette (Fig. 217), or with a specially curved curette (Fig. 218).

nasolabial folds, the short upper lip, and the protruding and twisted central incisors of the upper jaw, the broad, flat, upper half of the nose, and the narrow, slit-like nasal openings, all conspire to give the so-called "adenoid face." The general expression is one of stupidity. The

degree of the facial disturbance varies greatly in different cases, usually in proportion to the degree of the nasal respiration, rather than the actual size of the adenoid growths. According to J. E. Schadle, the average capacity of the epipharynx is about 17 c.c., and its lateral is longer than its anteroposterior diameter. If the capacity of the epipharyngeal space is diminished, or its anteroposterior diameter is contracted, a small adenoid mass may produce a more pronounced nasal obstruction than a larger growth in a more roomy epipharynx. The facial expression is more modified in the former than in the latter instance. It should not be deduced from the foregoing statements that the indications for treatment are in proportion to degree of nasal obstruc-

Fig. 216

Special curette for reaching the recesses in the vault of the pharynx.

Fig. 217



Meyer's ring curette.

Fig. 218



Pynchon's pharyngeal curette.

tion *per se,* as there are several other conditions resulting from small as well as larger adenoids that call for their removal as urgently as the complete nasal stenosis.

The Interior of the Nose.—The interior of the nose is also modified in its development. J. S. Thompson called attention to this fact in an article wherein he states that the loss of the physiological stimulation incident to nasal respiration results in underdevelopment of the turbinals, and that deviated septa are common. Such individuals are more subject to intranasal diseases, for obvious reasons.

The Hard Palate.—Adenoid subjects usually have a "gothic" or arched palate, especially in its anterior portion. The arch is apparently higher than normal, though, as Newkirk has shown by numerous casts, the increased height is apparent rather than real. The illusion arises from the contraction of the lateral diameter of the upper jaw while the height of the arch remains the same, thus producing a marked disproportion between its width and height.

The Teeth.—The contraction of the lateral diameter of the arch sometimes causes the central incisors to protrude and to be twisted upon their axes so as to cause their posterior surfaces to face. The teeth are often irregular, and require the services of a dentist to regulate them.

Epipharyngeal Inflammation.—When adenoids are present the epipharyngeal mucous membrane is almost always the seat of local inflammations of both the acute and the chronic type. The low resistance of the adenoid tissue, the rarefied or abraded cylindrcial epithelium, the retention of the secretions, and the insufficient ventilation of the epipharyngeal space all conspire to produce inflammatory processes. The inflammation may be lacunar, either acute or chronic, or it may be a diffused catarrhal inflammation affecting the mucosa covering the adenoids and the adjacent structures.

The Auditory Apparatus.—Adenoids are a prolific source of tubal, middle ear, and mastoid inflammations. It is a common clinical experience to see children with adenoids who complain of recurrent attacks of earache which is relieved by tympanic inflation. The Eustachian tubes are closed by catarrhal swelling, or "plugged" with thick, tenacious mucus, and the air in the tympanic cavity becomes absorbed and rarefied.

The drumhead is retracted and the mucous membrane lining the tympanic cavity is hyperemic. Tubal and middle-ear catarrh are thus established.

Suppurative otitis media is also caused by adenoids. The infective material from the epipharynx enters the tubes and middle ear during the acts of coughing, sneezing, or other violent movements of the pharyngeal and palatine muscles. Then, too, the ciliated columnar epithelium of the tubes may become rarefied or broken down by the pressure of the opposed walls from the catarrhal swelling. The absence of the ciliæ permits the infected secretions to travel toward the middle ear, and infection thus becomes established in the tympanic cavity.

Having gained a foothold in the tympanic cavity, it is but another step for the infection to invade the mastoid cells. The middle ear and mastoid inflammation is usually proportionate to the virulency of the microörganisms causing it. The labyrinth may also become involved in the infective inflammations of the middle ear, though such an occurrence is rare. Deafness, in some degree, is always present in the foregoing ear complications of adenoids.

The Mental Faculties.—The mental faculties are often much impaired in adenoid subjects. Among the mental states commonly present is that known as "*aprosexia*," or difficult attention. The child is listless and soon tires of his play, studies, or other tasks. He is "backward" in school in pronounced cases, while in those in which there is little obstruction his mental faculties are but little affected.

The Respiratory System.—The anterior nasal openings are narrow and slit-like, while the turbinated bodies are underdeveloped. Catarrhal inflammation of the mucosa of the nose finds favorable conditions for its development. The lateral walls of the chest are contracted (Figs.

219 and 220), thus throwing the ensiform cartilage into prominence. This characteristic deformity is known as "pigeon chest." The lungs are also undersized and respiration is shallow. The transfusion of gases through the walls of the air vesicles is impaired. Too little oxygen passes into the blood, while too little carbon dioxide is thrown off. The patient is both anemic and nervous, and is often irritable to a marked degree.

The Bones.—Frederick Coolidge called attention to the apparent relationship existing between adenoids and the various forms of clubfoot. I have often confirmed the saying that "if you will show me a bow-

Fig. 219

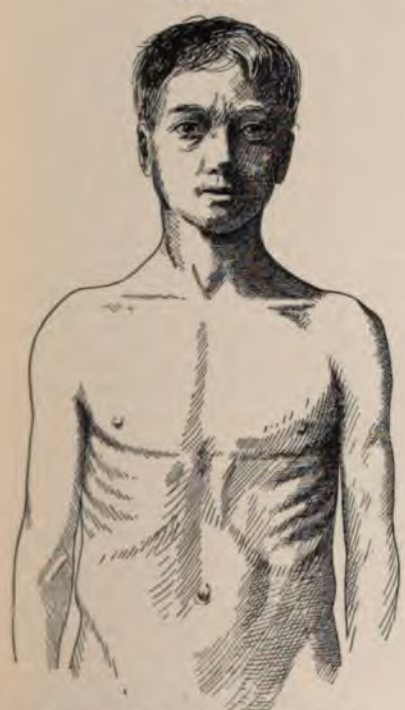

Deformity of the chest due to adenoids.

Fig. 220

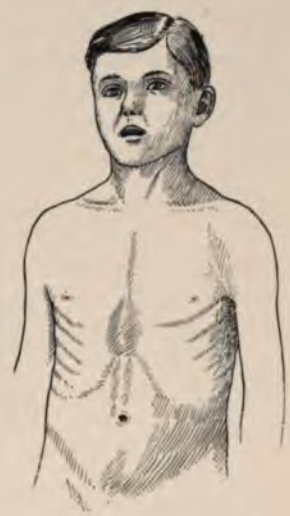

Author's type of chest deformity due to adenoids.

legged man I will show you one that had adenoids in infancy." Adenoids affect the nutrition, partly through the anemia present and partly through the excess of carbon dioxide in the blood. These two conditions cause faulty metabolism and nutrition. The bones are deficient in lime salts, hence are soft and easily bent under the weight of the body.

The Blood.—Adenoid patients are usually anemic. The red blood corpuscles are deficient in number and in hemoglobin. Carbon dioxide is present in excess. The nutrient qualities are diminished in quantity and quality.

Thornwaldt's Disease.—This condition is characterized by a suppurating canal in the recessus medius or groove between the lateral halves of the adenoids. It is due to the inflammatory adhesions of the median

Fig. 221

Pharyngeal scissors.

borders of the adenoid masses. That is, the recessus medius, a groove between the lateral halves of the adenoids, becomes converted into a canal. The lining membrane of the canal becomes infected and discharges purulent secretion. The symptoms are those of chronic pharyngitis attended by a cough.

Fig. 222

The operative treatment of Thornwaldt's disease. *a*, the left blade of the pharyngeal scissors introduced into the suppurating sinus between the lateral halves of the adenoids; *b*, the right blade of the scissors at the border of the adenoid tissue. When the blades are closed the lateral half of the adenoids upon this side is severed. The scissors are then transferred to the other lateral half of the adenoid tissue and closed. This completely severs the lower portion of the adenoid tissue, and obliterates the suppurating sinus. The remaining upper portion of the adenoids, *c c d*, is then removed with the scissors or a curette.

The canal may be seen by the use of a throat mirror, and a curved probe may be passed into it.

The author's method of treating it is to introduce one blade of the curved pharyngeal scissors (Fig. 221) into the canal and then cut off one lateral half with the scissors (Fig. 222). This is a better way than to attempt to remove the adenoids in the usual manner, as the fibrous canal is so dense it is difficult to cut it. The posterior and remaining portion of the canal wall should be thoroughly curetted to remove the pyogenic membrane.

THE LINGUAL TONSIL.

The lingual tonsil is situated on the base of the tongue between the faucial tonsils and extends anteroposteriorly from the circumvallate papillæ to the epiglottis. It is divided in the median line by the median glosso-epiglottic ligament. The tonsil consists of numerous rounded or circular crater-like elevations which are composed of lymphoid tissue, which at their circumference are surrounded by connective tissue. In the centre of each crater the mouth of the duct of a mucous gland opens. The crater or crypt is lined by stratified pavement epithelium.

The lingual tonsil usually reaches its greatest development in young children, and, like the other tonsil structures, may begin to atrophy at the age of puberty. In the adult the number of masses is generally greatly reduced, though they may be greatly hypertrophied.

Here, as in the other portions of the tonsillar ring surrounding the oropharynx, leukocytes are thrown out in great abundance.

Acute Catarrhal Lingual Tonsillitis.—Acute catarrhal inflammation of the lingual tonsil is characterized by a moderate rise of temperature, painful deglutition, and a burning, pricking sensation in the throat. There may be some tenderness on pressure in the region of the great cornu of the hyoid bone. Upon inspection the pharynx and the pillars of the fauces may be slightly reddened, while the faucial tonsils may appear normal. The laryngeal mirror shows the lingual tonsil masses to be greatly reddened and swollen.

Treatment.—The treatment consists in brushing the inflamed masses with a 20 to 50 per cent. solution of the nitrate of silver.

Acute Lacunar Lingual Tonsillitis.—The symptoms of acute catarrhal inflammation are present, and in addition the craters or crypts are lined with a whitish exudate and epithelial debris and microörganisms quite similar to the accumulations found in acute lacunar (faucial) tonsillitis.

Treatment.—The treatment consists of the local application of a 20 to 50 per cent. solution of the nitrate of silver.

Acute Phlegmonous Lingual Tonsillitis.—This process is usually characterized by a purulent accumulation beneath the lymph nodules at the base of the tongue, usually limited to one side. The temperature is elevated and the pain upon deglutition is severe. The patient complains of soreness and great tenderness upon pressure in the region of the great cornu of the hyoid bone upon the affected side. Inspection with the throat mirror shows great swelling and redness at the base of the tongue

upon the affected side. Palpation with the finger may or may not elicit fluctuation.

Phlegmonous inflammation here, as in the faucial tonsil, may undergo resolution without the formation of an abscess.

Treatment.—Treatment consists of incisions into the swollen tissue.

Hypertrophy of the Lingual Tonsil.—Hypertrophy of the lingual tonsil is rare in children and usually occurs between the twentieth and the fortieth years of life. It is more common in females. It is probably caused by repeated or continued infection of the lymph structures of the pharynx and fauces and epipharyngeal tonsils.

Symptoms.—The symptoms are sometimes absent, though the sensation of a foreign body in the throat is usually complained of. There is a pricking sensation, as though a splinter had lodged in the fauces, or the patient complains of the sensation of a lump, a hair, or other foreign body in the throat. Paresthesia of the pharynx presents the same symptoms (Ball), and hence neurosis of the pharynx must be differentiated from this condition. So also must foreign bodies. According to Lennox Browne, troublesome fits of coughing are often present.

During meals the symptoms disappear. Pain is rarely complained of except the disagreeable sensations already referred to. The use of the voice increases the symptoms, and often gives rise to the pricking sensation and the cough.

Upon examination with the throat mirror a few enlarged masses are seen upon the base of the tongue. Both sides are usually involved, though it may be limited to one. The masses may be so large as to push the epiglottis backward or even to overhang it.

According to Ball, Seifert emphasizes the value of the use of the probe and of cocaine in the diagnosis between paresthesia of the pharynx and hypertrophy of the lingual tonsil. With the probe the patient is enabled to locate the sensitive areas giving rise to the symptoms, and the application of cocaine causes these areas upon probing to give forth no symptoms.

Treatment.—The treatment is essentially surgical. Local applications of glycerin iodine, gr. xx to xxx to the ounce, afford relief by reducing the swelling and sensitiveness. Linear cauterization of the masses is an effective treatment, though the removal of the masses with stout, curved scissors has proved to be the best treatment in my experience.

Lingual Varix; Varicose Veins.—Lennox Browne, in his treatise on the *Throat and Nose*, says that varix occurs in 10.6 per cent. of the cases coming to the Central London Throat, Nose, and Ear Hospital. As early as 1863, G. Lewin, of Berlin, reported on pharyngitis varicosa, with sensations of scraping, burning, and dryness of the pharynx. Since then many writers have reported similar cases, so that its existence as a rather common form of disease is well established. I have seen cases in my own practice which presented the clinical picture described by Browne and others. It occurs more frequently in males, according to Browne (69 per cent.), though Swain and Seiss found it more frequently in females, while Seifert found it equally prevalent among males and

females. Excessive and improper use of the voice is an exciting cause. It is rare in childhood and most common between the twenty-fifth and forty-fifth years. Infectious inflammations of the pharynx and faucial tonsils and infection of the lymphoid tissue of the lingual tonsil probably are the chief etiological factors. On account of the greater resistance to these influences possessed by the lingual tonsil, hypertrophy in this region does not occur as early in life as it does in the faucial and pharyngeal tonsils. Hence chronic infectious processes are often necessary to establish the hypertrophy of the lingual tonsil and varix of the veins. Browne believes that a constitutional or acquired debility of the vasomotor system is the chief cause. Some cases are reported as occurring at the period of the menopause. Constipation and an obstructed portal circulation are etiological factors of some importance.

Pathology.—I am indebted to Escat for the information that, according to Verneuil, "superficial varices only make their appearance when the deep varices have acquired a certain development." Escat also says: "Many kinds of neuralgia, otherwise inexplicable, are today attributed to circulatory troubles in the satellite veins of the nerves, and to a consecutive neuritis." Quenu has thus explained certain neuralgias: "The trunk of the lingual nerve, the evident seat of a glossodynia, is in effect, according to Foucher, accompanied by a satellite vein, and even by two, according to Zückerkandl." This anatomical fact is held by Escat to support his hypothesis, and that of Piotrawski, that all neuroses in this situation may be attributed to varices, superficial and deep.

Symptoms.—As lingual varix is usually associated with hypertrophy of the lingual tonsil, the symptoms are about the same. Upon inspection, tortuous veins, bluish in color, are seen at the base of the tongue partially hidden by the hypertrophied tonsil.

Treatment.—The treatment consists in applying the galvanocautery point to the enlarged veins, and the removal of the hypertrophied lymphoid masses with the cautery point or with scissors. I have frequently resorted to these methods of treatment with satisfactory results. The after-treatment consists in gently massaging the wounds with a cotton-wound applicator dipped in a mixture of equal parts of glycerin, tr. ferri chloridi, and tr. iodini, at intervals of twenty-four hours. This prevents exuberant granulations and promotes healing with a smooth wound and a minimum of cicatricial contraction.

CHAPTER XVIII.

INFLAMMATORY DISEASES OF THE MESOPHARYNX AND FAUCES.

SIMPLE ACUTE CATARRHAL PHARYNGITIS.

THIS form of acute pharyngitis is usually accompanied by acute rhinitis, or "cold," though the pharynx may be chiefly affected.

Etiology and Pathology.—The etiology and pathology is the same as given under acute rhinitis, though digestive disorders play a more prominent role in causing the disease.

Symptoms.—The onset is characterized by malaise and a slight rise in temperature, as in acute rhinitis. The borders of the soft palate and the uvula are slightly red, while the adjacent mucous membrane is normal in appearance. As the disease progresses the uvula becomes slightly edematous and the secretions are increased. The uvula may become markedly edematous and painful, though this is not common. The tonsils are not usually involved, though they may become involved in severe cases. Pain is usually present, especially upon swallowing, and stiffness and aching of the neck muscles is complained of. Dysphagia or painful swallowing is a constant symptom.

Diagnosis.—The erythema of secondary syphilis may be confounded with this disease. The differential points are (*a*) the darker or dusky color (in syphilis) of the mucous membrane; (*b*) the more marked involvement of the tonsils and soft palate, the diminished secretion; (*c*) the line of demarcation between the inflamed area and the hard palate; (*d*) the dusky symmetrical patches on the anterior pillars; (*e*) the opalescent appearance of the mucous membrane of the tonsils and the persistence of the disease, as contrasted with the evanescence of acute catarrhal pharyngitis.

Treatment.—As the acute affection is somewhat dependent upon the presence of chronic rhinitis and sinuitis, these conditions should receive appropriate attention. The methods of treatment given for acute rhinitis are also of value, as the morbid process is almost identical.

The anatomical peculiarities, however, render special modes of treatment necessary.

Local treatment should vary according to the stage of the inflammation. Broadly speaking, astringents should be used in the first and third stages and sedatives in the second stage (Parker). They may be applied as gargles, sprays, paints, or lozenges. Gargles are suited to inflammations of the soft palate, uvula, and anterior pillars of the fauces. Sprays and paints are especially good methods of making local applications. Preliminary to all local treatment the alimentary tract should be evacuated.

From 5 to 10 grains of calomel, followed in six hours with a tablespoonful of castor oil, should be given. The following morning a tablespoonful of Epsom salt should be given to flush the bowels (Stucky). Having done this, the patient's condition is favorable for a speedy recovery under simple local treatments.

The following mixture is recommended by Parker:

℞.—Borax		gr. xxiv
Glycerin		♏ xxiv
Tincture of myrrh		♏ xxiv
Aquæ des.	q. s. ad	℥j

Sig.—Use every hour as a gargle.

If preferred, a gargle composed of 6 grains of alum, 15 grains of chlorate of potassium, to the ounce of water, may be used.

The patient may be supplied with lozenges containing krameria or catechu, with instructions to dissolve one of them in his mouth every three hours. A cold compress should be worn across the front of the neck.

After twelve hours red gum lozenges, which are very sedative, may be substituted for those containing krameria and catechu. A simple gargle containing 15 grains of the chlorate of potash to the ounce of water may also be used every three hours.

The inhalation of steam charged with the compound tincture of benzoin, one tablespoonful to the pint of boiling water, should be used if the throat is painful.

Pastils containing 3 grains of bismuth and $\frac{1}{40}$ grain of the acetate of morphia may also be dissolved in the mouth every three hours to relieve a painful throat.

Should edema of the uvula occur, it should be scarified or amputated.

CHRONIC PHARYNGITIS; GRANULAR PHARYNGITIS; LACUNAR PHARYNGITIS, OR CLERGYMAN'S SORE THROAT.

This disease may or may not be characterized by pronounced subjective symptoms, as irritability and dryness of the throat.

Etiology.—The chief etiological factors in the production of this disease are gouty and rheumatic diatheses, smoking and improper breathing in public speakers and singers, and the presence of morbid processes in the nose, accessory sinuses, and the epipharynx. Patients with a gouty or rheumatic taint complain of throat symptoms, whereas if they are free from gout and rheumatism they often make no such complaint. These conditions probably not only aggravate the pharyngitis, but to a certain extent influence its occurrence. Smoking to excess also aggravates and produces the inflammation. Clergymen, singers, auctioneers, and hucksters, who breathe through their mouths and abuse the vocal apparatus, are frequently affected by chronic pharyngitis. Chronic rhinitis, and especially sinuitis, affecting the posterior and ethmoidal and sphenoidal cells is very frequently the chief cause of the disease.

The changed respiratory functions of the nose in these diseases subject the pharynx and the lower respiratory tract in general to irritation. Of even greater importance is the discharge of heavy mucous or mucopurulent secretions from the nose and accessory sinuses into the pharynx. The secretions are charged with pathogenic bacteria, and have undergone decomposition, whereby certain irritating chemical products are liberated, and as the secretions flow over the pharynx the pathogenic bacteria attack the weakened mucous membrane and excite inflammatory reactions. The chemical irritation also adds to the reaction.

I wish, therefore, to emphasize the importance of making a careful examination of the nose and accessory sinuses in all cases of chronic pharyngitis.

Pathology.—The changes in the mucous membrane consist at first of an increased hyperemia and local leukocytosis, and later of the deposit of the least differentiated cells or connective-tissue cells. That is, hyperplasia of the mucous membrane occurs. The lymph tissue around the tubular glands of the pharynx are enlarged and are raised above the surface of the mucous membrane. Occasionally the tubular glands are filled with a whitish exudate or cheesy material.

Symptoms.—Subjective symptoms are not always present, especially if the patient is free from the gouty or the rheumatic taint, or if they do not misuse the voice. In gouty and rheumatic patients who smoke to excess or breathe improperly the subjective symptoms are usually present.

Subjective Symptoms.—In aggravated cases the voice becomes hoarse after moderate use, especially in public speakers, though the cords are neither red nor inflamed. According to Lennox Browne, the hoarseness is due to a spasm of the muscles of the pharynx and irritation of the superior laryngeal nerve, which supplies the thyroarytenoideus, one of the tensor muscles of the cords.

Smokers complain of a dryness or of the sense of a foreign body in the throat. They have a constant desire to hawk and expectorate.

Cough may be present, though it is often absent. When present it is irritable and hacking in character.

The secretions in the early stage of the disease are excessive, thick, and tenacious. At a later stage the glandular functions become impaired and the throat dry and glazed.

The digestive tract is disordered, the breath foul, and constipation is the rule.

Objective Symptoms.—Upon examination of the pharynx the mucous membrane appears redder than normal, at least in certain areas. In other areas it is pale and fibrous in appearance, especially in old chronic cases. Enlarged bloodvessels often extend across the posterior pharyngeal wall. The secretion is often thick, heavy, and mucopurulent, though in the later stages it may be scanty and only form a film over the surface. In these cases the patient complains of dryness of the throat. The uvula is often relaxed and elongated (Fig. 226), and should be amputated.

The lymph follicles of the posterior wall and of the lateral walls behind the posterior pillars of the fauces are enlarged from hyperplasia. This condition is often referred to as pharyngitis hyperplastica lateralis, a needless subdivision of chronic pharyngitis. The follicles are sparsely distributed on the posterior wall of the pharynx, but are closely grouped along the lateral walls. They appear as yellowish-red raised areas on the posterior wall and as nodular elongated masses behind the posterior faucial pillars.

Prognosis.—In the early congestive stage simple astringent and demulcent local remedies combined with the regular use of a mild aperient mineral water will effect a cure. In the more advanced cases in which hyperplasia of the mucous membrane has occurred, and in which the lymph follicles are hypertrophied, improvement will only follow the destruction of the tubular glands around which the lymph masses are located.

Fig. 223

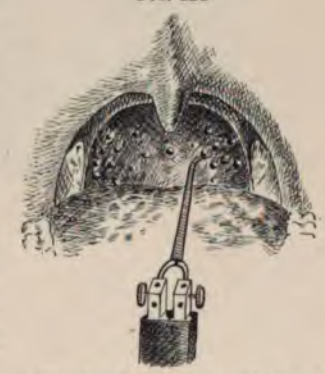

Showing the cautery point applied to pharyngeal follicular glands in the treatment of follicular pharyngitis. From four to five follicles may be thus treated at a sitting under cocaine anesthesia.

Treatment.—In mild cases and during the early stage of the disease, or before it has advanced to marked hyperplastic and hypertrophic changes, the remedies given under acute catarrhal pharyngitis may be used with some success.

Aperient salines should be given daily for a long period to eliminate the gouty and rheumatic toxic material and to free the stomach and intestines of putrefactive material.

In the well-advanced cases the lymphatic nodules, whether discrete or massed, as they may be on the lateral walls behind the posterior pillars of the fauces (pharyngitis hyperplastica lateralis), should be punctured with a cherry-red cautery electrode (Fig. 223). The mucous membrane should be brushed once or twice with a 10 per cent. solution of cocaine, and from four to five hyperplastic follicles burned out with the electrode. Follow with a spray of Seiler's solution, to soothe the burned areas. At the end of the fifth or sixth day four or five more follicles may be treated in a similar manner, and so on until they are all destroyed. This course of treatment is often very beneficial, though it may fail if the gouty or rheumatic diatheses are not also corrected. When the uvula is elongated it should be amputated.

EDEMA OF THE UVULA.

Acute inflammation of the faucial structures, especially of the peritonsillar tissue, is frequently attended by edema of the uvula.

The treatment generally recommended is scarification or multiple

punctures, to allow the excess of serum to escape. A more rational procedure would be to promote a freer flow of the blood through the tissues, and thus remove the obstruction to the blood current through the veins. The application of the rays of light and heat from a 500 candle-power electric lamp (Fig. 19) to the neck at the angle of the lower jaw acts admirably in this way. The lamp should be suspended

Fig. 224

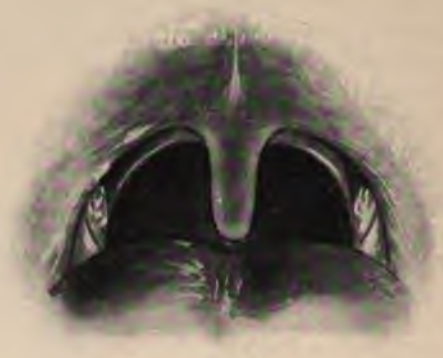

Edema of the uvula.

at a distance of eighteen inches from the patient and slowly passed back and forth over the neck for from fifteen to thirty minutes, three times daily. The patient's neck should then be sponged with iced water to prolong the hyperemia.

Astringent lozenges containing krameria and alum may be used with comfort to the patient.

ELONGATED UVULA.

An elongated uvula is not a disease *per se*, but is a symptom of a chronic pharyngitis, especially epipharyngitis. The relaxed pendulous condition of the uvula is due to the irritation resulting from the epipharyngeal discharge and to the changed nutrition attending the epipharyngeal infection and inflammation. The uvula may be slender and pendulous, or it may be enlarged (hypertrophied) and pendulous. An elongated and elastic uvula is sometimes observed as an idiopathic condition, as shown in the author's case (Figs. 225 and 226).

Symptoms.—In robust subjects it causes but slight or no symptoms. In sensitive patients it often causes a reflex cough when it touches the epiglottis or the base of the tongue. The cough may be spasmodic, and is usually dry. Nausea and vomiting, especially early in the morning, are sometimes complained of. Patients have applied to me for the relief of the persistent hacking cough, fearing tuberculosis had set in. An examination of the lungs failed to reveal disease in that region, whereas

an examination of the throat showed the presence of a long pendulous uvula. The amputation of the lower relaxed portion of the uvula immediately stopped all symptoms.

Fig. 225

Fig. 226

Fig. 225.—Author's case of elastic uvula. (See Fig. 226.) Note the spiral arrangement of the mucous membrane of the uvula when the muscle of the uvula is contracted.

Fig. 226.—Author's case of elastic uvula, evincing no tendency to elongation when at rest. (See Fig. 225.)

Fig. 227

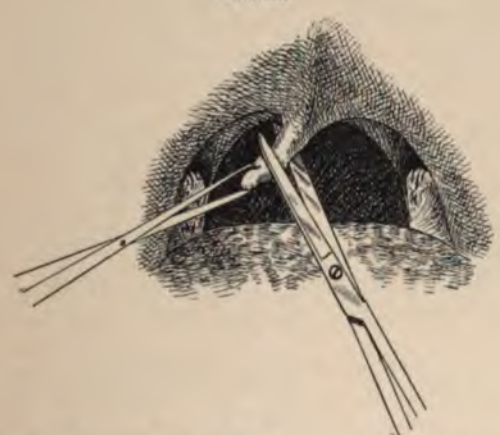

The amputation of the elongated tip of the uvula just below the lower extremity of the muscle. The scissors are so applied that the posterior surface of the uvula will be the wound surface. This prevents irritation in swallowing food and in breathing through the mouth.

Treatment.—In simple cases astringent remedies, as lozenges containing krameria, afford relief. The uvula may also be painted with astringent solutions of alum, tannic acid, or with adrenalin. In the

more pronounced cases amputation is indicated. In all cases the epipharynx and the mesopharynx (oropharynx) should be examined and the diseased conditions treated.

Fig. 228

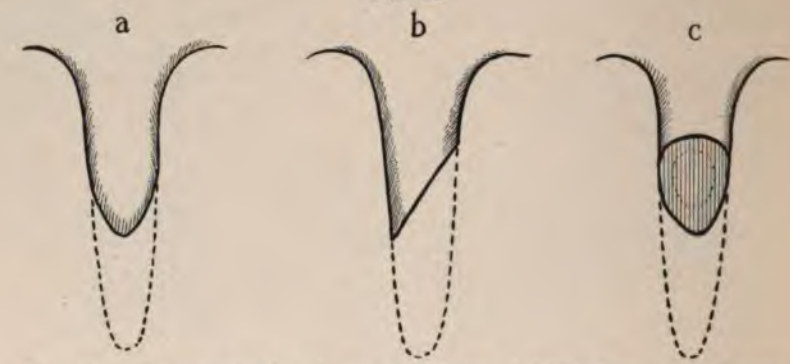

Three views of the amputated uvula. *a*, anterior view; *b*, lateral view; *c*, posterior view

Fig. 229

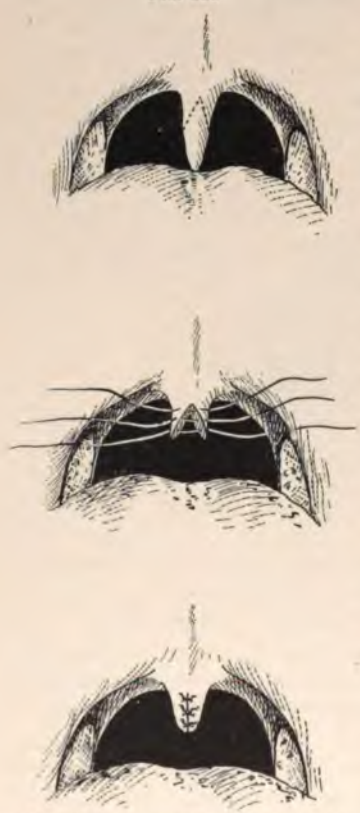

Casselberry's operation for elongated uvula.

Surgical Treatment. — (*a*) The uvula should be painted with a 10 per cent. solution of cocaine.

(*b*) The tip of the uvula is then seized with forceps and drawn directly forward.

(*c*) While in this position it should be operated with heavy blunt scissors, as shown in Fig. 227.

By cutting the uvula from in front while drawn anteriorly, the bevelled cut surface of the stump faces posteriorly. This is a point of practical importance, as in swallowing solid food the raw surface is not irritated by it (Fig. 228).

Casselberry's Operation.—Dr. Wm. E. Casselberry recommends the following technique in the amputation of the uvula:

(*a*) Secure anesthesia by painting the uvula with a 10 per cent. solution of cocaine.

(*b*) Seize the tip of the uvula with forceps and draw it directly forward.

(*c*) While in this position an upward and medianward cut is made with scissors to the central axis of the uvula. A similar cut is made on the opposite side, thus removing a wedge-shaped piece of the uvula, as shown in Fig. 229

(*d*) The anterior and posterior cut edges of the wound are then secured with two or three black silk sutures, black thread being used, because it is easier to locate at the time of its removal.

(*e*) The sutures should be removed at the end of three days.

The advantages claimed for this method of operating are that the cut surfaces are sealed and not liable to irritation from the ingested food, and to infection from ingested and inhaled pathogenic bacteria.

Hemorrhage has been reported after uvulotomy. This may be avoided by limiting the amputation to the portion of the uvula below its muscular fibers; that is, only the thin relaxed portion should be removed, as the bloodvessels of the uvula do not extend beyond the muscular fibers.

RETROPHARYNGEAL ABSCESS.

An abscess on the posterior wall of the pharynx may be acute or chronic, usually chronic. It may be situated in the mesopharynx, the hypopharynx, or the epipharynx.

Etiology.—There is an infection beneath the mucous membrane. The morbid germs gain entrance through the lymph vessels and have the atrum of invasion in one of the neighboring tissues which is diseased. Tonsillitis, a postoperative tonsillar wound, a tuberculous tonsil, tuberculous cervical glands, caries of the vertebra and syphilis of the throat may be the immediate predisposing causes. The author observed one case following the complete excision of the tonsil in an adult. Most of the chronic cases occur in tuberculous and strumous children. Postpharyngeal abscess is often associated with tuberculous glands of the neck. The glandular involvement is probably secondary to the pharyngeal abscess, or both may be secondary to a tuberculous affection of some other structure.

Symptoms.—The patient complains of painful deglutition, and, if the swelling is in the hypopharynx, of dyspnea, which may threaten life or even cause death. Cough is constantly present. The voice is similar to that present in quinsy. In acute abscess the temperature may be elevated from 1° to 2°, whereas in chronic abscess it is little altered.

Diagnosis.—The abscess should be differentiated from aneurysm, malformation of the vertebræ, and inflammatory swelling of the mucous membrane.

Aneurysm of an artery in this region has been mistakenly diagnosticated as retropharyngeal abscess, with fatal results following incision. The pulsation and bruit present in aneurysm should be sought for in all cases of suspected abscesses of the pharynx. The pulsation may be noted with the eye or finger, while the bruit may be distinguished with the stethoscope introduced through the mouth.

Malformation of the posterior wall of the pharynx, causing bulging of one side, is occasionally found. The hard, firm character of the mass readily distinguishes it from the soft baggy mass in abscess formation.

Acute infectious inflammations of the pharyngeal mucous membrane

sometimes simulates retropharyngeal abscess. The difference in the resistance upon digital examination will determine which of the processes is present.

Prognosis.—The danger in very young subjects is chiefly due to suffocation, and to strangulation upon the spontaneous rupture of the abscess. In older patients this danger is not so pronounced, as their reflexes enable them to ward off or anticipate these dangers. Under treatment the prognosis is nearly always good except when the disease is due to tuberculous caries of the vertebræ.

Fig. 230

The oral operation for retropharyngeal abscess. The finger is used as a guide to the fluctuating area and as a tongue depressor, while a short-bladed scalpel is used to open the abscess.

Treatment.—The main indication for treatment is the immediate evacuation of the pus. This may be accomplished by (*a*) the internal or (*b*) the external route. The internal operation should always be tried first, and followed by the injection of iodoform glycerin emulsion (Esmarch and Kowalzig). Should simple puncture and evacuation, followed by the injection of the iodoform emulsion, fail the external operation should be performed.

Technique.—*Internal Operation.*—(*a*) Place the patient upon a table with his head lowered, to prevent the larynx being bathed in pus. In children this precaution is especially urgent, as their reflexes are not sufficiently trained to prevent suction of the infected secretions into the trachea and lungs, where it might cause aspiration pneumonia.

(*b*) Introduce the left index finger into the mouth and place the tip against the soft fluctuating tumor.

(*c*) Introduce a short-bladed scalpel, or a longer one, the proximal end of which is wrapped with a strip of adhesive plaster or cotton into the mouth, using the introduced finger as a guide (Fig. 230).

(*d*) Incise the abscess wall by the side of the finger. The pus then flows through the incision into the pharyngeal cavity, from which it may be removed with moist gauze sponges grasped by artery forceps, or it may be expectorated by the patient.

(*e*) After all the pus has been thus removed, irrigate the cavity with warm boric acid solution and inject the iodoform glycerin emulsion into the wound. The injections may be repeated every day or two, and if steady improvement follows, a cure may be expected. If, however, improvement does not follow, the external operation should be performed.

Fig. 231

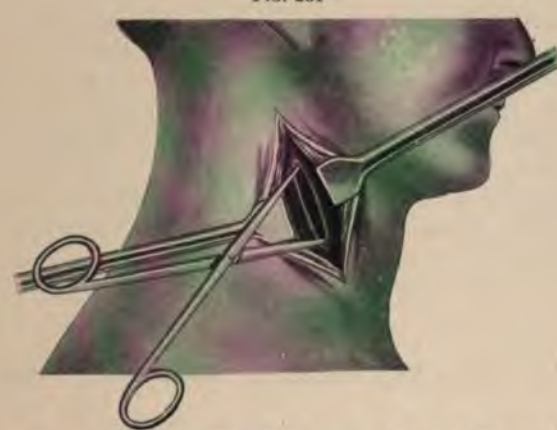

The external operation for retropharyngeal abscess. The fascia enclosing the abscess is punctured and opened with artery forceps.

External Operation.—Generally speaking, the external operation consists in making an excision either anterior or posterior to the sternomastoid muscle, and extending it inward by blunt dissection to the anterior wall of the vertebral column, where the abscess cavity is located.

If only the retropharyngeal abscess is to be included in the operation, the incision should be made posterior to the sternomastoid muscle; if, however, there are diseased cervical glands to be removed at the same time, the incision should be made anterior to the muscle (Fig. 231).

The following steps in the operation should be observed:

(*a*) The field of operation should be shaved and scrubbed.

(*b*) General anesthesia.

(*c*) An incision two or three inches long should be made through the skin over either the anterior or the posterior border of the sternomastoid muscle on a plane with the retropharyngeal abscess. The dissection should be continued until the deep cervical fascia is opened and the border of the sternomastoid muscle is brought to view.

(*d*) The sternomastoid muscle is then separated by blunt dissection from the adjacent tissues, and is drawn forward with a retractor to expose the operative field.

(*e*) Still using blunt dissection, the carotid sheath with its vessels and nerves is separated from the vertebra and carefully drawn forward.

(*f*) The dissection is carried in front of the vertebra to the abscess wall.

(*g*) The abscess wall is punctured with closed artery forceps; the forceps is then introduced into the cavity, the blades spread apart, and withdrawn from the cavity (Fig. 231). The abscess is thus freely opened and evacuated.

(*h*) Digital examination of the cavity should be made for necrosed bone, and to note the condition of the soft tissues and abscess contents. If the secretions are thick and caseous, they may be removed by gentle curettage.

(*i*) Irrigation with warm boric acid or the glycerin-iodoform solution completes the evacuation of the contents of the abscess.

(*j*) Introduce a spiral tube deep into the wound for drainage purposes. The tube may be withdrawn a little each day after the discharge has ceased, and abandoned altogether at the end of ten days or two weeks, after which the external wound closes by granulation.

If cervical glands are to be removed, or if the abscess points anteriorly to the sternomastoid muscle, the incision should be made anterior to the muscle. The group of glands involved should be removed *en masse*, as to leave some of them almost surely means a secondary operation.

MALFORMATIONS OF THE PHARYNX; STENOSIS OF THE PHARYNX.

Malformations of the pharynx may be either (1) congenital or (2) acquired.

Those of congenital origin may be in the form of an imperforate pharynx, from a failure in the embryological development of the anterior end of the foregut, and the invagination of the ectoderm, which forms the cavity of the mouth. The embryological structures in this region are very complex, and it is a wonder congenital malformations are not more frequent. Congenital malformation is usually in the form of a constriction or pouch, or of a complete closure.

Acquired malformations are due to inflammatory and degenerative changes in the walls of the pharynx. Syphilis is the most common cause. There is more or less destruction of the uvula and soft palate in the tertiary stage, followed by cicatricial contraction and adhesion to adjacent parts. The soft palate in these cases is usually adherent to the posterior wall of the pharynx, and may cause almost complete separation of the mesopharynx from the epipharynx. In Fig. 202 there is only a small opening the size of a lead pencil communicating with the epipharynx. The scars in syphilis are stellate in their arrangement, *i. e.*, they radiate from the site of the original ulceration. The inges-

tion of scalding fluid and caustic drugs may cause scar tissue and cicatricial contraction.

Treatment.—The treatment of syphilitic scar tissue and adhesions is attended by failure in the majority of cases. The scar tissue may be removed and the adhesions broken down, though they speedily reform and re-adhere. Obturators have been used in the isthmus between the mesopharynx and epipharynx, to keep the channel open and to prevent adhesions, with occasional success. The tendency for syphilitic scar tissue to reform in spite of all obstacles is the chief hindrance to the successful treatment of these cases.

CHAPTER XIX.

THE FUNCTIONAL NEUROSES OF THE PHARYNX.

Neuroses of Sensation.—The train of symptoms in pharyngeal neuroses of sensation is about the same as in the larynx, many of them being due to reciprocal lesions. (See Neuroses of the Larynx.)

Anesthesia of the pharynx is not of any great clinical significance, excepting, perhaps, when it accompanies progressive bulbar disease. Insane patients are apt to have it, even though no form of paralysis is present in the pharynx or elsewhere in the body. In cases of marked anesthesia involving the whole pharynx, the soft palate and larynx are usually likewise anesthetic. Diphtheria often causes it, and it sometimes accompanies the other exanthematous fevers. It may even be present in local inflammations of the pharyngeal mucosa.

(For treatment, see Anesthesia of the Larynx).

Hyperesthesia of the pharynx is the most frequent of the pharyngeal neuroses. It often occurs in those who are otherwise healthy. These cases do not tolerate the laryngoscopic mirror in throat examinations. They also resist the introduction of the Eustachian catheter. The most sensitive areas in the pharynx are the arch of the soft palate and the vault of the epipharynx.

Hypersensitiveness accompanies both acute and chronic inflammation of the pharynx. It is also a frequent manifestation of hysteria. It is more common in men, and especially fat men. Habitual smokers and drinkers are subject to it. It is but rarely a symptom of central brain disease. The hypersensitive areas sometimes appear on the tongue.

Paresthesia occurs about as frequently as anesthesia, and less frequently than hyperesthesia, and often baffles the skill of examiners and operators. Tonsillar disease is often the cause of it, hence these organs should be thoroughly examined for diseased conditions. The passage of a bolus of food or foreign body may cause an abrasion, which may be followed by the sense of a foreign body in the throat. The menopause is frequently attended by perverted sensations in the pharynx I have had patients at this period complain of the sensation of a rope or hairs in the throat. Hyperplasia of the lingual tonsil seems in some cases to cause it. The same is true of elongation of the uvula, though the elongated uvula is usually a sign of epipharyngitis, and the paresthesia may be due to the "dropping" from the epipharyngeal region. Granular pharyngitis, especially when it involves the lateral walls (pharyngitis hypertrophica lateralis), gives rise to an irritation between the posterior pillars and the pharyngeal wall, which is sometimes accompanied by paresthesia. It is occasionally associated with globus hystericus.

The perverted sensations complained of are cold, heat, a foreign body,

itching, tickling, and the dislocation of the essential parts of the fauces and pharynx. Patients sometimes complain of swallowing the soft palate, etc. Most of the female cases seen by me have suffered from melancholia during the menopause, and have had a suicidal tendency. One patient committed suicide by drowning some months after she passed from under my observation. The paresthesia may be so marked as to cause a distressing cough and laryngeal or esophageal spasm.

Neuralgia of the pharynx is difficult to differentiate from muscular rheumatism or neuralgia. Neuralgia is painful without pressure, while rheumatism is painful with and without pressure. Anemia and chlorosis are often the cause of neuralgia, whereas rheumatism is more often associated with plethora. Enlarged single pharyngeal follicles may become so painful as to simulate neuralgia. Localized pressure upon the follicles should cause pain and thus clear the diagnosis.

The treatment of neuralgia should be addressed to the cause when it can be determined, as well as to the relief of the pain. Iron, strychnine, arsenic, bitter tonics, and the regulation of the bowels should be the basis of the treatment in those cases in which anemia is the cause. In chlorosis enemata should be given to unload and cleanse the rectum and lower bowel, to stop the absorption of putrefactive material and bacteria into the circulatory system. Exercise in the open air and sunshine is of the greatest value in these cases. Patients should be encouraged to play golf or other outdoor sport, or to work in the flower or vegetable garden, or in the poultry yard. The outdoor exercise should have a constant and alluring motive, or it will soon be abandoned.

Neuroses of Motion.—Neuroses of motion of the pharyngeal muscles may, like those of the larynx, be divided into two general classes (Browne):

1. *Akinesis*, or paralysis, which may be unilateral or bilateral. The akinesis, or paralysis, may be still further subdivided into: (*a*) Paralysis due to bulbar disease (central paralysis). (*b*) Paralysis due to diphtheria (peripheral paralysis). (*c*) Paralysis due to or complicating faucial paralysis (central or peripheral paralysis). (*d*) Paralysis of the pharyngeal constrictors.

2. *Hyperkinesis*, or spasm.

Paralysis Due to Bulbar Disease; Central Paralysis.—The following central lesions may give rise to pharyngeal paralysis: acute and chronic bulbar myelitis, hemorrhage, tumors, embolism, and basilar meningitis.

Acute Bulbar Paralysis; Central Paralysis.—*Symptoms.*—In acute bulbar myelitis the symptoms develop rapidly, and the fatal end result is likewise rapid. The symptoms are as follows:

(*a*) Suddenness of attack.
(*b*) Severe headache.
(*c*) Dysphagia.
(*d*) Respiratory embarrassment.
(*e*) Difficulty in articulation.
(*f*) Giddiness.
(*g*) Unsteady gait.

Prognosis.—The prognosis is extremely grave.

Treatment.—While these cases are almost necessarily hopeless, they should be treated, for "while there is life there is hope." Bloodletting by cupping or leeches should be early and freely employed, to relieve the inflammatory process at the base of the brain. Ice should be applied to the pharynx and to the nape of the neck. The blood tension should be lowered by the administration of cathartics and such other remedies as are employed for spinal myelitis.

Chronic Bulbar Paralysis; Central Paralysis.—Undue exposure to cold, prolonged violent excitement, extreme fatigue, and lack of nutrition are etiological factors. Heredity seems also to largely influence its occurrence. It is more common in males, and is rarely observed before the age of thirty-five. In rare cases it may be due to an injury or to sunstroke. Syphilis and tuberculosis should also be included as causative agents.

Symptoms.—Pharyngeal paralysis may be the first symptom of progressive bulbar disease, though the tongue is usually the first organ affected. A typical case first involves the tongue, and is then followed by paralysis of the lips, the pharyngeal and laryngeal muscles. This order of involvement is almost always present. The paralysis, at first slight, gradually increases in severity.

Diagnosis.—In the beginning the disease may be mistaken for bilateral facial paralysis, though the history of a sudden onset, followed by progressive chronic paralysis of the tongue, pharynx, and larynx, together with the lips, should render the diagnosis of bulbar paralysis almost certain. In bilateral facial paralysis the tongue, pharynx, and larynx are not affected. In rare cases the tongue and fauces are not involved.

Prognosis.—The prognosis is usually fatal, though there may be remissions before death occurs. Patients often succumb to inanition or pneumonia.

Treatment.—Galvanism has been used to combat nerve degeneration and faradism to maintain the muscular vigor, with but little success. Strychnine is of value as a nerve tonic. In syphilitic cases the iodides are indicated.

Diphtheritic Paralysis; Peripheral Paralysis.—Paralysis of the pharyngeal muscles is often an early sequel of diphtheria and of pseudomembranous sore throat. The muscle fibers undergo more or less degeneration from the presence of the bacterial toxins, and there is a mechanical hindrance from the cellular infiltration of the tissues. In addition there is a degeneration of the peripheral nerve fibers from the same causes.

Symptoms.—The voice undergoes great changes on account of the paralysis of the pharyngeal muscles, as they are utilized in articulation and voice placement. The voice has the so-called "nasal quality," closely resembling that present in cleavage of the hard and soft palate. The velum and uvula are relaxed and can only be raised by forced inspiration. One side is usually more affected than the other, or it may be bilateral. The paralysis appears on or about the fifteenth day after convalescence, at which time ocular symptoms may also develop.

Treatment.—The prophylactic treatment consists in the administration of antitoxin during the diphtheria. After the paralysis has developed, galvanism, faradism, and rectal feeding should be adhered to in order to maintain muscular and nervous tone while the degenerated nerve fibers are being restored. Thick soups, grape juice, etc., may be given per rectum.

Paralysis of the Pharynx Complicating Facial Paralysis.—According to Ziemssen and Bouche, when the lesion is above the geniculate ganglion the pharynx is often associated with facial paralysis. The uvula does not move upon phonation and is deflected to one side. The symptoms are the same as those in diphtheritic paralysis, and include such structures as are supplied by the seventh nerve.

Paralysis of the constrictor muscles of the pharynx is always accompanied by paralysis of the esophagus. The dysphagia is, therefore, exceedingly well marked, and is often the only distinctive symptom.

Hyperkinesis, or Spasm of the Pharynx.—*Etiology.*—Spasm of the pharyngeal muscles of the pharynx is a rare affection. It may occur from insignificant causes, as uvulitis, foreign bodies, globus hystericus, enlarged pharyngeal follicles, neuralgia, and chronic and acute inflammations, or it may be an early symptom of a serious central lesion.

The more dangerous form of spasm of the pharynx is encountered in hydrophobia, edema of the glottis, brain tumors, paralysis agitans, and other nervous conditions.

Symptoms.—Chronic spasm of the pharynx involving the soft palate and uvula may be the chief symptom. The levator palati is the muscle affected. The spasm of this muscle draws the soft palate upward a number of times in rapid succession, after which it relaxes. During the spasm there is a clicking noise as the palate leaves the pharyngeal wall. The click is audible to those near by. Inspection shows the adhesion which upon being overcome causes the noise.

Prognosis.—The prognosis is fair in those cases due to simple causes, provided appropriate treatment is instituted. If due to a serious central lesion, hydrophobia, edema of the glottis, brain tumor, or paralysis agitans it is grave.

Treatment.—If the spasms are due to a foreign body, it should be removed. If due to local inflammations, appropriate remedies, elsewhere described, should be used. When due to saprophytic absorption from the rectum the lower bowel should be flushed by enemata, outdoor exercise advised, and a nutritious but unstimulating diet followed. When due to hydrophobia it should be treated rather than the spasms of the pharynx which are incidental to the disease. Stimulants of any sort should be avoided in all cases.

CHAPTER XX.

NEOPLASMS OF THE PHARYNX.

BENIGN NEOPLASMS.

(*a*) **Papillomata.**—Papillomata of the walls of the pharynx are rather rare, while they are common in the faucial region. Their favorite sites are upon the uvula, free borders of the pillars of the fauces, and the tonsils. The histological differences between the mucous membrane of the posterior wall of the pharynx and the mucosa of the uvula, pillars, and tonsils account for the sites elected. The posterior wall of the pharynx is covered by squamous epithelium, whereas the other structures are covered by columnar, and in many places by columnar ciliated epithelium. In spite of the varying structural differences, papillomata appear in all parts of the pharynx and fauces, though more frequently in the fauces.

They may be single or multiple, sessile or pedunculated. Behind the fauces, or in the pharynx proper, they are rarely pedunculated, and are chiefly limited to the ragged excrescences following syphilitic and lupus inflammations. Papillomata are composed of elevations of epithelial cells which contain a connective-tissue core more or less richly supplied with bloodvessels. The epithelial elevations grow outward, while in epitheliomata they grow inward. The elevations vary in size from a pinhead to tumors of considerable size. They often contain "pearls" or "nests," which may be mistaken for the nests or pearls of epitheliomata. The cells in papillomata are uniform, whereas in epitheliomata they are multiform. Papillomata are liable to become converted into epitheliomata of the malignant type, hence they should always be viewed with suspicion. They may be in the transitional stage when observed, though most of them are true papillomata with an outward growth of the epithelial elevations.

Primary papillomata are usually surrounded by an inflammatory area. Secondary papillomata are the result of a preëxisting inflammation, as in syphilis (Fig. 232).

The presence of a papillomatous growth in the fauces or pharynx often excites a cough reflex, with a sense of fulness and tickling in the throat.

Treatment.—The treatment of papillomata is usually so simple that a detailed description of the procedures need not be given. The tumor should be removed to its base with a knife, snare, cutting forceps, or cautery. The base of the growth should be removed or cauterized with solid silver or the galvanocautery. If this is not done they are apt to recur.

(*b*) **Teratomata.**—Lennox Browne says, "The connection between teratomata and cystomata is so intimate and their origin so obscure that it is expedient to describe them together." I shall not do this, but will attempt to characterize them as distinct pathological entities.

Teratomata are usually congenital and consist of tissue growths springing from two or three embryological germinal layers. They appear, therefore, most frequently in those regions where the various germinal layers are in close apposition (Browne). The pharynx, resulting practically from the junction of the neural and the dermal epiblasts with the hypoblasts of the foregut, is, therefore, a suitable location for the growth of teratomata. Bland-Sutton called attention to this fact in 1886.

The majority appear in the epipharynx, though quite a few recorded cases were in the meso- and hypopharynx. They were sometimes called "hairy pharyngeal polypi," as they are usually pedunculated cysts filled with hair and other histological structures.

Fig. 232

Author's case of follicular tonsillitis and syphilitic papilloma arising from the left supratonsillar fossa.

Conitzen reported 11 "hairy polypi," or teratomata, which were cystic and contained hair, cartilage, skin structure, and bone. The cysts are usually pedunculated, and may be attached to any part of the pharynx.

Treatment.—The treatment consists in the removal of the growth with the snare, knife, or cautery. Cauterizing the base seems to prevent recurrences.

(*c*) **Cystomata.**—They usually occur after the twentieth year of life, more often in middle and advanced age. They are usually retention cysts or mucoceles, due to the closure of the mouths of the pharyngeal follicles, either by inflammatory contraction, epithelial plugs, or by the flaccid folds of membrane in advanced life. The cysts contain a glairy fluid, though in some cases it is inspissated and much thickened. They are usually superficially located, though Raugi speaks of a submucous cyst occurring in the submucous tissue which was difficult to see, and which he thinks must occur much more often than is generally believed.

Cysts are usually sessile, and often give rise to the symptoms described under reflex neuroses, as asthma, migraine, etc.

Treatment.—The treatment consists in the enucleation of the cyst membrane, though thorough cauterization of the lining of the sac is usually followed by the obliteration of the tumor.

(*d*) **Lymphomata or Lymphadenomata.**—This variety of benign tumor is the most frequent growth in the pharynx. This is to be expected on account of the widely disseminated tonsillar tissue and the numerous lymphoidal vestiges. The matrix of the tumor is connective tissue, in the meshes of which are aggregated the lymphoid cells. The cell groups are often crowded together and vary greatly in size. They have a strong tendency to multiplicity, just as in lymphoidal tumors elsewhere. They may be attended by or even

follow mediastinal complications of a like nature (Villar). A single tumor, especially when pedunculated, at times offers some diagnostic difficulties. But when we take into consideration that the adjacent lymphatic glands in the neck are enlarged and soft, the tumor in the pharynx, though pedunculated, should be suspected to be lymphomatous.

(*e*) **Myxomata.**—Myxomata of the pharynx is exceedingly rare. Browne in his whole experience never saw a case. Closely allied to them, however, are the so-called mucoceles due to dilatations of the mucous glands. The mucoceles are important as they are readily recognized and are easily eradicated by excision or the actual cautery.

(*f*) **Fibromata.**—After lipomata, fibromata are next in order of frequency. The structural arrangement is often so like that of sarcomata it is difficult to differentiate them. The clinical history is, therefore, the guide in diagnosis. In very rare instances a myxomatous tumor may take on the tendencies and aspects of a fibroma, just as primary fibromata may become mucoid in character. Fibromata are rare in advanced age, but are quite common in young and middle adult life. This seems to be true of nearly all neoplasms springing from the mesoblast.

Fibromata may be either sessile or pedunculated, more often the latter. They are composed of densely packed spindle cells, with an undeveloped matrix of connective tissue. They are encapsulated, and do not often attain a large size. Bruns reports a case in which the entire fauces was filled by a fibroma. They are usually single and of slow growth. They have their origin in the fibrous tissue and the periosteum of any part of the pharynx. The covering of the basillar process of the occipital bone and body of the sphenoid are favorite sites. As the pterygoid plate of the sphenoid and the perpendicular plate of the palate bone, the posterior ends of the upper turbinated bodies, and the posterior portion of the vomer are all covered with fibrous tissue and periosteum fibromata usually arise from this region. Large fibromata are frequently attended by inflammatory processes, hence adhesions to the adjacent structures is common.

Etiology.—They are rare in females. Age is a decided factor in their occurrence, adolescence being the favorite period. As age advances there is a tendency for the growths to recede or undergo spontaneous cure. In this respect they resemble adenoids and other lymphatic enlargements.

Symptoms.—The early symptoms are those of epipharyngeal catarrh, with more or less hemorrhage. The bleeding sometimes becomes an alarming complication. The voice becomes "flat" or "dead" in quality and respiration and deglutition embarrassed as the process advances. Pain and mucopurulent discharge appear later on. When the growth has attained considerable size the "frog face" becomes well marked, the maxillary bones are separated, and exophthalmos becomes a prominent symptom. Aprosexia and drowsiness are often present. In one of the author's cases the patient often dropped into sleep or slight stupor while in the treatment chair. Greville Macdonald reports vomiting as an annoying symptom.

If the growth extends upward it may encroach upon the cranial contents and give rise to central symptoms, as paralysis, etc., followed in nearly every instance by death.

The foregoing symptoms increase in severity as the growth extends, until the absorption of bony tissue is considerable, unless the tumor extends beyond the nasal and pharyngeal chambers, as into the cranial cavity. In this event the pressure necrosis of the bony tissue is not so great.

Examination shows the tumor to be a rounded mass, of a pinkish or dark purple color. The veins are frequently varicosed, hence the examination by digital or instrumental aids should be done carefully, so as to avoid injuring them. The growth may project into the posterior nares, or its direction may be toward the antrum and other sinuses. Under finger pressure it is firm and elastic, and if small its base may be outlined. If pedunculated, it is movable, unless it has become fixed by inflammatory adhesions. If it extends through the sphenomaxillary fissure it may be felt under the zygoma. As adhesions are usually present, its outline is difficult to make out.

Diagnosis.—The histological resemblance to sarcoma is often so close that a differentiation is difficult, unless the age, sex, and origin are such as to point to its fibrous nature. Sarcoma is rarely or never pedunculated, whereas fibroma is frequently pedunculated.

Prognosis.—The prognosis is favorable in proportion to its early recognition and extirpation. It is also favorable as the age of the patient exceeds twenty-five years. In other words, small fibromata which do not fill the epipharyngeal space are more favorable under operative treatment than those which completely fill it. The tendency of the growth to undergo retrograde changes after the twenty-fifth year accounts for the more favorable prognosis in those cases appearing after this period.

Some cases even undergo spontaneous recovery. It is advisable in nearly all cases to remove the growth by surgical interference, as it is too great a risk to wait for a spontaneous cure. An additional reason for operating is to relieve the patient as speedily as possible of the intense pain and other distressing symptoms characteristic of these growths.

Treatment.—Small growths, especially if they are pedunculated, and those limited to the epipharyngeal space may be removed with a heavy snare or ecraseur, either through the nose or mouth. The galvanocautery snare may even be used through these routes. When the growth is large and sessile, and has extensive inflammatory adhesions to the adjacent structures, it is necessary to perform an external or more radical operation. (See Operations for Fibroma of the Nose.)

(*g*) **Lipomata.**—Lipomata of the pharynx are rare. When they occur they are usually small and sessile, especially when they spring from dense tissue. When they spring from loose tissue they may attain large size, and are apt to be pedunculated and multiple. They are oval, smooth, and elastic, hence are sometimes mistaken for retropharyngeal abscess. A puncture readily clears the diagnosis on this point. They usually occur

in advanced age. Lennox Browne says that the sessile and deeply seated ones are more often congenital than otherwise.

(*h*) **Angiomata.**—Because of Cruveilhier's submucous plexus, situated at the back of the pharynx, and the rather rich blood supply, both superficial and deep, we might naturally expect many angiomata. But, on the contrary, they are of rare occurrence. Moritz Schmidt does not cite a case in his excellent review of the tumors of the upper respiratory tract. Guyon cites one patient in whom digital examination caused profuse hemorrhage. Electrolysis checked the hemorrhage, and subsequently caused an atrophy of the growth. Angiomata of the pharynx, like similar growths elsewhere, are usually cavernous and often erectile in character. Farlow reports five cases of enlarged pulsating arteries in the pharynx. The red-currant-like clusters are, strictly speaking, angiomatous.

Treatment.—Most observers favor non-interference unless they bleed. There is some risk attending this attitude, as a serious hemorrhage may occur at any time. If large, they should be deprived of their arterial blood supply by ligatures applied to the efferent vessels supplying the tumor. If small, they may be treated by electrolysis or by ligation.

Electrolysis is performed as follows: (*a*) Anesthetize with local applications of a 10 per cent. solution of cocaine.

(*b*) Introduce the needles, connected with the positive pole of the galvanic battery, into the growth.

(*c*) Turn on from 10 to 25 ma. of current for five minutes. Repeat the seances at intervals of about seven days until the growth is obliterated.

The positive pole of the battery liberates nascent oxygen and coagulates the tissue, hence it should be the pole applied to a soft growth. If it is desired to reduce a hard or fibrous tumor, the negative pole is applied to the growth, as it liberates hydrogen, which softens the tissue.

Ligation or strangulation may be performed as follows: (*a*) Anesthetize by the local applications of a 10 per cent. solution of cocaine.

(*b*) Pass a ligature through the tissues, including an artery at the margin of the angioma, and tie it.

(*c*) Continue to thus tie off the larger vessels until the nutrient sources are closed.

(*d*) After three or four days the ligatures should be removed. A corkscrew cleft palate needle is well adapted to the introduction of the sutures.

MALIGNANT NEOPLASMS OF THE PHARYNX.

General Pathology.—Clinically it is an advantage to make a distinct demarcation between the fauces and the pharynx in treating of malignant growths. However, as is well known, their tendency to spread by continuity of tissue and by metastasis, and their insidious beginning, does not permit of an ironclad anatomical division. Oftentimes they originate on the borderland between the two regions. It should be borne in mind that when these tumors spring from the larynx they are prone to extend to the pharynx, but that those arising from the pharynx

seldom, if ever, extend downward to the larynx. Even those occurring in the hypopharynx have an upward rather than a downward tendency. This is explained in part by the difference in the tissues composing the two parts. In the larynx there is little soft tissue, and the glandular element is less, whereas in the pharynx the soft tissues and lymph glands are more abundant.

Embryologically the pharynx and the larynx have different origins, and the tendency to extension is thereby somewhat impeded.

The general symptoms are much the same as in cancer of the larynx. The special symptoms are dependent upon the anatomical and physiological differences in the two regions.

The lower portion of the pharynx is more often the seat of malignancy than the upper. Men are more often affected than women. Carcinomata here, as elsewhere, are more frequent in the old. This is in obedience to the physiological law, that mesoblastic structures are more active in the young, while the epi- and hypoblastic structures are more active in the old. An effort is made by some writers to differentiate between the malignancy of sarcoma and carcinoma. This is of no practical or clinical value, as either is usually the cause of death in whomsoever it occurs. True carcinoma, because of its glandular structure, more readily involves contiguous structures, and more frequently extends by metastasis.

Carcinoma of the pharynx is more frequent than sarcoma. The former are more apt to involve the glandular structures, subjected as they are to persistent irritation, especially in the pharynx. Sarcoma may, however, be due to traumatism.

It is often difficult to differentiate profuse scar tissue from sarcoma, as both are closely allied to embryonal tissue. The clinical phenomena are, therefore, often more reliable than the microscopic findings.

Varieties of Sarcoma.—The various types of sarcoma which have made their appearance in the pharynx in their order of frequency are:

1. Round-cell sarcoma.
2. Spindle-cell sarcoma.
3. Myxosarcoma.
4. Lymphosarcoma.

1. **Round-cell Sarcoma.**—The round-cell sarcomata are of two types, (*a*) large round-cell sarcoma, and (*b*) small round-cell sarcoma. Their structure is characterized by an aggregation of cells, intercellular cement, and numerous bloodvessels. Occasionally a few fibrous trabeculæ are distributed through the mass of cells. Lymph channels are also found in the cellular masses. The cells vary considerably according to their age and original site of growth. The older part of the tumor is in a state of degeneration, while the newer part is intact. The small round-cell sarcoma is softer than the large round-cell growth, which has more intercellular cement substance. The cells of the large round-cell sarcoma often have oval nuclei, and are the most malignant of all the sarcoma. Its local ravages are extensive and the constitutional manifestations are pronounced.

2. **Spindle-cell Sarcoma.**—This, like the round-cell variety, is divided into two classes, (*a*) small spindle-cell sarcoma, and (*b*) large spindle-cell sarcoma. The general structure of this variety is quite like the round-cell sarcoma, except the cells are often arranged in bundles. Lymph spaces are absent, whereas they are present in the round-cell variety. The vascular supply is accordingly greater than in the round-cell variety. Many spindle-cell sarcomata have a tendency to undergo degeneration in patches, and are less malignant than the round-cell variety. The spindle-cell sarcoma more often occurs in adults, while the round-cell variety is more often present in the young. The spindle-cell sarcoma develops slower than the round, is firmer, and less apt to ulcerate. It may be pedunculated, while the round-cell variety is seldom or never pedunculated. They are encapsulated and "shell out," while the round cell is not encapsulated.

The local malignancy is greater than in the round-cell variety while the general malignancy is not so great. The spindle-cell sarcoma usually springs from the posterior wall of the pharynx, though it may arise from the lateral wall.

3. **Myxosarcoma.**—The myxosarcoma is originally either spindle- or round-cell, which, having undergone an early mucoid change is converted into the myxomatous type. They are locally malignant, rather than constitutionally; that is, they have a tendency to recur, but seldom give rise to metastasis. They arise by preference in the loose cellular tissue of the lateral walls of the pharynx, though they may occur in the fauces and the glosso-epiglottic fold.

4. **Lymphosarcoma.**—Lymphosarcoma is a variety of round-cell sarcoma. They possess a very delicate reticulum, giving them the appearance of a lymphoid structure. They usually orig nate in the lymphoid tissue of the pharynx, which is, perhaps, another reason for their resemblance to normal lymphoid or adenoid tissue. When the growth is traversed by numerous fibrous connective-tissue bands it is more dense in structure. It is necessary to differentiate this neoplasm from benign hyperplasia and lymphoma, which are directly due to inflammatory processes.

Lymphosarcoma grows rapidly, and when removed invariably recurs. They usually involve everything in their course, especially that type which starts in the lymphatic glands. Pharyngeal lymphosarcomata are quite often observed in Hodgkin's disease, which is a true lymphosarcoma.

TRYPSIN TREATMENT OF MALIGNANT NEOPLASMS.

The trypsin treatment of malignant neoplasms is based upon the statistical findings of von Bergman, wherein he states (1) "that cancer of the stomach stops abruptly at the pylorus; (2) that the small intestine is but rarely the site of cancer; and (3) that cancer of the large intestine and rectum for the most part increases in frequency the farther the

distance from the duodenum. In 10,537 cases of cancer of the alimentary tract the stomach was involved 4288 times, the small intestine 20, the large intestine 224, and the rectum 1204 times. The natural and comparative immunity of the duodenum and small intestine, together with the slower rate of growth of cancer of the large intestine, would, therefore, appear to support the treatment of inoperable cancer by preparations of the pancreas, bile salts, intestinal gland extracts, and ferments alone or combined. In November, 1905, Dr. Wade, at the solicitation of Dr. F. Beard, began experiments, first, to determine the action of trypsin upon the living cells of carcinoma, such as Jensen's mouse tumor (an adenocarcinoma); second, to test the truth of the conclusion advanced by Beard in 1902 that cancer was an irresponsible trophoblast; and third, the length of treatment and number of injections of trypsin necessary to destroy the tumor" (James T. Campbell).

The results were such as to appear to show that the trypsin caused a degeneration of the cancer cells, a shrinkage of the tumor, and an improved condition of the system in general. Since then several cases of cancer in the human body have been reported wherein trypsin caused apparent shrinkage of the growth, a cessation of the pain, marked gain in weight, and great improvement in the health of the patients. It appears, however, that the improvement is but temporary, in some of the cases, a recrudescence of the neoplasm occurring later, with a rapid fatal termination. It is too soon to accurately judge the merits of the trypsin treatment. It is, however, worth the trial in inoperable cases. An operable case should always be operated in a most thorough manner. Delay and partial removal by operation are dangerous procedures. An early operation and complete removal offer the best chance of a cure. The operation may be followed by the trypsin treatment.

Technique of Trypsin Treatment.—The trypsin comes in sealed ampoules, of 20 minims each, of a glycerin extract prepared from the pancreatic glands, and with such a proportion of the ingredients of the normal salt solution that when diluted with two volumns of sterilized distilled water the medium corresponds in this respect to the normal salt solution; greater dilution may be employed if desired.

At first 5 minims of the trypsin solution diluted with 10 minims of sterilized distilled water should be injected through the skin of the buttocks deep into the subcutaneous tissue, but not into the muscles. The injections may be given every other day, gradually increasing the dose to 10 minims.

The skin should be scrubbed with soap and alcohol, and in sensitive patients $\frac{1}{10}$ grain of eucaine may be injected a few minutes before the injection of the trypsin.

Some writers recommend the administration of holadin in 3 grain capsules three times a day during the trypsin injections. Holadin is an extract of the entire pancreas gland, containing all the constituents of the digestive and the internal secretions of the gland.

THE EXCISION OF THE EXTERNAL CAROTID ARTERY AND ITS BRANCHES FOR INOPERABLE CANCER OF THE UPPER RESPIRATORY TRACT.

The excision of both external carotid arteries and their eight branches may be performed for the purpose of depriving inoperable malignant growths of the nose and pharynx of their blood supply, thereby starving the growths. Malignant tumors require a large blood supply, hence this operation seems to offer some degree of hope. Dawbarn reports encouraging results in a number of cases of inoperable cancer of the head. The operation should never be performed when the growth can be successfully extirpated. The ligation of the external carotids and their branches should be adopted as a last resort. While it may not cure the case it may prolong life.

The technique of the operation may be studied under the following heads:

The Position of the Head.—The shoulders should be placed upon a block or sand cushion, the chin well elevated and everted to the opposite side, so as to expose the region of operation to free access.

The Incision.—The incision should extend from the tip of the mastoid process close behind the angle of the jaw to the level of the middle of the larynx. At either extremity the incision is exactly over the external carotid artery. Dawbarn recommends that the incision be curved medianward about 1.5 cm., as the safety of the operation lies anterior to the artery, while danger lies posterior to it.

Exposure of the Artery.—Work from below upward, first exposing the superior thyroid, which extends downward to the thyroid gland. By tracing this back to the carotid the external is distinguished from the internal. Pass a chromicized catgut loosely around the external carotid. Examine the carotid and be sure that it bifurcates into the external and internal branches. If it does not it should not be ligated, as the blood supply to the brain would be cut off and death result.

If it does not bifurcate into the external and internal branches, only the branches supplying the external portions of the head should be ligated, the carotid being untied. Having determined that the common carotid bifurcates as usual, continue the dissection upward, exposing each branch and tying it in two places and dividing it. The dissection is thus continued upward until the level of the twelfth cranial nerve is reached, and all the branches of the artery but the terminal two have been controlled. The superficial carotid is itself tied twice and divided between. The ligature placed loosely around the external carotid below the superior thyroid branch should not be tied. It should not be tied sooner because the artery would collapse and render the dissection difficult. The ligature is placed in position early, ready for use in case of accidental hemorrhage in the course of the dissection higher up (Dawbarn). The upper portion of the artery should be dissected as it passes under the transverse loop of the twelfth nerve and the conjoined stylohyoid and

posterior belly of the diagastric and on into the substance of the parotid gland. It should be followed to its bifurcation when possible. The dissection should be done with a dissecting forceps or scissors and not with a sharp knife, as it might divide some of the lower branches of the pes anserinus and cause facial paralysis, or else, by cutting through some of the smaller ducts of the parotid gland, cause a salivary fistula (Dawbarn). Use gentle downward traction during the blunt dissection, and when as high as possible seize the artery with an artery forceps and tie above it as high up as possible and sever the artery below the forceps.

Close the wound by sutures, leaving a rubber-tissue drain at its lower angle, or make a counteropening an inch and a half below the angle and insert the drain through this, entirely closing the original wound.

At the end of five or six days the drain can be discontinued and the counteropening allowed to heal by granulation.

Structures to be avoided: The internal jugular, internal carotid, pneumogastric, the superior laryngeal nerve, the pharyngeal branch of the pneumogastric, and the glossopharyngeal nerve. They all lie behind and deeper than the external carotid artery. Careful dissection should be done.

The opposite carotid should be operated in like manner after an interval of ten days, though both may be done at one time if the patient is vigorous.

CHAPTER XXI.

DISEASES OF THE FAUCES AND TONSILS.

THE TONSILS AS PORTALS OF INFECTION.

SINCE Strassmann reported 13 cases of tuberculous tonsils in 21 tuberculous cadavers the tonsils have commanded considerable attention as channels of infection. The opinions of various observers since then have differed somewhat, especially in reference to the tuberculous process in the tonsils. There has been but little questioning of the fact, however, that the tonsils are portals of systemic and glandular infection. There is not, after all, a great divergence of opinion as to the tonsils being a much used highway of pathogenic infection, the seeming difference being more a question as to certain details, rather than as to the general proposition itself. For example, some observers have failed to find tubercle bacilli, or the characteristic tuberculous changes in the tissue of the tonsils, which have been reported by other writers. Notwithstanding this, practically all writers agree that various pathogenic organisms do gain an entrance to the deeper tissue of the tonsils, the lymphatic glands, the lungs, the heart, and, indeed, to the whole system.

In view of the growing interest and the exact information on this subject, the tonsils have gained a prominence in medical literature they did not have a quarter of a century ago. A brief *resume* of the current thought held on this subject will, therefore, be given in connection with a study of the diseases of these organs.

In reference to *primary tuberculosis* of the tonsils, there is a divergence of opinion, some holding that the tuberculous process in these glands is direct, while others contend that the infection reaches them from the lungs through the lymphatics and the bloodvessels, or by the flow of the bronchial secretions over them. Both views are probably correct in selected cases. It is probable, however, that tuberculous infection of the cervical lymphatics glands is usually due to the entrance of the bacilli and other microörganisms thorough the tonsils. This is borne out clinically by the fact that suppurating or tuberculous glands of the neck are rarely found in phthisical patients. Whereas, if they occurred secondarily to pulmonary infection they would be frequently found in such patients.

That a latent tuberculous process may exist in the tonsils or in adenoids without presenting distinctive clinical signs thereof is suggested by the reports of a few cases in which a fatal pulmonary tuberculosis followed the removal of tonsils and adenoids. Friedrich suggests that the removal of the tonsils may have excited a recrudescence of a latent tuberculous

tonsillitis in these cases. It seems to me that these cases point strongly to the conclusion that there is such a condition as latent tuberculosis of the tonsillar ring, which may continually infect the lymphatic glands of the neck, as well as the deeper structures in the thoracic cavity. Latent tuberculosis of the tonsils is not *per se* a serious menace to the health or the life of the patient, but the danger arises from the extension of the infection to the contiguous organs.

The experiments of Dieulafoy show that of 96 guinea pigs inoculated with pieces of tonsils and adenoids, 15 developed tuberculosis. While these experiments are not conclusive in their scope or character, they are, nevertheless, suggestive. We know that tubercle bacilli are found on healthy mucous membranes, and it is possible, though not probable, that in these experiments the infection may have come from the accidental presence of surface bacilli. If it is admitted that the germs giving rise to the guinea-pig infection were within the tonsillar epithelial covering, we practically admit the major proposition, namely, that the tonsils are, or may become under favorable conditions, the portals of systemic or circumscribed infections in the contiguous glands and organs. In many instances it is also shown by the caseation or the suppuration which takes place in the tonsils. That there is not a close functional connection between the cervical and the pulmonary lymphatic glands appears clinically in the rarity of the extension of the tuberculous infection from the cervical lymphatics to the lungs.

The facility with which the invasion of pathogenic microörganisms is accomplished through the tonsils depends upon the following factors:

(*a*) The virulency of the invading microörganisms.

(*b*) The pathogenicity of the microörganisms.

(*c*) The general health of the patient.

(*d*) The existence or the absence of the strumous diathesis.

(*e*) The condition of the epithelium of the mucous membrane covering the tonsillar crypts, and the condition of the tonsillar tissue.

Piera has shown that bacteria are much more readily absorbed by the tonsils than is the coloring matter with which Goodale experimented. The germs pass into the interior of the tonsil, while the coloring matter is absorbed in the clefts of the lacunar epithelium. He also found that the pathogenic germs were more readily absorbed than the non-pathogenic, and that healthy tonsils absorb better than the fibrous. He does not intend to convey the idea, however, that healthy tonsils are a menace to the system, for, on the contrary, they are protective in function. While the healthy tonsil readily absorbs the pathogenic germs, it also has the power of destroying them.

It has been thought that the tonsils are vestigial organs which once had a function that is now more or less obsolete. Packard has called attention to the fact that tonsils have been traced in the lower animals from the reptiles up to man; and that they are more complex in man, and cannot, therefore, be said to be vestiges. In this connection Watson Williams says: "But if the tonsils are in some measure a protection against the invasion of microörganisms, their protective power is limited,

and once this limit is passed they are a positive source of danger. The crypts and the fissures of the tonsils may become 'traps' for microbes, and the peculiar anatomical arrangement of their investing epithelium, described by Stöhr, opens the gates to their invasion into the tissues of the tonsil, whence through the lymphatic channels and vessels they may gain an entrance into the system; such systemic invasion by pathogenic microörganisms frequently occurs."

Williams also refers to the researches by von Babes, wherein he proves that in pulmonary gangrene the infection may enter through the tonsils as well as through the bronchi. He also says, "Primary tuberculosis of the tonsils is less rare than is generally believed, and the failure of the faucial tonsils to arrest the development of the bacilli results in tuberculosis of the cervical glands, so commonly observed in weakly children."

Having thus referred to the tonsils as the atrium of infection for pathogenic microörganisms in general, and the tubercle bacillus in particular, it remains to be said that it has long been thought that rheumatic fever has its origin in infection through the tonsils. Clinical observation certainly supports this view, as acute articular rheumatism is commonly observed following an attack of acute tonsillitis.

Dawson advances the ingenious theory that scarlet fever has its primary lesion in the tonsils. Whether or not this view will be supported by future observations remains to be seen. It has been shown by Kocher that acute suppurative osteomyelitis may be due to an infection by the same route.

Acute tonsillitis is due to a local infection from streptococci and staphylococci, which are almost constantly present in the crypts of the tonsils.

Wright and Walsham have failed to find the tuberculous process in removed tonsils, but this does not necessarily prove that they are not pathways of infection. I have already pointed out the fact that the tuberculous infection may exist in a latent form; that is, the bacilli may be present within the tonsillar follicles without giving rise to distinct histological changes. By the term follicle is not meant the crypts or lacunæ, but the lymphoid nodule.

The *lines of defence* against microbic invasions through the upper respiratory tract may be classified as follows:

(*a*) The mucous secretions are regarded as having in some degree bactericidal properties.

(*b*) The epithelial covering of the mucous membrane of the upper respiratory tract offers a mechanical barrier.

(*c*) The lymphatic tissue composing Waldeyer's ring (tonsillar ring).

(*d*) The cervical lymphatic glands.

(*e*) The bronchial lymphatic glands.

(*f*) The endothelial lining of the bloodvessels.

(*g*) The endothelial lining of the lymph vessels.

(*h*) The serum of the circulating blood.

(*i*) The leukocytes.

It will be seen by the foregoing that the system is pretty well guarded against the invasion of pathogenic microörganisms. Should the first

or the second barrier be overcome, the remaining ones are still ready to bar the further progress of the morbific bacteria.

In tuberculous infection of the cervical lymphatic glands the germs excite the reaction of inflammation, as shown by the enlargement of the glands. Under favorable conditions they are harmless on account of the phagocytic action of the leukocytes, which Stöhr has shown are thrown out from the clefts in the epithelial covering of the crypts.

Acute endocarditis, septic thrombophlebitis, and pyemic infarcts of the lungs have also been shown to be due to the absorption of microörganisms through the lymphatic ring.

Recapitulation.—(*a*) Tuberculous tonsils have been found in subjects which died from tuberculosis.

(*b*) Some observers have failed to find the tuberculous process in tonsils and adenoids removed from living patients, while others have been able to demonstrate it.

(*c*) Primary tuberculosis of the tonsils, while not common, cannot be said to be rare.

(*d*) Secondary tuberculosis of the tonsils has been demonstrated.

(*e*) Latent tuberculosis may exist in tonsils and adenoids without presenting distinctive clinical signs.

(*f*) The removal of tonsils and adenoids is sometimes followed by pulmonary tuberculosis.

(*g*) There are several barriers to the invasion of pathogenic microorganisms into the system.

(*h*) The invasion of the pathogenic microörganisms is favored by the virulency of the germ, and by certain local and constitutional conditions.

(*i*) The tonsil is a barrier against the invasion of microörganisms, and its power in this capacity is limited by the age of the patient and the condition of the tonsil.

(*j*) Rheumatic fever, acute endocarditis, septic thrombophlebitis, pulmonary gangrene, and other infective conditions have their initial lesions in the tonsils.

Practical Applications.—In view of the facility with which microorganisms, especially of the pathogenic type, gain entrance into the system through the tonsils, it becomes necessary under certain conditions to remove the tonsils in their entirety

I have seen cases in which repeated attacks of acute follicular tonsillitis and concurrent cervical lymphadenitis had taken place. After tonsillectomy, *i. e.*, the complete removal of the tonsils, the tonsillitis necessarily ceased to recur, and there was no further recurrence of the lymphadenitis. It may be logically concluded that the tonsils acted as a permanent incubator for the streptococci and the staphylococci, and the incubator being removed, the cervical lymphadenitis disappeared.

When the latent tuberculous process is present in the tonsils, the cervical glands are infected and give rise to the repeated enlargement and caseous degeneration of the glands. After the complete ablation of the tonsils, including the capsule, great improvement of the glandular disease should occur. While it may not always be advisable to perform

tonsillectomy, it is usually well to do so in those cases with enlarged cervical glands.

It is also advisable to perform complete ablation when there is an active tuberculous process in the tonsils with an incipient involvement of the lungs. I have removed tonsils in this condition with the most satisfactory results.

Singers and public speakers with a troublesome subacute laryngitis, and whose tonsils are small and fibrous, or enlarged, may be benefited by the complete ablation of the tonsils, ther by relieving a possible source of irritation of the larynx through the absorpt on of microörganisms and septic matter.

THE CLINICAL ANATOMY OF THE TONSIL.

The tonsil (Fig. 233) is situated in the sinus tonsillaris between the faucial pillars, and has its origin in an invagination of the hypoblast at this point Later the depression thus formed is subdivided into several compartments which become the permanent crypts of the tonsil. Lymphoid tissue is deposited around the crypts, and thus the tonsillar mass is built up. The inner or exposed surface including the cryptic depressions, is covered with mucous membrane, while the outer or hidden surface is covered by a fibrous capsule.

According to Landois and Stirling, the development of the palatal tonsil is most easily studied in the rabbit, where the single primary crypt generally remains without branches through life, and there the tonsil first appears in embryos $\frac{5}{8}$ inch long (occipitosacral measurement), or of about twelve days as a shallow epithelial fold whose apex points directly backward into the connective tissue concentrically condensed around the pharynx. At this stage there is no infiltration of the leukocytes in the connective tissue around the crypt, and it is not until the embryos are about twenty-one days old ($1\frac{3}{16}$ inches long) that the leukocyte infiltration becomes evident. The crypt has then become much deeper and broader, and by its ingrowth has produced a condensation of the connective tissues at right angles to the original peripharyngeal condensation, as well as a great increase in the number of capillary bloodvessels. From this stage the elongation of the crypt, the condensation of the connective tissue, the increase in the number of bloodvessels and in the amount of leukocyte infiltration go on *pari passu* until the adult condition is reached. As soon as the leukocytes appear in number in the submucous tissue they proceed to wander through the epithelium, as Stöhr has described.

In the fetus of the pig the condensation of the connective tissue, especially at the apex of the tonsillar crypts, and the consequent massing of leukocytes, mainly at these points, is particularly well shown.

In the human fetus the process is the same, though complicated by the early ramification of the original epithelial crypt and the appearance of fresh ones. The crypts become so deep that the cells from the surface

layers of their epithelium cannot at once be thrown off into the mouth, and remain as a concentrically arranged mass of degenerated cornified cells filling up the lumen of the crypt; this mass is ultimately forced out by the *vis a tergo* of the leukocytes emigrating through the epithelium. It will at once be seen how closely this resembles the formation of the concentric corpuscles of the thymus. The tonsils are preserved from the face of the epithelial thymus by retaining their lumen.

The prime factor in the formation of the tonsils is the epithelial ingrowth, which partly mechanically compresses the meshes of the connective tissue, and partly causes proliferation of the connective cells and vessels by the slight irritation it produces, thereby making it easier for the leukocytes to escape from the thin-walled capillaries and veno-capillaries so formed, and, when they have escaped, causing them to be detained in the finely meshed connective tissue longer than in other situations. As the leukocytes are well supplied with nutriment, they divide by mitosis here in large numbers, as Flemming and his pupils first showed, and at a late stage in development (with great variations in individuals) "germ centres" are formed, where a special arrangement of connective tissue and vessels favors the process of division.

The lingual and pharyngeal tonsils develop in the same way as the palatal. His shows that all the tonsils arise behind the membrana pharyngis, and, consequently, all these epithelial ingrowths pass into connective tissue already condensed around the primitive alimentary canal (G. L. Gulland).

It will be observed that the tonsil is an encapsulated organ, and that it is characterized by from eight to twenty crypts or tubular depressions. Many practitioners have confused the tonsil with the follicular tissue immediately surrounding it. So long as they were able to remove follicular tissue through the wound in the sinus tonsillaris, they thought they were removing tonsillar tissue. In this they were mistaken, as the lymphoid tissue immediately surrounding the tonsil is not encapsulated, nor is it characterized by cryptic depressions.

The tonsil does not always completely fill the sinus tonsillaris, the unoccupied space above it being known as the supratonsillar fossa, into which several crypts usually open.

The outer aspect of the tonsil is loosely attached to the superior constrictor muscle of the pharynx, thus subjecting it to compression with every act of deglutition. The palatoglossus and palatopharyngeus muscles of the pillars also compress the tonsil. Grober cites authorities who claim that the compression of the muscles forces food and bacteria into the crypts.

The Crypts.—The crypts are usually tubular and almost invariably extend the entire depth of the tonsil to the capsule on its outer surface. Some, however, are compound, *i. e.*, they divide below the surface into two or more tubules. They are usually comparatively straight, though they may be tortuous in their course. I have examined many tonsils removed with the capsule intact, and have rarely found crypts that did not extend through the follicular tissue to the capsule. Those opening

in the supratonsillar fossa usually extend downward and outward, whereas in the lower portion of the tonsil their direction is outward. The area occupied by the mouths of the supratonsillar crypts constitutes, according to Killian, the hilus of the tonsil. Clinically, the crypts seem to be the source of the greatest amount of local and constitutional disturbances, as they often become filled with food, tissue debris, and bacteria. This is especially true of those capped over by an overlying membrane, as in the supratonsillar space, and the antero-inferior portion of the tonsil which is covered by the plica triangularis. The plica supratonsillaris (Fig. 233) does not, in all cases, enfold the hilus, or supratonsillar crypts, as the tonsil often fails to fill the supratonsillar space. In other instances it closely hugs the upper end of the tonsil, thereby completely closing the mouths of these crypts. It is in these cases, particularly, that the contents of the crypts are retained. This is also true in reference to those covered by the plica triangularis.

FIG. 233

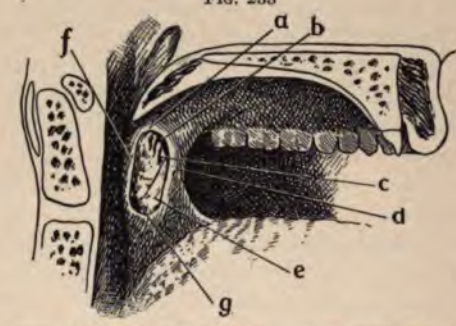

The anatomical landmarks of the tonsillar region. *a*, margosupratonsillaris; *b*, the supratonsillar fossa; *c*, hilum of the tonsil, the slit-like crypts of the tonsil in the supratonsillar fossa; *d*, anterior pillar of the fauces; *e*, plicatonsillaris (hyperculum plicatriangularis); *f*, posterior pillar of the fauces; *g*, a large crypt near the base of the posterior pillar, which often becomes closed, and gives rise to infection and inflammation.

Reasoning from a mechanical point of view, one would reach the conclusion that the retention of the infected secretions must necessarily give rise to infectious inflammatory processes. Clinically, we know that this is not true. The crypts are often found filled with food, tissue debris, and pathogenic bacteria, without any appreciable inflammatory reaction. Nevertheless, as I shall exemplify later, the mechanical closure of the crypts by the plica supratonsillaris and the plica triangularis adds greatly to the tendency to inflammatory and other morbid local and general processes.

It may be stated as a general law in physiological pathology that mechanical obstruction to the drainage of any secreting cavity tends to result in local morbid processes and in toxic or infectious manifestations in remote parts of the body.

The Epithelium.—The free surface of the tonsil, including the crypts, is covered with stratified pavement epithelium, the deeper layers of which are columnar in type, while the superficial are pavement. Goodale

has shown that certain coloring matter, when dusted in the crypts, is readily absorbed into the interior of the tonsil. He claims that the absorption probably takes place through the interspaces between the cells. From this the inference might be made that bacteria are absorbed with equal facility. This conclusion does not, however, coincide with either physiological or clinical data.

Jonathan Wright has shown that there is a vast difference in the absorptive power of the tonsil for dust and for bacteria. Wright introduced carmine powder and bacteria into the crypts of the tonsils and excised them in fifteen minutes. The microscope showed the carmine particles in great abundance beneath the epithelium and within the intercellular spaces, whereas no bacteria were found. He also observed that the carmine dust remaining on the outside of the tonsil was easily washed away, while the bacteria were more difficult to remove. The adherence of the bacteria to the live animal membrane and their failure to pass through it he ascribed to the viscosity of the bacteria, a biomechanical property of microörganisms. The mechanical affinity existing between the bacteria and a living mucous membrane he considered as one of their defensive and offensive properties of a biomechanical kind, as distinguished from their biochemical products, the toxin and endotoxin. Dust or carmine powder does not possess this adhesive property, hence it is readily absorbed, whereas the bacteria are not.

We know, however, from abundant clinical experience, that there are conditions under which the bacteria are absorbed through the cryptic epithelium in sufficient numbers to excite marked local and constitutional disturbances. Apparently the adhesive property of the bacteria has been overcome, or the toxin of the microörganisms within the crypts has converted the live epithelium into inert matter, through which it readily passes. Wright says: "From the experiments of Goodale and others with colored granules, from my own observations of dust particles passing the epithelial layer in health, and bacteria passing it in diseases, it is evidence enough that there must be something beyond mechanical obstruction which, under ordinary conditions of health, keeps the tissue beneath the epithelium free of bacterial life, which swarms in some of the crypts on the outer side of the epithelial cells. Hitherto the revelations of the antitoxic power of the blood sera have been insufficient to explain the problem. That explains the nullification of the toxic power of the pathogenic germ after it passes within the tissues, but it does not explain immunity from infection—to translate literally, the freedom from the carrying in of the germ. It seems probable from experimentation with various forms of protoplasm that the animal organism evolves defensive properties to destroy by lysis, when the system through lack of excretory power becomes embarrassed by their presence."

Wright further says that "bacterial protoplasms may excite bacteriolytic ferments in the epithelial cells, a property heretofore referred by Metchnikoff to the leukocytes only." In these ways he attempts to show equilibrium existing between immunity and infection. An imbalance of this equilibrium is effected by a loss of local tonicity or health, and infection then takes place.

In the epithelial lining of the crypts we find, therefore, the following properties:

(*a*) A biomechanical resistance to the invasion of the microörganisms, viscosity.

(*b*) A biochemical destruction or taming of the microörganisms in the crypts through the agency of a ferment thrown out by the epithelium under the stimulus of the retained bacteria. This process is known as bacteriolysis.

So long as the epithelium of the crypts is in a state of tonicity or health, an equilibrium between immunity and infection is maintained. When the cellular tonicity is impaired, the equilibrium between immunity and infection is lost and infection occurs. When the crypts are closed by the plica supratonsillaris and plica triangularis, or by concretions in the mouths of the crypts, a very active warfare between the retained microörganisms and the epithelial cells is begun. The cells throw out a poisonous ferment, whereas the bacteria throw off a toxin for the purpose of impairing the tonicity of the epithelium. If the siege is continued sufficiently long, the cells give way and the infectious host penetrates the epithelial barrier and enters the deeper tissues of the tonsil.

The Sinus Tonsillaris.—The anterior pillar contains the palatoglossus muscle and forms the anterior boundary, whereas the posterior pillar contains the palatopharyngeus muscle and forms the posterior boundary of the sinus. The pillars meet above to unite with the soft palate. Inferiorly they diverge and enter into the tissues at the base of the tongue and the lateral wall of the pharynx respectively. The outer wall of the sinus tonsillaris is composed of the superior constrictor muscle of the pharynx. The sinus tonsillaris is, therefore, a triangular depression on the lateral wall of the fauces which partially envelops the tonsil.

In so far as my clinical observations show, the tonsil is loosely attached to the sinus, that is, the so-called adhesions are not present. The extent of the attachment varies in different subjects. Patterson has shown that the supratonsillar fossa may extend downward so as to admit a bent probe between the outer side of the tonsil and the superior constrictor muscle of the pharynx, as far as the inner surface of the lower jaw. Even when the attachment is general it is not usually so firm as to greatly interfere with the enucleation of the tonsil. The "adhesion" to the anterior pillar so often spoken of is, in my opinion, a myth. It is true that the tonsil has an anatomical connection with the anterior pillar, but the union is not of that firm, fibrous nature usually implied by the term. Indeed, the term "adhesion" is often used in reference to the plica triangularis which covers the antero-inferior portion of the tonsil, and which is often attached to the tonsil at its inferior extremity. One writer even speaks of the plica triangularis as an hypertrophy of the anterior pillar, whereas, in fact, it is an embryological structure, which in some of the lower animals develops into the tonsil itself.

The anterior limit of the sinus tonsillaris often extends well under the anterior pillar, thus concealing a large portion of the tonsil. The outline of the tonsil may be readily determined by digital examination or by

seizing it with forceps and drawing it toward the median line of the throat. When thus drawn the anterior shoulder of the tonsil may be seen outlined beneath the anterior pillar, and if still more forcibly drawn inward, the tonsil mass slips from beneath the pillar, thus showing that it is not markedly adherent, but that, on the contrary, it is loosely attached and by proper procedures may be readily enucleated.

The Lymphatics.—The relation of the tonsil to the lymphatic vessels is somewhat different from that existing between the lymphatic gland and vessels. The difference in the relationship consists in the fact that the lymphatic vessels have their origin in the tonsil, whereas they pass

Fig. 234

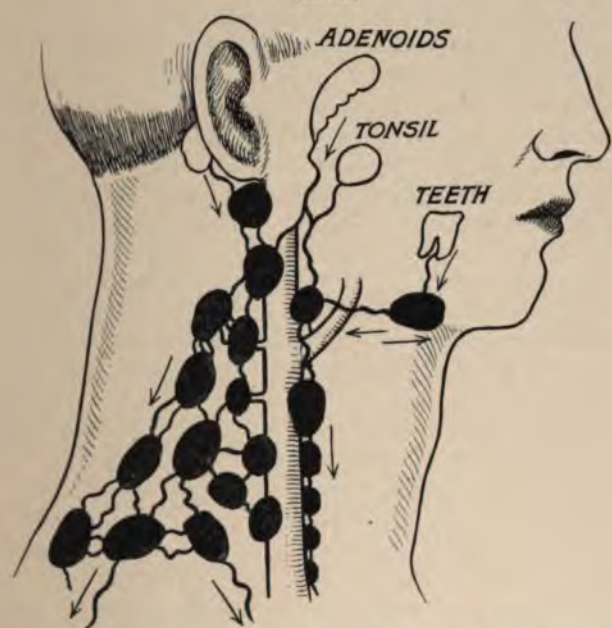

Schema of the lymphatic communications with the teeth, tonsils, adenoids, and mastoid region. The mastoid glands flow into the posterior chain of glands; the adenoids into both the posterior and anterior chains; the tonsil into the anterior group only; the dental glands into the anterior group, though in violent inflammations of the neck glands the current may be reversed. (After Eisendrath.)

through the lymphatic gland. The question of chief clinical importance is the course and termination of the tonsillar lymphatic vessels which drain into the deep cervical chain underneath the sternocleidomastoid muscle, and from thence to the thoracic glands, and finally into the thoracic duct. By this route infection is carried to all parts of the body. The tonsil, under certain conditions, being peculiarly susceptible to infection, becomes, therefore, the atrium of infection for a great variety of diseases extraneous to itself. The literature is rich with clinical reports of diseases illustrating this fact (Fig. 234).

In reference to the tonsil as the portal of infection in tuberculous

processes, it is generally admitted that it often takes place through the tonsil, and extends from thence through the lymphatics of the deep cevrical chain on into the thorax. It then passes through the hilus of the lung into the visceral pulmonary lymphatics. The apex of the right lung is the most frequent seat for the inception of the pulmonary tuberculous disease. This has, heretofore, been attributed to the fact that this area is less directly in line with the respiratory air current, and that this portion of the lung has less motion than other portions of either lung. It forms, therefore, a peculiarly favorable locat on for the development of the tubercle bacillus.

Dr. J. Grober has called this route of pulmonary infection into question, or at least he has set up a rival hypothetical explanation, based upon a series of experiments upon lower animals. He reports the following three suggestive experiments out of a total of twenty-eight:

First experiment, September 16, 1902. A young rabbit was anesthetized by ether and chloroformed, and 1 c.c. of a sterilized emulsion of black Chinese paint injected into the left tonsil.

September 23, 1902, the autopsy showed black particles in the blood. Behind the left tonsil there was a mass composed of the coloring matter and leukocytes. The lymph glands on left side of the neck, as far as the upper border of the thyroid cartilage, were stained black. The microscope demonstrated the lymph vessels filled with free coloring matter, as well as leukocytes which enclosed small particles of pigment.

The glands and lymph vessels were fairly packed with the coloring matter. Beyond the zone of the lymph glands and vessels little coloring matter was found.

Second experiment. A small dog was narcotized by morphine injections. Six and one-half c.c. of the sterilized emulsion of black pigment was injected into the tonsil.

The autopsy, after complete exsanguination, showed the following conditions: Very little coloring matter in the leukocytes, none being free in the blood. The tonsil and the loose connective tissue containing the afferent lymphatic vessels of the tonsil were of a deep black color.

Along the muscles of the neck, as far as the hyoid bone and to the median line, there were streaks of pigment. The pigmented area also spread downward below the hyoid bone, where it extended 1 cm. beyond the median line. The coloring matter was traced to the bony opening of the thorax and to the parietal pleura, which, when stripped off and examined by transmitted light, showed the black pigmentation. The lymph vessels of the paratracheal connective tissue and of the esophagus, as far as 2 or 3 cm. above the bifurcation of the trachea, were also colored, whereas on the left or uninjected side no such phenomenon was found. All the lymph glands on the lateral wall of the pharynx, hyoid bone, larynx, along the deep vessels of the neck and supraclavicular fossa on the right side were black. The parietal pleura at the apex showed an exudate, but no adhesion to the visceral pleura.

The microscope showed that in all the above-mentioned positions there were no other changes present. In the glands the coloring matter

occupied the paravascular spaces. In the lymph vessels between the supraclavicular glands and the parietal pleura of the apex there was a large number of leukocytes filled with coloring matter. Free coloring matter was also present in this region. In the apex of the lung there were no signs of an inflammatory reaction. The coloring matter here seemed to be freely deposited within the connective tissue. In the above-mentioned exudate at the apex there was coloring matter in the leukocytes.

Third experiment, April 4, 1903. A small dog was placed under morphine narcosis and 5 c.c. of coloring matter injected into the tonsil. April 13, the same experiment was performed on the opposite side.

May 10, the autopsy, after exsanguination, showed a large amount of coloring matter free in the blood; the leukocytes, the tonsil and connective tissue, and the connective tissue of the neck on both sides along the larynx to the aperture of the thorax were colored symmetrically. The lymphatic glands along the large bloodvessels, as well as those in the supraclavicular region, were deeply stained. The coloring matter was also found within the lymphatic vessels and in the paravascular spaces. A fibrous exudate was found in the apices of both lungs, thus forming a bridge of inflammatory material from the parietal to the visceral pleura. The coloring matter was also present in the exudate. The microscopic appearance of the apices presented a light grayish coloration. The glands in the mediastinum were stained on the left side, as were also the bronchial glands. In the left lung there were three other small fibrinous exudates in which the coloring matter was preseni.

From these experiments Grober builds the hypothesis that tuberculous infection of the apex of the lung may take place *via* the deep lymphatic chain, the supraclavicular glands, and thence to the parietal lymphatic vessels, where an inflammatory exudate is thrown across to the visceral pleura. The tubercle bacilli travel across this inflammatory bridge and enter the apex of the lung.

While these experiments are not conclusive, they are interesting and open a field for further observations.

The Blood Supply.—The tonsillar artery, a branch of the facial, is the chief vessel to the tonsil, though the ascending palatine, another branch of the lingual, sometimes takes its place. The tonsillar artery passes upward on the outer side of the superior constrictor muscle, through which it passes and gives off branches to the tonsil and soft palate. The palatine, another branch of the lingual, also sends branches through the superior constrictor muscle to the tonsil. The ascending pharyngeal also passes upward outside of the superior constrictor, and when the ascending palatine artery is small it gives off a tonsillar branch which is correspondingly larger. The dorsalis linguæ, a branch of the lingual artery, ascends to the base of the tongue and sends branches to the nostril and pillars of the fauces. The descending or posterior palatine artery, a branch of the inferior maxillary, supplies the tonsil and soft palate from above, forming anastomoses with the ascending palatine. The small meningeal artery sends more branches to the tonsil, though they are of minor importance.

Clinical Application.—Without reviewing the literature, which is rich in reports of cases showing the tonsil to be the portal of infection for many diseases in remote parts of the body, I have attempted to show under what conditions it becomes the portal or atrium of infection. Under conditions of local equilibrium or health of the epithelium lining the tonsillar crypts, infection does not take place, whereas, when the local equilibrium is lost, infection occurs. That the local equilibrium of the cryptic epithelium is frequently lost is apparent to every clinician. In addition to the diseases arising through the tonsil as a portal of infection, there are those limited to, or having their focal centre in, the tonsil itself. Perhaps the strongest indictment against the tonsil is that it is often the atrium of infection in pulmonary tuberculosis. Whether the route of infection is *via* the deep lymphatics and the hilus of the lung, or the deep lymphatics and the parietal pleura at the apex, as shown by analogy in the experiments of Grober, is immaterial in so far as the general question is concerned. The question of prime importance is, Do pulmonary or other types of tuberculosis have their origin through the tonsil as a portal of infection? In view of my own observations, and of others, I must answer in the affirmative. Just what percentage has not been fully determined. Various writers report from 4 to 10 per cent. of tonsils removed as showing local tuberculous lesions, as tubercle bacilli and giant cells.

The structures of the tonsil which seem to favor infection are the crypts, especially those in the supratonsillar fossa and those covered by the plica triangularis. Wright has suggested that the imperfect drainage of the crypt leads to the ultimate loss of tonicity (equilibrium) in the epithelial cells lining them, thereby opening the way to systemic infection through the tonsil.

The question naturally presented at this juncture is, What is the rational method of procedure to protect the system from further infection? The choice of remedial measures seems to lie between internal medication, local applications, and surgical interference.

As to the first and second methods of treatment, it may be said that there are cases which may be satisfactorily treated by them, especially in relieving the distressing local inflammatory symptoms; indeed, many cases may be practically cured by such treatment. There are many others, however, in which such measures are wholly inadequate, either to relieve immediate symptoms or to ward off future attacks. In these cases we have usually resorted to some surgical procedure, such as opening the crypts, plunging the cautery point obliquely across them, decapitation (partial removal of the tonsil), and the complete removal of the tonsil.

The literature shows a wide divergence of opinion as to what constitutes the best method of surgical treatment, though it shows nearly all writers as being practically agreed that some sort of surgical procedure is indicated.

What does the anatomy seem to indicate? It shows certain crypts so situated as to afford poor drainage of their contents, even though the

superior constrictor, palatoglossus, and palatopharyngeus muscles compress the tonsil with each act of deglutition. This is especially true of those crypts discharging into the supratonsillar fossa. Kauffmann has suggested that the supratonsillar crypts be opened with a sharp knife, and that the incised surfaces be painted with 5 to 20 per cent trichloracetic acid. By this opening of the crypts their contents are drained. The acid applications excite a violent inflammatory reaction which results in the contraction of the tonsil tissue. The process is often an extremely painful one, and may result in cellulitis and scar tissue. Furthermore, it does not always prevent further infection through the tonsil. It is, therefore, often necessary to repeat the incisions and acid applications.

The patient is entitled to immunity from tonsillar infection if it can be established without seriously jeopardizing either his health or life. When the tonsil becomes a well-established atrium of infection, the physical economy of the patient is constantly menaced by conditions ranging all the way from a follicular tonsillitis to endocarditis and pulmonary tuberculosis. Measures should, therefore, he adopted which will ensure future freedom from infection through the tonsil.

It has been shown by abundant clinical experience that cauterization of the lumen of the crypts or obliquely across them into the surrounding follicular tissue, does not adequately meet the indications.

The same is true of "decapitation," or partial removal of the tonsil. Decapitation leaves the deep and more diseased portion of the crypts, and, while it may afford some relief of the symptoms, it is often followed by recurrent infections and by the reformation of the tonsillar tissue.

The complete removal of the tonsil with its capsule intact is, so far as I know, the only mode of surgical procedure that guarantees immunity from infection through the sinus tonsillaris.

The function of the tonsil and the effect of its complete removal upon the general condition of the patient must be considered; so, also, must the question of hemorrhage. In reference to the effect of the removal of the tonsil upon the general system, it may be said that there is little evidence that it has any deleterious result. Masini, however, believes that the tonsil has an internal secretion comparable with that given off by the suprarenal gland. He arrived at this conclusion after experiments with the aqueous extract of the tonsil, intravenous injections of which gave the same results as obtained from the injection of suprarenal extract.

The last word concerning the treatment of the tonsil cannot be spoken until its exact function is established. Clinically, there is little to show evil effects from its removal, whereas there is much evidence to show the good resulting from its removal, especially its complete removal.

I have attempted its complete removal with the capsule intact in about 2000 cases during the past six years, and, barring one or two instances in which there was a temporary paresis of the palatopharyngeus muscle, one case of cervical cellulitis, and a half-dozen moderate hemorrhages, I have seen no untoward result. The general health of many was greatly improved and recurrent septic inflammation within the sinus

tonsillaris has been eliminated. Recurrence of the tonsillar tissue has not taken place in a single instance. The fact of its regrowth is almost prima facie evidence that the entire tonsil was not removed. I will not attempt to deny that follicular tissue can be removed from the sinus tonsillaris after the complete removal of the tonsil, and that follicular tissue may develop within the sinus tonsillaris. But this should not be mistaken for the recurrence of the tonsil. The tonsil is an encapsulated mass of lymphoid tissue characterized by numerous crypts.

Having removed the entire tonsil with its fibrous envelope, and its crypts, the chief source of infection is removed. It is, of course, possible for the follicular tissue which surrounds the tonsil to become diseased, but this should be differentiated from tonsillar disease. When the tonsil is not removed with its capsule intact, it is, of course, impossible to determine whether it has been entirely removed; and if a part of it is left, regeneration might well take place. With these facts in mind, it is apparent that the complete removal of the tonsil should show a distinctly defined mass of lymphoid tissue enveloped within a fibrous capsule on its outer, and with mucous membrane on its median, aspect. Lymphoid tissue which is not thus characterized is not tonsil tissue.

Hemorrhage.—The danger from hemorrhage is, perhaps, the greatest "bugbear" of the operation. Is this a real or an imaginary obstacle? It is both. It is real in so far as severe hemorrhage does occasionally occur in tonsil operations. It is imaginary in so far as the reputed frequency of its occurrence and the degree of the danger attending it. A clear knowledge of the possible sources of hemorrhage will enable the operator to largely exclude its occurrence. Furthermore, there are certain matters in the technique of local anesthesia, and in the after-treatment, which, if properly applied, will greatly reduce the frequency and amount of hemorrhage. Clinically, I have observed that the most frequent site of arterial hemorrhage is at about the middle portion of the sinus tonsillaris, where the tonsillar branch of the facial pierces the superior constrictor muscle of the pharynx. Other points of hemorrhage are usually limited to the inferior portion of the sinus tonsillaris, where the tonsillar venous plexus is located, and to the anterior and posterior pillars.

In another part of this chapter I have referred to the fact that three arteries, the tonsillar, the ascending palatine, and the ascending pharyngeal, pass upward on the outside of the superior constrictor muscle, which they pierce as they turn inward to ramify the tonsil and faucial pillars. Just before entering the tonsil they break up into several branches (Fig. 235). It is obvious that the smaller the branches cut during an operation, the less serious the hemorrhage. The clinical application of this fact is that if the arterial branches are severed as they enter the capsule of the tonsil, the liability to hemorrhage is reduced to the minimum; whereas, if they are severed on the outer aspect of the superior constrictor muscle before they are broken up into smaller branches, the danger from both primary and secondary hemorrhage is greatly increased. It may be said that the operator should not injure the

superior constrictor muscle in this operation, and this is true. Indeed, if he thoroughly appreciates the clinical significance of the anatomy of the tonsillar region, he probably will not injure it. There's the rub.

As to the anterior pillar, it should be borne in mind that there are arterial twigs coursing upward through it. The main trunks of the arterial branches are external to the palatoglossus muscle. Hence it follows that in order to injure them it is necessary either to pass the instrument behind the muscle, and thus injure them, or to include the

Fig. 235

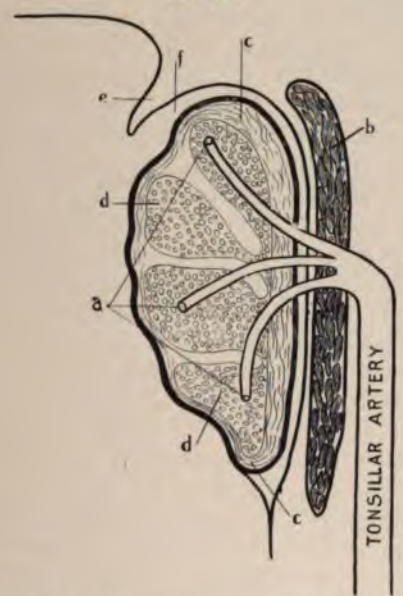

a, subdivisions of the tonsillar artery; *b*, superior constrictor muscle of the pharynx; *c c*, fibrous capsule of the tonsil: *d*, lymph follicles or substance of the tonsil; *e*, plica supratonsillaris; *f*, supratonsillar fossa.

musculature of the anterior pillar in the grasp of the tonsillotome, knife, blunt dissector, or scissors, etc., and thus sever the muscle and vessels of the anterior pillar. The same statements may be made in reference to the posterior pillar.

The technique should, therefore, be such as to avoid injury of the muscles bounding the sinus tonsillaris, namely, the superior constrictor of the pharynx, the palatoglossus and the palatopharyngeus muscles, as by so doing only the small branches of the tonsillar arteries are injured.

CHAPTER XXII.

THE INFLAMMATORY DISEASES OF THE TONSIL.

General Considerations.—The inflammatory diseases of the tonsils are usually subdivided into various types, according to whether the process is acute or chronic, and is limited to the crypts or extends to the substance or parenchyma of the tonsil. As a matter of fact, this classification is somewhat artificial, as it is now well established that all, or nearly all, inflammations of the tonsil are due to infection through the epithelium of the crypts. The manifestation may be acute or chronic in type; it may appear as an acute or chronic lacunar inflammation, with the typical exudate at the mouths of the lacunæ or crypts; or it may be manifested in the form of a parenchymatous inflammation, in which the whole substance of the tonsil is involved. There is no profound mystery surrounding the tonsil inflammations other than those of a biochemical nature, which are common to all inflammatory processes. The fact of chief importance is that in all types of tonsil inflammation there is a lesion of the epithelium lining the crypts, and that some form of pathogenic bacteria has penetrated it. The determination of the type and virulence of the microörganisms is of even greater importance than the determination of the type of tonsillar inflammation under the older classification. The bacteriological findings at least afford some useful information as to the virulence of the infecting microörganism, and, therefore, influence the mode of treatment to a certain extent. If the virulence is marked, surgical procedure is contraindicated; indeed, the presence of an acute inflammation would of itself constitute a contraindication to operative interference.

Much remains to be learned concerning tonsil inflammations. It may still be questioned whether it is good practice to remove tonsils in the wholesale manner now in vogue. The function of the tonsil in a child and in an adult is still an open question. When does the function cease or become so altered by disease as to justify the removal of the tonsil? Should the tonsil be partially or completely removed? When removed, what organ performs its functions? These and other questions are not fully answered. We know from clinical experience that when a tonsil shows a tendency to become the seat of recurrent inflammations the patient's health and life are conserved by its entire removal. Are there other methods of treatment that will better conserve the health and life of the patient? It is doubtful, though this is still an open question. The removal of the debris from the crypts, from time to time, would no doubt avert many acute exacerbations; the topical

application of solutions of silver might also prevent acute manifestations, but in the long run such methods of procedure must fail. The complete removal of the tonsil during a quiescent period must always succeed in preventing inflammations of the tonsil for all time to come. Will a tonsil thus removed recur? Never, if it is completely removed. Can it be removed by dissection with its capsule intact? Yes; with the most happy results.

ACUTE LACUNAR TONSILLITIS.

Synonyms.—Acute follicular tonsillitis; infectious tonsillitis; cryptic tonsillitis.

Etiology.—The chief causes of this and other forms of tonsillitis are the local impairment of the epithelial lining of the crypts and the invasion of certain pathogenic bacteria, as has been pointed out in the Tonsils as Portals of Infection, and the Clinical Anatomy of the Tonsil. There are other factors which enter into the etiology, and they will be discussed in the following analysis:

The Local Lesion of the Tonsil.—As shown by Goodale and Wright (p. 367), the crypts of the tonsil are the seat of absorption for dust and microörganisms, whereas the surface epithelium of the tonsil has but little part in this process. They have shown that dust, as carmine powder, is readily absorbed through the healthy epithelium of the crypts, whereas bacteria are not. Bacteria are only absorbed through dead or impaired cryptic epithelium. Hence, the prime requisite for tonsillar infection is an impairment of the cryptic epithelial lining. This condition may be brought about by the retention of exfoliated epithelium and other debris in the crypts of the tonsil. The retention is formed by the constriction of the mouths of crypts from previous inflammation, and by the plica supratonsillaris and the plica triangularis which cover the mouths of some of the crypts in such a manner as to prevent the expulsion of their contents. The toxin thrown out by the imprisoned microörganisms causes the death of the cryptic epithelium and thus opens the way for the invasion of the microörganisms into the tonsil and the general lymphatic and circulatory system, hence the constitutional symptoms in this disease.

The Bacteriology.—The bacteriology of acute tonsillitis embraces several pathogenic microörganisms, chief of which is Streptococcus pyogenes.

Besides these, the Staphylococcus aureus and albus, the pneumococcus, and the leptothrix are sometimes present.

Age.—The disease is more common in young adults between the twentieth and thirtieth years of life. It is also common in children, and more rare after the fortieth year of life.

Catching Cold.—Tonsillitis is frequently the immediate result of catching cold, which is but another way of saying the resistance was lowered, thus favoring the growth of the pathogenic bacteria.

Surgical Trauma.—The inflammations following surgical procedures in the nose and epipharynx frequently extend to the tonsil, and are of bacterial origin.

Specific Fevers.—Tonsillitis is often associated with the specific fevers, as scarlatina and diphtheria, and is of bacterial origin.

Pathology.—In acute lacunar tonsillitis the tonsil is swollen, though the chief changes occur in the crypts, where there is an accumulation of leukocytes and dead epithelial cells intermixed with pathogenic bacteria. The transudation of leukocytes occurs chiefly through the cryptic membrane rather than through the surface mucosa. The accumulated material in the crypts or lacunæ is sometimes entangled in a fibrous exudate or pseudomembrane, though the pseudomembrane is not always present.

Symptoms.—The Subjective Symptoms.—In this, as in other acute infectious processes, the onset is sudden and is attended by malaise and fever. Chilly sensations or light rigors may mark the attack. The temperature gradually rises until the end of the first to the third day to 102° to 103°, and in young children it may rise as high as 104° to 105°. The febrile movement is accompanied by soreness upon swallowing, which as the disease progresses may become quite painful. The inflammation extends to the pharyngeal mucous membrane, and even, in exceptional cases, to the Eustachian tube and the middle ear. There may be pain in the ear through reflex sources without actual inflammation in the tympanum. Tinnitus may also be present. The gland under the angle of the jaw is usually swollen and tender, as it is in a state of great physiological activity in its attempt to check the invading host of bacteria which has passed through the impaired epithelial barrier in the crypts of the tonsil. The swollen condition of the tonsil and surrounding muscles renders rotary motions of the head somewhat painful. The same conditions also render articulation and phonation imperfect, the voice being thick and indistinct. The tongue is coated with a yellowish-brown fur, and the breath is fetid and offensive. Transient albuminuria is sometimes present, especially if the attack is severe and prolonged. Casts may also be found in the urine. Such a condition is common to all acute infectious processes in any part of the body, and do not necessarily point to grave results.

The acute symptoms rarely extend beyond the third, fourth, or the fifth day. The febrile movement and the swelling and soreness rapidly subside until the temperature is normal and the act of deglutition and the rotation of the head may be performed with comfort to the patient. The patient, though convalescent, is often left in a very weakened condition.

The Objective Symptoms.—At the onset the tonsils are swollen and red, while the crypts may not present the characteristic yellowish furred appearance, especially in their central and posterior aspects. The pharyngeal mucosa and the pillars of the fauces are usually redder than normal. At a later period the tonsil and pharynx are still more swollen, and a creamy discharge is seen extruding from the mouths of one or more of the crypts.

PLATE VII

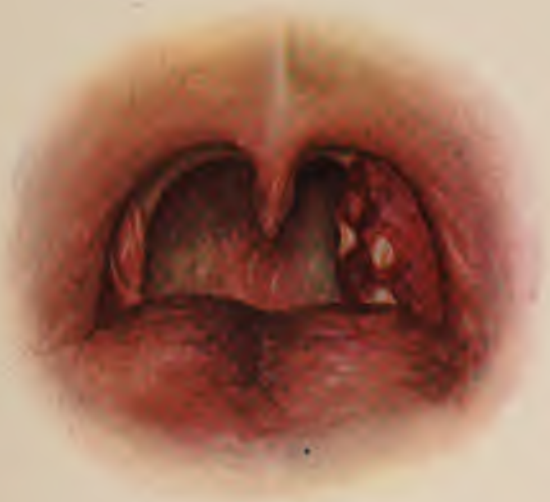

Acute Lacunar Tonsillitis.

This disease may usually be cured by one application of a 90 per cent. solution of the nitrate of silver.

The patches are not usually true membranous products, as found in pseudomembranous and diphtheritic inflammations, but are the secretions and debris which completely fill the crypts and are extruding from their mouths (Plate VII).

Occasionally there is a fibrinous exudate admixed with the debris, which gives it some of the characteristics of an inflammatory membrane. The protruding secretion and debris are easily wiped away, in contradistinction to the diphtheritic membrane, which is closely adherent to the epithelium.

I have seen cases of diphtheria which closely resembled acute follicular tonsillitis, inasmuch as the membrane was loosely attached, on account of the solvent action of antitoxin administered eighteen to twenty-four hours previously. The debris is occasionally found upon the surface of the tonsil, upon the pillars of the fauces, and upon the posterior wall of the pharynx. It is easily removed with a cotton-wound applicator.

Pharyngeal and lingual tonsils are usually simultaneously inflamed with the tonsil, and the yellowish exudate or debris peculiar to the faucial tonsil is found in the shallow crypts of the pharyngeal tonsil and still more shallow depressions of the lingual tonsil. The debris is similar in composition to that found in the crypts of the faucial tonsils. If the febrile symptoms continue after the faucial tonsil appears to be well, the pharyngeal and lingual tonsil should be examined with a laryngeal mirror for evidences of inflammatory processes.

Complications and Sequelæ.—Complications and sequelæ are comparatively rare, the case usually ending favorably in seven or eight days. Under appropriate treatment the duration of the disease is often much shorter than this; one application of a strong aqueous solution of silver nitrate often ending the disease within a few hours. Occasionally, when only one tonsil is diseased, the other is attacked at the close of the first attack. When this is the case the febrile and other symptoms are repeated. The follicular inflammation is rarely followed by a phlegmonous inflammation of the tonsil or of the peritonsillar tissue (quinsy). The cervical glands, beginning with the one under the angle of the jaw, may suppurate. Purulent otitis media, pericarditis, pleuritis, erythema nodosum, and erythema multiforme have been reported as sequelæ of acute tonsillitis. Transient albuminuria is a rather common complication.

Diagnosis.—The following table will aid in the differential diagnosis between acute lacunar tonsillitis and diphtheria, although there are cases in which the differential points are obscure and dependence must be placed upon the bacteriological findings:

Acute Lacunar Tonsillitis.	*Diphtheria.*
1. Onset marked by a sharp rise of temperature.	1. Onset, rise more gradual.
2. Rapid, bounding pulse.	2. Slow, feeble pulse.
3. Depression not marked.	3. Depression marked.
4. Exudation limited to the tonsil, especially the mouths of the crypts.	4. Exudation extends beyond the tonsils and is not limited to the crypts.
5. Exudate not adherent.	5. Exudate closely adherent.
6. Exudate soft and friable.	6. Exudate firm and leathery.
7. Exudate not distinctly membranous	7. Exudate membranous and may be removed in strips.
8. Swollen glands uncommon except in severe cases.	8. Swollen glands common even in mild cases.
9. Albuminuria not common.	9. Albuminuria common.
10. Klebs-Loeffler bacillus absent.	10. Klebs-Loeffler bacillus present.

I have seen cases in which repeated examinations failed to show the Klebs-Loeffler bacillus, which were finally shown at subsequent examinations. Absolute dependence must not, therefore, be placed upon negative microscopic findings; if, however, the Klebs-Loeffler bacillus is found, the case should be pronounced diphtheria, even though the clinical phenomena do not corroborate the microscopic findings.

Treatment.—This type of tonsillitis is more amenable to treatment than any other. One application of a 50 to 90 per cent. solution of nitrate of silver, if applied locally during the first twenty-four hours of the disease, will in nearly every instance abort the attack. I have repeatedly used silver in this way, and upon the following day have almost always seen the disease under complete control. A second application is rarely required. The febrile and other symptoms rapidly decline and convalescence is quickly established. This may appear to be an overstatement of the facts, but in my experience it corresponds with the facts. I have tried other remedies, but none of them have equalled the nitrate of silver. This strength of silver may appear to be caustic in action and unsuited for the treatment of acute tonsillar inflammation. As a matter of fact, it unites with the mucine so readily that its caustic action is greatly diminished before it acts upon the mucous membrane. It coagulates the secretions and blanches the mucous membrane, thereby checking the inflammatory infiltration of the tissues. It also entangles the pathogenic bacteria in the albuminate of silver and prevents further activity on their part. It appeals to me as an ideal remedy in the early stage of the disease, and is worthy of extended trial.

In applying silver to the tonsil the excess of fluid should be squeezed from the cotton-wound applicator to prevent it trickling to the larynx, where it will produce violent spasm of the intrinsic muscles of the larynx. The silver salts are not well tolerated by the motor nerves and muscles of the larynx, and severe suffocative symptoms may be produced by inattention to the technique of its application. I have seen cases in which cyanosis was pronounced from this cause. A little attention on the part of the physician will obviate this distressing occur-

rence. Guaiacol in a 25 to 50 per cent. solution of olive oil is the next most effective remedy. It should be applied locally two or three times daily for two days. The effect is pronounced, though not so immediate as with the nitrate of silver. It produces a hot, peppery sensation for about thirty seconds, followed by a sense of relief.

The carbonate of guaiacol given internally in 5 grain doses every three hours exerts a decided beneficial action upon the course of the disease.

The tincture of the chloride of iron in eight parts of glycerin given in teaspoonful doses every two hours is another good remedy.

The salicylate of sodium, the benzoate of sodium, and the chlorate of potash are also recommended, but the silver solution is so much superior to either of the other remedies mentioned that it should be used in nearly all cases to the exclusion of the other remedies.

If there is a history of repeated attacks of acute lacunar tonsillitis, the tonsils should be removed by complete dissection during the interval between the attacks. This procedure alone offers a considerable hope of permanent relief from the attacks and their more serious complications and sequelæ.

CHRONIC LACUNAR TONSILLITIS.

Definition.—Chronic lacunar tonsillitis is characterized by the presence of caseous material composed of layers of desquamated epithelial cells enclosing cholesterin crystals, fatty matter, leukocytes, micro-organisms, and occasionally calcareous deposits. The masses vary in size from a grain of wheat to a small bean. The crypts most often involved are those opening into the supratonsillar fossa and those covered by the plica triangularis, for the reasons already given in the Clinical Anatomy of the Tonsil. The tonsil may or may not be hypertrophied, though it is generally in that condition.

Etiology.—One of the chief causes of the disease is the retention of the desquamated epithelium, bacteria, and debris in the crypts, which in turn is due in part to the anatomical barriers afforded by the plicæ supratonsillaris and triangularis. Back of all this there is probably a diseased condition of the epithelium lining the crypts, due to previous acute inflammations.

Symptoms.—The subjective symptoms are not usually pronounced in character. The patient may complain of pain upon swallowing saliva, but not upon swallowing solid food (Ball). Neuralgic pains sometimes shoot toward the ear. Some patients have the sensation, lasting perhaps for only a minute or two, of a foreign body lodged in the tonsil.

The objective symptoms are more pronounced and characteristic than the subjective ones. The patient coughs up the caseous masses, which have a fetid odor, and he consults a physician, who upon examination notes the fetid breath and the yellowish masses in the crypts of the tonsil. Upon exerting pressure upon the tonsil with a flat instrument the caseous masses are forced from the crypts. If they are full to over-

flowing, the yellowish spots appear at the mouths much as they do in the acute form of the disease.

The tonsils are usually enlarged, the size of the tonsils often being greater than appears upon superficial examination, as they are covered by the plica triangularis and plica supratonsillaris indeed, some of the largest tonsils I have ever removed were thus concealed from view. The plica triangularis is not an "adhesion" or inflammatory product, as some authors state, but is an embryological structure, as stated in the section on the Clinical Anatomy of the Tonsil. When the anterior and median surfaces of the tonsil are completely covered by an unusually large plica triangularis, the mouths of the crypts cannot be seen without a throat mirror, or putting the patient "on the gag." By resorting to the latter of these expedients the tonsil is rotated forward so that its median surface may be seen by direct inspection. A blunt tonsil hook introduced into the crypts or into the pocket formed by the union of the plica triangularis with the tonsil will remove the caseous plugs and develop the fetid odor to its full extent. The caseous masses are not adherent, but are easily removed with a blunt hook, or by pressure upon the surface of the tonsil.

Occasionally the mouth of a crypt becomes closed by inflammatory adhesions and the caseous mass thus encysted, the yellowish color showing through the thin membranous covering over the mouth of the crypt.

A tonsil thus affected is subject to exacerbations of acute symptoms, generally of a mild type, the mucous membrane becoming slightly reddened. There is also some soreness upon swallowing. The temperature is but little elevated and attracts no attention. The patient sometimes complains of slight huskiness of the voice, and has fits of coughing from the local irritation in the tonsil. During these attacks he often coughs up the caseous masses. The repeated removal of the plugs affords some relief, and their tendency to reform is diminished, though a cure by this procedure does not often occur (Fig. 266).

Treatment.—If the symptoms are annoying to the patient, and recur at frequent intervals, or if the patient has had rheumatism, enlarged glands in the neck, or has other evidences of infection in a remote part of the body, which may reasonably be assigned to absorption through the tonsils, they should be removed in their entirety.

Slitting the crypt walls, followed by the application of a 20 per cent. solution of trichloracetic acid or of strong solution of iodine, has been strongly advocated by Kauffmann and others. Personally, I do not recommend this mode of treatment, as it is, at the best, a makeshift and fails to meet the fundamental requirements of the condition. The tonsil crypts are diseased, chronically infected, and have a tendency to continue in a diseased state. The rational procedure is, therefore, to completely remove the tonsil, preferably with its capsule intact. (For a description of the operation, see Surgery of the Tonsils.)

CALCULUS OF THE TONSIL.

Small quantities of calcareous or gritty particles are often found in the centre of the caseous plugs filling the crypts of the tonsil in chronic lacunar tonsillitis. They sometimes become quite large and fill the crypts, and are known as calculi of the tonsil. The etiology is not clear beyond the fact that they are usually found in tonsils affected by chronic inflammation.

Symptoms.—The symptoms are identical with chronic lacunar tonsillitis with caseous plugs in the crypts. That is, there are recurrent attacks of mild tonsillitis with redness especially marked around the affected crypts.

Treatment.—The treatment consists in the removal of the calculus, or the removal of the tonsil as in chronic lacunar tonsillitis. If the calculus is not easily disengaged from the crypt, an incision of the wall of the crypt facilitates its removal. Pain may be obviated by injecting a 4 per cent. solution of cocaine into the substance of the tonsil in the region of the calculus.

PHLEGMONOUS TONSILLITIS AND PERITONSILLITIS (QUINSY).

Phlegmonous tonsillitis is an acute abscess within the substance of the tonsil, whereas peritonsillitis is an acute abscess in the peritonsillar tissue. The processes are the same, while the location of the purulent accumulation is different. Peritonsillar abscess, or peritonsillitis (quinsy), is much more common than phlegmonous tonsillitis.

Etiology.—The causation is about the same as given under acute lacunar tonsillitis. Peritonsillitis (quinsy) probably arises from an infection of the crypts in the supratonsillar fossa, which are large, slit-like cavities with irregular outlines, and which are in intimate relationship with the posterior and outer aspect of the tonsil. These crypts appear to be the usual route of peritonsillar infection, hence the abscess is usually located in the tissue external to the tonsil. The disease is common in young adults and rare in children.

Symptoms.—Phlegmonous tonsillitis is more rare and less severe than peritonsillitis. Otherwise the symptoms are much the same. The onset is gradual in so far as the peritonsillitis is concerned, though there may have been a preceding acute lacunar tonsillitis with its sudden onset and severe symptoms. The temperature rarely exceeds 99° or 100°, whereas in acute tonsillitis it often rises to 103°.

The pain progressively increases with the extension of the purulent accumulation until it is almost unbearable. The muscles of mastication are encroached upon by the abscess so that the patient has the greatest difficulty in opening the mouth sufficiently wide to permit of an examination of the throat. Swallowing becomes difficult and very painful. The disease is usually limited to one side. The saliva dribbles from the

mouth and forms one of the characteristic symptoms. Lateral movement of the head produces pain on account of the infiltration of the tissues of the neck in the region of the tonsil.

Thick viscid secretion forms in the throat, and it is with the greatest difficulty that the patient succeeds in removing it. The tongue is heavily coated and the breath fetid. Breathing is interfered with on account of the swollen mucous and submucous tissue of the pharynx. The patient has an anxious expression of countenance. During sleep he often has suffocative attacks which awaken him. Laryngeal dyspnea from extension of the edema to the laryngeal tissue is fortunately rare.

Objective Symptoms.—At the onset there is slight redness and swelling upon one side. Both tonsils are rarely affected at the same time. If both are affected, the second usually begins as the first subsides. If both are affected at once, the suffocative symptoms are more pronounced and alarming. As the disease progresses the redness, tenderness, pain, and swelling increase in severity. If the abscess is in the tonsil, it is pushed toward the median line or even beyond it. If the abscess is in the peritonsillar tissue, the swelling often appears to be in the region of the upper portion of the anterior pillar. As a matter of fact, the apparent swelling in this region is often the anterior border of the tonsil projected against the pillar by the pus behind the tonsil. Incisions in this region often fail to reach the pus cavity for this reason; that is, the incision is carried directly into the tonsil instead of into the pus cavity outside of the tonsil. If the depth of the incision is carried beyond the outer border of the tonsil, the pus will be more often found. It should be remembered that the anterior third of the tonsil projects forward beneath the anterior pillar; hence, in making an incision through the anterior pillar to evacuate the pus, it should be made far enough anteriorly to escape the anterior border of the tonsil, and should be directed in an outward and a backward direction, so as to go outside of the capsule of the tonsil. If these anatomical facts are borne in mind, the anterior incision will nearly always evacuate the pus. If a posterior incision is to be made, it should be directed outward through the posterior pillar, or in its immediate vicinity, as the pus pocket often extends posteriorly to the tonsil.

The soft palate and uvula, as well as the pharyngeal mucous membrane, are red and edematous. The region of the tonsil is of a deep, dusky red color. The crypts are often filled with a pulp-like debris, which is probably the original source of infection. The infection does not originate in the peritonsillar tissue, but in the supratonsillar crypts of the tonsil.

Digital examination of the tonsillar region shows more or less distinct fluctuation. The focal centre of fluctuation is about one-quarter of an inch external to the free border of the anterior pillar; at the junction of the upper third with the middle third of the tonsil; or it may be posterior to the tonsil.

The duration of the disease embraces from five to fourteen days when allowed to run its course, though it may extend over a longer period. The termination of the disease is marked by the spontaneous or artificial

discharge of fetid pus. When the discharge is spontaneous it usually takes place through the anterior pillar, though it occasionally occurs through one of the crypts.

Complications and Sequelæ.—Complications and sequelæ are rare. Cases are on record, however, in which the following conditions were present:

(*a*) Edema of the glottis from the downward extension of the process.

(*b*) Strangulation of an adult from the spontaneous rupture of the abscess sac.

(*c*) Ulceration thrombophlebitis of one of the large veins of the neck.

(*d*) Ulceration of one of the large arteries in the submaxillary region.

(*e*) Chronic peritonsillitis with an intermittent flow of pus (Ball).

(*f*) Encysted abscess in the tonsil.

Treatment.—The Onset.—If the case is seen early when there is an infiltration and redness of the mucous membrane and the deeper tissues, but no pus, cold applied in the mouth or externally at the angle of the jaw diminishes the pain, and, indeed, it may abort the attack. Cold may be applied internally by means of iced gargles or by sucking cracked ice. It is applied externally with a Leiter coil. It should be borne in mind that cold applications are indicated in the early stage of acute inflammation, whereas hot applications are indicated in the more chronic stages. In very acute inflammation proliferation and local leukocytosis are active, whereas in the later stages cell proliferation and local leukocytosis are lessened, though the proliferated cells remain permanently; hence, heat is indicated to increase the leukocytosis, as the lymphocytes are needed to clear up the inflammatory products and the polynuclear leukocytes to destroy the bacteria.

Pain may be relieved by the inhalation of hot vapors or steam, or by the application of hot poultices or a hot Leiter coil to the neck and angle of the jaw. Local applications of cocaine may also be used for the same purpose. The leukodescent 500 candle-power lamp (Fig. 19), when available, provides an excellent mode of treatment. In peritonsillitis the rays of the lamp should be applied over the neck and angle of the jaw upon the affected side. The lamp should first be passed over the neck a few times at a distance of six inches, and then more slowly for ten to thirty minutes at a distance of eighteen inches. Such treatments will relieve the pain and reduce the swelling more readily and certainly than cold applications, as they promote the reaction of inflammation.

Surgical Treatment.—When the process is well established the evacuation of the pus is imperatively indicated. The point of election for the incision (in quinsy) should be determined by the location of the pouching or fluctuation. It is usually in front of the anterior pillar on a level with the junction of the upper and middle thirds of the tonsil, though it may be in the posterior pillar or through the tonsil. Some recent writers have advocated the posterior pillar as the most favorable site for the incision, whereas most of the earlier authors recommend the anterior pillar. As a matter of fact, many of the failures to evacuate the pus through the anterior incision are due to a failure to take into account

the fact that the tonsil often extends forward beneath the anterior pillar. The incision as usually made, therefore, penetrates the tonsil instead of the tissue outside of it (Fig. 236).

HYPERTROPHY OF THE TONSIL.

This subject is nearly akin to chronic lacunar tonsillitis, as in that disease the tonsil is nearly always hypertrophied. Likewise the hypertrophic tonsil is nearly always the subject to chronic lacunar inflammation. Nevertheless, it is practical to consider hypertrophy of the tonsil as a separate entity, as there are certain general considerations which justify it.

Hypertrophy of the tonsil usually begins about the second year of life and continues until young adulthood. Instances have been noted in which the babe seemed to have been born with enlarged tonsils. It is therefore occasionally congenital. While the hypertrophic process may continue into young adult life, it generally ceases to actively develop after puberty, and often seems to undergo an atrophic change. As a matter of fact, the apparent atrophy is a sclerosis; that is, the connective-tissue element develops in excess of other structures and the tonsil becomes firmer and firmer and shrinks on account of the contraction of the connective tissue formation. The difference between a child's tonsil and an adult's tonsil is thus explained: In a child the enlargement is due to an increase in all the cellular structures composing the tonsil, whereas in an adult the connective-tissue cells are increased in excess of the other cellular elements (hyperplasia). In a child the tonsil is soft and smooth in outline, whereas in an adult it is often much harder and nodular in outline. In some children the hypertrophied tonsil is so loosely attached to the sinus tonsillaris that it can be easily removed in its entirety, with its capsule intact, with the tonsillotome. In others it is more firmly attached, and the tonsillotome only removes the superficial portion. In a few adults the tonsil is loosely attached, though it is ordinarily more firmly attached than in children. The exact size of the tonsil is not always shown by the ordinary examination, as only a superficial portion (median) is visible. The greater portion of the tonsil may be hidden beneath the anterior pillar, the plica triangularis and the plica supratonsillaris.

Fig. 236

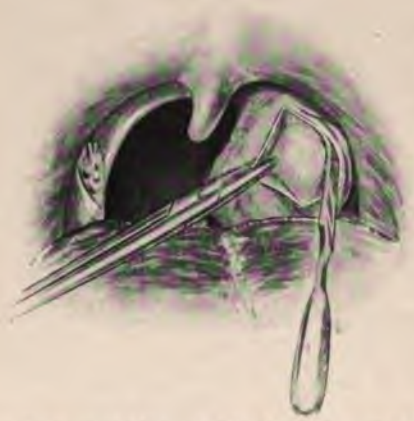

The author's dissection back of the capsule of the tonsil to evacuate a peritonsillar abscess. The dissection is started as though the tonsil were to be removed.

Wilson has shown by the examination of a number of cadavers that the average height of the tonsil above the margo supratonsillaris is about ½ inch. Hence, too, much importance should not be attached to the apparent size of the tonsil. It should be palpated with the index finger through the mouth, and its boundaries defined and its movability (degree of attachment) determined. In this way a good idea of the degree of enlargement and the ease with which it may be removed may be estimated.

The so-called submerged tonsil (Pynchon) is one that has undergone fibroid changes and is hidden behind the anterior pillar and the plica triangularis. Pynchon speaks of the plica triangularis as "an hypertrophy of the free border of the anterior pillar," whereas it is a normal structure appearing in embryonal life, and in some of the lower animals develops into the tonsil itself. There is no muscular tissue in the plica triangularis, and it should be removed with the tonsil. When it is left in place it may form a pocket or pouch where food and other debris collects, and is the source of considerable local irritation.

The hypertrophic and hyperplastic tonsil may have healthy crypts, but, as a rule, the reverse is true. The lining epithelium of some of the crypts is usually of low vitality or entirely deadened or hornified, and is unable to resist the invasion of pathogenic microörganisms. During the transitional stage between hypertrophy and hyperplasia of the tonsil hyperkeratosis of the cryptic epithelium may take place (hyperkeratosis of the tonsil). The leptothrix (mycosis tonsillaris) is an adventitious complication and not a disease *per se* (G. B. Wood). The hyperkeratosis is a self-limited condition, and usually disappears spontaneously in from one to three years.

If an hypertrophied or hyperplastic tonsil gives rise to untoward local symptoms or to constitutional disturbances, or to local morbid lesions in remote portions of the body, it should be removed in its entirety. (The Tonsils as Portals of Infection.)

Treatment.—Palliative treatment directed toward the removal of the caseous plugs from the crypts, and from the pocket formed by the union of the plica triangularis with the tonsil, may be instituted when for any reason an operation cannot be performed. The incision of the cryptic walls and the application of acids or iodine, as advocated by Kauffmann, Ball, and others, may also be tried, but the best results are obtained by the complete removal of the tonsil with its capsule intact. (Operations upon the Tonsils).

HYPERKERATOSIS OF THE TONSIL; MYCOSIS LEPTOTHRICIA.

According to Dr. George B. Wood, "Hyperkeratosis of the tonsillar tissues of the throat is a disease, or, better, a condition, characterized by the appearance of numerous white projections not only from the cryptal orifices of the tonsils proper, but also from the orifices of the lymph follicles on the posterior and lateral pharyngeal walls and on the lateral

glosso-epiglottidean folds. This condition does not occur on portions of the throat where there is no lymphoid tissue. The lymphoid tissue of the upper respiratory tract, however, is so ubiquitous that occasionally we may see the little white projections on almost any part of the mucosa. In the large majority of cases the condition is limited to the faucial and lingual tonsils. That it reaches its greatest development on the base of the tongue and at a position just behind the lateral glosso-epiglottidean folds and the posterior part of the inferior poles of the tonsils is due almost entirely to mechanical reasons. The contractions of the muscles during swallowing prevent food from coming in intimate contact with the surface of these parts, and therefore permit the projections to grow undisturbed. Although the horny material is quite resistant to trauma, the bacterial accumulations which form the greater mass of the projections are easily brushed off, so that the size of the growth is much greater where it is protected from mechanical disturbances.

FIG. 237

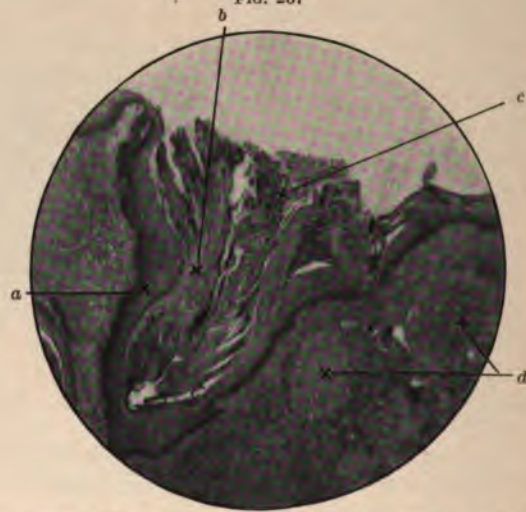

Hyperkeratosis. Showing the typical appearance under low power. The horny mass is growing from a comparatively small area of the cryptal epithelium, and the plug shows the ordinary fraying of its edges. *a*, crystal epithelium; *b*, horny material; *c*, masses of bacteria; *d*, follicles. (Wood.)

"The symptoms caused by this condition of the throat are either entirely wanting or very slight, and are due for the greater part to the local irritation caused by the hard, horny plug. If they project from the base of the tongue so as to come in contact with the epiglottis, there is an irritating tickling sensation which causes a hacking cough. If they are so placed as to be compressed during the act of swallowing, they may give rise to a slight pricking pain.

"Occasionally among the rich and various bacterial flora which grow in such luxuriance on this horny material there may lurk a germ possessed of more or less pathogenic power, which may set up an accompanying inflammatory reaction in the tonsil or surrounding structures.

Hence, the relation which some observers have noticed between acute tonsillitis and this disease."

Dr. Wood also says that to understand correctly the pathology and also the etiology of lacunar hyperkeratosis we must turn our attention for a few moments to the anatomy of the normal active tonsil. The tonsil consists of four chief elements: the connective tissue, the germinating follicles, the interfollicular tissue, and the crypts.

1. "The connective tissue, that is, the trabecule and the reticulum, acts as a supporting framework to the tonsil substance proper. The trabeculæ carry bloodvessels, the nerves, and the lymphatics.

2. "The germinating follicles are the centres wherein the larger mother cells of the leukocytic group undergo karyokinesis and form young lymphoid cells.

Fig. 238

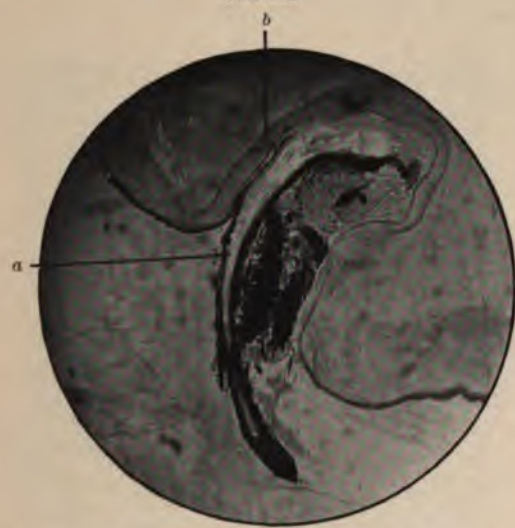

Hyperkeratosis, faucial tonsils. This specimen is from a case which had been vigorously treated with antiseptics. There are practically no microörganisms. The black staining is due to nitrate of silver which has been used in treating the patient. *a*, intact cryptal epithelium; *b*, keratoid plug. (Wood.)

3. "The interfollicular tissue is made up of lymphoid cells in various stages of development. The cells making up this interfollicular tissue differ in size and shape according to their location. They are greater in number around the follicles, and show greater difference in their anatomical construction in the immediate neighborhood of the crypts.

4. "The crypt of the tonsil is its peculiar and most characteristic structure. It consists of an invagination of the epithelium from the surface of the tonsil, which has undergone a very interesting anatomical change. In the first place the subepithelial connective tissue which is present in a marked degree beneath the surface epithelium disappears as soon as the epithelium starts to form the crypts. This permits the epithelial cells to come in direct contact with the lymphatic structures of the tonsil,

and very frequently it is impossible to distinguish a dividing line between the epithelium of the crypt and the interfollicular tissue. The epithelium of the crypt, unlike its progenitor which covers the surface of the tonsil, does not form a compact unbroken barrier or protection. For the greater part of its extent it presents an intact line only one or two or possibly three cells in thickness. Toward the parenchyma the epithelial cells show a peculiar condition. They are separated from each other by interposed cells varying in type from slightly changed epithelial cells to a well-formed lymphocyte. The epithelial cells may also extend from the crypt into the tonsillar substance, suggesting the ramifications of a malignant epithelioma. The smaller terminal invaginations of the cryptal epithelium are usually solid sprouts, frequently with central keratosed cores. The lumen of the crypt is formed by the subsequent exfoliation of the keratosed cells.

Fig. 239

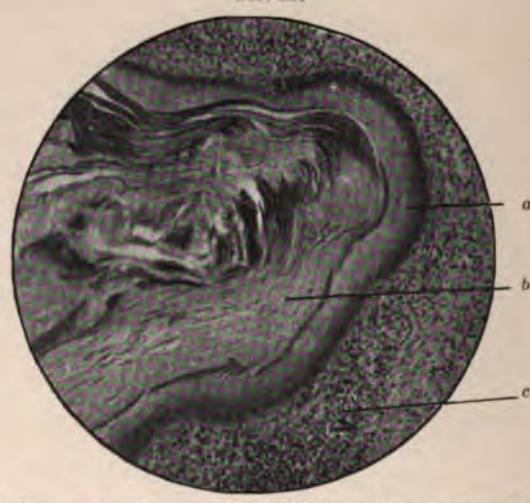

Hyperkeratosis. Cross-section of a crypt filled with keratoid material and bacteria. *a*, intact epithelium; *b*, hornified cells; *c*, lymphoid tissue. (Wood.)

"Turning now to hyperkeratosis, we find the epithelium of the crypts showing characteristic changes. In hyperkeratosis the epithelium loses its rarefied condition and becomes ordinary pavement squamous epithelium similar to that covering the surfaces of the tonsil, except that generally it does not show the connective-tissue papillæ. The crypt of the tonsil is markedly dilated and filled with a horny mass, which merges at various points into the epithelium, though in sections stained with eosin and thionin there seems to be a more or less distinct line where the epithelial cells become keratosed. The living cell has a nucleus which stains with thionin, and its protoplasm is of a purplish color, due to the mixed staining with eosin and thionin. The keratosed material stains only with eosin, and is, therefore, of a bright pink color. Occasionally in the keratoid mass a very faintly stained nucleus is found, indicating that the

material of which the mass consists has been originally derived from epithelial cells.

"According to the mechanical circumstances by which the tonsil is surrounded, the horny mass becomes sooner or later broken up into layers, between which multiply and grow organisms of all varieties. This fraying of the cryptal plug may take place within the crypt itself, so that the resulting fissures permit the bacteria at times to penetrate almost but not quite to the living epithelium. Mytotic figures may be seen in the epithelium at different places, but especially along the border toward the parenchyma of the tonsil. The epithelium is, therefore, in a state of active growth. This eccentric growth, however, which results in the formation of the keratoid plug, is not equally distributed to all parts of the epithelial lining of the tonsillar crypts. Take, for instance,

Fig. 240

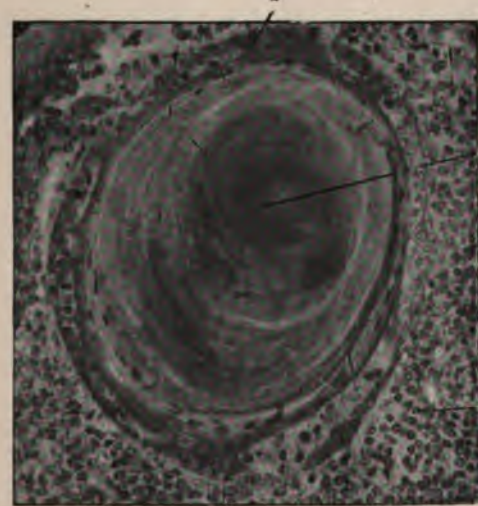

Hyperkeratosis. Cross-section of the terminal portion of a crypt showing the concentric arrangement of the layers of horny material and the epithelium, which is still somewhat disintegrated. *a*, epithelium; *b*, horny material in crypts; *c*, lymphoid tissue. (Wood.)

a single individual crypt: a portion of the epithelium may still persist in its normal condition of partial disintegration without a discernible border line between it and the tonsil parenchyma; in another part the epithelium may exist simply as a barrier of cells with a very thin layer of subepithelial connective tissue, and again in the same crypt we may see the hyperkeratosis in its most beautiful and characteristic appearance.

"This change in the epithelium of the crypts is the characteristic pathological feature of hyperkeratosis. Besides this there are generally other changes in the tonsil. The connective tissue extends from the surface epithelium for some distance down along the crypt. The follicles are small and much less numerous, and the surrounding zone of lymphocytes has become comparatively insignificant. The mitotic

figures in the follicles, though present, are less numerous, and the whole aspect of the organ is one of suppressed activity. We sometimes find, however, signs of local irritation in the immediate neighborhood of the crypts, as evidenced by the outwandering of polymorphonuclear leukocytes from the capillaries and their penetration between the cells of the cryptal epithelium. This irritation is easy to understand when we consider that the crypts contain a large number of saprophytes and probably also pathogenic microörganisms growing actively and receiving their nutriment from the accumulated keratosed cells.

"The toxins elaborated by these organisms must be absorbed to a greater or less extent by the tonsillar tissue. It is probably due to the fact that the cryptal epithelium has become an impact protective barrier that a more noticeable reaction is not a common result."

Hyperkeratosis is a condition peculiar to young adults, and is self-limited, from two to three years being required for it to run its course. Treatment is unnecessary, though if the bony masses cause irritation they may be removed by cauterization. The electrocautery should be used to destroy the bony masses, and the tissues surrounding them should be penetrated until only healthy tissue remains. From three to four masses may be thus treated at sittings one week apart.

CHAPTER XXIII.

THE SURGERY OF THE TONSILS.

It is being more and more recognized that the complete enucleation of the tonsil with its investing capsule is the most satisfactory method of dealing with diseased tonsils. It is true that in a certain number of cases the distressing symptoms yield to less radical measures, as the application of the cautery to the crypts, the incision of the crypts, the removal of the retained debris from the crypts, and the partial removal of the tonsil. I believe that if these cases were observed for a period of five or more years it would be found that the tonsil is still the seat of diseased processes not unlike those present before the operations above named. In addition to the diseased conditions it would also be found that in some instances the tonsil tissue had recurred, oftentimes in greater bulk than before the operation.

If, on the other hand, the tonsil is removed in its entirety with its investing fibrous capsule, the diseased processes in the tonsillar fossa and the tonsillar tissue will never recur. F. E. Hopkins, in a review of the literature since 1856, found several recorded cases of recurrence, chiefly before the year 1870, though instances of recent date were also cited. His conclusion coincides with that of Sir Morrell Mackenzie, Sir Felix Semon, and the author, that recurrence is nearly always due to incomplete removal of the tonsil. D. Braden Kyle expresses the opinion that some cases of apparent recurrence after excision of the tonsil are, in reality, the regrowth of an adenoma, the tonsil having taken on that type of benign neoplastic development. N. L. Wilson says that the complete removal of the tonsil may be followed by an inflammatory process in the tonsillar fossa, but that such processes will not often be found after a period of two years subsequent to the operation. Tuberculous and specific taints no doubt account for some of the recurrences after tonsillotomy.

It seems to me, therefore, after considering all the data obtainable, including my own experience, that many of the conditions heretofore regarded as only calling for cauterization, incision, partial removal, etc., should be operated by the complete method, whereby the entire tonsil with its investing fibrous capsule is removed.

In the following *indications* it should be remembered that they are given with especial reference to the complete operation technically known as tonsillectomy:

(*a*) Nasal catarrh and

(*b*) Ear diseases are sometimes true indications for tonsillectomy. Pynchon says: "In a goodly number of those cases applying for treat-

ment for nasal catarrh, or for ear disease, in which a plainly apparent hypertrophy of the faucial tonsils does not exist, it will be found upon close inspection that there is present a certain degree of faucial fulness which is markedly increased by causing the patient to gag. Among the embellishments of this every-day picture an abnormal faucial redness is observed, gradually increasing in depth of color from the normal pale pink of the lowest point of the pharynx disclosed by the use of the tongue depressor. There will also be observed a tendency for frothy saliva to adhere to the parts." The relationship between nasal catarrh and tonsillar disease does not seem perfectly clear, while that existing between the tonsil and the ear is more apparent, as the palatopharyngeus muscle extends to the pharyngeal orifice to the Eustachian tube, and inflammations of the tonsils and pillars might readily extend along the pharyngo-palatine fold to the mucosa of the tube and thence to the middle ear. Repeated anginas in this region may result in degeneration of the palato-pharyngeal muscle fibers and thus impair the muscular mechanism that controls the patency of the tube. Again, infectious material in inflammations of the tonsils may gain entrance to the tube and middle ear, either during coughing or vomiting, or in extensive inflammations by the destruction of the ciliæ of the epithelium lining of the tube. Ordinarily the ciliæ with their wave-like motion carry the secretions from the middle ear to the epipharynx. When they are destroyed, or their action is inhibited by violent inflammation, the entrance of foreign matter, as bacteria, etc., into the middle ear is comparatively easy. Hence, certain ear diseases having their origin in tonsillar inflammations call for the removal of the tonsils.

(*c*) Recurrent attacks of tonsillitis independent of ear or pharyngeal complications usually justify the enucleation of the tonsils. The operation should not, of course, be done during one of the acute manifestations, as to do so might give rise to severe infection of the wound and deeper structures.

(*d*) By referring to Fig. 234 it will be seen that the tonsils drain into the deep glands of the neck. When these glands are enlarged and tender the tonsils are usually the source of the infection, and if there is a history of repeated glandular involvement the tonsils should be excised.

(*e*) When the crypts of the tonsils are examined and they are found more or less filled with debris and bacteria, tonsillectomy should be considered. If the debris is removed with a tonsil hook or with a tonsil syringe (Fig. 266), the inflammation temporarily disappears, but in most instances it returns. If after repeated trials the inflammation recurs, tonsillectomy is indicated.

(*f*) Laryngitis with attacks of hoarseness is often due to tonsil disease, hence the tonsils should always be examined; and if the crypts are diseased or the tonsils are hypertrophied, the tonsils should be removed.

(*g*) Hypertrophy of the tonsils is an evidence of a diseased process, for in a perfectly normal throat the tonsils are of small size. There is a divergence of opinion upon this point, some writers holding that the tonsil is an organ of the body, while others believe it to be a pathological

entity which, under irritation from constant bacterial infection, becomes enlarged either through hypertrophy or hyperplasia. When thus changed its function as a lymphatic gland is impaired or lost, and the physical economy is best served by its complete ablation.

(*h*) Chronic follicular tonsillitis is an indication for tonsillectomy, as there is little likelihood of curing it by simpler methods. Even if the crypt are closed by the use of the actual cautery, the low vitality of the tissue forms a favorable site for infection and inflammation.

(*i*) Follicular pharyngitis is, according to George Troup Maxwell, often caused by a chronic suppurative follicular tonsillitis. He claims that after the tonsils are removed the follicular pharyngitis disappears.

(*j*) Tuberculous infection often begins in the tonsils, and when such a process is demonstrated or strongly suspected, the tonsils should be enucleated.

(*k*) Recurrent acute articular rheumatism following acute tonsillitis is an indication for tonsillectomy.

TONSIL OPERATIONS.

There are so many methods of operating upon the tonsils for the cure or relief of the morbid conditions affecting them and the neighboring structures and organs, that it is impracticable to attempt to describe all of them. I shall, therefore, select those methods which appeal to me as the most rational from a clinical and surgical standpoint, and which have, after long trial, given the best results. Some of the procedures to be described are not recommended as the best, but under some circumstances they must be resorted to as preliminary or tentative measures. Hemophilia, the reluc ance and refusal of the patient to submit to what seems to be the best method will occasionally lead the surgeon to elect an incomplete method of operating. Hence, both complete and incomplete operative procedures will be described, and their comparative merits stated as fairly as possible.

Complete Tonsil Operations.—By the term "complete tonsil operations," I mean those surgical procedures whereby the faucial tonsil is removed in its entirety with its capsule intact. Clinical observations have clearly shown that any procedure stopping short of this is often followed by little or no permanent improvement in the conditions for which it was done. Numerous cases are on record, and doubtless manyfold more are unrecorded, in which there was a continuation of the pathological processes and even of the recurrence of the tonsillar tissue after an incomplete operation.

As has been stated in a preceding paragraph, even after the complete removal of the tonsil, the sinus tonsillaris is sometimes the seat of an inflammation, but that it rarely persists for more than two years. I can say from a personal experience covering about 1000 cases in which the tonsils were removed in their entirety with the investing capsule intact, that such subsequent inflammations have been exceedingly rare, while recurrence of the tonsillar tissue has never taken place.

On the other hand, I can refer to a larger number of cases in which I did an incomplete operation, or what is known as "clipping the tonsils" with a Mathieu's tonsillotome or other instrument, in which the subsequent tonsillar inflammations occurred comparatively frequently.

It seems, therefore, that the time has come when a text-book should clearly recommend the complete operations upon the tonsils as the ones that should be used if it is at all expedient to do so, and that the incomplete operations should be resorted to only when the peculiar conditions of the patient contraindicate either of the complete methods, or when other circumstances prevent their adoption.

The Author's Complete Operation with Right-angle Knife and Ecraseur.—While every detail in the following technique is not original with me, the operation as a whole has been my own creation, especially with reference to the removal of the entire tonsil with its capsule intact. In most cases the diseased tonsil is composed of three lobes, or masses, each with an investing capsule, the three lobes being held together by a fibrous envelope amounting to a secondary enveloping capsule. For all practical purposes the tonsil may be regarded as one mass with an investing capsule, and as such it may be removed in its entirety.

(*a*) Anesthesia may be either local or general. Personally, I prefer local anesthesia, except in those cases in which, for various reasons, the patient cannot be operated in the conscious state. This is a matter that must be decided by each surgeon, as the personal element enters so largely into its consideration.

Local anesthesia may be induced by swabbing the tonsils and the faucial arches at five minute intervals with an aqueous solution containing 10 per cent. of cocaine and 5 per cent. of carbolic acid. Both ingredients produce blanching and anesthesia. From five to ten applications are usually required to produce complete anesthesia. In some cases a single application of a 20 per cent. solution of cocaine should be applied. A more frequent use of the 20 per cent. solution is quite liable to produce toxic results.

Robert E. Moss called my attention to the hypodermic injection of 4 per cent. cocaine in a 1 to 2000 solution of adrenalin (first published by Heitzmann) as a speedy and satisfactory method of inducing local anesthesia in the tonsillar region. I have used it with great satisfaction in a large number of cases.

The solution is made by adding 4 per cent. of cocaine to a 1 to 2000 solution of adrenalin.

The solution should be injected into the tissues surrounding the tonsil rather than into the tonsil itself. For instance, it should be injected at the upper, middle, and lower portions of both anterior and posterior pillars respectively, and just above the supratonsillar space. About 1 minim of the solution should be injected at each point. Street's syringe (Fig. 241) is well adapted to the purpose.

Anesthesia is thus immediate and the operation may be performed at once. After the first tonsil is removed prepare the other in the same manner.

The adrenalin usually prevents severe hemorrhage during the operation and lessens the cocaine toxemia.

The position of the patient is a matter of some importance. Under local anesthesia the upright position in the operating chair should be used. Under general anesthesia the patient is placed upon the operating table, with his head either over the end of the table in the Rose position, or upon his side (Fig. 209), according to the preference of the surgeon. A mouth gag (Fig. 210) should be used if a general anesthetic is given.

Fig. 241

Street's tonsil hypodermic syringe.

In the further description of the technique I will assume that the patient is conscious and in the upright position.

(*b*) Seize the tonsil with the vulsellum forceps (Fig. 242), one prong tip being placed in the supratonsillar fossa, and the other at the base of the tonsil. When they are thus placed they should be pushed deep into the tissues, closed and locked. In this way they engage the fibrous capsule or deep surface of the tonsil, and will not tear loose except in young children when traction is made.

When the blades are closed the bulk of the tonsil lies between the shanks of the instrument, as shown in Fig. 243. This has a distinct advantage over a superficial grasp of the tonsil, as it enables the surgeon to dissect around it with greater ease. It also enables the operator to bring the posterior pillar into easy access of the tonsil knife.

Fig. 242

The author's tonsil forceps.

(*c*) Dissect the anterior pillar from the tonsil and carry the incision above the margosupratonsillaris, or the supratonsillar space, to the posterior pillar (Fig. 243). The aim should be to dissect around the upper half of the tonsil, removing the mucous membrane forming the roof or dome of the supratonsillar fossa. These details are important if it is the intention to remove the tonsil with its fibrous capsule intact. The incision thus assumes the form of an inverted U. The instrument

used is the Kyle right-angle tonsil knife shown in Fig. 244. It should be hooked into the mucosa at the junction of the anterior pillar with the plica triangularis. It is then pulled toward the median line of he throat, thus severing the pillar from the plica triangularis and the tonsil.

FIG. 243

The tonsil is grasped with the author's vulsellum tonsil forceps, the upper prong tips being placed in the supratonsillar fossa, and the lower prong tips at the base of the tonsil; thus grasped the tonsil is drawn toward the median line of the fauces preparatory to removal by dissection.

Re-introduce the hook blade into the incision thus made and engage it as before, and pull toward the median line. Two or three such cuts are required to bring the incision above the supratonsillar fossa. While the foregoing incision is being made the tonsil is in the grasp of the vulsellum forceps, and it is pulled forcibly toward the median line. This puts the pillar upon the stretch and greatly facilitates its separation from the tonsil with the hook knife.

The posterior pillar should next be separated in much the same manner. This pillar is not as accessible as the anterior one, but it can

FIG. 244

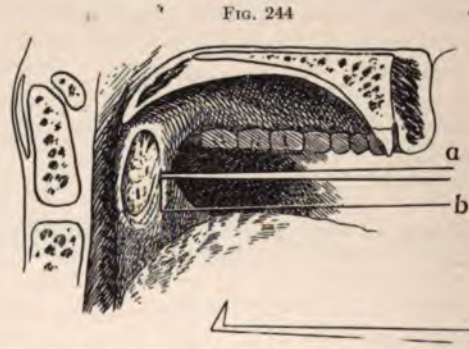

The primary incision being made with the right-angle crypt knife. The knife is introduced through the mucous membrane at the junction of the anterior pillar, and the plica triangularis upon being pulled forward makes the incision *b;* the knife is again introduced through the incision as shown (*a*) in the illustration. The incision is thus completed by three or four cuts with the knife.

be brought into view by rotating the handle of the vulsellum forceps, thereby turning the tonsil upon its lateral axis in such a way as to bring

the posterior pillar forward, where it is readily accessible to the hook knife (Fig. 245).

FIG. 245

Showing the direction of the posterior pillar from the tonsil with the right-angle knife. The tonsil is turned forward upon its lateral axis with the author's vulsellum forceps to bring the pillar upon the upper surface, where it is accessible to the knife.

The two incisions should be united above the margo-supratonsillaris. Observe carefully the margin of mucous membrane forming the roof of the supratonsillar space and make the incision just above it.

The combined incisions are thus converted into a U-shaped incision.

(*d*) Again seize the tonsil with the vulsellum forceps, with the upper prong tip introduced into the supratonsillar portion of the incision and the lower prong tip at the base of the tonsil. The tonsil is thus well within the grasp of the forceps and is ready for the dissection with the hook knife.

FIG. 246



The tonsil in the process of dissection with Kyle's crypt knife. During the dissection the tonsil is forcibly drawn toward the median line of the fauces with the author's vulsellum tonsil forceps.

(*e*) Pull the tonsil toward the median line, thereby putting the fibers attaching it to the superior constrictor muscle upon a tension. With the hook knife sever the fibrous bands (Fig. 246), following the external contour of the tonsil to its inferior portion. It is rarely necessary

to dry the wound during the operation, providing the cocaine-adrenalin solution is injected. If anesthesia has been induced by brushing the tonsil with cocaine there may be considerable hemorrhage.

Fig. 247



The author's tonsil ecraseur, a substitute for the snare.

Fig. 248

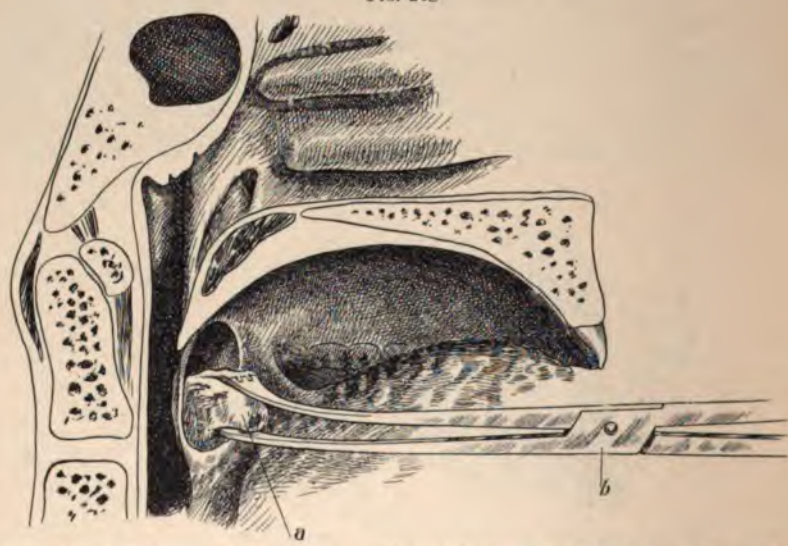

The tonsil *a* in the grasp of the author's tonsil forceps *b;* the upper half of the tonsil *a* has been enucleated by dissection with the capsule intact.

(*f*) At this stage of the operation the use of the knife may be abandoned and the author's ecraseur tonsillotome substituted (Fig. 247) to complete the operation This shortens the time of operation, though it may be completed with the knife.

(*d*) Pass the forceps through the ring blade of the ecraseur and seize the tonsil, then pass the ecraseur over the tonsil as shown in Figs. 248 and 249. Close the instrument and thus complete the operation. The dull ring blade of the ecraseur readily passes behind the tough fibrous capsule of the tonsil and makes a clean dissection of its lower portion.

FIG. 249

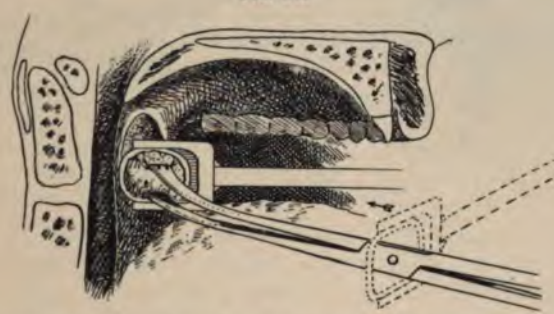

The final step of the tonsillectomy as performed with the author's tonsil ecraseur, a substitute for the tonsil snare.

The wire snare, on the contrary, tends to cut through the capsule and leave the lower portion of the tonsil *in situ*.

If hemorrhage follows the operation, it may be controlled by swabbing the sinus tonsillaris with a solution of the permanganate of potash, $\frac{1}{8}$ to 1 grain to the ounce of water. The peroxide of hydrogen may also be used for the same purpose. Stronger remedies are rarely required. Continuous gargling with iced water often controls it. Tonsil clamp forceps (Figs. 250 and 251) need rarely be used.

FIG. 250

Pynchon's tonsil hemostat.

General Remarks.—The operation is performed under cocaine anesthesia in adults, injections being made as described in Fig. 252. The Kyle knife should be very sharp. If dull, it cuts with such hesitancy

that it is very disagreeable to the patient. In making the primary incision the tonsil should be grasped with the forceps, one blade being in the supratonsillar fossa and the other at its base. The handles of the

Fig. 251

Boetcher's tonsil hemostat.

Fig. 252

Schema showing the points of injection of adrenalin and cocaine solution preliminary to the removal of the tonsil with its capsule intact. About 2 minims of the solution is injected at each point.

forceps should then be closed and locked. The tonsil is then drawn toward the median line of the fauces during the dissection. The tension thus exerted renders the mucous membrane taut, and the dissection easy. In making the incision at the upper portion of the posterior pillar (Fig. 245), the tonsil should be twisted forward and downward on its horizontal axis to bring the posterior pillar into easy access of the knife.

The advantage of the author's tonsil ecraseur over the tonsil snare is, that it is always ready for use, whereas the wire of the snare needs adjustment each time it is used. When two tonsils are to be removed, the wire for the snare must either be straightened or another one inserted before the second tonsil can be removed. This is not true of the ecraseur, as it is always ready for use, like an ordinary tonsillotome. The edge of the fenestrated blade is round, thus conforming to the cutting surface of a wire. (Sharp blades are also furnished with the instrument.) If there is less hemorrhage following dull dissection, the ecraseur meets this requirement. The same is true of the cold-wire snare. After many dissections with the ecraseur, I have rarely known it to fail to complete the dissection of the tonsil with its capsule intact.

This method of removing the tonsil with its capsule intact, while not based upon as good surgical technique as the author's method with a scalpel, is easier to perform by the average operator than the dissection with the scalpel. Personally, I prefer the scalpel dissection, because I can do it in much less time, with less hemorrhage, and less discomfort

Fig. 253

The author's tonsil knife.

to the patient. I also prefer the scalpel dissection, because I believe the wound after a clean dissection with a sharp knife heals more kindly and quickly than the wound left after a dull dissection.

Tonsillectomy with a Scalpel.—The Author's Operation.—After having tried almost every known method of removing the tonsils, the simplest of all instruments has been found to be the best adapted for the purpose. A common scalpel (Fig. 253), such as is used in making the mastoid and abdominal incisions, is the instrument now used in all cases. The only other instrument required is the vulsellum forceps (Fig. 242). A tongue depressor is not used, as the forceps crosses the tongue and keeps it out of the way.

Fig. 254



The first incision in the removal of the tonsil with its capsule intact. The tonsil is drawn forward and medianward from the sinus tonsillaris. The incision is extended, as shown in Fig. 255, a very sharp scalpel being required for the purpose.

Technique.—(*a*) Anesthesia by the injection of the cocaine-adrenalin solution (Fig. 252).

(*b*) Seize the tonsil with vulsellum forceps, one blade in the supratonsillar fossa, the other at its base, as in the preceding method. Pull

the tonsil medianward and forward to dislodge the anterior shoulder from beneath the anterior pillar. This pulls the posterior margin of the pillar forward and facilitates the introduction of the scalpel between it and the tonsil.

(*c*) Introduce the blade of the scalpel to a depth of about one-half inch between the anterior pillar and the tonsil at the junction of the pillar and plica tonsillaris (Fig. 254). Sweep the blade upward to the margo-supratonsillaris, and thence over the margo-supratonsillaris to the posterior pillar (Fig. 255). The knife should be very sharp for this purpose. This completely severs the tonsil from the anterior pillar and exposes the outer aspect of it to further dissection. By including the

Fig. 255

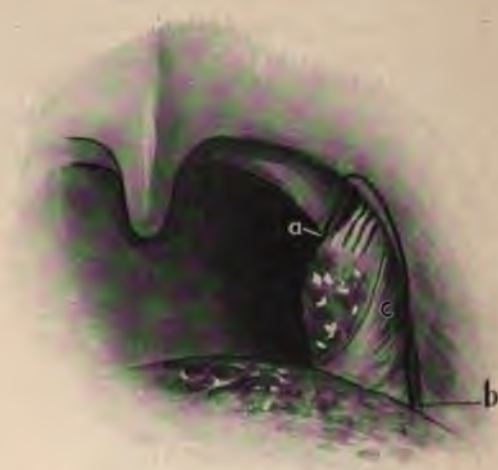

The author's operation for the removal of the tonsils with its capsule intact. *a b*, the line of incision beginning at *b*, at the junction of the anterior pillar and the plica tonsillaris (*c*) and extending upward to the upper lobe of the tonsil, thence forward so as to include the margo-supratonsillaris to *a*. The incision of the margosupratonsillaris liberates the upper or velar lobe of the tonsil and greatly simplifies the operation.

margo-supratonsillaris in the incision (the blade being in the tissues to the depth of about one-quarter inch) the upper portion of the tonsil concealed in the supratonsillar fossa is freed from its attachments. If this step of the operation is not observed, the dissection is more difficult.

(*d*) Continue to pull upon the tonsil with the forceps, and its capsule may be seen through the incision. Then introduce the knife through the upper part of the incision and hug the tonsil capsule and sever it from its attachment to the superior constrictor muscle, as shown in Fig. 256. The branches of the tonsillar artery are severed in this step of the operation. They are small and do not often give rise to troublesome hemorrhage. If, however, some of the fibers of the superior constrictor muscle are accidentally removed, the main stem of the artery is

severed and the hemorrhage may be severe. If the hemorrhage is severe, the bleeding points should be seized with artery forceps.

(*e*) Disengage the vulsellum forceps from the tonsil and place one prong tip into the anterior aspect of the wound the other over the inner

FIG. 256

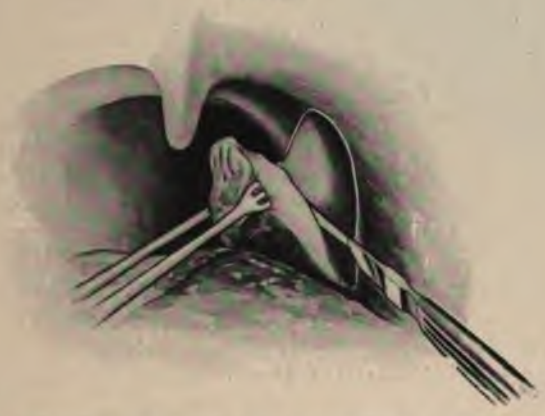

The tonsil being separated from the bed of the sinus tonsillaris, to which it is loosely attached, the capsule is hugged with the author's scalpel, care being exercised to avoid injuring the superior constrictor muscle which forms the bed of the sinus tonsillaris.

aspect of the tonsil, and close them upon the tonsil (Fig. 257). Tract the anterior border of the tonsil toward the median line of the throat, using the posterior pillar as a hinge.

(*f*) Then, having rendered the posterior pillar accessible, shave it free from the posterior border of the tonsil with the scalpel (Fig. 253). Great care should be taken to avoid injury to the muscular tissue of either

FIG. 257



The tonsil is drawn toward the median line of the throat to expose the posterior pillar to the knife. The pillar is incised to the bottom of the tonsil at its junction with the tonsil.

the anterior or posterior pillars during the dissection. If the muscles are not injured, there is little liability to hemorrhage from these regions, as the artery is within the muscular substance of the pillars.

(*g*) The tonsil is now only attacked at its inferior portion. While still pulling the tonsil toward the median line of the throat complete the dissection by cutting downward and inward. The tonsil is thus removed with its capsule intact. The first incision separates the anterior pillar and the plica supratonsillaris from the anterior and superior surfaces of the tonsil. The second separates the outer surface of the tonsil from the superior constrictor muscle of the pharynx. The third separates the posterior pillar from the corresponding border of the tonsil. The fifth incision completes the dissection by freeing the inferior attachment of the tonsil from the pharyngeal wall.

Since adopting this method of operating I have seen no alarming hemorrhages except in one instance, in which I injured some fibers of the superior constrictor muscle of the pharynx. The hemorrhage was primary and was easily controlled by a solution of permanganate of potash ($\frac{1}{8}$ gr. to the ounce of water).

The Complete Removal of the Tonsil with the Capsule Left in Situ.—Some operators (Robert C. Myles, Geo. B. Wood, and others) prefer to leave the capsule of the tonsil in the sinus tonsillaris, as they believe there is less liability to severe infection of the wound following the operation.

Fig. 258

Tonsillotome.

They also believe the hemorrhage to be less profuse. While I agree with these views, I have hesitated to advocate this method of tonsillectomy, because I fear the average practitioner would fail to remove all of the substance and crypts of the tonsil. If he would remove all of the parenchyma of the tonsil, including every vestige of the walls of the crypts, I would commend this method of tonsillectomy above all others. The temptation seems to be inherent in the operator to declare that what he has done has been complete, and all that could be desired, even though the work is but poorly or incompletely done. If I can sufficiently emphasize the importance of the total ablation of the substance of the tonsil, including the walls of the crypts, the bottoms of which lie in apposition with the buried capsule of the tonsil, I am ready to advocate this method of removing the tonsil.

Technique.—(*a*) Cocaine anesthesia, as shown in Fig. 252.

(*b*) Remove as much of the tonsil with the tonsillotome (Fig. 258) as possible.

(*c*) Remove the remaining substance of the tonsil with the Myles, the Reault, the Rhodes, or other models of tonsil punch forceps (Fig. 259). From time to time during the operation search for remnants of the crypts with a blunt probe (Wood). When they are found, remove more tissue

with the tonsil forceps or a sharp curette, and so continue until the crypts are totally obliterated.

Casselberry called attention to the advantage of dividing the mucous membrane along the margo-supratonsillaris. He claimed that this procedure rendered the liberation of the velar lobe, or supratonsillar portion of the tonsil, much easier and more certain. Without knowing of Casselberry's recommendation, I arrived at the same conclusion, though my technique is quite different from his.

By my method the mucous membrane is divided at the junction of the plica triangularis and the anterior pillar, and the incision is then extended along the margo-supratonsillaris to the posterior pillar, as shown in Fig. 255. If this preliminary incision is thus made, the subsequent steps of the operation will be more easily accomplished; indeed, the dissection of the tonsil is nearly consummated by this procedure alone.

Robertson's Operation.—Robertson's method of removing the tonsil is as follows: (*a*) General anesthesia preferred.

Fig. 259

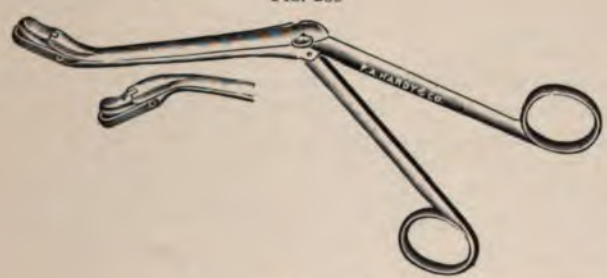

Myles' tonsil punch forceps.

(*b*) The anterior and posterior pillars are first separated from the tonsil with a curved double-edged knife, or, if the pillar is adherent, with his pillar scissors.

(*c*) The tonsil is then grasped with forceps and pulled forward and inward, the scissors pushing the pillars back out of the way. The scissors are then closed and the tonsil removed by a series of cuts (Figs. 260 and 261). The tonsil upon the opposite side shows the position of the tonsil before it was pulled from its sinus.

This operation may also be performed under local anesthesia, as in the author's method. It may also be removed in its entirety with its capsule intact by this method. The tonsil scissors are made in pairs to adapt them to either tonsil. This method of removing the tonsils is thorough and commendable. The prime question in reference to any tonsil operation is in reference to its completeness.

Pynchon's Cautery Dissection Operation.—According to Pynchon, this method of removing the tonsil in its entirety possesses the advantages of (*a*) but slight or no primary hemorrhage, and (*b*) the sealing of the wound by the eschar, thus preventing severe infection of the wound.

Technique.—(*a*) Local anesthesia is induced by repeated swabbings with a 10 per cent. solution of cocaine, ending with a 20 per cent.

Fig. 260

Robertson's tonsil scissors. The scissors come in pairs.

solution. To each solution of cocaine should be added one-half as much carbolic acid as cocaine. If preferred, the anesthesia may be induced by injection of cocaine and adrenalin.

(*b*) Seize the tonsil with mouse-toothed forceps at about the central portion and pull it inward and backward, thus putting the plica tonsillaris and the anterior pillar upon a tension. This renders the anterior border of the tonsil easily discernible.

Fig. 261

The removal of the tonsil with Robertson's scissors.

(*c*) With a nearly straight cautery electrode at a cherry-red heat puncture the membrane at the junction of the anterior pillar and the plica tonsillaris about one-third the distance from the top of the tonsil, and dissect downward to the tongue. Then dissect upward over the

margo-supratronsillaris and a little way down the posterior junction of the tonsil and pillar (Fig. 262). In other words, make the incision shown in Fig. 255.

(*d*) With a nearly right-angle electrode (Fig. 262) complete the dissection of the posterior pillar from the tonsil.

(*e*) Pull the top of the tonsil inward and downward, and dissect it, with the electrode, from its attachment to the superior constrictor muscle, thus freeing it from the sinus tonsillaris.

(*f*) The remaining pedicle, at the base of the tonsil, is severed by stretching it over the heated electrode.

(*g*) Only one tonsil is removed at a sitting, the remaining tonsil being removed in about two weeks, or after the first tonsil wound has healed.

(*h*) Applications of a 20 to 30 per cent. aqueous solution of the nitrate of silver may be made from time to time during the operation to check oozing hemorrhage.

Fig. 262

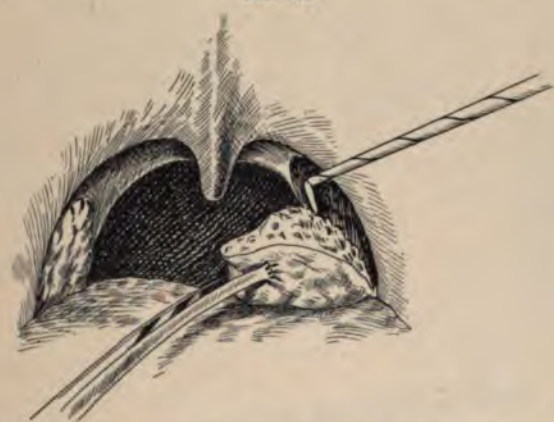

The removal of the tonsil by cautery dissection by Pynchon's method.

(*i*) The after-treatment should consist in the use of alkaline and aromatic gargles and the daily application of the following mixture:

℞—Tr. iron,
Glycerin . . . . . ãã ʒj

The above mixture should be rubbed into the wound with a cotton-wound applicator to prevent infection and exuberant granulations. The wound should heal with a smooth surface and without the formation of cicatricial bands. If the muscular tissue of the pillars is injured, contracture and disagreeable deformity of the fauces may result.

Tonsillotomy.—The author has elsewhere expressed his views as to the propriety of removing a portion of the tonsil, but inasmuch as it is a time-honored procedure, and is likely for various reasons to be practised in the future, it will be described in this chapter.

Technique.—(*a*) The operation may be done under either local cocaine anesthesia or general anesthesia.

(*b*) If the subject is an infant or a young child, and the operation is to be performed under either local or nitrous oxide gas or bromide of ethyl anesthesia, he should be held in the lap of an assistant.

Fig. 263



Tongue depressor.

He should be wrapped in a sheet tightly pinned around his body and arms, while his head should be grasped by the assistant's left arm and hand. The legs of the assistant should be crossed over those of the child to prevent struggling during the operation. If a general anesthetic is administered, one arm should be left exposed to test the pulse and the muscular reflexes.

(*c*) A mouth gag may or may not be used according to the discretion of the operator.

(*d*) Depress the tongue with a tongue depressor (Fig. 263) to expose the tonsil to full view.

Fig. 264

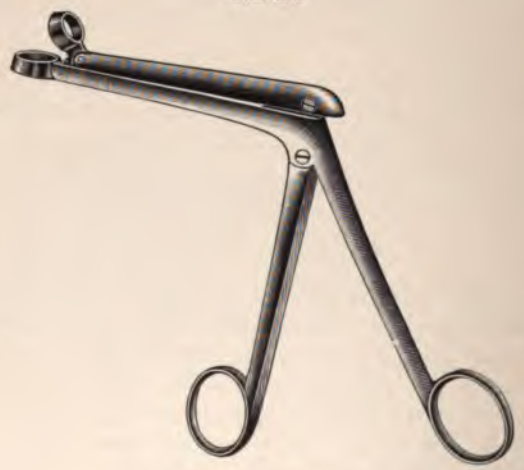

Farlow's tonsil punch

(*e*) Introduce the tonsillotome into the mouth of the child, place the ring blade over the tonsil, and forcibly push it outward, and at the same time move the ring blade up and down to engage the tonsil.

(*f*) When the tonsil protrudes through the ring blade close the instrument and thus cut off as much of the tonsil as happens to protrude through it.

It occasionally happens that all of the tonsil with its capsule intact is removed by this method of operating. More often only a portion of the tonsil is removed. The upper portion of the tonsil is often quite inaccessible to the ring knife, and as this usually contains the more diseased crypts the operation is but partially effective.

The remaining portions of the tonsil may be removed with punch forceps, preferably of the Reault, Farlow, or Rhoades type, as shown in Fig. 264.

The Complications and Sequelæ of Tonsil Operations.—Inasmuch as the tonsillectomy is, or should be, performed as often in adults as in children, the question of post-operative hemorrhage and of infection becomes an important one. In children hemorrhage and infection of a severe type are rare, whereas in adults they are much more common, on account of the larger development of the vessels and the greater abundance of fibrous connective tissue, which offers less resistance to microbic infection.

Fig. 265

Showing the bleeding points after adult tonsillectomy. *a*, the anterior pillar; *b*, the tonsillar plexus of veins at the inferior portion of the sinus tonsillaris; *c*, the central portion of the sinus tonsillaris, where the tonsillar artery enters the tonsil; *d*, the posterior pillar. *c* represents the most common site of hemorrhage (see page 374).

Hemorrhage.—(See Fig. 265 and page 374.)

Infection.—The infection following tonsil operations is usually more severe and prolonged in adults than in children. In children the temperature is elevated one-half to two degrees for two to five days, whereas in adults it is often more highly elevated for from two days to a week or more. The soreness in children is usually limited to three or four days, while in adults it often continues longer. If the infection was only thus manifested it would be a matter of small importance. Unfortunately, it is occasionally so severe as to be alarming, even to the point of actual danger to life itself. While I have never seen a case result in death, I have seen a few assume alarming symptoms. That is, I have seen two cases in about 5000 tonsil operations in which the hemorrhage was so prolonged that marked anemia and exhaustion resulted, and two of severe sepsis from streptococcus infection.

If the cases with secondary hemorrhage had been operated in the hospital, the bleeding could have been more quickly controlled and the danger averted.

In one of the septic cases the removal of the tonsils was done by partial dissection and completed with a snare, whereas in the other case the dissection was done with a sharp scalpel. In the latter case the infection was the more severe of the two, a fact which apparently controverts my previous statement that a clean-cut dissection is less apt to be followed by infection than a dull-cut or crushing dissection with a snare. In spite of the apparent discrepancy between this statement and the result in the case referred to, I wish to reaffirm my previous statement that dissection with a sharp instrument is less liable to be followed by severe secondary infection than one made with dull-cutting or crushing instruments. Another factor which must be taken into account is the virulence of the infective microörganism causing the infection. If a virulent type of streptococcus is the infective agent, the resulting infection and sepsis will be severe, no matter what method of dissection is used. Crushed tissue is less resistant than tissue cut with a sharp instrument, hence it is more readily infected, though either may be the seat of infection. The whole question is one of the microörganism on one side, and of the tone or resistance of the tissues on the other. If the resistance of the tissue is normal and the virulence of the microörganism is great, infection will follow. If the resistance of the tissue is low and the virulence of the microörganism is low, there may or may not be infection, according to the balance or imbalance existing between the resistance of the tissues and the virulence of the infecting microörganism. It follows, therefore, that the question of infection is not wholly dependent upon whether the dissection is performed with blunt or with sharp instruments, but that the general tone of the tissues previous to the operation, the local tone as affected by either blunt or sharp instruments, and the virulence of the invading microörganism each has its influence in determining the severity of the infection and the resulting sepsis.

An analytical statement of the chief factors influencing the severity of the infection and sepsis following the removal of tonsils in adults is as follows:

1. The general tone of the cellular and fluid tissues of the body.
2. The local tone as influenced by local disease and by the character of the dissection (dull or sharp).
3. The virulence of the microörganism.

The practical deductions to be drawn from the foregoing analysis are as follows:

1. If the patient's vital forces are low, tonics and fresh air should be prescribed for some time before the operation. It is true that it is not often advisable to delay the removal of the tonsil until the general tone of the system is elevated, as the tonsils may be the direct cause of the lowered vitality of the patient, and should be removed to stop the toxemia. Under such circumstances the risk of the infection and sepsis must be assumed, and such measures adopted as will avert or minimize the intensity of the two processes.

2. The resistance of the tissues is influenced by the previous local disease, and by the character of the dissection. The local changes due to

previous disease of the tonsil cannot, perhaps, be eliminated, and, in so far as this factor is concerned the operation must be performed in spite of it. In so far as the tone of the local structures is affected by the character of the dissection, this is entirely under the control of the operator. He can avoid the use of crushing instruments by substituting sharp ones. While this precaution will not always prevent infection and sepsis, it will reduce the number and severity of the infection.

3. The virulence of the local microörganisms present in the throat may be determined before the operation by the adoption of the routine practice of making cultures from the tonsils. This is not always practicable, but when it is it should be done. Another way of arriving at much the same result is to carefully inspect the tonsil, especially the crypts in the supratonsillar fossa and those covered by the plica triangularis, and note the local signs of irritation and inflammation, especially redness of the mucous membrane. Still further information may be obtained by questioning the patient as to the presence of soreness or pricking upon swallowing. If these signs are present, it is wise to defer the operation until the crypts are cleaned out and the local irritation and inflammation have subsided.

There is a possibility of severe infection following the removal of tonsils, even in cases in which there is no apparent inflammation. Virulent germs may be lodged in the bottom of the crypts without giving rise to obvious symptoms. Close inquiry might elicit the statement that the patient has a slight soreness upon swallowing, a sensation of pricking. In one such case in the author's practice a most violent and obstinate infection occurred. The patient, a rhinologist, came for the removal of his tonsils, and inasmuch as I presumed he knew whether his throat was in a proper condition for the operation, the tonsils were removed. After the occurrence of the infection he told me that he had been suffering for a week from a slight soreness or pricking in the throat. These facts all go to show that the surgeon should not presume anything, even though the patient is supposedly well informed concerning his condition. All cases should be subjected to close scrutiny by the surgeon before performing an operation.

Should the examination show such soreness to be present, the operation should not be performed. The crypts of the tonsils should be cleansed of all debris by syringing (Fig. 266) with a warm normal salt solution. A curved cotton applicator moistened with the tincture of iodine should be introduced into each crypt to allay any infection and inflammation present in them. Treatment thus carried out for one week will usually prepare the tonsils so that the operation may be performed without the danger of infection of tonsillar origin. It is urged, therefore, that surgeons should always prepare the tonsils for operation, just as he would in any other part of the body. The same rule should be applied to the nose, throat, and larynx, even though these regions are not susceptible to absolute surgical cleanliness. The breeding or incubating foci can at least be gotten rid of. Since the exceptional experience referred to in the preceding paragraph, the author has made it a routine practice

to thoroughly irrigate the crypts of the tonsils before operating, and if obvious signs of infection and inflammation are present the tonsils have been subjected to treatment for at least one week before removing the tonsils.

Is Tonsillectomy a Hospital Operation?—In young children it is not necessarily a hospital operation, as it is rarely followed by either severe hemorrhage or sepsis. In adults it should be a hospital operation, on account of the possible hemorrhage and sepsis.

A prominent surgeon has said that the tonsil is of greater clinical importance than the appendix; that it causes more suffering and more deaths. If this is true, and I believe it is, the tonsil is worthy of the most serious and painstaking study.

Fig. 266

The author's tonsil syringe.

The technique of its removal should receive the same careful and patient attention that has been devoted to the removal of the vermiform appendix. In view of the importance of the tonsil from a clinical standpoint, and in view of the possible complications and sequelæ following its removal, tonsillectomy should be regarded as a hospital operation. If performed in a hospital the danger from primary or secondary hemorrhage is largely eliminated, and infection and sepsis may be diminished in severity and in the frequency of their occurrence.

CHAPTER XXIV.

NEOPLASMS OF THE TONSIL.

BENIGN NEOPLASMS OF THE TONSILS.

BENIGN tumors do not occur as often in the tonsils as they do elsewhere in the pharynx. Of the variety found in this region, papilloma is the most common.

Papilloma.—Papilloma is more often multiple than single, and presents the general outlines of a bunch of grapes. If single and large it may be mistaken for a supernumerary tonsil. Like all papillomata it has a tendency to return, and is sometimes converted into malignant epithelioma. It should, therefore, be removed by clean surgical excision, rather than by a crude crushing method, as with a snare or dull forceps. It should be borne in mind that the transition from a benign papilloma to a malignant epithelioma is, histologically, rather easy. The epithelial growth in the papilloma is outward, whereas in epithelioma it is inward. There are, of course, other histological differences. The structural arrangements are, however, so similar as to warrant a certain amount of caution and discretion in their diagnosis and surgical treatment.

In some instances there may be one pedicle with many individual papillomata attached, whereas in others there may be many pedicles.

The growths, as a rule, give rise to no marked symptoms. A slight hacking cough, a tickling sensation, and the feeling of a foreign body in the faucial region is complained of. The only change noted in the surrounding tonsillar tissue is an increased hyperemia around the attachment of the tumor. Pain is never present. The tumors vary in size from a pea to that of an enlarged tonsil.

Lipoma.—Lipoma of the tonsil is rare, though Atkinson, Farlow, Ingalls, and others have reported cases. They are fatty tumors, and are innocent.

Angioma.—Angioma of the tonsil is also quite rare. Flatau, Phillips, Bosworth, Keimer, and others have reported a few cases.

Treatment.—The treatment is preferably by electrolysis, the positive pole being applied by means of gold-plated needles thrust into the neoplasm. The current strength should vary from 5 to 25 ma., and should be applied for from two to twenty-five minutes at each seance. Repeat the applications once or twice a week until the vascular growth is obliterated.

Fibroma.—Fibroma of the tonsil is a benign neoplasm next in frequency of occurrence to papilloma. It very rarely becomes malignant. Its growth is very slow, and is usually limited to one tonsil. Delevan

and others have suggested that fibrous tumors of the tonsils may be mistaken for supernumerary tonsils. This is especially true if the supernumerary tonsil acquires its fibrous tissue from the degenerative changes due to a constant irritation from its exposed position in the fauces. Technically it is a fibroplastic fibroma. Some claim it is only a fibroma which happens to incorporate some of the lymphoid tissue in pushing out from the tonsil.

Etiology.—Fibroma of the tonsil occurs equally often in each sex, and perhaps more often in the young than in middle and advanced age.

Pathology.—Fibroma is usually somewhat pedunculated, though it may be sessile. The larger the fibroma the larger the pedicle. They are more often single than multiple. Being of connective tissue of mesoblastic origin, it must of necessity have its origin from the trabeculæ of the tonsil. Occasionally it undergoes cystic degeneration. Usually it is firm and scantily supplied with vascular structures. It is composed of white fibrous tissue, the cells often being matted together, closely simulating embryonic connective-tissue cells.

Symptoms.—Annoying symptoms are seldom present, except in the large pedunculated type, when it produces mechanical obstruction. Its presence is not accompanied by discharge. It is characterized by symptoms similar to those of enlarged or hypertrophied tonsils.

Diagnosis.—The diagnosis is usually easily made, and in case of doubt a portion should be excised and submitted to microscopic examination.

Treatment.—The treatment is purely surgical and consists in its removal, a procedure easily accomplished if the growth is pedunculated. Occasionally it may be adherent to the tonsil or to the neighboring structures as a result of repeated inflammations of the tonsil.

Surgical Technique.—(*a*) Cocainize the growth and the area around the point of attachment with a 10 per cent. solution of cocaine by repeated swabbings.

(*b*) Separate the points of adhesion with a scalpel or scissors.

(*c*) Pass a cold-wire snare around the tumor, engaging it at its pedicle, or point of attachment.

(*d*) Sever the pedicle by closing the wire loop.

(*e*) Cauterize the stump of the pedicle, and if it penetrates the tonsillar tissue, dissect it to its point of origin.

(*f*) Frequent cleansing with some antiseptic gargle should be practised for about one week, or until healing takes place.

(*g*) Instead of using the wire snare as given in (*c*), the growth may be seized with the vulsellum or other toothed forceps and dissected with a scalpel from its attachment to the tonsil.

Fibro-enchondroma.—A few cases have been described, and notable among them is that of Cosolini, which was as large as an orange and was readily enucleated. Grosvenor reports one case.

Cystoma.—Cystoma of the tonsil is rare. It may be either superficially or deeply situated. Virchow reports having found them postmortem. I have occasionally found them of small size when enucleating

hypertrophied tonsils. They vary in size, and may contain a quantity of fluid or a mass of inspissated secretions and epithelial debris.

They give rise to no peculiar symptoms other than those usually present in enlarged tonsils.

They may be eradicated by freely incising them with a bistoury and curetting the lining membrane, and then swabbing the cavity with pure carbolic acid to excite reactionary inflammation and agglutination of their opposed walls. A still better method of treatment is to enucleate the tonsil as described under Tonsillectomy.

Lymphadenoma in Hodgkin's Disease.—In every case of Hodgkin's disease it is advisable to examine the tonsils, as they may be the seat of a lymphadenoma such as is present in other parts of the body. In the early stage of the disease it may be impossible to positively assert that the tonsils are involved, though they may appear abnormally enlarged. In the author's case the tonsils did not appear to be enlarged. By keeping the case under observation their growth may become apparent, and when it occurs is quite significant. Lymphadenoma of the tonsil is only a local expression of a disseminated lesion of a similar nature throughout the general lymphatic system. In my case the tonsils were not apparently involved, though the neck glands were enormously enlarged. The case improved markedly under the application of the Röntgen rays.

MALIGNANT NEOPLASMS OF THE TONSILS.

Carcinoma of the Throat.—According to some authorities carcinoma is more frequently found in the tonsils than sarcoma, while others hold the reverse to be true. More than 100 cases have been recorded, and according to Bosworth it occurs once in every 2000 cases of carcinoma in all parts of the body. It is a disease of middle and advanced age, though J. D. Bryant reports a case occurring in a patient aged seventeen years. Sarcoma may occur at any age, but more often in early life. The youngest case coming under my observation occurred at the eighteenth month. Cases of sarcoma have been reported as late as the eightieth year. The average age at which carcinoma appears is about the fifty-second year.

Carcinoma of the tonsil is more malignant than sarcoma because of the histopathological predominance of glandular epithelium. It is rarely primary, but is usually secondary to carcinoma of the tongue or pillars of the fauces. It is usually characterized by a squamous and spindle cell epithelium. It does not attain the large size of sarcoma of the tonsils, but it involves the neighboring lymphatic glands at an earlier period.

Symptoms of Carcinoma.—Early ulceration, a fetid breath, more or less pain of a lancinating character, emaciation, and cachexia are the usual symptoms. Before ulceration the secretions are of a heavy mucous nature, while after ulceration they are often purulent in character. Slight hemorrhage is a frequent symptom. It may, however, in exceptional

cases, be very profuse and cause death. Edema of the glottis is frequently present; indeed, one might say it is an almost constant concomitant complication of carcinoma of the tonsil in the advanced stage.

Pain is always aggravated during the act of swallowing, and the voice is either hoarse or aphonic. Secondary glandular involvement is an early feature (Fig. 234). The subjective symptoms are very little different from those of sarcoma of the same region, except in the advanced stage, when ulceration and pain are present.

Diagnosis.—Carcinoma of the tonsil is a disease of middle and advanced life, while sarcoma more often occurs in the young. Ulceration occurs early in carcinoma and later in sarcoma; carcinoma is nodular, while sarcoma is smooth and round. Carcinoma has a fleshy pink hue and is often fungoid, while sarcoma is blue in color and is crossed by rather large arteries.

When in the state of ulceration carcinoma may be mistaken for syphilis, particularly if the adjacent glands are not much involved.

The progress of the case and the administration of the iodides will soon clear the diagnosis.

The pain in carcinoma is lancinating and sharp, while it is dull and periodic in sarcoma.

Papilloma is painless, pedunculated, seldom ulcerates, and secondary involvements by direct extension of metastases do not occur. There are no constitutional symptoms, and the growth is multiple and presents the appearance of a bunch of grapes.

Fibroma of the tonsil has a constricted base, grows very slowly, is free from pain and glandular involvement, and does not recur when removed.

A microscopic examination of the tissue should be made in differentiating the various types of tumors.

DIFFERENTIAL DIAGNOSIS OF SARCOMA AND CARCINOMA OF THE FAUCIAL TONSILS.

Sarcoma.	*Carcinoma.*
1. Any age, most often after fifteen.	1. Not in early life, usually after forty.
2. Frequently primary.	2. Rarely primary.
3. Glandular involvement late.	3. Glandular involvement early.
4. Frequently encapsulated.	4. Not encapsulated.
5. Vascular, hemorrhages, ulcerates early.	5. Not so vascular, scant hemorrhage, ulcerates late.
	6. Frequent in males.

Treatment.—The treatment of carcinoma and sarcoma of the tonsil is palliative and surgical, though in most cases the latter affords little encouragement.

EXTIRPATION OF THE TONSIL BY THE EXTERNAL ROUTE.

In malignant disease of the tonsils where the surrounding tissues have become involved it may become necessary to remove the tonsil by the external route, or von Langenbeck's method.

Technique.—(*a*) General anesthetic.

(*b*) The external incision is in the form of a U, thus making a tongue-shaped flap (Figs. 267 and 268). The flap thus made lies immediately over the ascending ramus of the lower jaw. This portion of the jaw is to be temporarily resected, so as to expose the tonsil region to operation.

(*c*) The external maxillary artery (facial) is ligated to control the hemorrhage.

(*d*) The periosteum corresponding to the anterior incision should be divided preparatory to sawing through the bone.

Fig. 267

Fig. 268

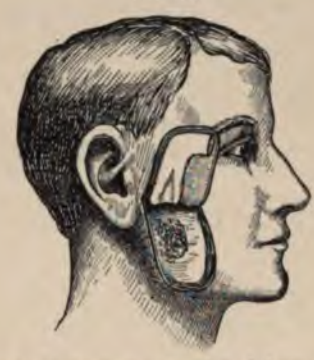

Fig. 267.—U-shaped incision preliminary to the temporary or permanent resection of the ramus of the lower jaw for malignant disease of the tonsil.

Fig. 268.—The temporary resection of the ramus of the inferior maxilla to expose the fauces in the removal of malignant tumor of the tonsil.

(*e*) The jaw bone is sawed through along the line of the periosteal incision just in front of the insertion of the masseter muscle.

(*f*) The connective-tissue attachments of the ascending ramus of the jaw on its inner surface are then carefully dissected from the bone, care being exercised to avoid injuring the muscles of mastication.

(*g*) The ascending ramus of the jaw is then lifted outward and upward, thereby exposing the region of the tumor to view (Fig. 268).

(*h*) The tumor is then exposed by dissection. The external carotid artery lies externally and posteriorly.

(*i*) The tumor should be removed with the knife and scissors, care being exercised to avoid opening into the cavity of the mouth until the last moment, so as to keep the secretions from entering the wound.

(*j*) The ascending ramus of the jaw is then returned to its normal position and sutured with wire.

(*k*) The skin is then sutured with horsehair or with Harris' buried suture.

(*l*) The wound is dressed through the mouth, healing taking place by granulation, as after an ordinary tonsillectomy.

PART III.

DISEASES OF THE LARYNX.

CHAPTER XXV.

INFLAMMATORY DISEASES OF THE LARYNX AND EPIGLOTTIS.

ACUTE INFECTIOUS EPIGLOTTITIS.

Synonyms.—Angina epiglottidea anterior (Michel); acute infectious epiglottitis (Theisen).

The disease is often primary, and is an acute infectious process. Clement F. Theisen reports three cases, and gives a most admirable review of the literature on the subject. Michel, in 1878, first described an inflammatory process, involving the anterior sufrace of the epiglottis, under this name. It is usually accompanied by more or less circumscribed edema. While the larynx may be somewhat involved in some cases, Theisen claims that true angina epiglottidea occurs quite often as a primary, separate, distinct condition.

Etiology.—In the diffuse type of inflammation the epiglottis may become inflamed by an extension from acute tonsillitis, pharyngitis, or lingual tonsillitis. In the true primary type its origin is not thus explained. In the cases reported by Theisen there was no history of coryza, or other acute infectious condition of the upper respiratory tract. The larynx was but slightly involved. The ages of the patients were thirty-six, forty, and fifty-nine years respectively, one male and two females. Hajek's experiments show that the submucosa of the anterior surface of the epiglottis is abundant and the mucosa loosely adherent, while on the laryngeal surface it is tightly adherent to the cartilage except at the nodules, where there is some loose submucous tissue. These anatomical facts explain why the edema does not extend to the larynx, as one might at first expect it would do. In excessive edema it may, however, extend to the larynx by way of the submucous tissue of the pharyngo-epiglottic ligament, thence to the aryepiglottic folds. Injury to the epiglottis or the neighboring tissue by swallowing foreign bodies or irritating substances may cause the condition. Hot drinks, raw spirits, or highly spiced liquids may also be regarded as possible predisposing etiological factors. In edema of the fauces due to large doses of

the iodide of potash the epiglottis may become involved. The infectiou fevers are also liable to give rise to this distressing condition.

Perichondritis, carcinoma, and ulcerative conditions due to syphilis or tuberculosis may suddenly become complicated by it.

Bacteriological examinations made in 2 of Theisen's cases showed Streptococcus aureus and pneumococcus in 1, and Staphylococcus albus and pneumococcus in the other. The atrium of infection in some instances seems to be a traumatic wound, in others it is an extension of an acute inflammation from contiguous anatomical parts, and in a third class it is a malignant tuberculous or syphilitic ulcer. The chief cause, then, is a mixed infection, which may or may not be preceded by a gross lesion of the anterior surface of the epiglottis.

Pathology.—From what has been given under Etiology and Symptomatology, it may be inferred that the pathology is such as is common to acute inflammation of mucous membranes covering loose submucous tissue. This consists of inflammatory congestion, exudation, and edema, which processes, in typical cases, are limited to the anterior surface of the epiglottis. The bacteriological infection is usually the pneumococcus with the Streptococcus aureus or the Staphylococcus albus.

Symptoms.—The onset is sudden and attended by fever, painful deglutition, stiff swollen tongue, and dyspnea, especially upon lying down. In one case reported by Theisen the latter symptom was so pronounced as to necessitate propping the patient up in bed.

The febrile symptoms are similar to infectious fevers in general.

Upon examination the anterior surface of the epiglottis is red and swollen, while the adjacent tissues are usually, but little, if at all, involved. These symptoms continue with more or less severity for five or six days, when they abate in intensity, the epiglottis remaining red and swollen a few days longer.

Diagnosis.—If certain characteristic symptoms are born in mind, there need be but little difficulty in arriving at a correct diagnosis. These symptoms are: (*a*) Sudden onset. (*b*) A febrile movement. (*c*) Redness and swelling limited to the anterior or lingual surface of the epiglottis. (*d*) More or less painful deglutition.

Acute angioneurotic edema is unattended by fever, and the edematous tissue is pearly gray instead of red.

It should be differentiated from acute miasmatic epiglottitis, which follows exposure to salt marshes, as in hunting for ducks on the mud flats of the California coast. Arnold has described this condition in Burnett's system on the *Nose, Throat, and Ear.* (See Acute Miasmatic Epiglottitis.)

Prognosis.—The prognosis in most cases is good, although deaths have been reported by Tompkins, Louis, Gibb, Crisp, and Fredet. Proper treatment exerts a favorable influence upon its course.

Treatment.—Early scarification of the edematous parts gives prompt relief in some instances. It should be done freely. Meyjer recommends the use of iced ichthyol sprays, which are prepared by putting cracked ice into the spray tube containing the ichthyol solution Theisen

speaks of using a ½ per cent. solution of ichthyol every twenty to thirty minutes while the acute symptoms continue, and at longer intervals afterward. It is important to give early relief, as the patient may not be able to swallow even liquid food until it is done. Calomel and salines may be given advantageously at the onset.

The physician should be prepared to do tracheotomy at any moment, as suffocative symptoms may suddenly develop.

MIASMATIC EPIGLOTTITIS.

Arnold, in Burnett's *System*, describes an acute inflammatory process chiefly involving the epiglottis. It is attended by pronounced edema of the epiglottis, painful swallowing (odynophagia), and dyspnea.

Etiology.—He attributes the cause "to some animal, vegetable, or chemical poison in the exhalations of the salt marshes." He describes six cases, all men who had returned from hunting ducks on the mud flats of the salt marshes on the California coast. It is probable that the cases were due to an infection (probably mixed) from some nidus of propagation in the marsh country along the coast. Whether the cases should stand apart as illustrative of a separate and distinct disease is perhaps doubtful.

Symptoms.—Epiglottic edema and inflammation may be pronounced, the adjacent structures also being somewhat involved. There is odynophagia and dyspnea. In one case the suffocative symptoms became so alarming that tracheotomy was performed. Pyrexia is more or less marked.

MALARIAL EPIGLOTTITIS AND LARYNGITIS.

There appears to be a type of laryngitis due to malarial poisoning. The adjacent anatomical structures, including the epiglottis, are somewhat red and slightly swollen. There is pyrexia of an intermittent type, as one might expect in malarial poisoning. Hoarseness and dyspnea are prominent symptoms.

The bromide of quinine should be administered in full doses in malarial poisoning attended by laryngeal symptoms. Iced sprays of a 0.5 per cent. solution of ichthyol will hasten a favorable issue, as there is probably also some coccus infection in these cases.

ACUTE CATARRHAL LARYNGITIS.

Synonyms.—Catarrhal laryngitis; acute catarrh of the larynx; simple laryngitis; laryngitis catarrhalis acuta.

Acute catarrhal laryngitis is an acute catarrhal inflammation of the laryngeal mucosa and of the vocal cords. It is characterized by hoarseness or aphonia, and pain upon phonation.

Etiology.—The etiology of acute catarrhal laryngitis may be studied under: (1) Systemic disturbances and diseases; (2) preëxisting diseases of the upper respiratory tract; (3) hygienic conditions and environment; (4) traumatism; (5) age; (6) climate; (7) idiopathic causes.

1. **Systemic Disturbances.**—Systemic disturbances, as "catching cold," arthritis, the eruptive specific fevers, syphilis, and tuberculosis, play an important role in the causation of catarrhal inflammations of the larynx. "Catching cold" is a complex process difficult to explain, but in general it may be said to include an imbalance of the vasomotor nerves, whereby the capillary vessels are erratically controlled. Increased vascularity, or congestion, is thus a common disturbance. According to Woakes and J. A. Stucky, the phenomena of "catching cold" are due to digestive disturbances and the end results therefrom, *e. g.*, toxic products in the circulation, which irritate the vasomotor nerves, thus establishing a predisposition to "catching cold." Clinical observation seems to support the above theory in so far that acute laryngitis quite often follows or accompanies digestive disorders. Arthritis also seems to have a causative relation to laryngitis, and, inasmuch as it is an inflammatory disease of infectious origin, it is easy to appreciate the fact that certain toxins are in the circulation and affect the tonicity of the vasomotor system, very much as in acute coryza, or "catching cold." The toxins of syphilis and tuberculosis likewise irritate and disturb the vocal apparatus. In addition, the pathological lesions are often localized in the larynx, and are specific in character. The exanthematous or eruptive fevers are often accompanied or followed by laryngitis. The specific microörganisms peculiar to these diseases are especially profuse in the upper respiratory tract; indeed, they probably gain entrance to the system through the mucosa of the nose and throat when the resistance is lowered, especially in the tonsil and adenoid; hence, the mucosa of the larynx is subjected to the direct irritation from their presence, as well as to the toxins in the blood.

2. **Preëxisting Diseases.**—Preëxisting diseases of the upper respiratory tract are important predisposing etiological factors in laryngitis. This is especially true in reference to sinus diseases, nasal stenosis, and infectious inflammations of the tonsils. It may be stated as an axiom that *inflammatory processes in one part of the upper respiratory tract tend to extend to contiguous parts.* This is in part explained by the extension by continuity of tissue, and in part by the simultaneous exposure of the various structures to microbic and toxic irritation. The most vulnerable area is first affected, the contiguous parts later becoming involved. The tendency is for the inflammatory process to extend downward rather than upward, probably because the flow of lymph streams is in that direction. It is true, however, that there is a marked hesitancy in the downward extension from the nose to the larynx. This is explained by the difference in the character of the epithelium covering the mesopharynx. Nearly the whole of the mucosa of the upper respiratory tract, except the mesopharynx, is covered with ciliated columnar epithelium, whereas the mesopharynx is covered with squamous epithelium. Inflammatory

processes do not readily extend from one kind of tissue to another, hence the hesitancy. If, however, the nasal inflammation is severe and prolonged, or often repeated, the inflammation finally reaches the larynx. Indeed, the "dropping" into the hypopharynx often leads to catarrhal inflammation of the larynx by lowering the resistance of the laryngeal mucosa, which subsequently becomes infected. In sphenoidal and posterior ethmoidal sinuitis the secretion and the exudate are discharged into the epipharynx and drop or trickle down the walls of the mesopharynx on the upper surface of the larynx, irritating the mucosa. The mucous membrane of the larynx becomes lowered in resistance, and infection and inflammation follow. In obstructive deflections of the septum the respiratory functions of the nose, namely, moistening, warming, and filtering the air, are lost. The pharyngeal and the laryngeal mucosa are, therefore, subjected to an air that is irritating to it. This in time causes lowered resistance, infection, and laryngitis.

We may say, then, in a general way, that diseases of the respiratory tract above the larynx often predispose to catarrhal inflammations of the larynx by (*a*) extension by continuity of tissue; (*b*) extension by contiguity of tissue; (*c*) extension by lymphatic communication; (*d*) by irritation and lowered resistance from nasal and accessory sinus secretions; (*e*) simultaneous exposure of the entire upper respiratory tract to microbic infection; and (*f*) by the irritation from the toxins evolved by the bacteria in the nose, the accessory sinuses, the epipharynx, and the tonsils. *The chief barrier to the downward inflammatory extension is in the squamous epithelium of the mesopharynx.*

3. **Hygienic Conditions and Environment.**—Under hygienic conditions and environment as causative agents in catarrhal laryngitis are included (*a*) the inhalation of noxious gases; (*b*) poor ventilation; (*c*) undue exposure of feet and body; (*d*) improper bathing; and (*e*) the abuse of the voice.

The inhalation of noxious gases, as in chemical laboratories, factories, etc., may cause laryngitis by direct irritation, or it may lower the resistance of the tissues and predispose to infection. Poor ventilation likewise causes laryngitis, though not by direct irritation. In the latter instance the vital energy is lowered by breathing impure air. Then, too, the oxygen in the air is diminished in quantity. The vitiated atmosphere irritates the endothelial lining of the air vesicles, and thereby causes changes which interfere with the absorption of oxygen into the blood and the expulsion of carbonic acid gas from the blood. These factors combine to deprive the patient of the normal amount of oxygen, and lead to an oversupply of carbonic acid gas. The processes of metabolism are thus deranged, and toxemia results. The vital energies are lowered, and the patient is in prime condition to be affected by bacterial infection and inflammation. Undue exposure of the body, especially the feet, is a prolific exciting cause of laryngeal inflammation. The large vessels of the feet give off large quantities of heat when the soles of the feet are insufficiently protected from the cold ground. When this occurs there is a shock to the terminal vascular system, which causes an imbalance of the physiological functions of the more delicate structures of the body.

The larynx in some cases is the vulnerable point, and reacts in the form of a catarrhal laryngitis. The question of clothing is discussed more fully under the etiology of the nasal inflammations. Suffice it to say, therefore, in this connection that there is danger in an excessive amount of clothing, as well as in too little. One accustomed to living in an open, poorly constructed residence, and changing to a well-built city residence, which is overheated and poorly ventilated, is especially subject to catarrhal inflammations of the upper air passages.

Bathing, when judiciously practised, is a healthful and invigorating procedure. When, on the contrary, it is injudiciously practised, it may cause considerable mischief to the upper respiratory tract. What is good practice for one may be bad for another. Hard-and-fast rules cannot be laid down. For some a cold plunge or shower bath after a warm bath is invigorating, whilst for others it throws them into a mild state of shock from which they do not quickly react. A Turkish bath is often a harmful procedure unless the bather remains for some hours in rooms of gradually diminishing temperature. Hyperemia of the superficial vessels is induced, and if the bather goes out into the open air before the circulatory balance is restored, he is liable to "catch cold." The abuse of the vocal apparatus in singing and speaking disturbs the circulatory poise, and by mechanical irritation excites inflammation of the cords and the mucous membrane. For a further consideration the reader is referred to the chapter on the Speaking and Singing Voice.

Pathology.—The histological changes in acute catarrhal laryngitis are the same as in inflammations of the mucosa of other portions of the upper respiratory tract. The peripheral vessels are congested and the tissues are infiltrated with round cells and leukocytes. If the inflammation runs a short course the infiltration disappears, leaving little or no trace of its occurrence. Should the inflammation be phlegmonous, the tissues become edematous and the surface epithelium eroded in patches. The secretions at first are thin and scanty, later becoming heavier and more profuse. In severe cases the secretions may become purulent and streaked with blood from the superficial follicular ulcers. The pathology of laryngitis secondary to the exanthematous fevers does not differ from ordinary laryngitis except as to the microörganisms causing the disease and the greater tendency to phlegmonous inflammation. The greatest swelling in laryngitis is naturally in the most lax parts, namely, in the ventricles, though the true cords are sometimes red and swollen like sausages. In children the swelling is sometimes below the cords, and is a source of extreme danger.

Symptoms.—Objective Symptoms.—The objective symptoms embrace the changed appearance of the cords, the mucosa, the secretions, the exudate, and pathogenic bacteria. With the laryngeal mirror and reflected light an inverted image of the larynx is shown. The mucosa is red and more or less swollen from hyperemia and infiltration, or edema, according to the virulency of the inflammatory process. The cords are pinkish red, or even as red as the mucosa. Sometimes ecchymotic spots of extravasated blood may be seen on their upper surfaces,

or free borders. The secretions are at first thin and scanty; later they become thick, semitranslucent, or opaque, according to the amount of lymphocytes thrown out. The secretions have a tendency to accumulate at the anterior commissure and to some extent along the cords. They appear as opaque plugs rather than as thin, diffused, glairy masses.

When follicular ulcers are present the denuded areas appear as slightly roughened red spots, or, if covered with secretions, as whitish opaque ones. In some cases there is a cloudy swelling of the epithelium in isolated areas. These areas are the beginnings of ulcerations. They appear as slightly elevated patches, with a grayish semitranslucent covering. Hemorrhages may occur at the commissure of the cords, or on the ventricular bands. At first the site of the hemorrhage is red, later almost black. When the inflammation is severe the venous flow may be blocked so that the parts are edematous. This condition is sometimes termed hydrops laryngis. The temperature varies from a slight elevation to one of several degrees, according to the severity of the inflammation and the virulency of the microörganisms contributing to the phenomena. The paralysis or paresis of the intrinsic muscles of the larynx, which sometimes occurs, may be due to a neurosis, though it is more often due to a mechanical interference by infiltration and degeneration of the muscles and the tissues immediately surrounding the nerve endings.

Subjective Symptoms.—The subjective symptoms have reference to the changes in voice and respiration, and to pain and cough. The voice may be hoarse in any degree, or aphonia may be present. The hoarseness is due to the swelling and infiltration of the cords and adjacent mucous membrane, and to the paresis or paralysis of the muscles. The respiratory effort may be slightly labored, on account of the diminished lumen of the chink of the glottis, or to the paresis or paralysis of the abductor muscles.

In those cases complicated by excessive edema the respiration may be labored because of the edematous swelling. The respiration is shallow on account of the cough excited by deep breathing. The character of the cough depends largely upon the individual, though it bears some relationship to the stage and intensity of the disease. In the early stage it is usually soft and husky, whereas later it is more heavy and harsh. In those cases in which there is extensive infiltration and edema it is spasmodic, hoarse, and wheezy, with but little tonal quality. If the inflammation is limited to the interarytenoid space, hoarseness may be absent.

Prognosis.—The prognosis depends somewhat upon the primary cause, that is, whether it is due to a chronic constitutional disease, like syphilis, or to a simple exposure which causes temporary lowered resistance of the tissues. If due to the former, the prognosis as to the voice is bad. If to the latter, it is good. If the attack is primary, it is good. If it is one of a series of acute attacks, the chances are in favor of its recurrence, as the etiology is evidently a fixed factor. Again, the prognosis depends largely upon the character of treatment administered. It is obvious that if the cause is a nasal obstruction from septal malformation, the

prognosis will depend upon the treatment instituted. If due to nasal disease, and sprays, lozenges, and medicated nebulæ are used, the prognosis is bad. If the nasal disease is corrected by suitable treatment or an operation, the prognosis is good. Finally, and perhaps of more importance than all other considerations, the prognosis depends upon whether complete rest of the vocal apparatus is observed. If this is done for from three to ten days, the simple catarrhal inflammation will subside, leaving the voice clear.

Treatment.—The successful treatment of the immediate symptoms consists largely in *giving the voice complete rest.* Without this all other methods are usually futile and the inflammation runs its full course. Confine the patient to his room, the temperature of which should be maintained at from 67° to 70°. The atmosphere should be surcharged with steam from boiling water to which turpentine and creosote have been added. Keep the bowels open with calomel and salines. Place the feet in a hot mustard bath, after which hot lemonade should be administered. Then wrap the patient in a woollen blanket and put him to bed. Still further relaxation may be induced by the administration of effervescing tablets of pilocarpine, $\frac{1}{100}$ of a grain. One tablet should be given every hour until three or four are taken. The inhalation of steam impregnated with the compound tincture of benzoin, one teaspoonful to the pint of boiling water, affords relief, and should be used every two to three hours. Kyle recommends the following prescription:

℞.—Acidi nitrici . . . . . ♏ iij (0.18)
Tr. opii deodorati . . . . . ♏ iij (0.18)
Cocaini phenati . . . . . gr. $^1/_{10}$ (0.006) M.
Sig.—Give every hour until three or four doses are taken.

An ice-bag applied to the neck exerts a favorable influence in the phlegmonous variety, though it should not be applied longer than a few minutes at a time. A compress of cold water applied over the larynx beneath a flannel bandage also relieves the laryngitis, as it induces hyperemia and leukocytosis just as when heat is applied. It is an open question as to whether the relief is due to the compress *per se* or to the constriction of the bandage, according to Bier's principle. The constriction also increases the local leukocytosis and thus frees the inflamed tissues of the infectious agents and dead tissue cells. Whether the good results are due to the water compress or to the constriction the effects are favorable. An oily spray of menthol, 1 to 2 grs. to the ounce, is a pleasant application, affording temporary relief. Its frequent use, however, irritates the mucous membrane, hence it should not be used oftener than twice a day.

In severe cases in which there is considerable obstruction to the breathing it may be necessary to puncture the swollen laryngeal mucosa with a laryngeal knife (Fig. 269). The serous fluid in the edematous membrane is thus let out without serious damage to the parts, and in addition the reaction of inflammation is promoted and the bacteria more rapidly destroyed. In extreme cases it may become necessary to intubate or to perform tracheotomy. (See Intubation and Tracheotomy.)

In infants the danger in acute laryngitis is much greater than in adults, on account of the relatively smaller and absolutely occluded chink of the glottis. Then, too, the mucosa is much more richly supplied with lymphatic and bloodvessels and is more loosely attached to the deeper structures. For these reasons the mucosa is more prone to become swollen or edematous and cause suffocation. A fatal issue is possible.

For the relief of the cough, codeine sulphate, gr. $\frac{1}{12}$ to $\frac{1}{8}$, may be administered every three hours until relief is afforded.

Fig. 269

Laryngeal lancet.

In the later stage (after the second week) it may be advisable to touch the inflamed cords with the solid stick of nitrate of silver. This should be done but once. In the milder cases the larynx may be painted with a 2 to 4 per cent. solution of the nitrate of silver.

The principles of treatment are: (*a*) Absolute rest of the voice, the patient remaining in a warm room containing steam vapor. (*b*) Free purgation to promote the elimination of the toxins and ferments, and (*c*) relaxation of the peripheral vessels of the body by the administration of pilocarpine and hot drinks. (*d*) Diaphoresis, aided by wrapping in warm blankets. (*e*) The relief of cough by the use of codeine or other sedatives. (*f*) Scarification, intubation, or tracheotomy in threatened suffocation. (*g*) Caustic and astringent applications in the late stage.

ACUTE LARYNGITIS IN CHILDREN.

Synonyms.—Pseudocroup; false croup; Miller's asthma; laryngitis stridulosa.

In children acute laryngitis is often characterized by a spasmodic, croupy, or barking cough and suffocative fits. The subjective symptoms are quite like those of tracheal diphtheria, hence the name pseudocroup. Histologically it is a true catarrhal process.

Etiology.—The etiology of catarrhal laryngitis in children is in general like that occurring in adults, though many of the exciting causes are absent, on account of the different habits of the child or infant. The special etiology in children consists of the presence of adenoids and the epipharyngitis accompanying them, and in the different anatomical construction of the larynx. In children the chink of the glottis is both

relatively and absolutely smaller, the lymphatic and vascular structures are more abundant, and the mucosa is more loosely attached to the underlying tissues. All these factors predispose the larynx of the child to attacks of laryngitis; they also render the disease a much more serious one on account of the suffocative phenomena. In addition to the foregoing facts should be added the greater susceptibility of children on account of the unstable condition of the nervous system and glandular tissues. A moderate amount of swelling of the mucosa, either above or below the true cords, to which is added an irritation of the terminal motor nerve filaments, is often sufficient to bring on severe and alarming fits of dyspnea and suffocation, even to the point of death.

The disease in children may be divided into two varieties, namely, (*a*) acute supraglottic laryngitis, and (*b*) subglottic laryngitis, or Miller's asthma.

The symptoms of acute supraglottic laryngitis more nearly resemble the adult type, though in many cases the spasmodic suffocative fits are present on account of the extreme swelling and edema of the mucosa and the paresis of the abductor muscles.

The subglottic variety is more dangerous on account of the swollen mucous membrane being confined at its circumference by the cartilaginous rings of the trachea. The swelling must, perforce, encroach upon the lumen of the trachea, and close the breathway.

Symptoms.—The objective symptoms are about the same as in the adult. (See Acute Catarrhal Laryngitis.) The subjective symptoms are somewhat different on account of the greater swelling and the smaller lumen of the chink of the glottis. The prodromal symptoms are those of cold, the respiration becoming embarrassed toward evening. A dry cough appears before bedtime, but is not severe enough to prevent sleep. Toward midnight the child is suddenly seized with a laryngeal spasm and embarrassed breathing. The cough is loud and harsh. Inspiration is difficult and accompanied by stridor. The child becomes cyanotic, and death seems imminent. After a few minutes the symptoms disappear and the child falls asleep. The following night, and perhaps for two nights, the attack returns with diminishing severity, until after a few days all signs of the disease disappear. In these cases there is a true spasm of the muscles of the larynx, probably due to the natural hypersensitiveness of the nervous system in infants and growing children. In the subglottic variety the swollen mucosa beneath the true cords may be seen through the chink of the glottis as beefy-red bands. These cases closely resemble tracheal diphtheria in their subjective symptoms, though an inspection of the larynx and a microscopic examination of the secretion and exudate will clear the diagnosis.

Diagnosis.—Acute laryngitis in children should be differentiated from diphtheria, pseudomembranous croup, laryngismus stridulus, foreign bodies, and perichondritis.

Diphtheria is characterized objectively by a membranous deposit, which may be seen upon laryngoscopic examination. It may be either on the laryngeal mucosa or in the trachea, or both. Cultures show the

diphtheria bacilli. In acute laryngitis there is an absence of the false membrane and the bacilli, while the mucosa is greatly swollen and reddened. If it is of the subglottic variety, the swollen red mucous membrane may appear as round, reddened cords, parallel with and below the true cords. The temperature is usually higher in acute laryngitis in children than in true diphtheria, while the prostration is not so pronounced.

Pseudomembranous croup has a sudden onset, while acute laryngitis begins with the symptoms of a cold. In pseudomembranous croup the suffocative symptoms make steady progress with little or no remission. The laryngoscopic image in pseudomembranous croup shows the presence of the membrane, whereas in acute laryngitis the mucosa is red and swollen. The Klebs-Loeffler bacilli are absent in both diseases. The systemic disturbance is less marked and not so severe. There are no nocturnal exacerbations, as there are in acute laryngitis with the laryngismus stridulus phenomena superimposed.

Foreign bodies in the larynx are differentiated by the history of the accident, the sudden onset of the suffocative symptoms with no prodromal history, and the image of the foreign body in the larynx.

Perichondritis of the cricoid cartilage is characterized by irregular nodules in this region and the chronicity of the case. It is usually associated with a tuberculous process in the lungs.

Prognosis.—The prognosis of acute laryngitis in children is favorable in most cases, though a fatal termination is possible, especially in the subglottic variety. The disease runs its course in from six to twelve days.

Treatment.—Prophylactic measures should be instituted in those cases in which there is a history of recurrent attacks. A child subject to laryngitis with pulmonary complications, as bronchitis, should have the tone of the system built up by daily cold sponge baths, followed by brisk rubbing with a towel until the skin glows. During the summer he should be kept in the open air and sunshine as much as possible. At night the room should be well ventilated. The food should be nutritious, easily digested, and liberal in quantity. The clothing should be of linen mesh next to the skin all the year round. In the winter light woollen underwear should be worn over the linen mesh. If there are adenoids or diseased tonsils, they should be removed. If suppurative rhinitis is present it should receive appropriate treatment. All other ailments should be corrected as nearly as possible. In short, all disorders should be attended to and a healthful vigor established as soon as possible. In this way laryngeal inflammation may be prevented.

In the beginning of the acute attack the bowels should be unloaded by the administration of broken doses of calomel, followed by a saline cathartic. During the acute stage the child should be confined in a room kept at a temperature of about 70°, and the atmosphere surcharged with steam. The feet should be placed in hot mustard-water for fifteen minutes, after which the patient should be wrapped in a woollen blanket and put to bed, to encourage diaphoresis. If there is much

mucus in the throat and trachea, an emetic should be administered. If the secretions are scanty or tenacious, the inhalation of menthol vapor from a nebulizer, or from the crystals in boiling water, stimulates the secretions and gives marked relief.

External application of an ice-bag or a cold compress to the neck often affords relief. The ice-bag should be covered with woollen cloth and left in position for only a few minutes at a time. Counterirritation to the neck with iodine, camphorated oil, kerosene, etc., is used to relieve the swelling when it is pronounced, and to promote the reaction of inflammation.

In the *later stage* paregoric, Dover's powder, codeine, etc., may be administered in small doses to relieve the cough. If the secretions are heavy and accumulate in the larynx and trachea, an emetic should be given to clear it away.

Surgical interference may be necessary when the symptoms become alarming. If, upon laryngoscopic examination, the mucous membrane above the cords is found to be greatly swollen, it should be punctured with a laryngeal lancet (Fig. 269). Or if the cyanosis is marked and does not yield to other methods of treatment, intubation or tracheotomy should be performed to save the child's life. (See Intubation and Tracheotomy.) These extreme measures are rarely necessary, but it is well to recognize that in children this disease is sometimes attended by death unless the breathing is maintained by medicinal, hygienic, or surgical interference.

ACUTE PHLEGMONOUS LARYNGITIS.

Definition.—Acute phlegmonous laryngitis is a catarrhal inflammation of the laryngeal mucosa, to which is added an edematous effusion which runs an inflammatory course, for example, serous, seropurulent, and purulent stages. The mucous membrane becomes undermined with purulent secretion.

Etiology.—The causes of this variety of laryngitis are about the same as in acute catarrhal laryngitis, except that the infection is more virulent. The disease is common among hospital attendants, on account of their exposure to erysipelas and other infectious diseases. It is rarely primary, but is usually secondary to some other infectious disease. It occurs most frequently between the twentieth and the fortieth years of life.

Pathology.—The pathology is the same as in inflammatory edema of mucous membranes elsewhere in the body. The mucous and submucous tissue are infiltrated with round cells, and there is an effusion of serum and pus corpuscles. On account of the loose texture of the mucous membrane in the aryepiglottic region, the ventricular bands, and the subglottic region, there is a great swelling and respiratory obstruction, as in acute laryngitis of children. There is at first a vascular engorgement, followed by a serous effusion. Later the effusion takes on a seropurulent and finally a purulent character. General sepsis may follow, and prove a serious complication.

Symptoms.—The symptoms during the first twenty-four hours are about the same as in the acute catarrhal variety. A chill and elevation of temperature are often the initial symptoms. The symptoms gradually grow worse, and dyspnea often occurs within the first twenty-four hours. Pain and soreness are usually complained of. Cough may or may not be present.

Objectively, the laryngoscopic mirror shows the mucous membrane to be red, tense, and glassy, with three rounded, swollen masses above the chink of the glottis. If the subglottic region is involved, the swollen membrane may be seen protecting from below the true cords.

Prognosis.—The prognosis is grave on account of the rapid development and the septic infection. If, however, the dyspnea persists longer than thirty-six hours without severe sepsis or other untoward complication, the case will probably end in spontaneous resolution. The cases should be watched closely during the first thirty-six hours.

Treatment.—The treatment consists in local depletion with ice-bags, followed by the use of leeches and scarification. The ice-bag should be applied for forty minutes, after which three or four leeches, two on either side, should be applied to the skin over the larynx. The cold reduces the swelling and thus establishes a more rapid flow of blood through the inflamed tissues, and the leeches bring about an increased leukocytosis. The cellular resistance is increased by the greater amount of blood flowing through the tissues. The various reactions produced by the cold and leeches establish ideal conditions for the destruction of the infectious microörganisms. The administration of calomel and salines promote the elimination of the toxins. The atmosphere of the room should be kept surcharged with steam. If scarification is resorted to, the laryngeal lancet (Fig. 269) should be used by the aid of the laryngeal mirror and reflected light, or by direct laryngoscopy. The swollen mucous membrane should be repeatedly punctured rather than scarified, as the damage to the parts is less and the relief is equally great. The chief benefit of scarification is in the increased leukocytosis excited by it. It may be necessary to resort to tracheotomy should suffocation become imminent. If sepsis is a pronounced complication, the administration of alcoholic beverages and strychnine is indicated to support the system.

MEMBRANOUS LARYNGITIS.

Synonyms.—Croup; croupous laryngitis; häutige bräune; diphtheritic laryngitis; pseudomembranous croup; idiopathic membranous croup.

Definition.—Membranous laryngitis is characterized by an inflammation of the larynx, attended by the formation of a false membrane of non-diphtheritic origin. Opinions differ as to the unity or duality of this disease and true diphtheria. The evidence, however, seems to show that they are two diseases, the latter being due to an infection from the Klebs-Loeffler bacillus, while the former (croup) is due to an infection

from other microörganisms, usually the cocci, or to a caustic irritant. When due to the latter the membrane is not of microbic origin, though it may become so secondarily. Under the microscope it presents the same appearance as that due to cocci.

Etiology.—The causes of membranous laryngitis are microbic, chemical, and mechanical irritants. Exposure to damp and cold, and neuroses are predisposing causes in young children. The cases of microbic origin usually follow or attend scarlet fever, measles, smallpox, etc. Exposure to damp and cold seems to precipitate attacks by lowering the vital resistance, and thus establishing a suitable soil for the bacterial growth. Chemical and mechanical irritants seem to cause the membranous formation without bacterial influence, although this is not certain. Some children seem to have a predisposition to a membranous inflammation of the larynx, though in these cases I suspect adenoids and epipharyngitis may be the explanation of the susceptibility. It is essentially a disease of young childhood, occurring chiefly between the ages of two and eight. It is most prevalent in the pneumonia or winter season.

Pathology.—The membrane is in two layers, a superficial or epithelial, and a deeper or fibrous layer. It is comparatively loosely attached to the mucous membrane, whereas in diphtheria it is firmly attached. The epithelial layer of the mucosa is rapidly proliferated, and enters into the composition of the pseudomembrane. The mucous membrane is hyperemic and red, and in places is denuded of its epithelium. The bacteria causing the inflammation are chiefly of the coccus group, for example, pneumococcus, streptococcus, and staphylococcus, though other bacteria, as the spirillum and the bacillus pyocyaneus are found and probably contribute to the etiology. The membrane is not grayish-white, as in diphtheria, but is yellowish and of a soft, friable consistency. It is more easily removed and does not leave an ulcerated or bleeding surface as in diphtheria.

Symptoms.—The laryngoscope shows a free fauces, a coated tongue, and hyperemia of the fauces and the larynx. The membranous formation appears on the aryepiglottic fold, on the ventricles, and occasionally on the vocal cords. It is usually primary in the larynx, though it may originate in the fauces and pharynx, and spread to the larynx. The laryngoscopic image, therefore, shows a yellowish, friable, dirty membrane in one or more of these regions. The temperature rapidly rises to 102° or 103°.

The *onset* of the disease may be the same as in acute catarrhal laryngitis, but in the course of an hour or two a loud, brassy cough develops, which steadily increases until toward midnight, when it reaches its climax. There is loss of appetite, and the patient complains of thirst. The pulse is full and the skin is hot and dry. Deglutition becomes painful. The cough, at first infrequent, becomes more and more frequent, and is finally followed by laryngeal spasm. Great dyspnea then comes on, and the child, in his endeavors to cough out the obstructing membrane, clutches at his throat and tosses about in his bed. These symptoms

increase in severity as the membrane is formed in the larynx, until the voice is aphonic (silent croup) and the inspiration through the narrowed glottis gives rise to a peculiar crowing sound. The next morning the symptoms are lessened in severity, only to be increased again in the evening. Sometimes the climax is delayed until the third night. The disease is progressive, whereas in laryngitis the obstructive symptoms are spasmodic and are not steadily progressive. In case of marked glottic obstruction the inspiratory and expiratory dyspnea and asphyxia may necessitate intubation or tracheotomy.

If the dyspnea continues, the pulse becomes weak, the temperature falls, and the general strength rapidly ebbs away on account of the diminished oxygenation of the blood and the increased amount of carbon dioxide in the blood. When the membrane is thick in the region of the soft palate there may be a regurgitation of fluid food through the nose. This is not due to paresis of the palatal muscles, as in true diphtheria, but to the mechanical interference by the false membrane with the action of the muscles.

Laryngismus stridulus sometimes appears in the course of the disease, and is to be regarded as a neurotic phenomenon.

Diagnosis.—Membranous croup resembles in some respects spasmodic laryngitis, diphtheria, laryngismus stridulus, and retropharyngeal abscess.

Prognosis.—The prognosis is grave, some authors reporting from 50 to 60 per cent. of deaths, while others claim as low as 10 per cent. This discrepancy in the reported death rate is probably due to the difference in the diagnosis. Those reporting a death rate of 50 to 60 per cent. probably include cases of true diphtheria. The prognosis is grave in inverse ratio to the age of the patients. The younger the patient the more serious is the prognosis. In adults the danger is greatly diminished, as the lumen of the larynx is relatively and actually greater, and the mucous membrane is more firmly attached.

In *spasmodic laryngitis* there is a catarrhal inflammation with spasms of the laryngeal muscles, which cause suffocative symptoms. They disappear, however, in a few minutes and the child rests comfortably. In membranous croup the suffocative symptoms come on gradually and disappear as gradually.

In *diphtheria* the temperature does not rise so high or so rapidly. The chief diagnostic points, however, are the culture of the Klebs-Loeffler bacilli and the ashen-gray and firmly adherent pseudomembrane. After its removal the mucous membrane is ulcerated and bleeding, whereas in membranous croup it is smooth and does not bleed.

Laryngismus stridulus is a neurosis and not an inflammatory disease, hence the laryngoscopic examination shows the absence of inflammation. Then, too, there is a history of a healthy child who suddenly has a suffocation fit. In membranous croup there is a history of inflammation and progressive dyspnea.

Retropharyngeal abscess may simulate membranous laryngitis in its suffocative symptoms; otherwise there is little similarity. An examination of the throat reveals a fluctuating tumor on the posterior wall of

the hypopharynx, whereas in membranous laryngitis the tumefaction is within the laryngeal zone.

Complications.—Membranous laryngitis may become complicated with rapid edema of the bronchial mucous membrane or with cardiac infection. In either event the case becomes one of great gravity.

Treatment.—The treatment consists in the administration of broken doses of calomel until free catharsis is produced, and in the inhalation of steam vapor charged with lime and turpentine. The child should be put into a tent-bed and a piece of lime the size of two fists placed in a bucket of water, to which has been added a tablespoonful of spirit of turpentine. The tent-bed is thus filled with the vapor, which is inhaled by the child. The lime and turpentine seem to aid in loosening and expelling the false membrane. The steam-tent seances should last about fifteen minutes, and should be repeated every four or five hours. The efficiency of the steam-tent baths is increased by the administration of ipecacuanha wine or powder, which is a non-depressing emetic.

Calomel fumigations, as advocated by Corlin, have proved an efficient method of treatment. He recommends the administration of one or two grains of calomel before the fumigations begin. The patient should then be placed in a completely closed tent-bed. It requires about ten minutes to volatilize the calomel, and the patient should be exposed to the fumes in the closed tent for about fifteen minutes. It is recommended that fifteen grains be volatilized every two hours for two days and nights, after which the intervals should be prolonged to three hours on the third day, four hours on the fourth day, and three times daily thereafter as long as indicated. Pure calomel thus used does not produce ptyalism, though anemia may occur and should be combated by the administration of iron.

EDEMA OF THE LARYNX.

Synonym.—Edema glottidis.

Edema of the larynx is an inflammatory process attended by an edematous infiltration of the loose submucous tissue of the larynx which is due to a more serious general disease of the heart, kidneys, or the liver, though it may be caused by local conditions.

Etiology.—The local causes are mainly traumatic from the injudicious use of caustics, laryngeal injections of creosote in tuberculous inflammations, operations, foreign bodies in the supraglottic region of the larynx, the swallowing of hot liquids and the inhalation of hot steam, or the inspiration of alcoholic or other irritating liquids into the larynx. The prolonged or violent use of the voice, as in shouting, may bring on edema of the larynx. Local diseases of the larynx, as tuberculosis, syphilis, abscesses, neoplasms, perichondritis, and peritonsillitis may also cause it. Abscess of the larynx may be accompanied by a non-inflammatory edema.

The constitutional causes of simple edema of the larynx are Bright's disease, diabetes, valvular lesions of the heart, sclerosis of the liver, and Ludwig's angina. In the latter disease there is a neurotic paresis of the

bloodvessels of the neck, which causes engorgement and edema. Certain drugs, as the iodide of potassium and the fumes of ammonia and bromine, may cause it.

Pathology.—There is an effusion of clear serum into the laryngeal submucous tissue, producing swelling of the aryepiglottic folds and of the anterior and superior parts of the epiglottis. Sometimes the loose subglottic tissue becomes edematous. In associated ulcerative processes the serous infiltration may be seropurulent.

Symptoms.—The onset is sudden and is characterized by the loss of the voice and rapidly increasing dyspnea. In severe cases a fatal issue may occur in from two to three hours by asphyxiation. There is little or no pain or cough. The laryngoscopic image shows the mucosa in the region of the aryepiglottic folds, the anterior and upper surfaces of the epiglottis, and sometimes the subglottic region to be tumefied. The surface of the mucous membrane is of a pale-gray color, in marked contrast to the tumefaction in phlegmonous or inflammatory edema of the larynx, in which it is red.

Prognosis.—The prognosis is grave on account of the sudden development of the edema, and the serious nature of the constitutional disease back of it. If it is due to an extraneous irritation, the danger is less, and the liability to recurrence is less.

Treatment.—If the disease is secondary to a serious constitutional disorder, this should, of course, receive appropriate treatment. For the immediate relief of the symptoms cracked ice should be dissolved in the mouth, and the patient should be assured by the attending physician that the dyspnea will disappear, as the sense of impending death only aggravates the distress. Astringent applications of cocaine and adrenalin should be made. Diaphoresis and catharsis should be induced by the administration of Dover's powder, hot lemonade, etc., followed by the administration of a twelve ounce bottle of citrate of magnesia. In addition to the above, it may be necessary to puncture the edematous tissue with the laryngeal lancet (Fig. 269). If suffocation is imminent, the patient should be tracheotomized (see Tracheotomy), to prevent a fatal issue. The surgeon should not hesitate to perform tracheotomy on a deeply cyanotic case because he does not have with him the instruments usually used for this purpose. A pocket knife, or a paring knife from the kitchen, may be quickly sterilized and used to open the trachea. A needle and thread may be used to retract the parts until a tracheotomy tube is secured. In the meantime the patient's life has been saved, whereas to have waited for suitable instruments would have jeopardized his life.

ABSCESS OF THE LARYNX.

Etiology.—Abscess of the larynx is usually a complication of tuberculous perichondritis. Perichondritis of the laryngeal cartilages is attended by ulceration of the mucous membrane. Infectious bacteria gain entrance beneath the perichondrium and cause the formation of pus. The accumulated pus causes a rounded tumor-like mass. This

is a laryngeal abscess. It has also been known to follow erysipelas of the larynx, and it may be of traumatic origin.

Symptoms.—The abscess swelling encroaches upon the glottis, hence there are loss of voice and intense suffocative symptoms. It is an infectious inflammatory process, and causes febrile phenomena. There is retention and pressure, hence pain in the larynx. The laryngoscopic image shows a greatly swollen and reddened mucous membrane at the site of the abscess. Upon puncturing it with the laryngeal lancet there is a free flow of pus.

Fig. 270

Sajous' laryngeal forceps applicator.

Treatment.—It is obvious that there is but one method of treatment, namely, the evacuation of the pus with a laryngeal lancet (Fig. 269). This may be done under cocaine anesthesia with the patient in the sitting posture. The anesthesia is induced with a 10 to 20 per cent. solution of cocaine applied repeatedly with Sajous' forceps (Fig. 270). The curved laryngeal lancet should then be used with the aid of reflected light and the laryngoscopic mirror, or by direct laryngoscopy (Fig. 324), and the tumor-like mass freely incised. The relief is immediate. If suffocation threatens tracheotomy may be necessary. (See Tracheotomy.)

CHRONIC LARYNGITIS.

Definition.—Chronic inflammation of the mucous membrane of the larynx includes the glandular, vascular, and connective-tissue layers. It is usually secondary to an acute attack, or to inflammation in the nose, epipharynx, and tonsils, though it occasionally seems to occur as a primary affection.

The following classification meets both the clinical and the pathological requirements:

1. Chronic hypertrophic laryngitis.
   - (*a*) Diffused hypertrophic laryngitis, sometimes called chronic hyperemic laryngitis.
   - (*b*) Discrete or localized hypertrophy of the mucous membrane, either supraglottic or subglottic.
   - (*c*) Chorditis nodosa, or trachoma of the vocal cords.
2. Atrophic laryngitis.
3. Hemorrhagic laryngitis.

Chronic Hypertrophic Laryngitis.—(*a*) **Chronic Diffused Laryngitis.**—Each of the three varieties of chronic hypertrophic laryngitis presents a distinct clinical and pathological picture, hence they will be described separately.

Synonym.—Sometimes called hyperemic laryngitis.

It is characterized by a diffused infiltration throughout the laryngeal mucosa, no one part being affected more than another As it is due to irritations of a general character, rather than to those directed against one part, it is easy to understand the diffusion of the hypertrophy and hyperemia.

Etiology.—It is extremely doubtful if there is a *primary* chronic laryngitis, except from the improper use of the voice. It is always, or nearly always, secondary to a preceding disease of the nose, epipharynx, or the faucial tonsils. It is possible to conceive of a chronic laryngitis following the excessive use of tobacco or alcohol, or even following digestive disturbances. Clinically, however, it is rare to see cases in which there is not an associated or a preceding disease higher up in the respiratory tract. The diffused hypertrophic variety arises from obstructed nasal breathing and from the discharges into the pharynx from the sinuses. Other sources of irritation may also be present, but they are generally incidental and of secondary importance.

The etiology may be classified under the following headings:

1. Improper preparation of the inspired air on account of nasal and sinus diseases.
2. Hematogenous irritation of the larynx in mouth breathing, hepatic and digestive disorders.
3. Passive hyperemia in cardiac disease, thoracic tumors and enlarged glands.
4. Smoking, the inhalation of dust-laden air, the excessive use of alcohol, and the violent use of the voice.
5. Climate conditions.
6. Age and sex.

Mouth breathing, adenoids, deflections of the septum, turbinal hypertrophy, sinuitis, and polypi, also improper breathing by public speakers and singers, lead to a diffused irritation of the laryngeal mucous membrane. As the improperly prepared air and secretions pass over the whole laryngeal mucosa, there is a diffused hypertrophy. As the air in damp cold weather is more irritating than it is in warm and bright weather, it follows that the symptoms are aggravated during the winter and early spring months in the higher latitudes. This is especially true in the region of the Great Lakes and on the northern Atlantic coast of the United States.

The breathing of improperly prepared air results in deficient oxygenation of the tissues and an excess of carbon dioxide in the blood. This in turn disturbs the metabolic processes, and still further loads the blood with deleterious material. This blood in circulating through the laryngeal mucosa irritates all its parts, and causes a diffused hyperemia and hypertrophy. The excessive use of alcohol and tobacco similarly affects

the larynx. Smoking does it by direct irritation, and indirectly through the blood. The ingestion of alcohol affects the larynx by direct irritation of neighboring parts, and through the circulation, to say nothing of the digestive and metabolic disturbances thus aroused. The foregoing etiological factors predispose the larynx to acute attacks, and the chronic state is usually a sequel or a continuation of repeated acute inflammations. I am of the opinion that through disease and obstruction in the nose the laryngeal mucosa is kept in a state of irritability, and is made susceptible to chronic inflammation by the inspiration of the improperly prepared air and by the toxins in the blood. At the age of puberty boys are subject to attacks of chronic laryngitis on account of the unstable condition of the vasomotor nervous system, the rapid development of the larynx, and the consequent instability of the same. Any disease of the heart, wherein there is an interference with the return circulation, may cause huskiness, and perhaps diffused hypertrophy of the mucous membrane. Thoracic tumors, or enlarged thoracic and cervical glands, also interfere with the return circulation, and lead to hypertrophic changes. Stonecutters, tobacconists, metal workers, and workers with certain chemicals are often affected by chronic laryngitis from the inhalation of the contaminated air. Men are more often affected than women, for obvious reasons. The aged are more prone to it on account of the vascular and glandular changes accompanying senility. Indeed, many old people living in the northern part of the United States are more or less afflicted with chronic laryngitis.

Pathology.—There is a diffused hypertrophy of the laryngeal mucous membrane, including the glandular and the connective tissue. The bloodvessels are but little affected excepting a few small arteries on the surface of the epiglottis and the vocal cords, where they may be enlarged.

Symptoms.—The objective symptoms of the diffused hypertrophic laryngitis, if carefully studied, are somewhat different from those of the other two varieties of hypertrophic laryngitis, and are as follows:

Diffused hyperemia of the laryngeal mucous membrane, including that of the epiglottis, is usually present. It may be more pronounced in the ventricular pouches, on the epiglottis, the aryepiglottic folds, or on the vocal and the ventricular bands. Indeed, it often spreads from one part to another in the order given above, until in the later stages it is general. In singers and speakers the hyperemia is generally greater on, or is entirely limited to, the true cords. The color varies in different individuals, and, indeed, in the same case at different times. The cords may be the normal ivory white, or pinkish red, or they may be streaked with red, or of a pale, mottled brown or slaty gray. Enlarged bloodvessels are rarely seen, except upon the epiglottis and the vocal cords.

The secretions are increased but little, indeed, in some cases they are apparently decreased. The image may present, therefore, either a moist or a dry membrane. The hyperemia is rarely demonstrable by laryngoscopic examination. The mobility of the cords is usually unaffected, though in some cases there is a tardy action from the infiltration of the muscles.

The subjective symptoms have reference to the voice, the sense of accumulated secretions, and the ease with which the vocal apparatus becomes tired. The voice upon rising is often quite husky, or even aphonic. During the day it becomes nearly or entirely clear, unless it is used excessively. In this event it remains husky, and is attended by aching in the larynx. The secretions are rarely increased and are sometimes diminished in quantity.

The diffused hyperemia and hypertrophy give rise to the sense of accumulated secretions and the desire to clear the throat.

Diagnosis.—The diagnosis is based upon the hoarseness or aphonia, the diffused hyperemia in the later stage, the absence of discrete hypertrophy, and the small amount of expectoration, except when complicated by bronchitis.

Prognosis.—The prognosis in the early stage is good, but when the hyperemia has extended over the entire mucosa it is not so favorable. If the laryngitis is due to the excessive use of alcohol or tobacco, or to an excessive or violent use of the voice, the excesses should be corrected. If it is due to nasal obstruction or to adenoids these conditions should be corrected. No matter what the cause, the prognosis as to the voice is bad if the hypertrophy is pronounced. In these cases there may be an infiltration of the thyro-arytenoidei interni muscles, thus giving rise to a sluggish action of the cords.

Treatment.—From the foregoing description of the disease it is apparent that the treatment must be addressed to (*a*) the correction of the preexisting nasal and sinus diseases; (*b*) the removal of adenoids; (*c*) the discontinuance of the use of tobacco and alcohol; (*d*) the correction of digestive and hepatic disorders, and (*e*) the avoidance of excessive use of the vocal organs.

When the nose and accessory sinuses are the seat of a catarrhal or a suppurative inflammation, it should receive appropriate attention. Deflections of the septum, turbinal hypertrophies, sinuitis, polypi, etc., should be corrected or removed by surgical procedures. Adenoids, if present, even though they are somewhat reduced by atrophy in adults, should be removed, and the associated epipharyngitis treated with silver applications. The faucial tonsils when enlarged or diseased should be removed in their entirety. The use of tobacco and alcoholic beverages should be forbidden, as but little benefit can be expected while the larynx is subjected to their deleterious effects. Singers who practice improper placement of the voice should either be forbidden to sing, or be taught proper methods of voice building. (See the Singing Voice.) Violent use of the voice, either in singing or speaking, should be avoided.

The use of sprays, gargles, and oily nebulæ by the patient are of little value. These remedies, at most, can do no more than thin the secretions and thus facilitate their expulsion.

Local applications of a 2 to 10 per cent. solution of the nitrate of silver with Sajous' forceps should be made three times a week. The chloride of zinc in the same strength should be tried, although I have found nothing as efficacious as the nitrate of silver. Other prepara-

tions of silver in my hands have proved disappointing. In making applications to the larynx the excess of fluid should be squeezed from the cotton, to prevent it trickling between the cords, where it would excite spasm of the laryngeal muscles. Should a spasm occur, have the patient take a number of deep breaths in rapid succession. Sustained efforts of this sort quickly stop the spasms. Spasms of the larynx excited by an excess of silver solution may be so violent as to cause cyanosis and extreme apprehension on the part of the patient.

Constitutional remedies, as saline cathartics, calomel, and the iodide of potash, should be given if syphilis is suspected. They are often of value in small doses when syphilis is not present, as the cathartics improve the elimination, while the iodide of potash stimulates the glands.

The improvement following the correction of digestive and hepatic disorders is often very gratifying. To this end I advise the daily use of one of the bitter salines in small doses, and a five-grain dose of the iodide of potash three times a day. In addition to these remedies it may be necessary to use others, according to the needs of the case. If chronic bronchitis is present, the administration of a ferruginous tonic, with five grains of the iodide of potash three times daily for from three to six months, will often effect a cure of both the laryngitis and the bronchitis. I recall one case that gained twenty pounds in five months under this treatment.

The hygienic conditions should be good, the living and the sleeping rooms ventilated, and proper clothing worn. Even with all these precautions it is often impossible to greatly improve the quality of the voice.

(*b*) **Discrete or Localized Hypertrophic Laryngitis.** — *Synonyms.* — Chronic subjective laryngitis; laryngitis hypoglottica; chorditis vocalis hypertrophica inferior; Stoerk's blennorrhea.

Discrete or localized hypertrophic laryngitis is characterized by hoarseness or aphonia, dyspnea, a brassy cough, and an infiltration of the tissues in the subglottic space.

Etiology and Pathology.—The pathological changes are the same as those given under the diffuse form, except they are more localized.

Symptoms.—The subjective symptoms are about the same as those given under the diffuse form, but they are greatly exaggerated. The hoarseness usually amounts to aphonia. The hypertrophic tissue in the subglottic space and the infiltration of the laryngeal muscles, interfere with the normal movements of the cords to such an extent that approximation is often impossible. The dyspnea, or suffocative symptoms, are due to obstruction in the glottis. The brassy cough is characteristic of obstructive swelling and hypertrophy in the subglottic region.

The objective signs of this variety of laryngitis are quite characteristic. The hypertrophied tissue below the cords appears as two sausage-like masses, nearly parallel with and beneath the true cords. Their color varies from a pale grayish pink to the pronounced red of active inflammation. The epiglottis is also congested, enlarged bloodvessels passing

over its posterior surface. In some cases there is more or less edema. In these cases deglutition is difficult, owing to the imperfect closure of the glottis. The dyspnea in discrete hypertrophic laryngitis is increased upon exertion. Patients sometimes complain of a sense of stuffiness, or of a foreign body in the larynx. After the disease is well advanced the above symptoms are fairly persistent, as the hypertrophic swelling is a fixed factor. Upon attempted phonation the cords fail to approximate, and instead of the free edges presenting straight lines they are slightly concave or wavy, owing to the weakness of the abductor and tensor muscles from infiltration. No doubt the hypertrophic masses in the subglottic region also interfere with the movements of the cords. The secretions are thick and whitish in color and are often accumulated in the interarytenoid space, and over the sluggishly moving cords.

Diagnosis.—Rhinoscleroma presents some points of similarity, but in view of the fact that it is a very rare disease in this country, and that if the subglottic swelling is touched, under cocaine anesthesia, with a curved probe, it is yielding, whereas in rhinoscleroma it is hard and resistant, there is little difficulty in excluding rhinoscleroma. The removal of a piece of the growth for microscopic examination may be practised in case of doubt. This, when stained by Gram's method (see Rhinoscleroma), shows the characteristic cell formation and the bacillus of rhinoscleroma if that disease is present.

Prognosis.—On account of the hypertrophic swellings below the cords, the dyspnea may become so pronounced as to require the performance of tracheotomy (see Tracheotomy), and the wearing of a tube throughout the remainder of life. The danger from suffocation and the pulmonary complications incident to the wearing of the tracheal tube render it a grave disease.

Treatment.—Before undertaking the treatment the cause or causes of the affection should be carefully studied. When the etiology has been definitely determined an endeavor should be made to overcome the predisposing causes of the disease. If rheumatism, gout, dyspepsia, anemia, or constipation (Watson Williams) are present, appropriate remedies should be given. The iodide of potash and the protoiodide of mercury should be given in suspected syphilis, or even if syphilis is not suspected, as they often promote more or less absorption of the deposit. Tonic remedies, as iron, arsenic, quinine, gentian, and strychnine, should be given to promote the general tone of the system and to innervate the laryngeal muscles. Obstructive lesions and inflammatory diseases of the nasal chambers and of the epipharynx should be remedied by appropriate medicinal and surgical measures. If the excessive use of tobacco and alcohol enter into the etiology their use should be interdicted. The local application of astringents, as the chloride of zinc (10 to 30 grains to the ounce), nitrite of silver (10 to 30 grains to the ounce), alum (5 to 15 grains to the ounce), should be made with Sajous' laryngeal forceps or with the spray during phonation. A change of climate or a sea voyage is sometimes beneficial, though not curative. Last, but not of least importance, is the absolute rest of the vocal organs. Improvement

is sometimes striking when these precautions are faithfully observed for a few days.

(*c*) **Chorditis Nodosa.**—*Synonyms.*—Trachoma of the vocal cords; chorditis tuberosa; singer's nodules; pachydermia laryngis.

Chorditis nodosa, or "singer's nodules," is characterized by the formation of nodules along the free border of one or both of the vocal cords. Some authors claim they are more often nearer the posterior, and others, that they are more often at the junction of the anterior and the middle thirds of the cords. The cases I have seen have been in the latter position.

Etiology.—The nodules usually occur in connection with chronic hypertrophic laryngitis in singers and public speakers who use faulty methods of respiration and voice placement (Curtis). Curtis insists upon lower costal respiration with the upper ribs elevated, and that the patient should practice voice placement by attacking the initial tone with the lips gently closed as in humming, so that when they are plucked with the finger the tone flows therefrom. If the tone does not emit through the lips when plucked, but entirely through the nasal chambers, it is an evidence of faulty voice placement. When such is the case there is an overtension of the intrinsic and extrinsic muscles of the larynx. This causes attrition of the cords in phonation, hence the nodules. Chiari claims that chorditis nodosa is a typical pachydermia laryngis. Hajek thinks the nodules are glandular hypertrophies. The term as herein used refers to nodules from improper voice placement.

Pathology.—The nodules consist of layers of stratified squamous epithelium surrounded by a circle of congested tissue. They are not unlike corns from ill-fitting shoes.

Symptoms.—As the nodes accompany a diffused hypertrophic laryngitis, the symptoms are sometimes similar to those described under that condition. The special subjective symptoms have reference to the inability of the singer or the public speaker to strike the tone he desires, especially in the middle register. When the cords are widely separated, as in the lower register, no difficulty is experienced, as the opposing nodes do not touch. When the higher register is attempted, the posterior thirds of the cords are necessarily closely approximated and not in use, and the voice is not greatly affected. When, however, the middle register is attempted, the cords vibrate their entire length, and as the nodes touch they interfere with the voice production. Hence, a prominent symptom is the difficulty in tone placement experienced by singers in attempting to use the voice in the middle register. The laryngoscopic image shows a nodule on the free border of one or both cords, usually at the junction of the posterior and the middle thirds, though the nodules may occasionally form anywhere along their borders. If both cords are involved the nodules are exactly opposite. A small area of hyperemia is often present at the base of the nodule. If diffused hypertrophic changes are present, they may not be apparent except as shown by the hyperemia.

Prognosis.—The prognosis in so far as the nodules are concerned is good, provided the patient faithfully follows the instructions contained

in the chapter on the Singing Voice, or by practising external massage of the larynx, as recommended by Miller.

Treatment.—The treatment consists in refraining from singing and loud speaking, and in practising proper methods of breathing and tone placement. This should be done under an intelligent and appreciative instructor, which, alas! is hard to find. I have treated a few cases of "singer's nodules," according to Curtis' suggestions, with most excellent results. In none of the cases did I resort to either local, medicinal, or surgical treatment, as the nodules were apparently the result of faulty methods of singing.

Fig. 271

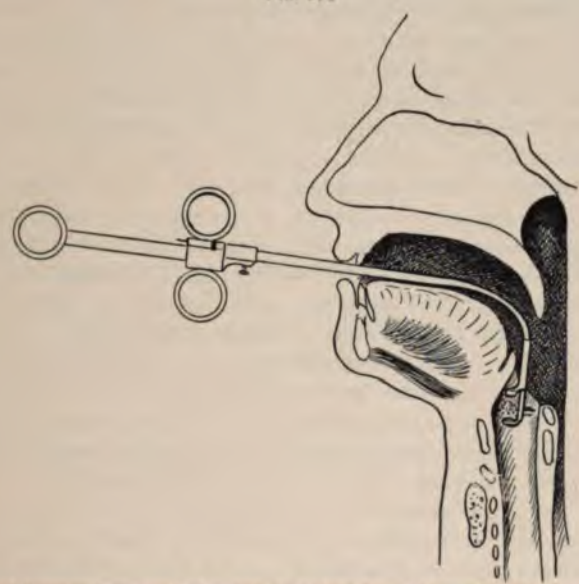

The endolaryngeal removal of a singer's nodule from the vocal cord of the larynx.

If thought advisable, the astringent remedies described under discrete hypertrophic laryngitis may be used. In extreme cases it may be necessary to remove the nodules with an intralaryngeal cutting forceps (Fig. 271). This should be done only after failure to cure by the other methods suggested. Miller recommends external massage of the larynx with a mechanical vibrator as an adjunct to proper training in tone building and voice placement. The massage improves the circulation and nutrition of the mucous membrane, increases the local migration of leukocytes, and relieves the associated laryngeal inflammation.

Atrophic Laryngitis.—**Synonym.**—Laryngitis sicca.

Atrophic laryngitis is characterized by a burning or pricking sensation after exercising the voice, and by suffocative attacks (simulating spasmodic croup and asthma) during the night.

Etiology.—The atrophic changes in the larynx are usually secondary to the same process in the nose and pharynx. Bosworth believes there

is some influence brought to bear upon the mucous glands of the laryngeal mucous membrane which deprives them of their secretory power, and that this influence is often independent of intranasal or pharyngeal atrophy. According to my observation, atrophic laryngitis is often secondary to ethmoiditis and sphenoiditis, and I usually address therapeutic measures to these cavities as well as to the larynx.

Pathology.—The mucous membrane undergoes a retrograde change, fibrous tissue finally replacing the normal elements constituting the mucous membrane and submucous tissue. The mucous glands and the blood vessels disappear, or become greatly diminished in size. The ciliated columnar epithelium is gradually replaced by squamous epithelium. The secretions are diminished in quantity and changed in quality. They are thicker and admixed with white corpuscles and epithelial debris. The desiccated secretion appears as brownish, blackish, or grayish crusts on the cords, and in the interarytenoid space. Ulceration of the mucosa is not generally present, though it may be, especially on the posterior wall.

Symptoms.—After using the voice there may be a burning or pricking sensation in the throat. Cough, of a hoarse, spasmodic character, is excited by the presence of, and the attempt to remove, the crusts from the larynx. The cough and hoarseness are more pronounced in the morning. Dyspnea, simulating spasmodic croup or asthma, may occur at night on account of the accumulation of the crusts over the vocal cords. Upon laryngoscopic examination the mucous membrane appears pale and dry, with discolored crusts on the cords, or in the interarytenoid space. They may also be seen upon the posterior wall of the larynx in some cases, especially if there is ulceration in this region. The cords are dry and wrinkled and more or less covered with crusts. The trachea may be dry and glazed or covered with crusts.

Prognosis.—The prognosis is bad except in those cases in which the atrophic changes have progressed but little. In such cases the surgical exenteration of the ethmoid and sphenoid sinuses may effect a cure or an amelioration of the diseases, provided, of course, the sinuses are affected.

Treatment.—The internal administration of the iodides occasionally stimulates glandular activity and thus affords relief. Pilocarpine may also be given for the same purpose if the heart is strong. It should never be given without first making an examination of this organ. The chloride of ammonium and cubebs stimulate the glands and thins the secretions, rendering them easier to dislodge. The inhalation of aromatics in solution in olive oil, thrown into the larynx with a nebulizer, is grateful and affords temporary relief. Medicated lozenges with a mucilaginous base may be used to protect the dry membrane. A warm, moist climate or a sea voyage will ameliorate the symptoms. Careful attention should be given to the condition of the nose, the accessory sinuses, and the pharynx. If the nose is kept free from crusts and the secretions are increased the larynx will undergo a corresponding improvement. In empyema of the posterior ethmoidal and the sphenoidal

cells the secretions discharge into the pharynx and trickle downward into the larynx, where they become dried and adherent to the posterior wall, or lodge upon the cords. In such cases great improvement follows the radical operative treatment of the sinuses.

Hemorrhagic Laryngitis.—Synonyms.—Spurious hemoptysis; laryngeal hemorrhage; bleeding in the throat; spitting blood.

By hemorrhagic laryngitis is meant a laryngeal inflammation accompanied by hemorrhage from the laryngeal mucous membrane. The spitting of blood, or hemoptysis, is not always of laryngeal origin. It may come from the nose, the pharynx, the trachea, the bronchi, or the lungs. The term hemoptysis, or spitting of blood, should be limited to hemorrhage from the lungs, and especially that occurring in tuberculosis.

Etiology.—Hemorrhage occurring in the course of laryngitis is due to ulcerations, acute inflammations, and the excessive use of the voice. Syphilis and tuberculosis of the larynx may be attended by laryngeal hemorrhage. Albuminuria, diabetes, variola, typhoid fever, yellow fever, leukemia, hemophilia, and malignant disease also predispose to hemorrhages.

Symptoms.—If a chronic laryngitis is present the usual symptoms of such a condition are present. (See Chronic Laryngitis.) Added to this the patient complains of a tickling sensation in the throat, followed by cough and the expectoration of blood. The quantity varies from a mere streak to a mouthful; usually, however, it is small.

The laryngoscopic examination shows one or more areas of extravasated blood on the cords or mucous membrane, and perhaps some fresh fluid blood may still cling to the surface of the laryngeal mucosa.

Treatment.—Ordinarily no treatment is required. Astrigent sprays and the external application of ice may be tried. If the coughing is continued, it should be quieted by the administration of morphine by hypodermic injection (Coakley). The act of coughing prevents coagulation and tends to prolong the bleeding.

General Diagnosis of Chronic Laryngitis.—The differential diagnosis of chronic laryngitis from other laryngeal diseases is not always easily made. It may be confounded with laryngeal tuberculosis, syphilis, adenitis, carcinoma, and certain benign growths.

Tuberculosis is characterized by a rapid pulse, elevation of temperature, loss of appetite, emaciation, and a general lowered vitality. These symptoms are not present in chronic laryngitis. An examination of sputum for tubercle bacilli will still further aid in the diagnosis. A laryngoscopic examination does not always settle the diagnosis, unless the larynx is the seat of the tuberculous infiltration. In most cases of tuberculosis the laryngeal mucosa is ashen gray in contrast with the diffused hyperemia of chronic laryngitis. In the inflammatory type of laryngeal tuberculosis (mixed infection) the mucosa is red, but the swelling of the arytenoid cartilages is too great to be mistaken for catarrhal inflammation.

If the tuberculous process is well advanced ulcerations may be present.

Syphilitic affections of the larynx may present much the same appearance as the edematous type of chronic laryngitis. Hyperplasia may be present in both diseases, but is more often present in syphilis. Careful inspection will often reveal small ulcers, which condition lends to the diagnosis of syphilis. An accurate history of the case is, therefore, necessary to make the differential diagnosis. In the tertiary stage the diagnosis is easily made. The ulcers in hypertrophic laryngitis are stationary, while those of syphilis and tuberculosis are deep and spread rapidly.

Carcinoma in the subglottic region is distinguished from discrete hypertrophic laryngitis by the nodular outline of the growth and the cachexia present. Perichondritis in this region more nearly simulates carcinoma on account of the nodular outline of the tumor-like mass.

In *lupus* the surface of the membrane is markedly red and granular.

Sarcoma of the larynx presents a red and an uneven contour, whereas in all forms of hypertrophy the swelling and purulent discharge come on before the perichondritis becomes manifested.

Enchondrosis of the laryngeal cartilages is differentiated from edematous laryngitis by the sense of hardness on probe pressure and the uneven contour of the swelling.

Paralysis of the posterior crico-arytenoid muscle may be mistaken for subglottic hypertrophy unless a careful examination is made. In paralysis the lagging movements of the cords reveal the nature of the lesion. The paralysis may also be mistaken for pachydermia laryngis.

Prolapse of the ventricles is differentiated from superior hypertrophy by the pronounced pitting upon probe pressure.

Angina laryngis is differentiated from hemorrhagic laryngitis by the elevated whorl of bloodvessels and the absence of hemorrhage.

Papilloma is distinguished from chorditis nodosa by the point of attachment, and the size and shape of the growth.

DIPHTHERIA; TRACHEOTOMY; INTUBATION.

Definition.—Diphtheria is an acute infectious disease, characterized by the presence of the Klebs-Loeffler bacillus. It is still further characterized by a false membrane on a mucous surface or an abraded skin, and is communicable, either directly or indirectly, from one person to another. The lesion is usually located in the upper respiratory tract.

Etiology.—As to its geographical and racial distribution, it may be said to be well-nigh universal. No climate, season, country, or race is exempt from its ravages. It is, however, less prevalent in the summer season in temperate and northern latitudes, on account of the open-door life of the people at this season, and an account of the school vacations, the overcrowding, and the close contact incident to school life being temporarily suspended. Statistics show that among the poor in crowded tenements, and in illy ventilated school-rooms, the disease is more prevalent. A curious exception to this is shown by Walsh to exist among the

negroes of Washington. The percentage of diphtheria among 10,000 negroes was 4.43, as against 15.25 per cent. among the same number of whites. This may be due to an antitoxic state of the blood in the negro race, or to a greater freedom from disease of the upper respiratory tract. (Nasal obstruction is comparatively rare among negroes.)

Sanitation is an important factor in the development of the disease. Sunshine and fresh air are twin sisters of charity in the prevention and the amelioration of infectious diseases. In one of the great children's hospitals of London, diphtheria was prevalent in one of the wards. As soon as they were convalescent the patients were removed to another ward and no recurrences were reported. An adjacent building was torn down and the solid iron shutters of the convalescent ward were closed to exclude the dust. Incidentally the sunshine and the fresh air were also excluded, and there were many recurrences among the convalescents.

The overcrowded tenement districts in the great cities are usually poorly ventilated and the rooms little exposed to the sunshine. When many are in close contact, the opportunities for transmitting the infection are multiplied, hence, for these and other reasons the poor of the cities, are especially afflicted with diphtheria.

Defective plumbing, sewer gas, cesspools, etc., are often charged with the production of the disease. While these may indirectly influence the spread of the contagion, it should be remembered that the Klebs-Loeffler bacillus is absolutely essential to the production of the true disease. The presence of sewer gas may produce lessened resistance to the diphtheria bacilli, and thus predispose the patient to their ravages.

Bodily conditions have much to do with the susceptibility of the individual exposed to the Klebs-Loeffler bacillus. The "scrofulous habit" lowers the tone of the cellular elements of the body and thus renders it less fit to cope with the inroads of the disease-producing germ. Abraded or diseased surfaces in the upper respiratory tract also offer local lowered resistance areas for the growth of the bacilli. Hence enlarged and diseased tonsils, adenoids, glandular enlargements of the neck, and catarrhal diseases of the nose and throat favor the development of the diphtheritic process.

Rich and poor alike are affected, the only difference being the more favorable sanitary conditions surrounding the rich, who are, therefore, relatively less often affected.

Age has a decided influence on the prevalence of the disease. The blood of nurslings is decidedly antitoxic in its properties, hence children under one year of age are comparatively exempt from the disease. After the fourteenth year there is relatively slight liability to diphtheria. Baginsky shows by the statistics of 2711 diphtheritic cases that under six months the percentage of cases is 0.55; six months to one year, 2.5 per cent.; one to two years, 8.3 per cent.; two to three years, 11.6 per cent.; three to four years, 13.05 per cent.; four to five years, 12.4 per cent.; five to six years, 9.7 per cent.; six to seven years, 10.3 per cent.; seven to eight years, 7.7 per cent.; eight to nine years, 6.4 per cent.; nine to ten years, 5.5 per cent.; ten to eleven years, 3.7 per cent.;

eleven to twelve years, 2.9 per cent.; twelve to thirteen years, 2.02 per cent.; thirteen to fourteen years, 2.6 per cent. (Fig. 272).

Modes of Infection, Direct and Indirect.—The direct infection is from the one affected to another, *i.e.*, by breathing the atmosphere immediately surrounding the patient, inhaling his breath, or receiving the mucous or the saliva into the mouth or the nose during an act of coughing, spitting or sneezing on the part of the patient. Kissing is another mode of direct infection, and is to be condemned when diphtheria is known to exist in the family. All members of the family should refrain from this manifestation of affection during the term of diphtheritic infection in its ranks, as there may be a mild or an incipient infection without the knowledge of the individual. Without doubt many cases are often transmitted by persons who are not suspected of being infected.

The indirect mode of infection is not so easily traced as the direct; nevertheless, it is well established that the bacilli may be transmitted by domestic animals, as dogs, cats, chickens, rabbits, etc., which, being

Fig. 272

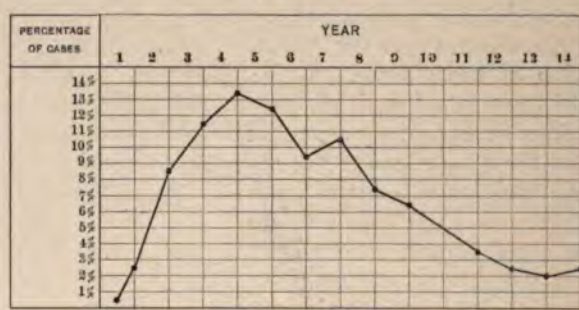

The above chart is arranged from the statistical data of Baginsky, and shows at a glance the relative prevalence of diphtheria from birth to fourteen years of age.

directly exposed to the contagion, convey it to persons removed from the direct source of infection. The author recalls a case which aptly illustrates this point. He was in the house of a minister when a member of the parish called to make the funeral arrangements for his child, who had just died of diphtheria.

The man was accompanied by a collie, which was hugged and fondled by the four-year-old son of the minister. Within a few days the boy was ill with diphtheria, having no doubt received the infection from the collie. It may also be conveyed by towels, table-linen and dishes, bedding, books, wall-paper, carpets, rugs, clothing, and all other articles bathed in the germ-laden atmosphere surrounding a diphtheritic patient. Food may be the source of infection, milk being especially accused in this connection.

The hands and the clothing of physicians, nurses, and parents should be mentioned as sources of infection.

The custom of serving the elements at communion services in churches from common cups is to be condemned as a possible mode of conveying

contagious diseases. Individual cups should be used, thereby minimizing if not absolutely removing the danger. The church should be as cleanly in its table manners as its individual members are in their homes. There they do not think of drinking from a common vessel, each member and each guest being provided with one for his individual use. The same decent, cleanly, sanitary custom should prevail in ecclesiastical functions.

The disease may be endemic, epidemic, or sporadic in its manifestations in a community. The mode of manifestation is largely due to the density and the numerical strength of the settlement. In large cities, where there are large numbers congregated in small areas, diphtheria is epidemic, coming as a tidal wave of infection and carrying many away in its course. The community may then be free from the disease for months or years. The sporadic or isolated cases are more difficult to explain, but we know that the Klebs-Loeffler bacillus must be present. It is known that it may live under varying and peculiar conditions for a long time, and the sporadic cases are often to be explained by the latent existence of the germ, which suddenly becomes virulent and gives rise to the isolated attacks of the disease.

Bacteriology.—The Klebs-Loeffler bacillus being the specific cause of diphtheria, its characteristics and the methods for its detection are important. The announcement of Klebs in 1883 that he had discovered a bacillus which was constantly present in the false membrane of diphtheritic patients, marked an epoch in the history of medicine, and soon revolutionized the methods of treating diphtheria. Loeffler in 1884 made pure cultures of the bacillus, and inoculated the mucous membranes of animals, getting the characteristic pseudomembrane of diphtheria. In 1888–89, Roux and Yersin reported the results of their experiments relative to the toxins produced by this germ. Serumtherapy thus had its beginning.

The Klebs-Loeffler bacilli vary greatly in size, shape, and curvature, according to the medium in which they are grown, and often vary in the same medium. They also vary with the fluidity, the age, and the temperature of the medium, but they generally present the appearance of narrow rods, straight or curved, swollen at either extremity, and are found in groups with a tendency to parallelism. They are not always parallel, but may have a tangled, irregular arrangement, or be in broken chains.

The atypical forms may be thickened at one end only, or at the centre of the rod, the extremities being pointed. They may also be lance-, spindle-, or club-shaped, or even pear-shaped. One characteristic is always present, namely, segmentation.

The Klebs-Loeffler bacilli stain readily with alkaline methylene-blue and many other aniline dyes.

Northrup gives the following directions for the preparation of Neisser's stain and its application to the differentiation of the diphtheritic germ:

"No. 1.—1 gm. methylene-blue dissolved, 20 c.c. of 96 per cent. alcohol, 90 c.c. distilled water, 50 c.c. glacial acetic acid."

"No. 2.—2 gm. vesuvin to 1 liter of boiling distilled water.

"The culture is stained in No. 1 for one to three seconds, or, better,

somewhat longer; washed off in water and stained with No. 2 for three to five seconds or longer; washed off and mounted. Colored in this way, a twenty-four-hour-old culture on blood serum or bouillon will show the body of the bacilli stained brownish yellow, while at one or both ends may be frequently seen the so-called polar granules (Neisser-Ernst bodies) as deeply colored blue, oval-shaped areas, the diameter of which is greater than that of the bacillus in which they are found. The outlines of these bodies are sharply defined, and they are not peculiar to true diphtheria bacilli, but are found occasionally in a slightly atypical form in certain forms of pseudodiphtheria bacilli, especially in older cultures."

The diphtheria bacilli may be grown upon blood serum, agar-agar, bouillon milk, etc., and they are pathogenic for pigeons, rabbits, guinea-pigs, chickens, certain small birds, cattle, goats, and horses.

Bacteriological Diagnosis.—A portion of the pseudomembrane should be removed from the throat of the patient with an aseptic cotton-wound probe, wire loop, or other instrument, and smeared over a clean cover-glass, dried and stained with Roux's double stain of dahlia violet and methyl green, or with Loeffler's blue-staining solution.

The coverglass thus prepared should be mounted and examined with a microscope. The diphtheritic bacilli, if present, will be readily recognized by their typical appearance. If not found, a culture in blood serum should be made, which, in from twelve to twenty-four hours, in a temperature of 37° C., will develop grayish colonies, the size of a pinhead, with regular outline, the surface being dry. Held to the light, the periphery is translucent, the centre being somewhat opaque, on account of its greater thickness.

Upon the above appearances and reactions a fairly positive diagnosis of diphtheria may be made.

The *streptococcus* is developed much slower (twenty-four to seventy-six hours), the colonies are white, and pinpoint in size.

The *staphylococcus* develops slower than the diphtheritic bacillus, but faster than the streptococcus. It presents the appearance of a flocculent or white colony much larger than a pinhead, and has a halo-like border. The areas are darker in the centre.

A negative result with the microscopic examination, or with the cultures, does not justify a positive statement that the case is not one of true diphtheria. The author knows of an instance in which seven different examinations were made by an expert bacteriologist and pathologist, before the Klebs-Loeffler bacillus was found.

Mixed infection is the rule, hence a case of simple diphtheria is not commonly seen in practice. The Klebs-Loeffler bacilli are usually associated with streptococci, staphylococci, and diplococci, and the symptoms and the progress of the disease are modified accordingly. Again, virulent diphtheria bacilli may be present in a healthy throat without giving rise to any symptoms. Should, however, these same bacilli be lodged in a throat with enlarged, ragged tonsils there is every probability that the person would be affected by true diphtheria. Mixed

infections are more serious than simple, as the accessory germs may produce severe pathological changes, independent of the diphtheritic process.

The Systemic Distribution of the Bacilli.—Many investigators report the presence of Klebs-Loeffler bacilli in pneumonic areas and lymphatic glands, but they are generally associated with other germs. They have been found in the lungs, the spleen, the bone-marrow, the liver, the nasal accessory sinuses, the heart's blood, and they are probably in other tissues of the body.

Pseudodiphtheria Bacilli.—There are two schools of thought regarding the so-called pseudobacilli of diphtheria: (*a*) The larger school holds that the pseudodiphtheria bacillus is under no circumstances convertible into the true diphtheria bacillus. (*b*) The smaller school holds that the two germs are identical. The scope of this work will not permit of a presentation of the data upon which these two schools of thought rest their claims. Suffice it to say that the two germs are differentiated, according to the first or larger school, by their mode of development on various culture media, their morphology, and their pathogenicity.

Histopathology.—The distribution of the false membrane may involve the mucous membrane of the nose, the pharynx, tonsils, hard and soft palate, mouth and lips, larynx, trachea, the bronchi from the largest to the smallest, the ear, and abraded surfaces of the skin. The vagina, the duodenum, the conjunctivæ, and other mucous membranes may also be involved.

In about 75 per cent. of the cases the membrane is above the larynx. In 15 per cent. of the cases the larynx is involved. Previous to the use of antitoxin, autopsies often showed the pseudomembrane extending from the tip of the nose to the smallest bronchi; since the use of antitoxin it is rarely found so extensively distributed.

The appearance of the pseudomembrane varies from a pale yellow through a dirty brown to a black color. Its consistency is usually tough and leathery, although it may be friable. It is *firmly attached* to the underlying tissues when found on the uvula or the pharyngeal wall, and *loosely* attached in the trachea.

The *formation of the pseudomembrane* begins with an exudation of lymphatic cells, which rapidly undergo coagulative necrosis, leaving a reticulated substance composed of fibrin from the broken-down cells.

If the *fibrin penetrates* the deeper layers of the mucosa, it is difficult to remove it, as the line of demarcation is not easily established between the living and the dead tissue. If, on the other hand, the fibrin remains superficially attached, it is easily removed, for obvious reasons. When the pseudomembrane is deeply attached, its removal is attended by some bleeding; if superficially attached, there is no bleeding.

Sloughing of the mucous membrane may occur when the bloodvessels supplying it become degenerated, thrombosed, or otherwise injured, so that the nutrition supplied to the parts is shut off. This is often spoken of as "gangrenous diphtheria."

It is seen by the foregoing statement of the varying appearances and

conditions of the pseudomembrane of diphtheria that the picture presented is kaleidoscopic in character. Its appearance in the early stage is usually as a whitish or yellowish, circumscribed film, and, at a still later period, it may become yellowish or dirty brown in color. If hemorrhage takes place beneath or within the false membrane it may become black.

According to Northrup, the pathological changes in various parts of the body have been shown by numerous writers, and only a brief mention of them can be made here.

The *nervous system* is involved in some cases, with degeneration of the posterior roots (Bikeles and Kalisko) where they enter the gray matter of the posterior cornua, thus accounting for the ataxic symptoms occurring in diphtheritic paralysis. Manicatide reports his findings as follows:

(*a*) Purely muscular changes with no nerve involvment.

(*b*) Polyneuritis.

(*c*) Lesions of the spinal cord, which were either localized in the gray matter, leading to atrophy of muscles, or involving the white matter of the cord, in a similar way to that seen in locomotor ataxia or multiple sclerosis.

(*d*) Cerebral paralysis, chiefly due to circulatory changes.

The *heart* undergoes degeneration, chiefly fatty. This simple type of degeneration precedes the more destructive hyaline changes, which lead to the loss of the sarcous elements. The changes are due to toxins.

The *lungs* are, in about 60 per cent. of cases, affected by bronchopneumonia. True lobar pneumonia has not been found.

The *spleen* is affected by cell infiltration in the splenic follicles. In the centres of the follicles masses of epithelial cells are sometimes found. There is local edema of the centre or the periphery of the follicles. Necrotic areas and hyaline changes are also present. No bacteria have been found in sections of the spleen.

The *lymphatic glands* first undergo congestion and hemorrhage and there is dilatation of the lymphatic sinuses. Later, foci very similar to miliary tubercles form, by a process of proliferation, phagocytosis, and degeneration. These changes are due to the toxins formed by the lymphatics and not to bacteria. The same changes, with minor modifications, take place in the tonsils.

The *thymus gland* undergoes the same changes described under lymphatic glands.

The *skeletal muscles* undergo fatty degeneration.

The *bone-marrow* undergoes hyperplastic changes.

The *pancreas* has not been found involved in autopsies following true diphtheria. Hibbard and Morrissy found *glycosuria* in 25 per cent of 230 patients. Others have failed to find it so commonly present. *Examinations for sugar should be made in every case of diphtheria.*

The *alimentary canal* may be affected by true diphtheria of the stomach. The pseudomembrane has not been found in the intestine.

The *liver* undergoes degenerative changes, ranging from simple fatty

to hyaline degeneration. Focal necrosis is the most characteristic change in this organ in diphtheria.

The *kidneys* undergo fatty and hyaline degeneration. Casts are present. There are also interstitial changes in about 25 per cent. of cases examined. There is an increase in the cells of the glomeruli, and sometimes necrosis with hemorrhage into the capsular space is present.

Types of Diphtheria.—Before considering the symptomatology, it will be well to briefly consider the various types of diphtheritic manifestations. It is often described according to the seat of local manifestation as angina, local or general; nasal diphtheria; bronchial diphtheria; broncholaryngeal (ascending) diphtheria; conjunctival diphtheria; aural diphtheria; vaginal and rectal diphtheria, etc.

Monti's classification, according to Northrup, in Nothnagel's *Encyclopedia of Practical Medicine*, is as follows:

Catarrhal Diphtheria (Bacteriological Diphtheria; Diphtheria Fruste).—This type is characterized by simple redness and swelling of the tonsils and the pharynx, with no false membrane. Microscopic examination shows the Klebs-Loeffler bacilli present. Spontaneous recovery occurs in a few days. The germs, transplanted into another throat, might give rise to a more severe type. Careful quarantine should be maintained to prevent the spread of the disease.

Fibrinous Diphtheria.—This type is due to the action of the Klebs-Loeffler bacilli uncomplicated by any other germ. It may be purely local in its character, the membrane and the slight redness surrounding it being the only symptoms; or it may be general, with a tendency for the false membrane to spread to other parts, with great toxemia and severe complications. It is more often local in its manifestations. Microscopic findings: the Klebs-Loeffler bacilli.

Mixed, Phlegmonous, or Streptodiphtheria.—This type is characterized by great inflammatory reaction in the neighborhood of the pseudomembrane, and by the presence of the Klebs-Loeffler bacilli with some other pathogenic organism, usually the streptococcus, and their toxins. Mixed infections are more dangerous, and experiments on animals (Roux and Martin) show that antitoxin has little or no effect in checking the ravages of this type of infection.

Septic or Gangrenous Diphtheria (Septicemia).—In dealing with this type, we are essentially treating septicemia of diphtheritic or of mixed infectious origin. It is usually of mixed infection (Klebs-Loeffler, streptococci, and staphylococci) origin, although in rarer cases it seems to originate from the simple Klebs-Loeffler bacillus infection, which has assumed the so-called gangrenous diphtheria type. In other words, what started out as a simple diphtheria later became complicated by other germs and their toxins, a true septicemia resulting. It is doubtful if true septicemia ever results from pure Klebs-Loeffler bacillus infection.

General Symptomatology.—The disease is ushered in by a feeling of discomfort, lassitude, loss of appetite, constipation, slight sore throat, difficulty in swallowing, and more or less hoarseness.

The *temperature* varies with the type, but has certain characteristics

which may be recognized. For instance, even in the fibrinous type, which is the least febrile, there is a rise of temperature with the beginning of the formation of the membrane. It is commonly said that this type is not attended by fever. Notwithstanding, it will be found, and there will be a recurrence of elevated temperature with each extension of the pseudomembrane to a new part. In all types of diphtheria there is an increase of temperature with each extension of the local field of infection. There is a greater fluctuation of the temperature curve in the mixed infection and the septic type than there is in the catarrhal and the fibrinous varieties.

The *pulse* rate is invariably increased in uncomplicated cases, in the beginning, in proportion to the toxic products eliminated. The pulse rate in infants is especially high.

Brachycardia (slowing of the pulse rate), if persistent, is a grave symptom.

Tachycardia (increased pulse rate), when reaching a rate of 140 or more, is a grave symptom. At 140 the death rate is about 20 per cent., increasing to 90 per cent. at a pulse rate of 180. Nasal diphtheria is usually the cause of the tachycardia, hence the occurrence of a rapid pulse should at once lead to a critical examination of the nasal fossæ. The nose is very richly supplied with lymphatic tissue, hence the rapid absorption and the toxic symptoms.

Reduced blood pressure, as shown by sphygmographic tracings, indicates an increased absorption of diphtheria toxins, and warrants a grave prognosis. The same is true of an intermittent pulse.

Partial angina is the most common anatomical form of the disease. Early there is a general redness of the pharynx and the pillars of the fauces. At the site of pseudomembrane formation, which is usually the tonsil, there is increased redness. It may form, however, on the posterior pillars, the uvula, or the walls of the pharynx. First one tonsil is involved, then the other. The cervical glands are somewhat swollen and tender. Temperature elevated 1° to 2° with frequent oscillations. General health good. Transient albuminuria. Course, six to eight days.

General or *toxic angina* is characterized by a thicker and more extensive pseudomembrane, gray or dirty yellow in color, or even brown or black. The whole, or nearly the whole, of the tonsils, the pillars (arches), the uvula, and the pharynx are covered by the membrane in from three to six days. Grave symptoms appear early, usually ushered in by a chill followed by fever. Delirium, restlessness, apathy, and vomiting are often present. Swallowing becomes difficult on account of the swollen and stiffened condition of the fauces and the pharynx. The epipharynx (nasopharynx) is filled with tenacious mucus. The cervical glands are swollen and tender. Albuminuria is pronounced. Without treatment the pseudomembrane may be cast off and be reformed, continuing thus for three to six weeks. Under proper treatment the disease may be brought under control in from three to six days.

Phlegmonous or *streptodiphtheritic angina* involves the entire throat from the beginning. The mucous membrane is dark red, and the uvula

swollen. Within a few hours a dirty gray or blackish membrane forms, and rapidly spreads. The cervical glands are much swollen and very tender. While the membrane is forming and spreading, the temperature is elevated. Toxic symptoms, as rapid pulse, delirium, restlessness, apathy, etc., set in after the membrane has reached its limit. The temperature usually drops at this time. Albuminuria often appears within forty-eight hours. Under antitoxin treatment the disease may be controlled in from five to six days. In obstinate cases the kidneys and the heart may become involved and thus complicate the case.

Septic angina is characteristic of certain epidemics, although it usually develops from the phlegmonous variety. The symptoms are most grave from the beginning. Vomiting is violent and attended by extreme prostration. The temperature curve rises very suddenly. The pulse is small, soft, and rapid. Respiration is increased proportionately. The tonsils and the fauces are swollen. They are a livid bluish white, with discolored spots. Bloody matter is mixed with the exudate. The cervical glands are very much swollen and tender on both sides. Death occurs usually on the second to the fourth day, from collapse and general sepsis.

Diphtheria of the nose may assume any one of the foregoing types, although it is probably more often of the simple fibrinous type. It may be primary or secondary. The upper lip is excoriated by the nasal discharge. The child "snuffles," sleeps a great deal, and takes food poorly on account of the nasal occlusion, and he may become cyanotic in attempting to nurse the breast. The glands of the neck are swollen. Nasal hemorrhage occasionally takes place. Many cases run a benign course, while others are malignant from the beginning, death occurring within a few days. In older children the disease runs a more favorable course. In scrofulous children it may be more chronic, often extending over many weeks.

The nasal occlusion is at first often thought by the parent to be due to a foreign body in the nose. The membrane is usually situated on the septum, although it frequently involves the whole Schneiderian membrane. and may be removed with the forceps or the syringe, as a cast of the interior of the nose.

In *phlegmonous, mixed,* or *streptodiphtheria of the nose* the symptoms are more pronounced from the beginning, the membrane is mixed with blood and appears black (black diphtheria). Toxic symptoms are marked, and the glands of the neck much swollen and tender. The patients are little inclined to take food. Early and vigorous treatment is often followed by recovery. The disease is, however, to be regarded as very grave in its nature. On account of the rich lymphatic supply of the nose, the septic form of nasal diphtheria is especially serious.

Laryngeal Diphtheria (True Croup; Membranous Croup; Diphtheritic Croup, Etc.).—Laryngeal diphtheria may be primary, although it is usually secondary to diphtheria of the nose, the pharynx and tonsils, the trachea and the bronchi. On account of the great danger, and at the same time a possibility of a favorable issue under proper treatment,

we will, according to Northrup, enter into a brief but careful analysis of this type of diphtheria. It should be studied under three headings, namely: (1) Stage of invasion; (2) stage of spasm—exudation; (3) stage of asphyxia.

Stage of Invasion.—This is characterized by a simple angina becoming suddenly complicated with hoarseness, and a cough characteristic of laryngeal irritation. The Klebs-Loeffler bacillus may or may not be found. A negative finding is not conclusive, however, as heretofore stated.

Stage of Spasm (Exudation).—The pseudomembrane may develop so rapidly that within twenty-four hours there is laryngeal stenosis. The cough is dry, short, and hoarse, becoming paroxysmal in character and often lasting for several minutes. It is attended by cyanosis, full veins, and a perspiring forehead. Aphonia, more or less complete, soon develops. The respiration is wheezing and noisy. As the stenosis becomes more advanced, the inspiratory act is prolonged and is attended by a whistling noise. There is pronounced depression of the supraclavicular region, the neck, and the epigastrium. The severe symptoms come in waves; extreme cyanosis, and harsh, difficult respiration, giving way, temporarily, thus affording the little sufferer a brief respite from the aggravated symptoms. The natural duration of this stage is from one-half to seven days.

Stage of Asphyxia.—This stage is characterized by greatly impeded respiration and toxic symptoms. The respiration becomes more rapid and irregular, the child sits up suddenly, and falls back again exhausted. The cyanosis and the retraction of the supraclavicular, the jugular, and the epigastric regions is more pronounced. The suffocative attacks occur more frequently. The head is thrown back, and all the accessory muscles of respiration are called into action. Even the abdominal muscles are retracted. The larynx rises with each inspiratory effort. During one of the suffocative attacks, complicated with convulsions, death comes. According to Monti, in untreated cases the death rate is from 95 per cent. to 98 per cent. Under modern methods of treatment the death rate is small in cases taken early.

Phlegmonous or Mixed Infection of the Larynx.—It is usually secondary to a similar process in the nose or the throat, and is characterized by great redness of the mucosa of the larynx and the trachea, with some grayish pseudomembrane scattered here and there in the larynx and the trachea. The stenosis of the larynx is not so marked as in the preceding type, nevertheless, death may occur suddenly from it. The toxic symptoms are also pronounced in this type, and no doubt contribute toward a fatal result.

Septic Diphtheria of the Larynx.—This is also secondary to a similar process in the nose or the throat, or both, and begins with fever, apathy, and marked weakness. The mucous membrane of the larynx and the nose is swollen, and covered with a grayish-yellow exudate. Toxic symptoms, as vomiting, delirium, suppression of urine, heavily coated tongue, rapid pulse, etc., are pronounced. The prognosis is quite grave.

Causes of Asphyxia in Diphtheria.—Four theories have been advanced: (*a*) Spasm of the glottis; (*b*) obstruction by pseudomembrane; (*c*) paralysis of the dilators of the glottis; (*d*) excitation of the respiratory centres by carbonic acid poisoning, and reflex action of the pneumogastric nerve.

Autopsies have shown many instances of death from asphyxia when there was little or no false membrane to account for it. This leaves spasm of the glottis, paralysis of the dilators, and the irritation from carbonic acid as possible theoretical explanations. The latter two have but few supporters; hence the probable explanation of the majority of cases is to be found in the first theory, namely, spasm of the muscles of the larynx.

Diphtheria of the Trachea and the Bronchi.—This is usually secondary to laryngeal diphtheria, although it may occur primarily in the bronchi or the trachea. Where it thus forms, and the larynx is secondarily involved, it is known as "ascending croup." If a cast of the bronchi is coughed up, it is a positive sign of bronchial involvement. Other signs, as respirations 50 to 60 per minute, continuous dyspnea (as contrasted with intermittent when the pseudomembrane is in larynx and upper trachea), supraclavicular and epigastric depressions not so well marked, pale face, blue lips, and great physical depression, may aid in reaching a diagnosis of bronchial diphtheria. The prognosis is very grave.

Diphtheria of the Ear.—This is usually carried to the external ear by scratching (abrasion) with the infected fingers of the patient. Infection of the external auditory meatus is seen in rare instances in which there is diphtheritic otitis media with extension through the tympanic membrane.

Otitis media complicating diphtheria occurs in only about 4 to 6 per cent. of the cases. When present it is characterized by deafness, pain in the ear upon swallowing and coughing, followed by aural discharge, after which the pain subsides.

Diagnosis.—The differential diagnosis of diphtheria should be made between (*a*) peritonsillar abscess; (*b*) follicular tonsillitis; (*c*) pseudodiphtheria; (*d*) pseudocroup; and (*e*) catarrhal rhinitis, the chief diagnostic point in each case being the microscopic and the culture findings.

Prognosis.—This may be summarized under the following headings:

(*a*) **The Age of the Patient.**—The mortality is the lowest in the first year and the tenth year, and the highest in the second to the sixth year of life.

(*b*) **The Site of the Local Lesion.**—The larynx furnishes the highest mortality. Nasal diphtheria in infants is very fatal.

Treatment.—Antitoxin treatment has reduced the cases coming to operation one-half. The death rate in laryngeal cases under antitoxin has been reduced from 70 per cent. to 16 per cent. Intubation is attended by a better mortality table than tracheotomy.

Time of Beginning Treatment.—Briggs and Guerard have compiled the following table:

	Cases.	Deaths.	Mortality Per cent.
First day of disease	1415	5	3.5
Second day of disease	2640	213	8.0
Third day of disease	2340	300	12.8
Fourth day of disease	1458	346	23.6
Fifth day of disease	1912	671	35.0

It will be seen by the foregoing table that early treatment influences the prognosis very favorably.

Complications and Sequelæ of Diphtheria.—Adenopathy.—Swelling of the lymphatic glands in the region of the local diphtheritic lesion is the rule. The cervical glands and the tonsils are accordingly most commonly affected. After these come the bronchial, the intestinal, and the mesenteric glands.

In the *pure diphtheria, i. e.*, the simple fibrinous type, the glands are swollen, slightly tender, and freely movable in the surrounding tissue.

In the *mixed forms* of infection there is greater swelling and tenderness, the glands being lost to the touch in the surrounding swollen and infiltrated tissue. In some cases the swelling is enormous, constituting the symptoms known as "le con proconsulair." Suppuration occurs only occasionally, and then only in the mixed type. In the *septic type* gangrenous sloughing may occur. Treatment often results in recovery from even severe diphtheritic adenopathy.

Gastro-intestinal.—Vomiting, loss of appetite, diarrhea, and diphtheria of the esophagus and the stomach sometimes occur.

Urine.—The urine is variable in quantity and chemical proportions. Probably one-half of all cases of diphtheria are albuminuric, the toxic varieties having albumin present in nearly all cases. The albuminuria is generally due to degenerative changes in the kidneys. Hyaline, granular, and epithelial casts may be found.

"In diphtheria a well-marked increase is the rule, and with the exception of very mild or extremely severe cases, of constant occurrence. It is interesting to note that, barring a temporary diminution immediately after the injection, the leukocytosis is nowise influenced by the antitoxin treatment." (Simon.)

Hyperleukocytosis.—This exists in nearly all cases, depending upon the toxemia and the sepsis present. It may be so pronounced as to constitute a true leukemia.

Heart Lesions.—Endocarditis, myocarditis, waxy degeneration, nerve degeneration, heart clots, and dilatation have been found in some certain cases examined postmortem.

Nervous Affections.—Degeneration of nerve tissue, paralysis, lessened functional activity, etc., sometimes attend, but more often follow, an attack of diphtheria.

Postdiphtheritic Paralysis.—Postdiphtheritic paralysis usually affects the velum palati (benign and discrete form) and the pharynx. The chief symptom present is difficulty in swallowing and the return of liquids through the nose. Each act of swallowing is accompanied by a laryngeal cough. The voice is nasal, articulation very much interfered

with, and the patient snores during sleep. The paralysis disappears in from one to three weeks.

In the general or diffused postdiphtheritic paralysis the palatal and the neighboring muscles are involved. The muscles of the eye are most frequently affected. Unequal pupils, diplopia, strabismus or ptosis may be present. Complete recovery eventually takes place. The patellar reflex is impaired, or lost, and the muscles of the feet may be paralyzed. The patients shuffle their feet on the floor in walking. "Diphtheritic pseudotabes," or even complete paralysis of the lower extremities, may complicate some cases. The muscles of the upper extremities are less often affected. The muscles of the neck and the head are rarely involved. If they are, the child's head falls over on his shoulder. The facial expression may be lost, giving an idiotic cast to the countenance.

Diaphragmatic paralysis occurs in about 7 per cent. of cases, and may lead to a fatal termination. The chief sign of diaphragmatic paralysis is a sinking in of the abdomen during inspiration, and distention during expiration. Respiration is rapid and panting. Bronchitis or other slight lesion of the lower respiratory tubes may lead to asphyxiation and death.

Cardiac or **Vagus Paralysis** complicates about 1 per cent. of the cases.

Skin.—Erythema, papular eruption, brownish discolorations, and measles and scarlet-fever-like eruptions of the skin may complicate the disease.

Bronchopneumonia.—This is a serious complication, often causing death after tracheotomy and intubation. It is ushered in by a rise in temperature, increased cyanosis (in laryngeal cases), change of the respiration-pulse ratio from normal 1.4 to 1.3. At first the physical signs are those of diffuse bronchitis, later of consolidation over several areas.

Prophylaxis.—The following rules should be observed in preventing the spread of diphtheria. (Abstracted from the Rules of the Health Department, City of New York.)

1. No one but the attendant and the physician should be permitted to enter the sick chamber.

2. The discharge from the nose and the mouth should be received on cloths provided for the purpose, and immersed for two or three hours in a solution composed of six ounces of carbolic acid dissolved in one to two gallons of hot water, and then boiled in soap-suds for one hour. All bed and personal clothing used about the patient should be similarly treated *inside the sick room.*

3. The hands of the attendant and the physician should be washed in the same carbolic acid solution, and washed in soap-suds after making applications or handling the patient, and before eating.

4. Surfaces soiled by discharges should at once be flooded with carbolic acid solution.

5. Table utensils used by the patient should be *kept in the sick room,* for his especial use, and should be washed in carbolic acid solution and

then in hot soap-suds. The soap-suds vessel should then be washed in the carbolic acid solution.

6. The sick room should be aired two or three times daily, and swept frequently after scattering sawdust, wet tea-leaves, etc., on the floor to prevent the dust from rising. The furniture and the woodwork should be wiped with damp cloths. The sweepings should be burned, and the cloths soaked in the carbolic acid solution.

7. All unnecessary articles of furniture, pictures, draperies, clothing, etc., should be removed from the room as soon as the nature of the malady is recognized.

8. When the patient has recovered, he should receive a hot soapsuds bath, including his hair, clean clothes put on, and be removed from the sick room. He should be kept in quarantine as long as cultures of the diphtheria germ can be obtained from his throat.

In addition to the rules given in regard to the patient and the sick room, the physician and the nurses should protect their clothing by wearing long gowns, which should be kept just outside the patient's room.

9. They should also be given immunizing doses of antitoxin.

10. The room should be scrubbed with bichloride of mercury solution, 1 to 1000, *all over*, woodwork repainted or varnished, walls cleaned and repapered, and the furniture sterilized with formaldehyde vapor, or, in the case of upholstered furniture, disinfection is better done by steam.

11. The periodical inspection of public schools by a corps of physicians will do much toward limiting the spread of the disease.

Immunization by Antitoxin.—An immunizing dose of antitoxin ranges from 100 to 500 units, according to the age of the patient and the length of time immunity is desired. In an average case 100 units will be effective for ten days, while 500 units will be so for twenty-eight days.

Treatment of Diphtheria.—The treatment may be divided into (1) local, (2) general, and (3) measures for the relief of the suffocation.

Local Treatment.—This consists in the use of an antiseptic solution, such as boracic acid, chloride of sodium, etc., at a temperature of 110°, with a fountain syringe. The patient should be wrapped tightly in a sheet fixed with safety pins. He should be placed upon his side and the glass or hard-rubber nozzle of the syringe applied to one nostril, the fluid flowing out at the other, until it comes forth clean. The patient's mouth should be held open with a spool or a mouth gag to prevent swallowing, as this act might force the solution into the middle ears and cause infection and mastoiditis. The pharynx should be treated in a similar manner. If it is desirable to combat pain and swelling, the solution should be about 130° The irrigations may be repeated at intervals of six hours.

General Treatment.—The general treatment of diphtheria consists in the administration of stimulants to overcome the depression, the weak heart's action, the irregular pulse, and the septic condition. Alcohol, in the form of whisky or brandy, is the best for this purpose, and should be given to an infant in 10 to 15 drop doses, well diluted with water,

three or four times a day. A child of three or four years may be given an ounce in twenty-four hours. In septic cases much more can and should be given. Strychnine is the second best stimulant. Dose, child one year old, $\frac{1}{100}$ grain every two or three hours. Child three to four years old, $\frac{1}{50}$ grain every two or three hours.

Sedatives should be given to relieve restlessness, cough, and spasm (second stage) in laryngeal cases. Morphine in $\frac{1}{20}$ to $\frac{1}{12}$ gr. doses. Emetics may be given to overcome spasms and to remove mucus in the laryngeal cases.

Antitoxin in Diphtheria.—The value of antitoxin is shown by a comparison of the following tables:

TABLE I.—By Briggs and Guerard.

	Treated with antitoxin.		Mortality.
Ages.	Cases.	Deaths.	Per cent.
0–2 years	1494	469	31.4
2–5 years	3678	762	20.7
5–10 years	3184	473	14.8
Over 10 years	1444	99	6.0

TABLE II.—By Baginsky.

	Not treated with antitoxin.	Mortality.
Ages.		Per cent.
0–2 years		63.3
2–4 years		52.8
4–6 years		37.9
6–10 years		24.6
10–15 years		14.6

The advantages of the antitoxin over the other methods of treatment at the various ages is strikingly shown by a comparison of the foregoing tables, and needs no further comment.

Antitoxin in laryngeal cases is valuable in two ways, namely: (*a*) It prevents many cases coming to the operative stage, and (*b*) it affects favorably the intubated and tracheotomized cases. Statistics go to show that it affects the intubated cases more favorably than it does those upon which tracheotomy has been performed.

Antitoxin in relation to *paralysis* seems to increase it rather than to decrease it. This is perhaps explained by the fact that cases treated with antitoxin live longer, and thus give more time for it to develop. Many more bad cases survive.

Antitoxin injections often produce a *transient albuminuria.*

Dosage and Clinical Administration of Antitoxin.—The following dosage is recommended: (*a*) 2000 to 3000 units in ordinary diphtheria to a child over one year old; (*b*) 3000 to 5000 units in severe laryngeal cases of any age; (*c*) 1500 to 2000 units to an ordinary case in a child under one year old.

Repeat the dose in twelve hours, or less, if the symptoms are increasing, and in eighteen to twenty-four hours if there is not decided improvement. A third dose may be given, if needed, in twenty-four hours.

An ordinary sterilized *hypodermic syringe* holding 5 c.c. is suitable for making the injections. The skin should be cleansed with an antiseptic solution.

Place of Injection.—The skin of the thigh, the posterior axillary line of the chest, or the abdomen are favorable locations.

Effects of Antitoxin on the Pseudomembrane.—In a few hours after the injection it becomes blanched, the dirty color less pronounced, and the membrane more granular and swollen. Later it becomes loosened around its edges, and rolls up, detaching itself spontaneously or after irrigation. If the membrane returns repeat the dose of antitoxin at once.

Fig. 273

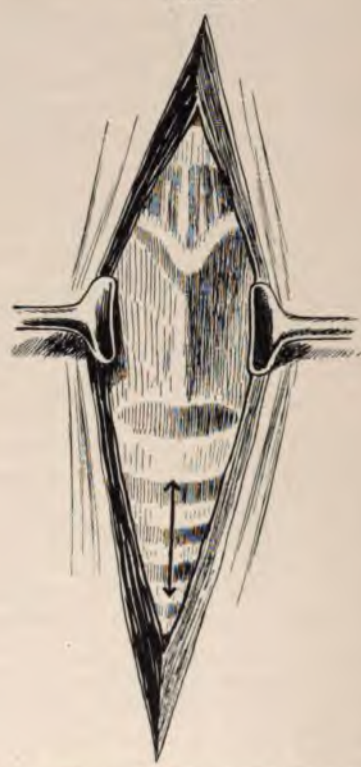

The line of incision in upper tracheotomy preparatory to laryngeal fissure or laryngectomy.

Effects on the Temperature.—In pure or simple diphtheria the temperature rapidly returns to the normal, whereas in the mixed cases it comes down more slowly. If the temperature does not fall in the regular way, a second injection is indicated, provided the temperature cannot be accounted for by some complication.

Indications for Antitoxin.—1. In mild suspicious pharyngeal, nasal, buccal, conjunctival, or cutaneous cases, give antitoxin if the child is over one year of age and there is a distinct history of exposure.

2. In suspicious laryngeal cases give antitoxin *at once*, and make microscopic and culture examinations afterward.

3. All catarrhal cases require antitoxin.

4. In pseudodiphtheria, with repeated negative findings as regards the Klebs-Loeffler bacillus, antitoxin need not be given. If in doubt, however, give it.

Surgical Treatment.—*Tracheotomy.*—This operation is not now in vogue, relatively, as it was in former years. Intubation is usually elected in its stead, as it is a safer and surer means of tiding the patient over the suffocative period. Nevertheless, there are still cases in which tracheotomy is indicated.

The *indications* for tracheotomy are: (*a*) When intubation tubes are not available, or if, for any reason, their use is not understood (Northrup); (*b*) in excessive edema of the larynx, where the intubation tube does not give relief; (*c*) when the membrane is in the lower tracheal tract, though these cases are favorable for tracheotomy.

Fig. 274

Tracheotomy tube.

Fig. 275

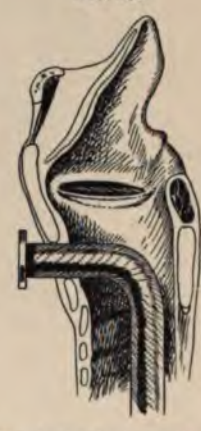

Tracheal tube in position.

The *method of performing tracheotomy* now in use is known as the high operation, in contradistinction to *tracheotome inférieure*, as first practised by Trousseau. In the low position of Trousseau, the blood-vessels passing over the field of operation render the operation difficult.

High tracheotomy is preferable. It should be done under antiseptic precautions, although this is not always practicable, on account of the urgency for immediate relief.

Steps.—(*a*) The cricoid cartilage should be located with the index finger of the left hand, while the larynx is held firmly but lightly between the thumb and the second finger.

(*b*) The skin and the subcutaneous tissue should now be incised, beginning with the location of the tip of the index finger, carrying it downward in the median line ½ inch to 1 inch (Fig. 273).

(*c*) With the tip of the index finger in the superior angle of the wound,

the bistoury should be passed under it into the trachea and the incision carried downward in the median line far enough to admit the finger into the wound. With the finger thus placed blood cannot enter the trachea. A still better practice is to first check all bleeding with artery forceps or ligatures, and then open the trachea. If suffocation is imminent, the first method may be adopted.

(*d*) The cannula (Figs. 274 and 275) should next be introduced as the finger is gradually withdrawn. If necessary, the dilator and the retractors may be used.

(*e*) The cannula should now be secured in its position by pieces of tape passed around the neck.

(*f*) If the suffocation is not relieved at once, there is either pseudomembrane still lower down in the trachea—perhaps a detached piece over the orifice of the cannula—or the cannula has become filled with

Fig. 276

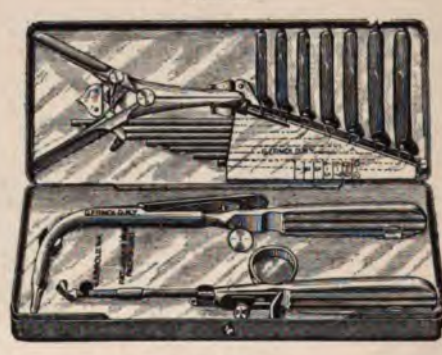

Dwyer's intubation instruments.

mucus and shreds of pseudomembrane. In this event the inner cannula should be removed and cleared of mucus, etc. (*g*) If the removal of the inner cannula does not relieve the suffocation, there is probably membrane low down in the trachea.

The *mishaps* or *accidents* which may attend the operation are: (*a*) Failure to open into the trachea, especially in very fat children; (*b*) hemorrhage where the incision is carried too far to either side or too far downward; (*c*) an irregular or too small incision, making the introduction of the cannula difficult; (*d*) secondary hemorrhage; (*e*) asphyxiation from dislodged membrane; (*f*) a too greatly retracted head, thus flattening the trachea and causing stenosis.

The *after effects of tracheotomy* may be summarized as follows: (*a*) Disappearance of the cyanosis and suffocation; (*b*) sleep; (*c*) coughing with expulsion of pieces of membrane and mucus through the cannula; (*d*) slight fever of two to three days' duration.

The *complications* which may arise are: (*a*) Infection of the tracheal wound, the bronchi, and the lungs; (*b*) ulceration of the trachea at the

tip of the cannula; (*c*) erysipelas of the wound; (*d*) and most important of all, bronchopneumonia from the second to the seventh day after the operation. When this occurs the prognosis is very grave.

The *after-treatment* consists in: (*a*) The removal of the inner cannula every two or three hours for cleansing; (*b*) the external cannula should be removed and cleaned every twenty-four hours, the child being placed flat on his back as in the operation—the wound should be cleansed each time the external cannula is removed; (*c*) under antitoxin it is not probable that the cannula will need to be worn after the third day, whereas under the older methods of treatment it was usually worn a week or more.

Fig. 277

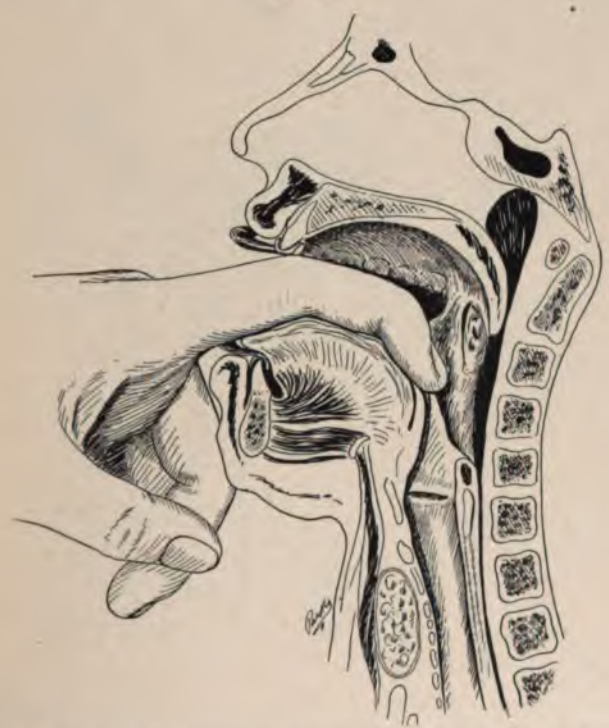

The index finger of the left hand holding the epiglottis against the base of the tongue preparatory to intubation. (After Shurley.)

The author recently removed the cannula from a child who had worn it for four years. It was necessary to first dilate the glottis with curved Heryng bougies introduced through the tracheal opening. After a few treatments laryngeal respiration was sufficiently restored, and the tube was removed. An attempt was afterward made to close the tracheal wound, but the anterior wall of the cartilaginous rings of the trachea had disappeared from pressure necrosis. The skin, when brought over the wound, acted as a valve closing the trachea, asphyxia resulting.

Intubation.—To O'Dwyer is due the credit of first practising intubation upon his charity patients. The tubes used at that time were straight and easily expelled. Being discouraged by the many obstacles in his way, he was almost persuaded to abandon the practice. At about this time Dr. F. E. Waxam successfully intubated a patient in private practice. Dr. O'Dwyer was greatly encouraged by Dr. Waxham's success, and improvement in the tubes and instruments for their introduction and removal rapidly followed, and, though there was much opposition, intubation became one of the recognized therapeutic measures in stenosis from laryngeal diphtheria.

Fig. 278

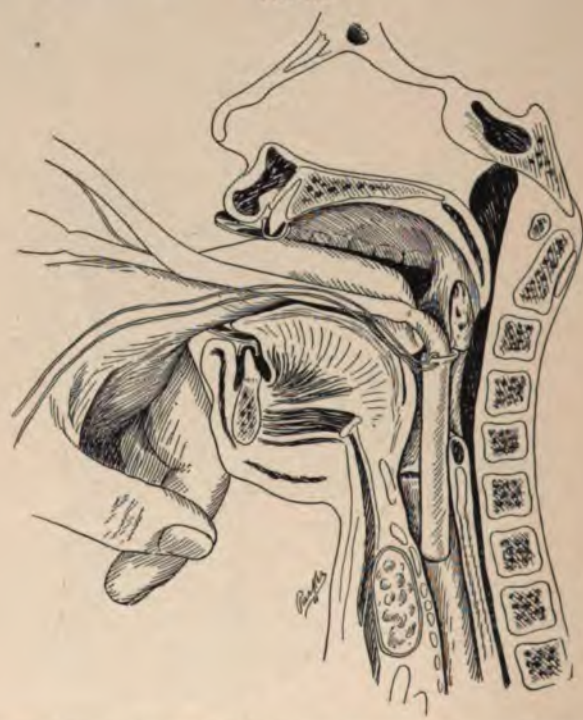

The tube passing through the chink of the glottis, the index finger still holding the epiglottis against the base of the tongue. A stout loop of thread is attached to the tube to provide for its speedy removal in case suffocative symptoms follow its introduction, and in case it is accidentally engaged in the esophagus.

The introduction of antitoxin has very greatly reduced the necessity for intubation, though there are still many cases in which it is indicated.

Indications for Intubation.—(*a*) Pronounced tracheal stenosis, as shown by greatly retracted supraclavicular and epigastric areas calls for the immediate resort to intubation, even though antitoxin has been given and sufficient time has not elapsed for its favorable influence. If milder suffocative symptoms are present, and antitoxin has been given, intubation may be delayed pending the results of the antitoxin. Since

the use of antitoxin not one-half as many cases come to operation as formerly. (*b*) If the physician is not within easy call, it is safe to intubate without waiting for pronounced suffocative symptoms.

Technique of Intubation.—The child is prepared for intubation by wrapping it in a sheet or a blanket from the shoulders downward. The sheet should be secured with strong safety pins, so as to bind the arms and legs of the child. This being done, the nurse should sit upright in a chair with the child upon her lap, his head resting against her left breast. His legs should be secured between hers, her right hand grasping his left, and her left hand his right. The assistant should stand behind

Fig. 279

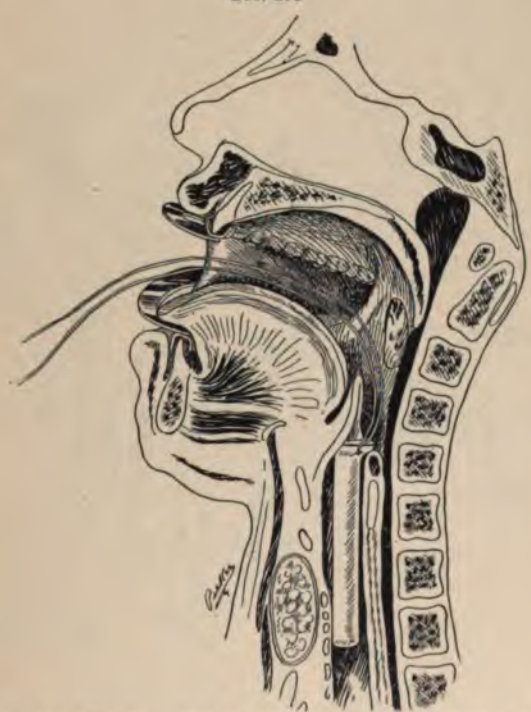

The tube in position in the larynx. The loop of thread is still attached, as the tube may have to be removed by the nurse to relieve impending suffocative symptoms.

the nurse and hold the child's head between his hands, as though suspending the child from the parietal walls of his cranium. A proper sized tube (Fig. 276), threaded with silk through its eyelet, should be in readiness. The operator should stand or sit in front of the child, introduce the mouth gag, turn it over to the assistant, who holds it between his hand and the patient's left cheek while the operator introduces the index finger of his left hand and hooks it over the epiglottis (Figs. 277 and 278). Then crowding his finger as far to the left as possible, the intubation tube, on the introducer, is carried

into the mouth, closely hugging the centre of the posterior portion of the tongue, the handle of the introducer being on the chest of the child. As the tip of the tube passes back of the epiglottis under the finger of the operator, the handle should be gradually elevated, until the tip of the tube is directly over the chink of the glottis, when it should be suddenly lowered, thus passing the tube into the box of the larynx, and on downward into the glottis and the trachea. The tip of the finger then engages the rim at the head of the tube (Fig. 280), the introducer is loosened and removed, and with a gentle pressure the tube

Fig. 280

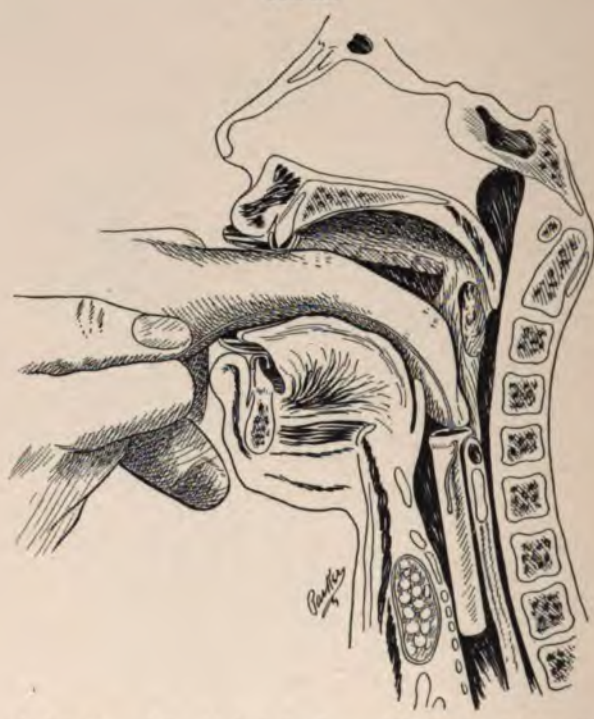

The removal of the loop of thread, the index finger of the left hand being placed against the head of the tube to prevent its displacement.

is firmly pushed deep into the larynx and the trachea. If, after waiting twenty to thirty minutes, the child tolerates the tube, the loop of string should be cut (Figs. 279, 280 and 281), the index finger re-introduced against the head of the tube, and the string removed. For obvious reasons the child should be kept wrapped until the string is removed. Fig. 282 shows a false entry of the tube into the esophagus because the handle of the introducer was not sufficiently elevated before the tube was dropped into the laryngeal box.

Intubation may also be performed in the dorsal position, the same relative positions and steps being observed as in the upright position.

Extubation or the Removal of the Tube.—The removal of the tube may be done by observing the same precautions used in intubation, the index finger of the left hand guiding the extractor to the opening in the tube (Fig. 283). Another method now occasionally used is to leave the silk string attached, looping it over the left ear and securing it to the cheek with adhesive plaster. The removal of the tube is thereby rendered quite easy. It is also easy for the child to remove it, hence this is a serious objection to the method. One grain of Dover's powder, or $\frac{1}{16}$ to $\frac{1}{12}$ gr. of morphine, may be given a few minutes before extubation, to prevent spasm and re-intubation for its relief.

Fig. 281

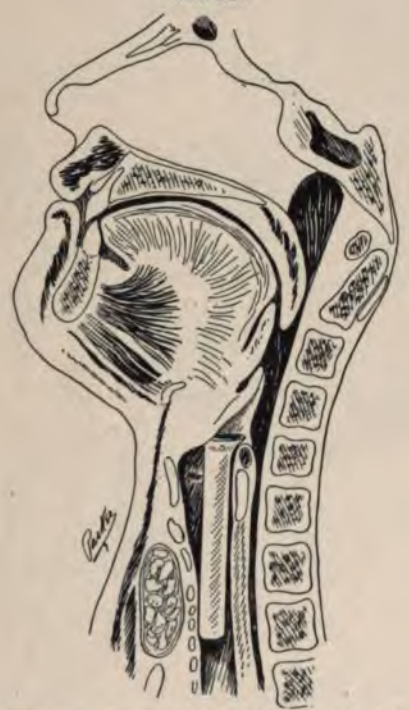

The tube in position after the withdrawal of the thread.

When to Remove the Tube.—Under antitoxin treatment the tube may ordinarily, in a child over two years of age, be removed in from three to five days. Should the tube become obstructed, it should be immediately removed.

Complications and Difficulties.—(*a*) If the finger of the operator is short and stubby, it may be difficult to introduce the tube beside and beneath it. (*b*) The tube may make a false passage through the ventricles of the larynx. (*c*) The prolonged efforts of an awkward or inexperienced operator may cause suffocative symptoms. (*d*) Transient spasm of the glottis may cause temporary delay in introducing the tube. (*e*) The

narrowest point through which the tube must pass is the cricoid ring, and edema or swelling at this point may give rise to some difficulty in introducing it.

A smaller one may be passed with slight force. The action of the tube in being expelled in this condition has been aptly said to "creep back like an oiled cork in a bottle." (*f*) Prolonged retention of the tube may be necessary on account of the persistence of the pseudomembrane, ulcerations about the cricoid cartilages, traumatisms, cicatricial contractions, edema, abductor paralysis, or exuberant granulations.

FIG. 282

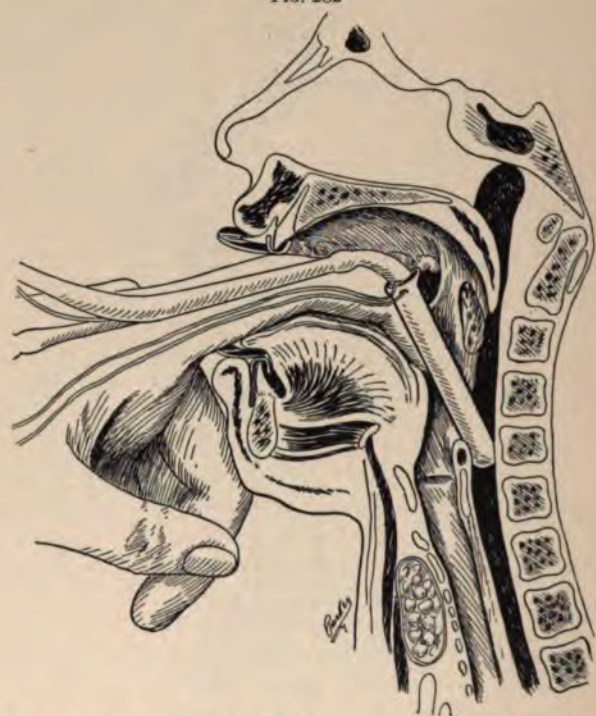

Making a false passage into the esophagus on account of lowering the handle of the obturator. The tip of the tube should be introduced by the side of the finger tip, and the handle of the obturator elevated until the tube stands perpendicularly, and then passed directly downward through the chink of the glottis.

(*g*) More rarely, the tube may be swallowed (no danger from it). (*h*) The tube may become obstructed by the thread or catgut being aspirated into it and swollen by the secretions; even food may obstruct it.

The Feeding of Intubated Children.—Most cases take liquid food very well in the upright position, although some take it with pain and cough. If the upright position is not practical, Casselberry's position may be resorted to. It consists in placing the patient on his back with a pillow beneath the shoulders, his head bent downward and backward at an angle of 45°, the legs being elevated (Fig. 284). Liquid or semisolid

Fig. 283

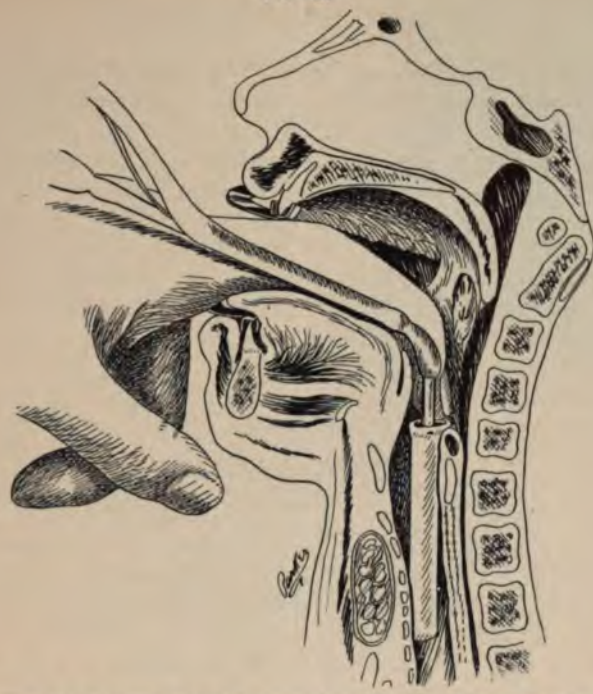

The introduction of the obturator for the removal of the tube. The finger is first introduced to lift the epiglottis and to guide the tip of the obturator into the intubation tube.

Fig. 284

Feeding an intubated child with a nursing bottle. Casselberry's position. The shoulders are raised to allow the head to assume a lower position than the shoulders.

food may be given in this position. The child should be allowed to swallow several times before assuming the upright position, to remove the food from the epipharynx. Hillis places the patient upon his stomach, as shown in Fig. 285. Gavage may be resorted to if the pharynx and the larynx are not too swollen and painful. The tube

Fig. 285

Feeding an intubated child through a rubber tube by suction.

should be introduced through the nose and rapidly passed into the esophagus. Food being poured into the funnel passes into the esophagus and the stomach. When removing the tube, pinch it to prevent the liquid passing into the larynx as it comes out.

Rectal alimentation may be resorted to if feeding by either of the foregoing methods is not practicable.

CHAPTER XXVI.

PACHYDERMIA LARYNGIS. MALFORMATIONS AND DEFORMITIES. PROLAPSE OF THE VENTRICLES. STENOSIS. SUBGLOTTIC STENOSIS.

According to Chiari, "the verrucous form of pachydermia is identical with the papilloma of the laryngologist, and has no relation to the diffuse form. Diffuse pachydermia may be primary, or it may be secondary to some other affection of the larynx, such as tubercle or syphilis." In Chiari's experience typical pachydermia is a very rare disease. He describes the following forms:

"1. The most frequent and mildest form is a thickening and loosening of the epithelium of the interarytenoid fold and the vocal cords, such as frequently occurs in chronic catarrh. The treatment is the same as for chronic catarrhal laryngitis and consists of inhalations, insufflations, applications by means of a brush, and cauterization. The best applications are lactic acid and iodine. The nitrate of silver is apt to cause increased thickening. Small singer's nodules may disappear under the influence of rest and the application of the nitrate of silver in solution or in the solid stick. If they are of considerable size, forceps should be used to remove them (Fig. 271).

"2. The typical form of pachydermia laryngis (chorditis nodosa), as it affects chiefly the vocal processes, calls for a plan of treatment varying according to the circumstances of the case, authors differing greatly in their opinions. Some recommend purely expectant treatment and avoidance of tobacco, strong drinks, and the abuse of the voice; others recommend the internal administration of the iodide of potassium, which, though occasionally of some benefit, may also at times produce general impairment of health." Chiari recommends the use of electrolysis, as employed by Moll, of Arheim, a current of from 10 to 12 milliamperes being used for from three to five minutes at a time. He considers it the best means of preventing recurrence, though good results have also followed operative procedures.

"3. Large genuine pachydermia growths in the interarytenoid space interfere very materially with the voice. Unfortunately, treatment by means of cutting forceps, hot or cold snares, etc., do not guarantee freedom from recurrence.

"4. The last group includes those circumscribed thickenings, outgrowths, or nodules which accompany tuberculosis, syphilis, chronic perichondritis, and perhaps also lupus, which have been referred to as secondary or "accessory" pachydermia. The prognosis depends on their etiology, as also does the treatment, the latter varying according to the

nature of the most distressing symptoms. Naturally the syphilitic form is much more favorable than the tuberculous, though not infrequently it resists specific remedies. Operative treatment of the same kind as for the typical primary form is called for in suitable cases; that is, if the general health is good and the respiration or voice is not seriously interfered with by the local disease. The method of treatment which is most highly recommended is the use of electrolysis by means of a bipolar instrument with a current of from 10 to 15 ma. This causes no reaction, and seems to protect against recurrence better than any other treatment.

"There is no doubt that pachydermia laryngis, whether in the simplest form in the interarytenoid space or in the typical form on the processes vocalis, is only a symptom of chronic catarrh, and is not to be looked upon as a disease in itself."

MALFORMATIONS AND DEFORMITIES OF THE LARYNX.

Malformations of the larynx may be either congenital or acquired. But little is known concerning the true cause of congenital malformations, only that some paternal disease or taint acts as a predisposing factor. Acquired deformities are the result of postnatal disease.

Malformations of congenital origin are often associated with arrested development of the genitalia. The lungs, the bronchi, and the trachea have the same embryological origin (the foregut) as the larynx, hence in malformations of the larynx there is also a similar defect in these organs. In monstrosities having no larynx the lungs are absent also. If the larynx is diminutive the lungs are likewise affected. Of the other congenital deformities, webs or bands across the glottis are a common form. The webs usually connect the vocal cords at the anterior commissure, though they are sometimes between the ventricular bands. They are of a pale color, but may be differentiated from the vocal cords by their position. Sometimes they are fragile and sometimes resilient. The perforated diaphragm variety is rare, and is associated with poorly developed lungs. Another form consists of clefts in the interarytenoid space extending to the palate and the cricoid cartilage. The epiglottis is often deformed by arrested development, the small V-shaped epiglottis of childhood being a common variety. Very small, and total absence of the larynx have been reported.

Hypertrophy or *hyperplasia* at the anterior commissure has been mentioned as being of congenital origin.

Laryngocele (dilatation of pouches) is due to congenital malformation and failure of union in portions of the thyroid cartilage. It is rare in man, though common in the lower animals.

In *acquired malformations*, erosions from syphilis, tuberculosis, etc., may result in the partial destruction of the framework of the larynx, the epiglottis often also being thus partially destroyed.

Acquired stenosis (see also Stenosis of the Larynx) may follow traumatism or constitutional causes, as syphilis. These cases are serious

on account of the edema and the dyspnea. Tracheotomy or intubation may become necessary. Redundant granulations following the prolonged use of the tracheotomy tube caused laryngeal stenosis in one of my cases. The child had been tracheotomized four years before he came under my care, and upon examination I found him unable to breathe through his larynx. The larynx was opened by bougies passed upward through the tracheal wound and through the glottis. This procedure was done under general anesthesia.

Hypertrophies or growths, usually of a *papillomatous nature*, form at the anterior commissure in either the single or the multiple variety. Microscopically they appear as local hypertrophies of the mucous membrane, having a stratified epithelial covering, enclosing a core of connective tissue with some bloodvessels and a glandular substance near the base. Indeed, they are but elevations of the normal tissue. This seems to distinguish them from true papilloma. While these papillomatous elevations of the mucous membrane are congenital, mouth-breathing, according to Lennox Browne, tends to perpetuate them.

PROLAPSE OF THE VENTRICLE OF MORGAGNI.

Watson Williams claims there can be no prolapse of the ventricles, but that which appears to be a prolapse is, in fact, an infiltration of the tissues. This is apparently supported by the fact that nearly all reported cases have been either syphilitic or tuberculous. On the other hand the tumor-like mass is quite soft to probe pressure, and a number of observers have reported successful, though fugitive, replacement of the pouching membrane.

The presence of this condition should arouse suspicion of either syphilis or tuberculosis. The treatment by local applications is useless. Replacement, followed by cauterizations to excite inflammatory reaction, offers some hope of permanent cure. The extirpation of the mass with cutting forceps, or by thyrotomy, may be resorted to if simpler measures fail. Antisyphilitic remedies should first be tried, however, before surgical interference is attempted, unless it becomes necessary to perform tracheotomy to relieve suffocative symptoms.

STENOSIS OF THE LARYNX (MALFORMATIONS OF THE LARYNX).

Stenosis of the larynx properly comes under malformations, but its importance merits separate treatment; hence, the various types of stenosis are included in this section, regardless of their relationship to malformations. Stenosis arising from constitutional disorders, as syphilis, tuberculosis, and leprosy, each have their peculiarities.

Syphilitic Stenosis.—There are three prominent conditions arising in the course of syphilitic laryngitis which may cause laryngeal stenosis, namely:

(*a*) Chronic edema.
(*b*) Cicatricial contraction or webs.
(*c*) Hyperplastic or papillary growths.

(*a*) **Chronic Edema.**—Chronic edema is commonly present in syphilitic laryngitis, though it does not always seriously occlude the glottis. Nevertheless, it presents favorable conditions for the supervention of an acute process, which may produce serious stenosis. This is especially true in children who inherit a syphilitic taint. Such children are very liable to acute edema, which gives rise to symptoms quite like those found in croup. Fortunately the infantile cases respond quickly to antisyphilitic remedies. In adults, as well as in children, the treatment consists in the administration of the iodide of potash or iodonucleoid, which often reduces the local edema in a short time.

Fig. 286

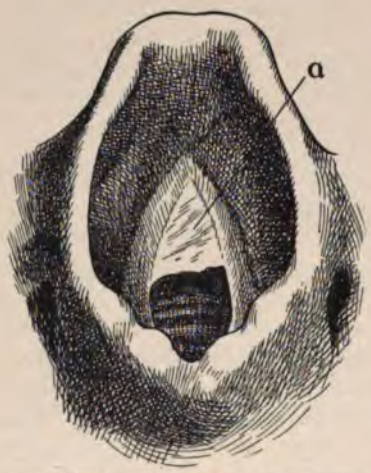

a, cicatricial webb across the anterior commissure of the vocal cords.

It should be stated that it is the tertiary stage of syphilis that results in stenosis, hence the treatment should be conducted accordingly.

(*b*) **Webs and Cicatricial Contraction.**—Webs and cicatricial contraction are the most common manifestation of syphilitic laryngitis. The webs vary in color and thickness. They are usually pale, and may be indistinguishable from the cords over which they extend. The vocal cords and the ventricular bands are usually bound together, and the web often extends across the chink of the glottis, especially at the anterior portion (Fig. 286). Lennox Browne cites a case in which the epiglottis was bound down by cicatricial adhesions.

The voice is hoarse or restricted in its register, while the breathing is dyspneic. The degree of the dyspnea depends upon the amount of edema and fixation of the cartilages, as well as upon the overlying web or cicatricial contraction. When a patient gives a history of recurrent attacks of dyspnea extending over several years, it is good presumptive evidence that he is suffering from syphilis of the larynx. A spasmodic cough, not unlike that in pertussis, is usually present. Pain is not uncommon. There may be an admixture of syphilis and tuberculosis, which may somewhat obscure the diagnosis.

(*c*) **Hyperplastic or Papillary Growths.**—These usually form near the anterior commissure of the glottis, and they may be either single or multiple. The treatment should be antisyphilitic and expectant. If they produce stenosis, they should be removed with the curved laryngeal forceps or the snare, or by laryngofissure.

Tuberculous Stenosis.—Tuberculosis of the larynx does not often close the glottis by cicatricial contraction, as is so frequent in syphilis. This is explained by the slight reparative effort following tuberculous ulceration. It may produce stenosis by the excessive infiltration of the arytenoid cartilages, which may overhang the glottis and occlude the respiratory passage. Tuberculous perichondritis and chondritis may result in fixation of the arytenoids, and thus prevent abduction of the vocal cords. The lumen of the glottis is thereby rendered very narrow, and distressing dyspnea results.

Lupus Stenosis of the Larynx.—This disease in the larynx is characterized by a cicatricial contraction and matting together of the parts. Lupus runs a much more chronic course than active tuberculosis of the larynx, hence the greater changes. Virchow says the arytenoids are occasionally surrounded by hard papillary growths in the active stage of lupus. The scar tissue in lupus is very unyielding and not readily absorbed, even under the pressure of laryngeal tubes.

Leprous Stenosis.—The stenosis rarely occurs until the patient is in the last stages of the disease. In this stage it often becomes so pronounced as to call for tracheotomy to relieve the distressing dyspnea.

Ventricular Eversion and Stenosis.—The eversion of the sacculus laryngis is scarcely possible as a primary condition. (See Prolapse of the Ventricle of Morgagni.) Anatomically it appears to be too firmly adherent to the adjacent tissues to permit of its prolapse. There may be a disease of the underlying perichondrium of the laryngeal cartilages predisposing to the eversion and the consequent stenosis. Tumors and glandular enlargement may also push the sacculus toward the median line and cause stenosis.

Traumatic Stenosis.—Stenosis of the larynx may be due to the inhalation of hot vapors or to the ingestion of corrosive fluids, as carbolic acid.

Treatment.—The treatment of laryngeal stenosis is both medical and surgical. The following table gives a suggestive line of treatment in the various conditions causing stenosis:

Medical Treatment.—(*a*) In syphilitic edema and infiltration without cicatricial contraction the iodides are indicated. Saline laxatives may be given with good results.

(*b*) Acute edema supervening upon a preëxisting fibrous stenosis should be treated by the local application of adrenalin and by free saline catharsis.

(*c*) The edema of tuberculous laryngitis may be relieved by tonic remedies and the cautious administration of mild cathartics.

Surgical Treatment.—(*a*) Webs of syphilitic origin should be broken down by systemic dilatation by means of Schroetter's laryngeal tubes (Fig. 287). The larynx should be cocainized, the index finger of the left hand introduced through the narrowed chink of the glottis. The web will thus be put upon the stretch, or torn. A larger tube should be introduced after leaving the first one in place a few minutes. This process should be continued three times a week until the stenosis is

completely overcome. Even then the tubes should be introduced at intervals of a few weeks to prevent the reformation of the webs.

(*b*) Cicatricial contraction due to syphilis should be overcome in the same manner as described in the preceding paragraph, though the dilatations will have to be used more persistently.

(*c*) Hyperplastic or papillary growths of syphilitic origin do not always yield to the iodides, and should, therefore, by either direct or indirect method, be removed with laryngeal forceps under general or cocaine anesthesia. Occasionally the papillary growths become wedged in the chink of the glottis and cause sudden and alarming dyspnea, and necessitate an emergency tracheotomy. (See Tracheotomy.)

(*d*) Tuberculous chondritis and abscess of the larynx, when causing stenosis, should be relieved by the removal of the diseased and dislocated cartilage with a laryngeal curette or biting forceps.

Tuberculous ankylosis of the arytenoid cartilages, attended by fixation of the cords in adduction with severe dyspnea, calls for tracheotomy for the immediate relief of the symptoms, or laryngofissure may be necessary at a later time to overcome the ankylosis, or to remove the arytenoid cartilages. The abduction of the cords during respiration is thus made possible and the distressing dyspnea relieved.

Fig. 287

Schroetter's laryngeal dilator.

(*e*) The cicatricial stenosis of lupus should be treated by dilatation with Schroetter's tubes, as described in a preceding paragraph, excepting that it may require greater persistence.

(*f*) Leprous stenosis should be relieved by tracheotomy if the gravity of the suffocative fits warrants it.

(*g*) Ventricular eversion with stenosis, while secondary to some diseased process of the underlying perichondrium, should be overcome by removing the prolapsed sacculus membrane with a snare under cocaine anesthesia. Failing in this, tracheotomy may be performed, and the everted mass removed subsequently by laryngofissure. (See Laryngofissure.)

Subglottic Stenosis.—Sajous pointed out that the subglottic space has not received the attention which its importance as an inherent portion of the larynx warrants. He urges systemic examination of this space in all laryngeal cases. The forms of stenosis peculiar to the lower subglottic region present features of unusual danger and symptoms likely to be ascribed to syphilitic disease. Inasmuch as the iodide of potassium greatly increases the danger in subglottic stenosis, it should not be administered in a case presenting dyspnea as a symptom, unless the

non-existence of this condition is determined by infralaryngoscopical examination, or the causative disease is clearly recognized as being independent of the respiratory tract. He advised that preliminary tracheotomy be performed when the iodide of potassium is to be administered during the existence of advanced subglottic stenosis.

Massei states that the subglottic space is the most frequent seat of syphilis, tuberculosis, tumors, rhinoscleroma, and foreign bodies. Slight syphilitic stenosis is frequently curable without local treatment by the administration of sublimate injections with or without the iodides. In simple inflammatory and neoplastic stenosis, intubation offers the best results. He agrees with Sajous that too great dependence is placed in general antisyphilitic treatment in severe stenosis, and that such a course may be fatal.

CHAPTER XXVII.

NEUROSES OF THE LARYNX.

NEUROSES OF MOTION.

THE classification of J. Solis-Cohen is as follows:

Neuroses of the Motor Nerves of the Larynx.—The motor neuroses are divided into two groups:

1. Spasms of the larynx, or hyperkinesis, *i. e.*, excessive motion.
2. Paralysis of the larynx, or akinesis, *i. e.*, absence of motion.

Spasms of the Larynx.—Spasms of the larynx may be due to irritation of the central brain cells in which all the intrinsic muscles are thrown into violent action, or to irregular nervous impulses sent out from the motor centres of the brain, causing incoördination of the laryngeal muscles.

Paralysis of the intrinsic laryngeal muscles may be limited to one muscle or to a group of muscles, or it may affect all of them.

The spasms may be either tonic or clonic.

Tonic spasms are (*a*) of central origin; (*b*) from irritation of the trunk of the recurrent laryngeal; and (*c*) from reflex irritation.

(*a*) **Tonic Spasms of Central Origin.**—In tabes dorsalis spasm of the adductors of the larynx occurs. The clinical picture shows sudden dyspnea with loud inspirations, the cords remaining in adduction for a variable time. It also occurs in tetanus and hydrophobia.

(*b*) **Tonic Spasm from Irritation to the Trunk of the Recurrent Laryngeal Nerve.**—When the injury is transient and slight, the laryngeal spasm is a forerunner of paralysis. Aneurysm of the arch of the aorta, cancer of the esophagus, pleuritic adhesion of the apex of the right lung, and tumors of the mediastinal glands may cause the irritation. A slight lesion may also occur in tabes.

(*c*) **Tonic Spasms from Reflex Irritation.**—These may occur from irritation of the larynx, the fauces, and the neighboring parts. In highly sensitive children irritation in a remote part of the body may cause adduction spasms. The latter condition has been described as laryngospasm infantum, and is usually due to intestinal irritation, tapeworm, a tight prepuce, or constipation.

Clonic spasms of the laryngeal muscles are always of central origin, and they consist of rhythmical inward movements of the cords. The condition may last but a few moments, or it may persist for many months. The pillars of the fauces are also often affected in a like manner.

Both tonic and clonic spasms may be present in the same case,

especially in the depressors of the epiglottis. The diseases most often causing clonic spasm of the larynx are syphilis, meningitis, and intracranial tumors.

Clinically, spasm of the larynx may be classified as follows (after Coakley):

(*a*) Spasm of the adductor muscles (laryngismus stridulus).
(*b*) Spasm of the tensor muscles.
(*c*) Spasmodic laryngeal cough or laryngeal chorea.

(*a*) **Laryngismus Stridulus (Adductor Spasm).**—*Synonyms.*—Spasm of the larynx; laryngeal spasm; spasm of the abductors of the vocal cords; spasm of the glottis; spasmus glottidis; false croup; child-crowing; thymic asthma; asthma rachiticum; Miller's asthma.

Laryngismus stridulus is a spasmodic act of the intrinsic muscles of the larynx accompanied by stridor. It is a neurosis, and is not necessarily associated with laryngeal disease. It is not a disease, but a symptom. While it is not a disease, it is a symptom causing great alarm. It is often associated with laryngeal or tracheal diseases, though it may be a reflex phenomenon from irritation in either contiguous or remote organs. It is sometimes a symptom of acute laryngitis, pseudomembranous croup, and diphtheritic croup, especially in children. It may also occur in non-inflammatory diseases of the larynx. It is common in children, but rather rare in adults. It is sometimes associated with intestinal disorders, as indigestion, worms, and constipation. Uterine disorders and sexual excesses have been known to produce it. Disorders of the contiguous organs, as the lingual tonsils, the teeth (dentition), elongated uvula, and inflamed tonsils, sometimes excite the spasm. The irritation of the fauces with a brush, or a foreign body in the pharynx sometimes causes the symptom to appear. Cases have been reported in which the pressure from an enlarged thymus gland caused laryngismus stridulus. Cerebral irritation, caries of the vertebræ, and rickets are known causes. Laryngismus stridulus appears in the laryngeal crises of tabes.

Treatment.—The treatment consists in relieving the source of the irritation rather than in applications to the larynx. For the immediate relief from the suffocative spasm the application of cold water to the chest or hot water to the nape of the neck should be made. If suffocation seems imminent and the lower jaw is relaxed, seize the tongue between the thumb and the forefinger and exert traction about every three seconds, to excite the respiratory centre through the reflex action of the phrenic nerve. If the jaw is set, the same result can be accomplished by exerting pressure with the fingers under the angles of the jaw. Should these measures fail, resort to intubation or tracheotomy.

(*b*) **Spasm of the Tensor Muscles of the Vocal Cords; Aphonia Spastica; Phonatory Spasms.**—Spasm of the tensor muscles is essentially a neurosis from overuse of the voice. The muscles are fatigued and fail to respond to the nervous stimulus sent out from the motor centres of the brain; they are tired and irritated by a local accumulation of the toxins from faulty metabolism. Writer's and telegrapher's cramp are similar affections.

Symptoms.—Spasm of the tensor muscles is characterized by sudden onset at any moment during speech. It may come on at the beginning or in the midst of a sentence. I have seen cases in which the speech was suddenly almost or entirely lost for some minutes, after which it would quickly clear up and remain so for an indefinite period. The patient complains of a rough, harsh feeling in the larynx, accompanied by the spontaneous flow of a few tears and slight congestion of the conjunctivæ. A drink of water hastens the cessation of the spasms. The cords are tense and approximated in the median line.

Treatment.—The cases seen by the author have been mild, and occurred only at long intervals. They required no special treatment other than a few minutes' rest of the voice and a drink of cold water.

In severe and oft-recurring spastic aphonia prolonged rest of the voice is necessary. Such cases are usually overtaxed, or are affected by a slight general debility, and they should, in addition to prolonged rest away from the persons with whom they are daily associated, be given tonic or specific remedies to correct the debility or the specific diseases with which each is affected. To this end iron, strychnine, arsenic, cathartics, iodide of potash, eggs, milk, etc., should be given.

(*c*) **Spasmodic Laryngeal Cough or Laryngeal Chorea.**—This condition is quite similar to chorea in other parts of the body, though it is not usually associated with it. There are, however, synchronous contractions of other respiratory muscles which furnish the blast of air back of the cough. The choreic cough occurs at frequent intervals, and is a dry, noisy, respiratory explosion resembling the yelp or bark of a dog. It occurs most often in females at about the age of puberty, or at the age of greatest instability of the nervous system. They rarely occur during sleep. Between the intervals the voice is clear. The vocal cords appear normal and are closely approximated during the attacks.

Treatment.—The cough is due to an hysterical temperament or to an imbalance of the nervous system at or about the age of puberty, and little can be done to improve it. A sea voyage or an outdoor life will add tone to the system, and thus tend to check the recurrence of the attacks. Tonics and sedatives may also be administered. The child should be taken from school and sent to the country, or in some way kept outdoors. Fresh air and sunshine will do more for these cases than any other mode of treatment.

NEURALGIA OF THE LARYNX.

True neuralgia is rare, and is characterized by pain without a visible cause. Similar pain may be caused by malaria, gout, rheumatism, pressure from some tumor or swelling, epipharyngitis, and angina of the pharynx. It is obvious, therefore, that the foregoing diseases should be excluded before making a diagnosis of neuralgia.

Treatment.—The treatment of a true neuralgia is successfully accomplished with phenacetin, gr. v to x, every three hours, also with cannabis

indica, aconite, and morphine, pushed to their physiological effects. While cocaine sprayed into the throat affords immediate relief, it is not to be recommended, as these patients easily acquire the cocaine habit. Menthol affords relief. Cold or hot applications to the neck also prove grateful to these patients.

If the pain is due to gout, rheumatism, malaria, or pressure of a tumor or a gland, treatment appropriate to these conditions should be instituted.

MOGIPHONIA.

Mogiphonia is characterized by a difficulty in maintaining the tension of the vocal cords while singing, or during forced accentuated speaking. In ordinary conversation no difficulty is experienced.

Treatment.—The treatment is rest. Overtaxation being the cause, other forms of treatment are scarcely indicated, unless the condition has recurred often and at frequent intervals. When this is the case, tonics, massage, cathartics, and eliminative treatment should also be used.

NERVOUS COUGH.

This is a spasmodic, croupy, or even musical laryngeal cough, for which no physical cause can usually be assigned. It is peculiar to neurotic individuals who present other stigmata of a neurosis. It is a "daytime" cough, entirely subsiding during sleep, to return the following morning, often with increased severity. It often occurs in the hysterical. It may be a reflex disturbance from a hypersensitive area in the nose, the epipharynx, or the chest, hence a careful examination of these parts should be made. The sensitive areas in the nose and the epipharynx may be located by gentle probe pressure without the use of cocaine. In the nose Jacobson's tubercle near the anterior end of the middle turbinated body may be the seat of the sensitive area. When this is touched with the probe it will give rise to the peculiar nervous cough, provided, of course, that it is the source of the reflex. Impacted cerumen in the external auditory meatus may cause it. The reflex may also have its origin in the gastro-intestinal tract.

Treatment.—As most cases are due to a true neurosis rather than to some physical lesion, the treatment must be of a tonic and sedative character. Sprays of iced lime-water, or menthol in combination with camphor, gr. ij to an ounce of liquid petrolatum, etc., may be used to relieve the laryngeal irritations. Antispasmodics and sedatives, as aconite, cannabis indica, and the bromides may be given internally to allay the spasms and the local irritation.

LARYNGEAL APOPLEXY.

Synonyms.—Laryngeal vertigo; laryngeal syncope; bronchial syncope; complete glottic spasm in the adult.

Laryngeal apoplexy is characterized by a transient irritation and burning sensation in the lower part of the throat, followed by a fit of coughing, dimness of vision, dizziness, and unconsciousness, the patient falling to the floor. The face may be congested or pale.

The disease is a neurosis affecting the coördination of the respiratory centres and the nerves of the larynx. It is rare. The attacks may last but a few seconds, when the spasms cease and the mind becomes clear again. They may recur at intervals of a few weeks.

Etiology.—The disease is chiefly found among the well-to-do and those leading sedentary lives, though one case is reported as occurring in a sailor (Whalan). Getchell reported 77 cases ranging in age from seventeen to seventy-seven years. All but four were males. Rheumatism and gout are occasionally associated with it. Neurasthenia is a pretty constant factor. Local inflammatory disease of the bronchi, the pharynx, and the larynx is commonly present, and may be an important causative agent. Lennox Browne reported 3 cases in which there was varix at the base of the tongue.

Among the exciting causes may be named worry from strenuous business or social conditions, and either physical or mental overwork. A pinch of snuff or other irritating substance inhaled into the larynx and the bronchi may bring on an attack.

Symptoms.—The face is usually flushed, though it may be pale. A deep breath is taken, followed by laryngeal spasm. There may be epileptiform convulsions, and the sequence ends in a few moments by a return to consciousness. After the attack all signs of the disease disappear. The disease is clinically like apoplexy with a laryngeal aura and laryngeal spasm, the latter being continued long enough to produce unconsciousness. Such spasms are liable to occur in neurasthenia and in tabes. Other signs of neurasthenia, epilepsy, and tabes should be sought for before pronouncing the case one of laryngeal apoplexy.

Treatment.—The treatment should be addressed to the correction of alimentary and hepatic disorders, and to the regulation of the excretory organs of the body. Tonics and antispasmodics may be given to tone and tranquillize the nervous system. Local lesions, if present, should receive appropriate treatment. For instance, bronchitis is the most common concomitant disease, and possibly has something to do with its causation. It should therefore be treated by the administration of 4 grains of iodide of potassium in a glass of water after each meal for several weeks or months. By relieving the associated diseases of the upper respiratory tract the laryngeal spasms and the syncope are sometimes entirely relieved.

PARALYSES OF THE INTRINSIC MUSCLES OF THE LARYNX.

It is difficult to make a classification of the paralyses of the laryngeal muscles in such a way as to have it coincide with clinical observation.

The intrinsic muscles are supplied by branches of the right and the left pneumogastric or vagus nerves. It will be remembered that these nerves have their origin near the median furrow beneath the floor of the fourth ventricle. Two motor branches, the superior laryngeal and the recurrent or inferior laryngeal, are given off from each vagus to the larynx. The superior laryngeal also supplies sensation to the whole laryngeal mucous membrane.

Fig. 288

Schema of the nerve supply of the intrinsic muscles of the larynx. *P*, the pneumogastric nerve; *R*, recurrent laryngeal nerve; *S.L.*, superior laryngeal nerve; *A.C.*, arytenoid cartilages; *T*, thyroid cartilage; *C*, cricoid cartilage; *A*, interarytenoideus muscle; *C.A.P.*, crico-arytenoideus posticus muscle; *C.A.L.*, crico-arytenoideus lateralis muscle; *T.A.I.*, cricothyroidei interni muscles.

By reference to Fig. 288 it will be seen that the superior laryngeal supplies only one pair of the intrinsic muscles of the larynx, the cricothyroidei. These muscles are tensors of the vocal cords, hence the wavy outline of the cords (Fig. 289) in superior laryngeal paralysis.

The recurrent or inferior laryngeal nerves supply all the other intrinsic muscles of the larynx, namely, the arytenoideus, the crico-arytenoidei postici, the crico-arytenoidei laterales, and the internal tensors of the vocal cords.

If the lesion involves all the fibers of the left recurrent laryngeal nerve,

there is total paralysis of all the muscles of the left side of the larynx except the cricothyroideus (external tensor). The same is true of the right side (Fig. 289). If the lesion involves only a small branch of the left recurrent, one muscle alone may be involved, say the crico-arytenoideus posticus. This muscle is an adductor, hence there would be incomplete closure of the anterior two-thirds of the vocal cord on the left side, while the opposite cord would slightly encroach beyond the median line. The adduction of the posterior third is controlled by the arytenoideus, hence, this muscle being unaffected, closure in that region is complete. Single muscles are rarely affected except in diphtheria and other local inflammations of the larynx, and in hysteria. It is always a question when a single muscle is affected, excepting one of the cricothyroidei, as to whether the lesion is in a nerve twig or in the muscle itself. Inflammatory infiltration may inhibit the nerve twig supplying a certain muscle, or the infiltration may cause a mechanical barrier to the proper motion of the muscle. Hysterical paralysis is, of course, not a true paralysis.

FIG. 289

Paralysis of the cricothyroidei. The only muscles of the larynx supplied by the superior laryngeal. All the other intrinsic muscles of the larynx are supplied by the recurrent laryngeal nerves.

Paralysis of involuntary muscles usually has its origin in a lesion of the medulla oblongata or the spinal cord. Lesions of the cerebral cortex, on the other hand, cause central paralysis of voluntary motion. In making a diagnosis in this class of cases, aphasia must be distinctly separated from aphonia; the same is true in considering the etiology. Kraus, in 1884, demonstrated that stimulation of the gyrus prefrontalis in the lower animals produced a contraction, or muscular movements, of the larynx, the pharynx, and the palate. Semon and Horsley fully substantiated the findings of Kraus by a long series of experiments on the lower animals.

Irritation of one of the external borders of the restiform bodies produces unilateral adduction of the vocal cords. Bulbar lesions usually produce unilateral paralysis, but many cases of unilateral paralysis are also caused by lesions in the medulla.

Laryngeal paralyses are seldom brought about by tumors of the medulla or the pons. Gottstein thoroughly reviewed this aspect of the question, and refers to several cases of glioma and one of aneurysm of the basilar artery. A bulbar lesion causing laryngeal paralysis usually involves the dorsal motor nucleus of the penumogastric, which lies near the median furrow, and is beneath the floor of the fourth ventricle.[1] In

[1] Edinger, Anatomy of Central Nervous System of Man, English translation from fifth German edition, p. 375, says:

"We have learned, then, two nuclei for the vagus, *a ventral one*, which from its position (in the prolongation of the ventral horn) and from the appearance of its cells (multipolar with axis cylinders passing directly into the nerve) *is motor;* and *a dorsal one*, which, lying in the prolongation of the gray matter of the base of the posterior horn, is also by its structure characterized as *sensory*."

laryngeal paralysis the abductors are usually the first, perhaps the only, muscles affected as a result of a central or a peripheral lesion, while in hysterical aphonia the adductors are affected.

Tumors, traumatisms, and other lesions at the base of the skull give rise to laryngeal paralysis by implicating the trunks of the pneumogastrics. It is often difficult to differentiate these conditions from bulbar lesions, as they frequently involve the facial, the glossopharyngeal, the acusticus, the spinal accessory, also other branches of the pneumogastrics beside the laryngeals, depending upon the extent of the lesion. The portion of the pneumogastric which lies in the neck (usually the trunk and the recurrent laryngeal after it winds around the large vessels in the thorax, travelling back along the esophagus to the larynx) is very often the seat of the lesion causing the laryngeal paralysis. Among the lesions in this locality causing paralysis of the nerves just mentioned are enlarged glands, traumatisms due to wounds in operating, goitres, aneurysms, mediastinal tumors, tumors of the esophagus and the pharynx, pleurisy, scoliosis of the cervical vertebræ, tuberculosis of the apices of the lungs, and even pericarditis.

Laryngeal paralysis may be the very first, and for a long time the only significant indication of an aneurysm of the arch of the aorta. Often no palpable reason for the paralysis can be ascertained, and then recourse must be had to a tentative diagnosis of a simple neuritis. The rare cases of paralysis of individual muscles must be ascribed to lesions of their respective nerve twigs, or to an involvement of the muscular structure itself. Paralysis of the abductors is now and then due to traumatism by the passage of a bolus of food through the lower pharynx into the esophagus, or even to exposure to cold drinks, as the location of the muscles is very superficial. In paralysis of the pneumogastric due to a bulbar lesion the involvement of other nerves readily establishes the diagnosis. However, an injury to the base of the skull may simulate a bulbar lesion by implicating several nerve trunks in addition to the pneumogastric. Jackson, Proust, Senator, and Eisenlohr have reported cases of bilateral paralysis as being due to bulbar lesions, though they are comparatively rare. There is no authenticated case of paralysis of the adductors alone from an essential lesion. Occasionally a bulbar lesion produces bilateral paralysis, in which instance the abductors alone are usually involved; more often the paralysis is unilateral, though not so often as when due to other lesions.

PARALYSIS FROM DISEASE OR INJURY OF THE SUPERIOR LARYNGEAL NERVE; PARALYSIS OF THE EXTERNAL TENSORS OF THE VOCAL CORDS.

So far the only lesions which have been noted as causing paralysis of the cricothyroid muscles are diphtheria, enlarged glands, and inflammation of the areolar tissue beneath the angle of the jaw. Typhoid fever may cause it. Paralysis of these muscles is extremely rare.

Symptoms.—Anesthesia of the larynx, the phenomenon which was described under neuroses of the larynx, is a prominent and significant symptom. The anesthesia is explained by the fact that it is the superior laryngeal nerve, a branch of the pneumogastric, which is affected. This branch supplies the cricothyroid muscles with motor stimulus, and the whole of the mucosa with sensation. Whenever, therefore, there is anesthesia of the whole mucosa of the larynx, the lesion involves the superior laryngeal nerve fibers, either after they leave the pneumogastric or higher up in the pneumogastric itself. A low-pitched voice and inability to sing high tones is characteristic of this affection. When the thyro-epiglottic and the aryteno-epiglottic muscles are paralyzed the epiglottis stands upright, hence the larynx cannot be closed. Because of this and the attending anesthesia, food often finds its way into the larynx and upper respiratory tract. No warning is given the patient until the food reaches an area below the vocal cords. Hence, pneumonia is frequently a serious sequence. Complete bilateral paralysis of the cricothyroid muscles is manifested by the peculiar wavy outlines of the vocal cords (Fig. 289). According to E. MacKenzie, when this paralysis is unilateral the laryngoscope shows one vocal cord on a higher plane than the other.

Diagnosis.—The peculiar wavy outline of the vocal cords and the local anesthesia clear up the diagnosis as to the hoarseness and aphonia, and distinguish it as a true motor paralysis rather than a neurosis or an inflammatory disease.

Prognosis.—It is very bad if there is a complete bilateral paralysis, but not so very grave when only one cord is implicated. The patient may succumb to inanition or pneumonia. Lobar pneumonia is the usual type, and cases have been recorded where death from this disease could only be ascribed to the passage of food or other foreign substance into the trachea because of the anesthesia. The prognosis is very bad if the recurrent laryngeal nerve is involved at the same time.

Treatment.—Nourishment by the esophageal tube, galvanism, strychnine, and general tonics are indicated.

PARALYSES OF THE RECURRENT OR INFERIOR LARYNGEAL BRANCH OF THE PNEUMOGASTRIC NERVE.

All the intrinsic muscles of the larynx except the cricothyroidei are supplied with motor stimulus by the recurrent laryngeal nerves. The crico-arytenoidei postici are abductors of the vocal cords and therefore muscles of respiration, in a sense, also, of phonation, as their action is necessary to maintain the required equilibrium of the other muscles in this act and in modulating the voice.

The recurrent laryngeal supplies motor stimulus to the following muscles:

Recurrent laryngeal (inferior laryngeal)	Crico-arytenoidei laterales (abductor). Arytenoideus (adductor). Crico-arytenoidei postici (adductor). Thyro-arytenoidei (internal tensor).

The superior laryngeal nerve supplies the cricothyroidei (external tensors).

It is clear, from the above analysis, that the recurrent laryngeal nerve is the chief motor supply to the larynx, and that it presides over both adduction and abduction of the vocal cords. It is obvious, therefore, that when all the fibers of the main trunks of the recurrents are affected there is total paralysis of both the adductor and the abductor muscles of the larynx. The only intrinsic muscles of the larynx not affected are the external tensors, the cricothyroidei, which are supplied by the superior laryngeal nerves. These play so small a part in the general movements of the cords that their action under these circumstances is practically nil. The cords, therefore, assume the so-called cadaveric position (Fig. 290). In studying the various paralyses of the recurrent laryngeals I shall first speak of total paralysis, and follow with the partial paralyses. I mean by the term partial paralysis, the paralysis of certain groups of muscles rather than an incomplete paralysis of part or all of the muscles of the larynx.

Fig. 290

Larynx in quiet breathing and the cadaveric position.

COMPLETE PARALYSIS OF BOTH RECURRENT LARYNGEAL NERVES.

Etiology.—By reference to Fig. 291 the course and distribution of the right and the left recurrent laryngeal branches from the pneumogastrics is illustrated in diagrammatic form. The left recurrent is given off at the level of the transverse portion of the arch of the aorta, and passes under it, thence upward in the groove between the trachea and the esophagus to the muscles of the larynx. As it reaches the larynx it breaks into several twigs, thus supplying motor stimulus to all the intrinsic muscles of the left half of the larynx except the cricothyroid, which is supplied by the superior laryngeal. The left recurrent nerve is the most often affected, on account of its relationship to the arch of the aorta and the left subclavian artery. Aneurysm of the transverse portion of the arch of the aorta causes compression and neuritis of the left recurrent laryngeal, and thus inhibits the motor impulses from reaching the left half of the larynx. Unilateral paralysis results. Occasionally the aneurysm is so large as to encroach upon the structures on the right side of the chest, and thus may cause compression and neuritis of the right recurrent, in which event the paralysis would be bilateral.

While the right recurrent laryngeal is not so often involved, it is,

nevertheless, so situated with reference to the subclavian artery and the apex of the right lung as to be somewhat frequently the source of laryngeal paralysis. The right recurrent nerve is given off on the level with the subclavian artery, and curves around the latter as it starts upward to the larynx. Aneurysm of the subclavian may therefore compress it and cause neuritis and consequent laryngeal paralysis of the intrinsic muscles of the right half of the larynx. The right recurrent nerve is in close proximity to the apex of the right lung, and may become involved in pleuritic exudates and adhesions in this region, and thus cause paralysis of the right half of the larynx.

Fig. 291

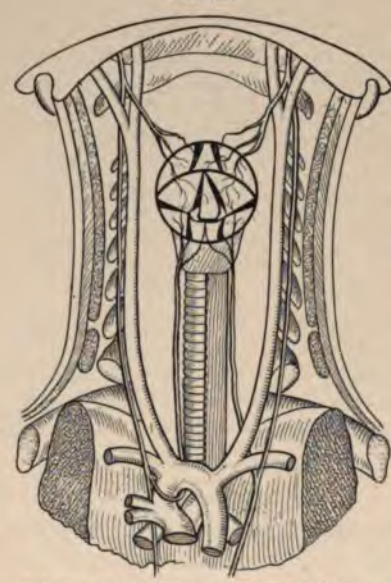

Schema showing the relations of the pneumogastric nerve to the trachea, esophagus, vessels of the thorax. Also the recurrent laryngeal and superior laryngeal branches and their distribution to the intrinsic muscles of the larynx. (See Fig. 288.)

The mediastinum is frequently the seat of malignant or other growths which press upon one or both of the recurrent nerves. Enlarged glands of the neck, malignant tumors of the esophagus, and other growths in the neck may cause pressure and degeneration of one or both pneumogastric nerves, and produce unilateral or bilateral paralysis of the larynx. Scoliosis, goitre, and pericarditis may also injure the recurrent nerves. Gummata are frequently the source of the nerve lesion.

The central lesions causing laryngeal paralysis are in the medulla oblongata or the spinal cord. The exact location of the pneumogastric nuclei seems to be, according to Kraus, Semon, and Horsley, in the gyrus prefrontalis. Tumors of the medulla and the pons rarely cause laryngeal paralysis. Aneurysm of the basilar artery is a known cause. Bulbar lesions causing laryngeal paralysis usually involve the dorsal motor nucleus of the pneumogastric which lies near the median furrow beneath the floor of the fourth ventricle.

Tumors, traumatisms, and other lesions at the base of the skull give rise to laryngeal paralysis by implicating the trunks of the pneumogastric nerves. It is often difficult to differentiate these from bulbar paralysis, as these conditions often involve the facial, the glossopharyngeal, the acusticus, the spinal accessory, or other branches of the pneumogastric nerve.

The nerves and their filaments may be completely atrophied. The remains of the neurilemma have been found, but fatty degeneration is the most frequent degenerative change.

Symptoms.—The symptoms, whether due to lesion of the pneumogastric trunk or to the recurrent laryngeal, are very much alike. The voice is usually weak and husky. The sensibility of the mucous membrane is usually unimpaired, unless the lesion of the pneumogastric trunk is above the point where the superior laryngeal is given off. If both pneumogastric trunks or both recurrent nerves are injured, the voice is aphonic, as the cords stand in the cadaveric position. If the recurrent on one side only is affected, the vocal cord on that side rests in the cadaveric position, while the opposite cord has its normal movements. Indeed, it encroaches beyond the median line upon attempted phonation, while during deep inspiration it is widely separated from the opposite cord. In one-sided paralysis the position of the arytenoid cartilages is characteristic; the arytenoid cartilage on the unaffected side overlaps the opposite arytenoid, and is either anterior or posterior to it. Cough is usually absent, and when present is due to an irritation of the trachea by pressure of a tumor in the neck or upper mediastinum. The cough is like that in aneurysm of the arch of the aorta. I have seen a few cases of aneurysmal cough, and they were dry and slightly harsh or brassy. One case in particular was free from cough except in public gatherings or other places likely to excite the heart's action. Coughing and expectoration are performed with great difficulty in bilateral paralysis.

Dyspnea is absent in unilateral paralysis, but may be present in bilateral paralysis in spite of the fact that the cords are separated in the "cadaveric" position. In the "cadaveric" position the cords stand midway between adduction and complete abduction. They are not as widely separated as is usual in inspiration, hence the dyspnea.

In some cases the paralysis is partial, and the symptoms are, therefore, correspondingly modified. I have elsewhere called attention to the fact that the abductor twigs are more frequently implicated by pressure than the twigs supplying the adductors.

Diagnosis.—Bilateral abductor paralysis during quiet respiration bears a slight resemblance to complete paralysis. The act of phonation, however, is attended by the adduction or approximation of the cords, which readily distinguishes it from the passivity of the cadaveric position.

Prognosis.—In view of the serious nature of the causes back of complete paralysis of one or both recurrent laryngeal nerves, the prognosis is grave. In case it is due to syphilitic gummata or to the pressure of enlarged glands, the prognosis under appropriate treatment is good. If due to the toxemia of diphtheria or to an acute inflammation, complete recovery may occur in a few weeks.

Treatment.—The treatment depends upon the cause of the paralysis and the duration of the symptoms. If enlargement of the thyroid gland is the cause, the administration of thyroid extract may diminish the size of the tumor and thus relieve the pressure upon the nerve. An operable tumor causing pressure upon the trunk of the pneumogastric or the recurrent laryngeal nerve should be removed to relieve the pressure. If the nerve has undergone degenerative changes, the improvement may be slight or absent; if, however, the nerve is still healthy, the paralysis

may disappear after the operation. In aneurysm of the arch of the aorta or of the right subclavian, dependence should be placed in the use of iodonucleoid in from 5 to 15 grain doses three times a day. Syphilitic gummata may be treated with mercurial inunctions and the internal administration of iodonucleoid in doses ranging from 10 to 25 grains three times a day; or the iodide of potash 10 to 60 grains three times a day. The iodonucleoid is as reliable a drug as the iodide of potash, and has the advantage of being tolerated by the most sensitive stomach. It is free from potash, having a nucleoid base. It is absorbed more readily by the blood and rapidly saturates the system with iodine, which is the active agent in both the iodide of potash and the iodonucleoid.

Galvanism and faradism combined with external massage over the laryngeal region may be practised to increase the circulation and nutrition of the atrophied muscles. Strychnine is also a valuable remedy, as it increases the nerve energy and tones the muscles.

If the paralysis is due to diphtheria or one of the exanthemata, constitutional remedies, as strychnine, iron, and the bitter tonics, should be given to build up the waning and depleted cell energy. Eliminative remedies, to stimulate the excretory powers of the intestines, the kidneys, the liver, and the skin, should be given to clear the toxins from the blood and the lymph.

Tracheotomy may become necessary in a case of severe dyspnea.

UNILATERAL PARALYSIS OF THE RECURRENT LARYNGEAL NERVE.

Etiology.—Unilateral paralysis of one-half of the intrinsic muscles of the larynx is quite common, as each nerve traverses a long and uninterrupted course before it gives off the terminal twigs to the muscles of the larynx. The left recurrent is given off from the pneumogastric on a level with the transverse portion of the arch of the aorta around which it curves (Fig. 291) and passes upward in the groove between the trachea and the esophagus to the larynx. Aneurysm of the transverse portion of the arch of the aorta compresses it and causes degenerative changes and consequent laryngeal paralysis. Tumors of the mediastinum and of the neck or enlarged glands of the neck may compress and injure it. The right recurrent nerve is given off from the right pneumogastric on a level with the right subclavian artery, around which it curves in close contact with the apex of the right lung. Aneurysm of the right subclavian causes compression and degeneration of the right recurrent laryngeal nerve, and paralysis results. Pleuritic inflammation and adhesions at the apex of the lung may involve the right recurrent and cause laryngeal paralysis upon that side. Malignancy of the esophagus or other growth, or inflammatory swelling, may involve either the right or the left recurrent laryngeal nerve and produce unilateral paralysis.

Symptoms.—The symptoms include hoarseness or even aphonia at the beginning of the paralysis. Later the unaffected cord compensates for the loss of motion on the affected side, and the aphonia or hoarseness

is improved. Dyspnea is absent. The laryngeal image shows the vocal cord on the affected side in the "cadaveric" position, *i. e.*, half-way between adduction and abduction, while the unaffected cord performs both adduction and abduction without restraint. The epiglottis may deviate from the median line.

Prognosis.—The prognosis depends upon the cause. If due to a transient inflammation or exudate, it is good under appropriate treatment. If due to syphilis, the prognosis is good if the case is properly treated. If due to some incurable disease, the prognosis is correspondingly grave. If dyspnea is present, the prognosis is more grave.

Treatment.—When practicable, treat the disease causing the paralysis as in postdiphtheritic or postexanthematic and syphilitic affections. If an incurable disease, as carcinoma or sarcoma of the mediastinum, the esophagus, or the larynx, is the cause of the paralysis, treat the distressing symptoms as they arise. If the thyroid gland is enlarged, give thyroid extract, or perform thyroidectomy if the extract fails.

LARYNGEAL PARALYSIS FROM LESIONS OF THE MEDULLA AND THE NUCLEI OF THE SPINAL ACCESSORY NERVE.

Laryngeal paralysis from disease or injury of the medulla oblongata and the nuclei of the accessory portion of the spinal accessory is characterized by paralysis of all the intrinsic muscles of the larynx on the side involved, or, if only a few filaments are involved there will be paralysis of only one or at most two muscles of the larynx. It is still further characterized by the paralysis of certain muscles, extrinsic to the larynx, which are supplied by nerves having their origin in the immediate vicinity of the motor nucleus of the pneumogastric. Thus there may be paralysis of the facial, the acusticus, or of the nerves leading to the extremities.

Pathology.—Laryngeal paralysis due to a central lesion is dependent upon the involvement of the spinal accessory roots, from which some of the fibers of the pneumogastric nerves arise in the floor of the fourth ventricle. There must be a lesion in the medullary or nerve roots supplying the larynx. Syphilis, locomotor ataxia, progressive bulbar paralysis, multiple sclerosis, and tumors of the neck and the brain comprise the chief morbid anatomy of central paralysis of the larynx.

Diagnosis.—The diagnosis depends on the symptom complex of all the nerves involved. There is usually an associated paralysis of the nerves supplying the tongue, the palate, and the facial muscles, or of the nerves of audition, or of the extremities. Other regions supplied by the accessory root may be paralyzed. All the intrinsic muscles of the larynx may be paralyzed, or only a part of them, depending on whether all or only a few of the fibers from the motor pneumogastric nucleus are diseased.

Prognosis.—The prognosis is nearly always very grave, and even when the disease is due to syphilis it should be guarded, though under antisyphilitic treatment improvement may be expected.

Treatment.—The treatment should be varied to meet the symptomatic indications. If syphilis is present, the iodonucleoid or the iodide of potash should be given in large doses. If a malignant growth is at the

Fig. 292

Bilateral paralysis of the thyro-arytenoidei interni and of the arytenoideus.

bottom of the trouble, treat the unfavorable symptoms as they arise. If marked dyspnea is present from paralysis of the abductors on both sides, either intubation or tracheotomy should be performed.

BILATERAL ABDUCTOR PARALYSIS.

Etiology.—The causes of bilateral abductor paralysis of the vocal muscles are syphilis, mediastinal tumors, aneurysm, and enlarged mediastinal lymphatic glands. Neurasthenia is also a cause of the paralysis.

Symptoms.—The symptoms have been so admirably given by N. L. Wilson in an article read before the American Laryngological, Rhino-

Fig. 293

Position of the cords when emitting a high-pitched tone and in abductor paralysis.

logical, and Otological Society, in 1900, that I will quote him in this connection:

"The patient gave a remote history of syphilis, and was somewhat addicted to alcohol; has had a few attacks of dyspnea, especially at night, for the past eight months. Voice only slightly husky, inspiration a little

noisy, and expiration soundless. Occasionally had headaches. Ophthalmoscope showed nothing abnormal. Heart and lungs normal, urine acid and clear, specific gravity 1020. There was no albumin or sugar. The laryngoscopic examination showed the epiglottis to be normal, mucous membrane of the larynx normal, the vocal cords white, with a small slit between them during inspiration. The left vocal band was immovable in the median line; the right moved slightly." (Fig. 293.)

The patient was warned of the danger of sudden death from dyspnea, but refused to be tracheotomized. Three months later he died suddenly from dyspnea.

Fig. 294

Fig. 295

Fig. 296

Fig. 297

Fig. 298

Fig. 299

Fig. 294.—Unilateral paralysis of the thyro-arytenoidei interni and of the arytenoideus.
Fig. 295.—Paralysis of the thyro-arytenoidei interni.
Fig. 296.—Bilateral paralysis of the arytenoidei.
Fig. 297.—Unilateral paralysis of the right arytenoideus.
Fig. 298.—Paralysis of the adductor muscles of the larynx. It also shows the position of the cords in deep inspiration.
Fig. 299.—Paralysis of the adductors and arytenoideus.

Pathology.—When due to syphilis the disease may affect the abductor muscles, the peripheral nerve filaments of the recurrent nerves, the nerve trunk, or the medulla. When due to mediastinal tumors, aneurysm, or enlarged glands, the recurrent trunk is pressed upon, causing atrophy or other degenerative changes in the nerve fibers. When due to neurasthenia, the flow of the nervous impulses through the recurrent are inhibited.

Prognosis.—The paralyses due to neurasthenia generally recover, though death may occur. When due to other causes, more than half die. When operated upon, more than two-thirds recover. In the syphilitic cases the administration of the iodides and mercury sometimes effects a cure. When due to mediastinal tumors, aneurysm, and enlarged glands, it may be necessary to remove a portion of the vocal cords pending the consideration of the operation or other treatment of the mediastinal disease.

Treatment.—The faradic and galvanic currents have been used, and in but few cases with success. Antisyphilitic treatment has proved of value in a number of cases. Surgical treatment should be early recommended, as procrastination may lead to a fatal issue.

Surgical Treatment.—Three methods of procedure are available, namely, (*a*) tracheotomy, (*b*) intubation, and (*c*) laryngofissure and the removal of a part or all of the vocal bands.

Tracheotomy is usually preferable, as it affords the least inconvenience to the patient and is ordinarily easily performed. The cyanosis, congestion, and edema of the tissues which sometimes complicates the case (A. G. Root) may, however, render this procedure difficult to perform. (See Tracheotomy.)

Intubation may be performed for the temporary relief of the dyspnea. It is not suitable for permanent relief, as the tube may be coughed up, and its use is uncomfortable to the patient.

Laryngofissure and the removal of a portion or all of the vocal cords may be practised if the tracheotomy tube is objected to. After this operation the vocal functions are sometimes gradually resumed. (See Laryngofissure.)

CHAPTER XXVIII.

THE SINGING VOICE.

THE range of the average voice is from two to two and one-half octaves, although many singers embrace three to four octaves.

The singing voice begins from the third to the sixth year, and changes but little until puberty. At this time there is a decided change, especially in boys, in whom it becomes deeper or lower in pitch, assuming more the quality of an adult male. There is some change in girls' voices, although it is not so noticeable as in boys. The larynx becomes larger, the cartilages consolidated, and the cords longer and thicker.

The vocal organs should not have special stress put on them during this transition period, as coördination is distributed by the rapid changes in the shape, the size, and the position of the parts of the larynx.

Voice production is dependent upon three functions of the vocal apparatus. By "vocal apparatus," as used in this connection, is meant the larynx (primary source of tone), the chest (source of motive power), and the resonant chambers of the chest and the head.

Without the motive power of the outgoing current of air through the larynx there could be no vibration of the cords, and without the vibration of the vocal cords and the outgoing current of air through the upper respiratory tract there could be no vibration or secondary tones or harmonics to enrich the laryngeal or primary tone. In other words, a voice, to be pleasing or "sympathetic," must have all the qualities which can be imparted to it by a proper respiratory act, a normal placement of the larynx, and unimpeded vibration of the vocal cords; also the richness or quality imparted to it by the resonance chambers of the chest and the head.

Defects of the singing voice are, therefore, largely due to the following causes:

(*a*) Improper methods of breathing.

(*b*) Improper action of the extrinsic and the intrinsic muscles of the larynx.

(*c*) Local disease of the larynx.

(*d*) Faulty or imperfect use of the resonance chambers of the head and the chest.

The nose is one of the most important resonant chambers, hence diseases or abnormalities in this region are especially productive of harm to the singing voice. The epipharynx, the soft palate, the uvula, and the tongue are also largely concerned in voice production. Growths or diseased conditions of the epipharynx, the soft palate, and the tongue are therefore potent factors in defects of the singing voice. Enlarged

tonsils, especially if they are adherent to the pillars of the fauces, mar the purity of the tone and interfere with its placement. The same is true of postnasal adenoids. In both instances the mobility and the normal action of the uvula form a curtain or valve which regulates the volume and the direction of the vibrating air current from the larynx in its passage through the epipharynx and the nasal chambers. It is important that their action should be free and untrammelled. Postnasal adenoids push the soft palate forward and downward, while enlarged and adherent tonsils interfere with its free movement in an upward and backward direction toward the posterior wall of the pharynx. A voice thus modified loses its power to charm the ear. Not only is the quality or timbre impaired, but the range is also curtailed. I could cite instances in which the quality has been improved and the range increased one to three intervals by the removal of the tonsils. As adenoids are chiefly found in children, they do not so often affect the adult voice. On account of an associated postnasal catarrh with and subsequent to the atrophy of adenoids, the singing voice is often thereby indirectly affected. Postnasal catarrh involves the postsuperior surface of the soft palate and produces a laxity of the tissues composing it, including the palatine muscles. There is an increase in the fibrous tissue, together with an edema (slight), and boggy condition of the muscular fibers. The uvula is relaxed and often hangs down until it touches the base of the tongue or the posterior wall of the pharynx. This gives rise to a tickling sensation, and is often a source of annoyance to singers and speakers.

The presence of enlarged and diseased tonsils not only interferes with the muscular activity of the soft palate, but causes a chronic enlargement of the mucous membrane of the epipharynx and the oropharynx, thus augmenting the catarrhal condition already mentioned. A very common symptom of tonsillar disease is a sensation of a splinter of wood lodged in the throat. This is a symptom which, so far as I know, has not heretofore been attributed to this condition. I have often noted it, and regard it as significant of cryptic infection.

Defects of the singing voice due to nasal diseases are chiefly due to an interference with the production of the harmonics or overtones which give quality and character to the voice. The bones of the face are so constructed that there are numerous cavities communicating with the nasal chambers. The lightness of the bones makes them admirable sounding boards for the primary tones of the vocal cords. It becomes apparent at once that any condition of the nose which interferes with the proper entrance of the column of air into the nasal and the accessory cavities will prevent the voice taking on the rich coloring or tonal qualities which make it pleasing to the human ear.

Deflection of the septum, thickening of the nasal mucosa from chronic catarrhal inflammation, polypi, and other morbid processes interfere with the resonant chambers of the head. The mucosa of the nose is reflected through the normal openings into the accessory sinuses, and is here affected by catarrhal or other thickening simultaneously with the invasion of the nasal membrane. The openings into the sinuses are more

or less closed by the thickening, and the resonant quality of the cavities is thereby diminished. More often the middle turbinal or a high deviation of the septum blocks the nose and affects the resonance of the voice.

Jean de Reszke has well said that the more he studies the voice the more he is convinced it is a question of the nose. I have for many years been impressed that the chief charm in a public speaker's voice is its nasal quality. If this were lacking it failed to hold the attention of his auditors. I only speak of this to emphasize the fact that there is something very attractive to the average person in the resonance of nasal origin. There seems to be no other quality that can take its place. What is true in this regard of the speaking voice is doubly true of the singing voice.

The mouth influences the singing voice to a marked degree, not only in modifying the resonance, but more particularly, in enunciation and articulation. The placement of the tongue, its concave-convex shape, with the tip elevated against the roof of the mouth, etc., modify the musical quality of the voice. Hence, all abnormal conditions of the tongue which interfere with its movements affect the voice. If it is "tongue-tied," adherent to the anterior faucial pillars, or the geniohyoglossus muscle is too short, the musical value of the voice is impaired. Hypertrophy of the tongue is occasionally an impediment to the acquirement of vocal excellence.

The larynx being the primary source of tone, it is natural to presume that most defects of the singing voice are due to some lesion or faulty method of using it. This is probably true, although it should be remembered that many of the laryngeal inflammations are indirectly the result of nasal disease. Chronic laryngitis and, in many instances, acute laryngitis are secondary effects of chronic nasal obstruction and catarrhal sinuitis. Recurrent or persistent hoarseness should, therefore, lead to a thorough inspection of the nasal chambers for obstruction or sinus diseases. Hoarseness is not necessarily a sign of an antecedent nasal disease, as it is also a prominent symptom of laryngeal tuberculosis, cancer, etc.

Papillomata or other *laryngeal neoplasms* interfere with the motility and the adjustment of the vocal cords, and thus produce hoarseness, aphonia, or spasm of the muscles of the larynx. Morbid growths in this region should be removed with great care and with due regard to the functional integrity of the vocal apparatus. Awkward or aggressive surgery might forever banish the possibility of a musical career, or even a voice for ordinary social purposes.

Paresis of the Adductors from Aneurysm.—Gradual compression of either of the recurrent laryngeal nerves due to a developing aneurysm of the arch of the aorta may cause a partial paralysis one day, with characteristic choking spells, and on the following day all symptoms disappearing, only to recur again in a few days. Even though no other symptoms of aneurysm, such as dulness on percussion or bruit on auscultation, be present, the above symptom should be considered very suspicious.

Other tumors or conditions that cause gradual compression of the recurrent laryngeal nerves may show the same symptoms.

Methods of Breathing.—Defects of the Singing Voice Due to Improper Methods of Breathing.—To obtain the purest and richest singing voice the method of breathing should be carefully cultivated. The natural method of breathing is not suitable for the singing voice (H. Curtis). It is adapted to the ordinary function of oxygenating the blood, but is poorly suited for singing. For this purpose the respiratory acts should be done in such a way as to give the most perfect control over the expiratory current, and at the same time maintain the same quality or color of the voice during the varying stages of the act.

In order to obtain the most *perfect control* of the expiratory current of air for artistic purposes, the respiratory method should be such as will give the greatest chest capacity, as well as full control over the emission of the air for phonatory purposes.

The *quality or timbre* is best maintained throughout all the registers by such a method as will keep the upper portion of the thorax in a fixed position.

The *control of the expiratory current* for artistic purposes is a complex coördination of the muscles of the chest walls (scaleni and intercostals), the diaphragm, the abdominal walls, and the larynx. The singer should not, however, be made conscious of the part the larynx plays in this capacity, as this would lead to an undue tension of the laryngeal muscles. Nothing could be more damaging to the quality of the voice than this. In fact, the larynx has but an infinitesimal muscular function in voice production. The singer should be made to clearly understand that only when the laryngeal muscles are at "ease" can the voice charm the listener. The auditory nerve should only be conscious of quality, richness, sweetness, fulness, splendor, unlimited reserve, and all the emotions that make the inner self a free spirit, travelling through the world of ennobled thought and imagination. The most beautiful song, when coming from an overtense larynx, calls attention to the material, the singer, as opposed to the ethereal, the song, thus defeating the purposes of artistic singing.

I have thus digressed at this point in order to emphasize the importance, indeed the absolute necessity, of maintaining a proper poise of the laryngeal muscles during the artistic activity of the expiratory current of air with which the singing voice is produced.

The Inferior Costal Type.—The *chest cavity* is conical in shape, with the apex at the top. It may be increased in all its diameters during the inspiratory act by the action of the scaleni, the intercostals, and the diaphragmatic muscles. All these muscles should, therefore, be used to fill the lungs to their greatest capacity. The inferior intercostals and the diaphragm are especially important in this connection, hence it is usually spoken of as the inferior costal type. The upward and outward movement is chiefly confined to the ribs and the sternum below the sixth rib. The downward movement of the diaphragm pushes the abdominal viscera with it, and thus tends to increase the abdominal

convexity. The experience of the great artists has shown that the lower portion of the abdominal walls should not be allowed to participate in this distention, as the perfect control of the expiratory current is thereby hindered. The lower portion of the abdominal wall should, therefore, be retracted, while the upper portion is allowed to distend.

The upper chest wall should be maintained in the position it assumes during deep inspiration. That is, during expiration it should remain fixed in the position assumed during deep inspiration. In this way the resonance imparted to the voice by the thoracic cavity is increased and maintained of the same quality throughout all the registers of the voice. Failure to thus fix the upper chest wall will result in the voice taking varying tonal qualities as it passes from one register to another. I have heard singers whose voices were rich in quality in the middle register, but in passing into the upper or the lower register assumed an entirely different quality. This change is not always due to a failure to fix the upper chest wall as described, as it may also arise from improper placement of the soft palate. Nevertheless, it is important that the upper wall of the thorax should be maintained in the position assumed during deep inspiration.

The inferior costal or artistic type of breathing may be analyzed as follows:

(*a*) It is chiefly performed by the inferior portion of the chest walls and the diaphragm.

(*b*) The upper abdominal walls also participate in the outward expansion.

(*c*) The inferior abdominal walls are maintained in a retracted position during inspiration and expiration.

(*d*) The upper chest walls are maintained throughout inspiration and expiration in the position assumed during deep inspiration.

The effects sought for are:

(*e*) The greatest chest capacity.

(*f*) Perfect control of the expiratory air current.

(*g*) A maintenance of the same resonant quality throughout all the registers.

Factors which Influence the Voice.—Deviations from the foregoing type of breathing during the act of singing are detrimental to the artistic qualities of the voice. It is true that some of the greatest artists do not use this method of respiration. What their voices would have been had they used this method can only be conjectured. There are so many elements entering into the composition of a great artist, that a fault in one direction may be obscured or compensated for in other ways. For instance, an artist may use superior costal breathing and overcome in a large measure any voice defect resulting therefrom by the brilliancy of vocal execution or by the transcendent spiritual or mental conception which dominates the mind and the body during the singing. There is no shadow of doubt as to the transforming power of an exalted or overmastering conception of the part being rendered. This alone does not make one a great artist. The physical mechanism whereby this con-

ception is expressed should be so coördinated and adjusted as to not detract from its full expression.

The Vocal Resonators.—The voice, like musical instruments, has its sounding board. The sounding board of the piano and the violin are familiar to all. If the string of a violin were stretched upon a heavy slab of marble the tone given off would be weak and disagreeable. It would lack the overtones or harmonics which make it rich and grateful to the ear. The same string when adjusted on a violin gives forth a tone of great sweetness and power, as the sounding board adds numerous overtones to the fundamental tone of the string. The fundamental tone predominates while the harmonics coördinate in such a way as to give it "color" or timbre.

What is true of the violin string is also true of the vocal cords. The fundamental tone is weak and thin, but it is enriched by the harmonics of the resonance chambers of the chest and the head.

The resonance chambers (sounding board) of the head are: (*a*) The ventricular pouches; (*b*) the pharynx; (*c*) the epipharynx; (*d*) the nares; (*e*) the accessory nasal cavities; and (*f*) the mouth.

The resonancefrom the chest has been referred to under Methods of Respiration.

The ventricular pouches do not, perhaps, play an important role in the production of overtones. The pharynx (including the epipharynx) communicates with the mouth and the posterior nares. The soft palate acts as a valve or curtain which regulates the amount of the vibrating current of air going to the nose and the mouth. In this way the quality of the resonance is regulated to suit the musical expression of the singer. The soft palate is, therefore, an important part of the vocal apparatus. If it is elevated against the posterior wall of the pharynx, the voice assumes a peculiar and objectionable quality known as *throatiness*, a condition also assisted by the elevation of the posterior portion of the tongue (H. Curtis).

The soft palate is prolonged downward in two pairs of folds known as the pillars (palatine arches) of the fauces.

The anterior pillar contains the palatoglossus (glossopalatine) muscle, while the posterior pillar embraces the palatopharyngeus (pharyngopalatine). They assist in the modulation of the voice by coördinating with the movements of the soft palate. The function of the uvula is not well understood.

The *faucial tonsils* lie between the pillars, and when enlarged or diseased, affect their motility and impair the voice. They often become adherent to the sinus tonsillaris and thus very materially interfere with their action. I have no hesitancy in indorsing the opinions of Sir Morrell Mackenzie, H. Curtis, and others who advocate their removal in adults when they give rise to the slightest trouble. Curtis says their existence in the adult is unnecessary, as they serve no good purpose. When we remember that in childhood they are composed of lymphatic tissue, to meet the exigencies of the infectious fevers to which childhood is so susceptible, and that in adulthood they are usually fibrous from repeated

and long-continued inflammation or irritation, it is easy to understand why they no longer serve any useful purpose.

If the pillars are adherent to the tonsils, they should be freed, and in most instances this should be followed by complete ablation of the tonsils. (See Operations of the Tonsils.) The immediate effect of their removal is sometimes detrimental to the voice. After a few weeks this passes away and the voice begins to show the value of the procedure. At first the loosened pillars may relax and fail to perform their muscular function. After a few weeks they become attached to the fibrous tissue formed in the sinus tonsillaris, and perform their function in a much better manner than before the tonsillectomy. Sir Morrell Mackenzie says he has never seen any other than beneficial effects to the voice follow their removal.

The *pharynx* is supplied with numerous lymphatic masses, especially near its vault and along the lateral walls. The enlargement of the lymphatic tissue in the vault is commonly known as *postnasal adenoids*, while that along the lateral walls of the pharynx is called *pharyngeus hypertrophica lateralis*. When the scattered masses over the posterior wall of the pharynx are diseased and enlarged, the condition is known under various names as follicular pharyngitis, granular pharyngitis, or "clergymen's sore throat."

Adenoids are not commonly present in adults, although they may be. Many children, however, have marked defects of the voice from their presence. The resonance is interfered with by the obstruction in the epipharyngeal space and the entrance to the nares. The soft palate is crowded forward and downward by them. The voice has a dead or so-called "nasal" quality, which in reality is an absence of nasal resonance. Jean de Reszke has said that the more he studies the voice, the more he is convinced that it is a question of the nose. In other words, the nasal chambers are the chief resonators of the voice. It is obvious, then, that adenoids are an absolute hindrance to the singing voice. The treatment is their complete removal (see Adenoids).

Hypertrophica lateralis impairs the voice by perpetuating a chronic irritation and congestion of the parts, including the larynx. The voice becomes husky and the muscles of the larynx tire upon slight or moderate singing. The hypertrophic glandular masses should be removed.

"Clergymen's sore throat," or chronic pharyngitis, is, according, to Sir Morrell Mackenzie, the most common cause of trouble to singers, the voice becoming husky and tiring upon slight use. Just behind the soft palate the muscles of the posterior pharyngeal wall contract in coördination with those of the soft palate, and aid in closing or constricting the pharynx at this point. Resonance is, therefore, modified by the existence of inflammatory disease of the pharynx, as the muscles of the pharynx and the soft palate are edematous and somewhat restricted in their movements.

Chronic pharyngitis is accompanied by a similar affection of the posterior wall of the soft palate and the uvula. A relaxed or *elongated uvula* is nearly always a sign of chronic epipharyngitis. The practice

of amputating the uvula under such circumstances should not be done without first attempting to cure the preëxisting pharyngitis.

The *tongue* performs an important function in regulating the resonance chamber of the mouth. If there is a shortening of the geniohyoglossus muscle, or an hypertrophy of the entire tongue, this function is impaired. I have frequently seen the tongue adherent quite high on the anterior pillars of the fauces. This not only interferes with the correct movements of the tongue, but with those of the anterior pillars also. In one case of this kind, where the tonsils had been completely removed by cautery dissection, hoarseness became a troublesome factor.

Lingual tonsils and *varicosities* sometimes give rise to hoarseness and a web-like feeling in the larynx.

"Tongue-tie" interferes with the proper performance of the glossal function, especially in articulation.

The *absence of some of the front teeth*, or even marked *irregularity* of the same, might also interfere with resonance and articulation in singing.

Cleft palate (either hard or soft) would for obvious reasons interfere with both resonance and articulation.

The Nasal Chambers.—As these are the chief resonators or sounding boards of the voice, special attention should be directed to their condition in searching for defects of the singing voice. This is of special importance in view of the fact that many pharyngeal and laryngeal affections are caused by preëxisting disorders of the nose.

The nose is divided into two cavities by the nasal septum, and these cavities are still further partially divided by the turbinated bodies. The lateral walls of the nares are in communication with numerous air cells or sinuses which communicate with the nasal chambers. Above the nose they open into the frontal sinuses, while posteriorly they open into the sphenoidal sinuses. Thus the bones of the face form numerous bony chambers which make up the chief sounding board of the vocal apparatus. At least it is this portion of the resonance apparatus that gives the voice its sympathetic and attractive quality. I would not minimize the importance of the chest and other resonance chambers, but I would emphasize the importance of the resonance chambers of the nose.

Defects of the Singing Voice from Improper Methods of Respiration.—While there can be no well-defined analysis of the defects due to improper methods of breathing, there can, nevertheless, be a classification which will emphasize the underlying principles. The following is given for this purpose rather than to catalogue a series of defects:

(*a*) Superior costal breathing does not use the entire thoracic capacity, hence the voice does not possess the reserve force and the evenly sustained quality afforded by the *inferior costal type* of breathing.

(*b*) The same may be said of the abdominal type of breathing with even greater emphasis. The resonance is less pronounced than in either the superior or the inferior costal type, while the control of the expiratory breath is jerky. The voice is thereby rendered uneven and less sympathetic in quality.

(*c*) On account of the greater difficulty in controlling the expiratory breath, the extrinsic and the intrinsic muscles of the larynx are put upon a tension in an involuntary attempt to compensate for the lessened control of the thoracic and the abdominal muscles. This at once impairs the artistic qualities of the voice and in some cases almost destroys its singing qualities. The voice becomes rough, metallic, unsympathetic, and forced. The laryngeal muscles tire easily, prolonged singing being an impossibility. There is a feeling as of a web across the cords. Frequent ineffectual attempts are made to clear the throat.

The foregoing symptoms may be present in so slight a degree as to escape notice, or they may be so pronounced as to ruin the voice.

The superior costal or artistic type of breathing, if intelligently and faithfully practised, will avoid these difficulties and add materially to the power and attractive qualities of the singing voice.

Defects of the Singing Voice Due to Tone Blindness.—J. Mount-Bleyer has called attention to a condition of the hearing centres of the brain which is neither a disease nor a defect, but is the result of inattention or lack of training. For instance, some hear an orchestra as a whole, while others distinguish the tone of each instrument; still others distinguish the exact musical quality of each instrument. The difference is not so much in the mechanism of hearing as it is in the training which the brain centres have received. One, through a love of music, seeks for the finer qualities and variations, while another casually receives only the most general impressions from music. In the first place there is eager, expectant attention, while in the latter there is an indifferent, passive attention. It cannot be said that one has a good ear and the other a poor ear. Each may have equally good ears, or the one hearing the less may have the better. One, however, has a cultivated brain centre, which enables him to distinguish tones and qualities unnoticed by the other. Suitable training of mechanically perfect "ears which hear not," and "ears that hear and hear not," would rapidly convert them into highly discriminating organs of hearing.

We often hear the remark, "I do not sing because I have no ear for music." In other words, he sings poorly because he has not educated the so-called ear to fully appreciate musical intervals, rhythm, and the other qualities which make music so attractive. His belief is that his ears are defective as to musical matters, while the opposite may be true. The whole matter may be summed up in the statement that his "ears" have not been educated.

J. Mount-Bleyer refers to Mr. Evans' work as superintendent of singing in the London schools, where he has 300,000 pupils under his direction. In no instance of obstinate inability to distinguish one sound from another has he failed to educate them to appreciate such distinctions. This fact is significant and should encourage those interested in the cultivation of the voice to give more attention to the exact education of the "ear."

Treatment.—I will here briefly outline the method of procedure used by M. Duchemin, director of music in the asylums of Paris:

"M. Duchemin, setting aside all ideas of notations, commences by demonstrating to the pupil, by means of any musical instrument whatever, the interval of a note and that of a half-note. When the pupil has been sufficiently instructed in the distinction of these intervals, he makes him listen to the interval of a note and to that of a major third. He next makes him compare the major third with the fourth, and thus successively all the major intervals of the same octave. He then returns to the point from which he started, and makes him compare the major with the minor intervals. When the pupil is acquainted with all the ascending intervals, he then repeats all the intervals, but in the descending scales. Finally, when the pupil has compared all the intervals by twos and twos, M. Duchemin makes him listen to isolated intervals, either ascending or descending, at first to those comprised within a single octave, afterward to those within two octaves, and so on." (Mount-Bleyer.)

I have recently tried this method in a few cases where the claim was made that they "had no ear for music," with gratifying results. The quickness with which they learned to differentiate between the various intervals was surprising to me. Both vocal and instrumental music, including the orchestra, assumed a new and delightful place in their lives. I would, therefore, urge that further attention be given to this part of the subject.

It is not within the province of this work to speak of methods of teaching, except in so far as they may apply to the defects of the singing voice. I cannot refrain, however, from the remark that, in my judgment M. Duchemin's method of procedure might be used with great advantage in both vocal and instrumental instruction as a preliminary training in musical education. Public schools, conservatories of music, and private teachers might, with great advantage to their students, follow this method. As music is made up of these intervals arranged in varying rhythm, periods, and sequence, it is of primary importance that the ear be trained to recognize them readily. This is all the more apparent when we remember that only when sensory impressions become intimate parts of one's experience, can they be reëxpressed with power and beauty. An "ear" trained in this way will not only hear the music of others more accurately, but its possessor will be able to render music more accurately himself.

I wish in this connection to consider a few of the more common conditions which impair the singing voice.

Laryngitis of a subacute or chronic type is one of the most frequent derangements of the vocal apparatus to be found among singers. It renders the voice slightly rough or hoarse, and in extreme cases aphonic. The impairment is not constant, but comes and goes with the changes of the weather or with fatigue and use of the voice. Its tendency is to become more and more fixed with each recurrence. The etiology may be embraced in an antecedent nasal disease, an improper use of the laryngeal apparatus, or in some general condition which lowers the vital energy. If it is due to the first, the nose and the epipharynx should receive appropriate attention, with a view to restoring their respiratory

functions. Nasal obstruction, chronic sinuitis, etc., should be treated according to the descriptions given elsewhere in this work. The hoarseness may be due to an improper use of the vocal apparatus; the faulty method should be detected and corrected if possible. Six years ago a lady consulted me concerning her throat, stating that she was a student of vocal music, and that after moderate use of the voice she became slightly husky, there being the sensation of a web over the cords. Upon examination of the nose and throat I could detect no apparent cause for the condition. I found her, however, to be quite "high-strung," and asked her to go through some of her exercises in my presence. It was quite apparent that the whole muscular system, including the larynx, was on a "high tension." As she was a woman of culture and intelligence, I explained to her the necessity of overcoming this overtension, and offered her some suggestions as to how to do it. She was told to assume a natural and comfortable position in the chair, and to allow her arms, including the hands, to drop at her sides in extreme relaxation. She was then to allow the whole body, including the tongue and the lower jaw, to participate in the relaxation. Next she was to hum very softly the note that came naturally to her throat. After she had gone through with this exercise for a few minutes the vocal exercise was varied by singing the tones within a range of one-half octave, cautioning her all the time to maintain extreme relaxation of the whole body. The exercises were gradually broadened to those she was in the habit of singing, the difference being in her physical condition during their production. In a surprisingly short time she thus trained the extrinsic and the intrinsic muscles of the larynx to a normal tension, which not only caused the hoarseness to disappear, but resulted in a placement of the larynx which gave added richness to her voice. There was a poise and dignity in it hitherto unnoticed.

I do not mean to imply that all persons suffering from "high tension" can be made to sing beautifully, but I do want to say that many singers who become hoarse from overtension of the laryngeal muscles may be speedily and effectually relieved of the hoarseness and other tension anomalies of the voice by suitable advice and vocal exercises. The *manner* of going through with the exercises should be emphasized.

If the hoarseness is due to some general *systemic disturbance* which results in laxity of the cords or the laryngeal mucosa, remedies suited to the case should be given.

CHAPTER XXIX.

DEFECTS OF SPEECH.

Defects of speech are due to a great variety of causes, most of which are extra laryngeal. The larynx is the primary source of spoken tones, but it is not the complete vocal apparatus. It has been customary, in times past, to speak of it as the vocal organ, but this can no longer be done in strict conformity to well-known facts concerning voice production. While the vibrations of the vocal cords produce the primary tone, it is much modified by the chest, pharynx, epipharynx, nasal and accessory chambers, tongue, and the mouth. The character of the tone is also somewhat dependent upon the respiratory movements of the chest, abdominal muscles, and diaphragm. The voice changes when there is a marked increase in the physiological activity of other parts of the body, as at puberty. This is especially noticeable in boys. Mental states exert a marked influence on the quality of the voice, as may be noted in anger, joy, hatred, and love.

It is, therefore, apparent that defects of speech may have their origin in parts remote from the laryngeal apparatus. The demands of domestic and social life often make it important that one possess a voice that is pleasing in timbre, range, pitch, and modulation, as well as in articulation. Hence, attention should be directed to some of the more important lesions which impair the quality and integrity of speech.

Speech and Brain Development.—That there is an intimate connection between the development of the organs of speech and the cerebral centres of intelligence is, I think, scarcely open to question. This is especially true in children. I have seen them four years of age, apparently as bright and intelligent, with the exception of speech, as other children of the same age. They had reached the age at which spoken language should be used to communicate their wants and express their ideas. If it is not acquired within a reasonable length of time, they are in danger of becoming mentally inferior to other children of like age. That this inferiority is not altogether due to their inability to acquire knowledge through the senses, and through the natural inquisitiveness of childhood, has been shown by various writers who have reported remarkable increase in the mental development in children who were only trained to use the muscles of articulation, not yet having been led into the realm of thought, in which information concerning things and affairs is inculcated. Makuen, of Philadelphia, reports cases in which the simple training of the muscles of the mouth, tongue, and fauces aroused the dormant faculties of the brain. The use of the motor tracts, of the muscles of speech, stimulated the centres of speech and thought, and

the patient passed rapidly from a "backward child" to one of ordinary intelligence.

I will not at this time consider fully the interdependence of the organs of speech and mental development, but will only thus briefly refer to it in order to emphasize the importance of slight impediments of speech in children who are of the age at which language is most naturally acquired. It is obvious that an impediment at this time is a much more serious hindrance than it is after speech has been acquired. It is very much easier for him to cover up or compensate for a defect in the organs of speech, if the faculty of speech has been already acquired, than it is if that faculty is not developed. Hence, abnormalities of the organs of speech, which develop after speech has been acquired, result in but slight defects of speech; whereas abnormalities of a similar nature, in a child who has not yet acquired the faculty of speech, will in some cases prevent the acquisition of spoken language, while in others it will only interfere with it to such an extent as to make it defective. If this were the extent of the damage done, it might be passed over with comparative indifference; but, as I have already suggested, mental development is also hindered. I have no doubt that a considerable number of the so-called "backward children" coming under this category are so chiefly on account of a slight physical imperfection of some part of the organs of speech. I do not mean to say that all "backward children" come under this classification, as no doubt many of them are defective in cerebral development from quite different causes. I only wish to call attention to the fact that each case should be carefully studied, the physical impediments to spoken language corrected, and suitable training of the organs of speech instituted, in order to give the child the best possible chance of taking the position in society to which he was born.

An analysis of the peripheral causes of the defects of speech is interesting as well as instructive, especially to those who meet them in practice, or at least to those who attempt to treat them. Defects of speech are subdivided into six varieties, by R. Cohen, of Vienna as follows:

1. Stammering.
2. Stuttering.
3. Nasal twang.
4. Defects due to malformations of the hard and soft palates.
5. Deaf-mutism.
6. Defects of speech due to diseases of the central nervous system.

Instead of following the classification given by Cohen, the author will treat the subject under the following heads:

1. Defects of speech of nasal origin.
2. Defects of speech of epipharyngeal and faucial origin.
3. Defects of speech of lingual origin.
4. Defects of speech of laryngeal origin.
5. Defects of speech of thoracic and abdominal origin.
6. Defects of speech due to deaf-mutism.
7. Defects of speech due to malformations of the palate.
8. Defects of speech of central origin.

1. **Etiology of Defects of Speech of Nasal Origin.**—(*a*) Deflection of the septum. (*b*) Spurs or ridges on the septum. (*c*) Split or double convexity of the septum from an old traumatic lesion or abscess. (*d*) Nasal polypi or other neoplasms. (*e*) Chronic turgescence of the inferior nasal conchæ. (*f*) Hypertrophy of the inferior nasal conchæ. (*g*) Hypertrophy (mulberry) of the posterior ends of the inferior and middle conchæ. (*h*) Congenital occlusion of the posterior nares. (*i*) Displacement of the columnar cartilage. (*j*) Enlargement of the middle conchæ from hyperplasia or cystic degeneration. (*k*) Obstruction to the olfactory fissure.

The foregoing conditions do not cause pronounced defects of speech, as they only interfere with the resonant quality of the voice. Nor do they materially interfere with the muscular mechanism taking part in speech production.

In a general way they may be said to produce those changes in the voice which make it "dead," "muffled," "thick," "flat," or lacking in resonance. The speech is still further modified by the diffidence so often accompanying nasal obstruction. The diffidence, backwardness, or timidity is due to a self-consciousness, to which the defect gives rise, and to a direct effect upon the brain and general system, through the lymphatic and venous stasis attending nasal and postnasal obstruction. Guye, of Amsterdam, has called attention to a condition which he calls "aprosexia," or difficult attention.

Inability to fix the attention is often attended by diffidence and timidity, and not only is articulation impaired thereby, but fluency and coherency is also somewhat affected.

The elementary sounds of spoken language which depend largely on the resonance of the nasal chambers are not so markedly impaired as those but slightly depending upon it. For instance, the letters *m*, *n*, *b*, and *d* derive their peculiarity from the initial sound, while the final vowel and nasal tones are secondary. Notwithstanding the fact that they are secondary, their absence or suppression makes a noticeable change in the speech, and amounts to a defect. If the final vowel-nasal sound in the above examples were more prominent, the nasal obstruction would not interfere with speech nearly so much, as the speaker could "force" them, and thereby somewhat overcome the apparent effects of the stenosis. The letters *m* and *n* end in a kind of "hum" which is very difficult to produce in nasal obstruction, especially when the hum is somewhat suppressed.

The letters *b* and *d* seem to begin with the sound thrown forward against the lips (*b*) and against the tip of the tongue and roof of the mouth (*d*) respectively. The initial sound is, however, made in the larynx and rendered resonant in the chest and nasal chambers. Nasal obstruction modifies the resonance, thus causing a "dead" or "flat" tone to explode at the lips or the tip of the tongue. Thus the speech is rendered defective. We might continue the analysis of the various sounds in speech, showing how nasal obstruction from one or more of the foregoing conditions affects the beauty, music, rhythm, and coherency

of speech. We might go still farther and show that coherency of thought is impaired also.

2. **Etiology of Defects of Speech of Epipharyngeal and Faucial Origin.**—(*a*) Postnasal adenoids. (*b*) Fibroma or other neoplasms of the nasopharynx (epipharynx). (*c*) Chronic catarrhal thickening of the mucosa of the epipharynx. (*d*) Hypertrophied or hyperplastic faucial tonsils. (*e*) Adhesions of the anterior and posterior pillars of the fauces to the tonsils. (*f*) Depression of the soft palate against the root of the tongue by the postnasal adenoids. (*g*) Paralysis of the palatine muscles, especially those of the membranous curtain which control the current of air passing to the nares. (*h*) Paralysis of the soft palate and uvula. (*i*) Adhesion of the anterior faucial pillars to the base of the tongue. (*j*) Cleft soft palate and uvula. (*k*) A shortened soft palate, as is sometimes found after operation for cleft palate.

In the above table the muscular mechanism of speech is affected, and the speech defects are correspondingly more pronounced. The explanation of the more marked speech defects which seem to have their origin in this classification is not as easy as may appear on first thought. We cannot say that the speech is defective because the muscular action of the parts is interfered with, because many cases come under our observation with great muscular impairment who have little impediment of speech, while others can scarcely be said to have articulate speech at all; and in still others they cannot be said to have coherent thought. The explanation in some cases is embraced in the fact that the muscular impairment existed quite early—before articulate speech was acquired. The impediment thus interfered with the acquirement of articulate speech. The presence of postnasal growths produced mental hebetude, (aprosexia), heretofore referred to, and the mental ability to acquire articulate speech and consecutive thought was thus impaired. In a few years the growing child becomes more vigorous in mind and body, and makes renewed and voluntary efforts at articulate speech. His failures humiliate and irritate him. He avoids the necessity of speech as much as possible. The speech centres and motor vocal tracts are little used, and lie dormant. His mental growth is thereby retarded. The sensitive, reticent child loses the mental growth to be gained by spoken language. He becomes and is regarded as a "backward child."

It becomes the duty and privilege of the rhinologist and laryngologist to loosen the bonds which fetter his imprisoned mind, thus enabling him to enjoy the common pleasures of life, even though he may never become a brilliant member of society.

3. **Etiology of Defects of Speech of Lingual Origin.**—(*a*) Inflammatory adhesions binding the tongue to the anterior faucial pillars and epiglottis. (*b*) A congenital shortness of the geniohyoglossus muscle. (*c*) Tongue-tie. (*d*) Enlargement of the tongue. (*e*) Excessive enlargement of the lingual tonsils.

Of the foregoing, the most important are adhesions of the tongue to the anterior faucial pillars, tongue-tie, and shortening of the geniohyoglossus muscle. Either condition materially interferes with the

articulatory function of the tongue, thus impairing speech. Lisping is a common sign in these conditions. If these lesions exist prior to the acquirement of speech, they may give rise to the clinical picture heretofore referred to under "backward children." The early correction of these physical imperfections may place the child on an equal footing with his fellows, and save society the disagreeable presence of a crippled mind in its midst.

4. **Etiology of Defects of Speech of Laryngeal Origin.**—(*a*) Too great strength in the uplifting muscles of the larynx. (*b*) A weakness of the down-pulling muscles of the larynx. (*c*) Laryngitis. (*d*) Singer's nodules. (*e*) Chorditis nodosum. (*f*) Tuberculous inflammation and infiltration. (*g*) Perichondritis. (*h*) Laryngeal rheumatism. (*i*) Catarrhal accumulations. (*j*) Neoplasms. (*k*) Paralysis of the intrinsic laryngeal muscles.

If the acute affections of the larynx, as laryngitis, and the chronic conditions, such as chronic laryngitis, laryngeal tuberculosis, perichondritis, paralysis, rheumatism, and neoplasms which cause hoarseness or aphonia, are omitted, there is little to catalogue as causes of defects of speech. This is the more surprising when we recall the fact that the larynx is the primary source of the voice.

Makuen has referred to a condition of the extrinsic muscles of the larynx which rendered the voice sibilant and *falsetto*. It is given in the table above in *a* and *b*, and is interesting because it illustrates one of the fundamental problems in voice culture—namely, voice placement. If the larynx is allowed to rise too high the voice becomes *falsetto* and unnatural in quality. If, on the other hand, the laryngeal box is held down in its proper position, the voice assumes its natural register, the tone being pure and pleasing to the ear—that is, it is natural.

The natural and simple things of life appeal most strongly to normal minds. The simple rural scenery, the grandeur of the mountains, the simple melodies of the negroes, the rugged vitality of the Wagnerian opera, and the eloquence of the orator stir the imagination, quicken and fascinate the mind, as the unnatural, the complex, and the artificial cannot do.

Hence the aim should be to give those having defective speech a speech that is simple and natural. It should be natural in quality, tone, pitch, *timbre*, and rhythm, as well as in modulation and articulation.

5. **Etiology of Defects of Speech of Thoracic and Abdominal Origin.**—(*a*) Pulmonary tuberculosis in its relation to stammering. (*b*) Irregularity of the respiratory rhythm.

Irregularity of the respiratory movements is an almost constant factor in stammerers. Whether this is due to some fault of the respiratory centre, or to some peripheral lesion, has not yet been determined. Makuen has called attention to the fact that all, or nearly all, stammerers are either tuberculous, or come from families with this disease well marked in its history. He thinks the peripheral tuberculous lesion accounts for the irregularity of the respiratory rhythm, which in turn causes the stammering.

His conclusion is not necessarily correct, as the lack of rhythm may be due to developmental causes within the medulla, or along the motor nerve tracts leading to the diaphragm, lungs, and intercostal muscles. It is a well-recognized fact that those having a tuberculous tendency, especially those inheriting it, have a lowered cellular vitality, and that nutrition, or the processes of metabolism, are imperfectly performed. It is therefore possible to explain the lack of respiratory rhythm as being the result of the malnutrition and faulty development of the respiratory centre and the motor respiratory tracts.

Whatever the explanation may be, the clinical fact remains, that nearly all persons who stammer are of tuberculous parentage and complain of ill health. Another fact, however, which makes it seem probable that the lesion is peripheral (in the lungs and diaphragm) is that under suitable treatment and training they may be freed from the speech defect.

La Fayette Page calls attention to intoxications arising from diseased conditions of the upper respiratory tract. He cites the work of Schwalbe and Retzius, who demonstrated the connection of the lymphatic vessels of the nasal mucous membrane and those of the cranial cavity. Through the lymphatic and venous stasis of the nasal mucous membrane, the effects extend to the cranial cavity, thus giving rise to mental dulness.

He also cites the intimate nervous connections between the nasal mucous membrane and the cortical centres of the brain, as a possible source of mental dulness and irritability.

Makuen in his writings seems to lay greatest stress on impairment of the organs of speech, as the larynx, fauces, nose, or tongue, as the chief hindrances of mental growth and development.

In the opinion of the author, defects of speech and mental acumen are due to complex conditions which it would be difficult to define. It appears, nevertheless, that children who are defective in speech are improved by correcting, either surgically or by training, the physical impediments to speech. We also know, from clinical observation, that upon the removal of postnasal adenoids or section of the geniohyoglossus muscle, etc., the mechanism of speech and the mental activity of the child are often much improved. Those who hold, as Guye and Page, that the mental quickening is due to the removal of the cause of the venous and lymphatic stasis, overlook the fact that the mechanism of speech is at the same time improved. The soft palate which was crowded down against the base of the tongue is freed, or the tongue is loosened, and resumes its normal function in articulate speech. Again, those who hold the views of Makuen to the exclusion of all others overlook the fact that the veno-lymphatic stasis, with its attendant toxemia and brain hebetude and irritability, is overcome and allows the brain to resume its normal activity.

It should not be forgotten that the toxemia referred to by Page affects the system much deeper than the brain. The whole system is poisoned, as has been shown by the author in various articles on mouth breathing.

There may be great imperfection of speech without impairment of

the mental faculties. Nevertheless, it must be said that in nearly all cases "the speech belieth the man."

Elegance of speech is an index of a finished mind. Training the organs of speech improves not only the expression of thought, but the thought itself is more elevated, more finished. The quality of mind is improved by a better mode of expression.

6. **Defects of Speech Due to Deaf-mutism.**—This subject is quite fully considered under deaf-mutism, and will only be briefly analyzed in this connection.

(*a*) Congenital defect of the auditory apparatus.
(*b*) Acquired defect of the auditory apparatus.
(*c*) Nasal and epipharyngeal diseases.
(*d*) Improper and untimely training.
(*e*) No training.

Congenital defects of the auditory apparatus are probably present in about one-half of the cases of deaf-mutism, whereas in the balance the defect is due to the ravages of some disease, usually one of the exanthematous fevers. In either instance the child is partially or totally deaf, and cannot, therefore, readily acquire the faculty of speech. He is not mute because the organs of speech are defective, nor because the centres of speech are impaired. Both the peripheral organs of speech, and the central mechanism of the brain may be in perfect condition. The child is mute because he cannot hear others speak, and is thereby deprived of the most useful aid in learning, namely, imitation. If he learns to speak he must be taught by other and more difficult methods. He must be given timely and proper special training. If he has acquired deaf-mutism after having some ability to speak, he may not be a mute in the full sense of the word, but may need some special training to prevent his losing the little speech he already possesses. If the deafness comes before the seventh year of age, there is a strong tendency to lose the faculty of speech; hence, special training is necessary to maintain that already acquired, as well as to broaden it. If the deafness comes on after the seventh year, the patient rarely loses the faculty of speech, hence his training can be more simple than that of a child losing his hearing before that age.

Reference has been made under Deaf-mutism to the interdependence of the brain development and the use of the organs of speech. Brain development and intellectual growth depend largely upon the voluntary use of the organs of speech. It is a common observation with most of us that an idea or train of thought is much clearer after having been expressed in words. The growth of the brain seems to depend upon the coöperation of the various senses and peripheral organs. The intelligence of the child will, therefore, largely depend upon the use of its vocal apparatus, as well as all the other peripheral organs of the body.

At certain ages the various faculties of the brain develop most naturally, and these periods should be taken advantage of by his instructors. At one time the imagination, which later in life finds expression in so many practical ways, has the ascendancy. The training at this

period should be of such a character as to lead the imagination along wholesome lines. It should be bridled, but not suppressed. When adulthood is reached, and the practical affairs of life must be faced, the faculty once known as imagination is utilized in foreseeing the outcome of a given series of events. Cause and effect, and the sequence of events, will be correctly interpreted, somewhat in proportion to the character of the training received during the imaginative period in childhood.

The other faculties of the mind should also receive due consideration in the training of the child. The child that is deaf needs this training tenfold more than the one with normal hearing. It becomes obvious, therefore, that the deaf-mute needs a teacher well schooled in the knowledge of the child mind, that he may facilitate its unfolding in the most wholesome and natural manner. *Not one mother in ten thousand* is fitted for this task, and even if she were, her love for the child would probably make her its worst enemy, in so far as its proper training and restraint are concerned. The proper thing to do, therefore, is to place the child who is a deaf-mute under the care of the most competent teacher available for the purpose, at the earliest possible time, certainly before the sixth year of age.

The child that has no training will remain a deaf-mute. He may go through the manual sign language, learn to communicate with his fellows, but he will always be much handicapped in the race of life, as his communication with his fellows must be limited to the few who have likewise learned the sign language. Then, too, he is forever debarred from the pleasure and developmental power derived from the mechanical action of the vocal apparatus, and the pleasurable sensation experienced in ventilating the blood and stimulating articulation, which accompany voice production (Makuen).

CHAPTER XXX.

NEOPLASMS OF THE LARYNX.

BENIGN tumors of the larynx and the trachea are characterized by absence of pain and the absence of a tendency to recur, or to destructive processes. Malignant neoplasms, on the contrary, are characterized by pain, recurrence, and destructive processes.

Varieties.—Almost all types of benign tumors occurring elsewhere in the body are found in the larynx. The following are more or less frequently reported in the literature: Papilloma, fibroma, myxofibroma, polyp, cystoma, lipoma, telangiectases, chorditis nodosa, and pachydermia laryngis.

Location.—In looking over the literature for a period of ten years, I found lipoma and cystoma on the epiglottis; cystoma on the ventricular pouches; lipoma, cystoma, and papilloma in the arytenoid region; polyp, telangiectasis, fibromyxoma, papilloma, fibroma, singer's nodules (chorditis nodosa), and myxocystoma on the upper surface of the vocal cords and in the subglottic region. These and doubtless other benign neoplasms occur in the locations indicated.

Etiology.—Much has been written, while but little is known, concerning the exciting causes of these growths in the larynx.

Jonathan Wright says: "There is a strong likelihood that if these tumors are not the result of chronic inflammatory changes, the chronic imflammations play an important role in their etiology, and that this should be borne in mind in the treatment." They occur at all ages, but most frequently in middle adult life. Papilloma, however, occurs more frequently in children, measles seeming to be a prolific exciting cause. Both men and women are affected, but they are found more frequently in men. Sir Felix Semon has called attention to the fact that they are described in Germany and France more frequently than in the United States or England.

Benign neoplasms are relatively more common among street vendors, singers, and speakers. Congenital tumors are rare. Papilloma is the most common variety. The anterior commissure is the most frequent site for laryngeal tumors. Lipoma rarely occurs within the cavity of the larynx, but is located extrinsically on the anterior surface of the epiglottis. Syphilis and tuberculosis, though they produce growths of their own kind, have little influence in causing innocent neoplasms. Papilloma, fibroma, and singer's nodules are more frequent than lipoma, myxoma, and cysts. Gerhardt says he has never seen an adenoma, a chondroma, angioma, or a neuroma. Others, however, have reported

adenoma in the larynx. Moritz Schmidt, in his work on *New Growths of the Upper Air Passages*, gives the following table of laryngeal tumors seen in his clinic of 32,997 cases in ten years:

	Men.	Women.	Cases.
Fibroma	178	78	256
Papilloma	31	15	46
Singer's nodules	56	53	109
Lipoma	1	0	1
Myxoma	3	0	3
Fibromyxoma	1	0	1
Tuberculous tumors	14	22	36
Cysts	2	6	8
Sarcoma	3	0	3
Carcinoma	61	15	76
Tracheal carcinoma	1	1	2

This table is significant, and is contrary in some respects to the accepted opinion. For instance, in the above table fibroma occurs more frequently than papilloma. He found 256 fibromata and only 46 papillomata. Singer's nodules occurred in 109 cases, hence both the fibromata and the singer's nodules (chorditis nodosa) were found more frequently than papillomata. The apparent discrepancy is, no doubt, in the differential diagnosis, which is often carelessly made. It is too often made without a microscopic examination, and is, therefore, often incorrect.

The discussion concerning the exciting causes of benign neoplasms may be summarized as follows:

The causes are (*a*) local and (*b*) constitutional.

(*a*) Prominent among local causes is irritation. This produces hyperemia and cell activity, hence the persistence and the exaggeration of these two conditions may endanger life by allowing the tumor to grow so large as to interfere with respiration, or they may assume malignant tendencies. Mouth breathing is an important factor in producing irritation of the larynx. The required amount of moisture and warmth is not carried to the larynx, and the mucous membrane is overtaxed by the burden thrown upon it. The imperfectly prepared air causes a dryness as well as a hyperemia incident to the increased physiological activity of the mucosa, and the resultant irritation leads to an increased cellular activity. In the "hurry," so to speak, the cellular arrangement is disarranged and neoplastic growths result.

(*b*) Constitutional influences play an insignificant part in the etiology of innocent neoplasms. This does not take into consideration the specific constitutional dyscrasias, as syphilis and tuberculosis, which produce peculiar local laryngeal redundancies.

In an adult laryngeal papilloma is often associated with a warty skin, so much so that we can almost speak of a "warty diathesis." This theory was advanced by Fauvel, but it may be said, on the contrary, that the skin and the larynx have a totally different developmental origin. Sir Morrell Mackenzie maintained that syphilis and tuberculosis exercised a decidedly antagonistic influence to the development of new formations. Lennox Browne did not share this view, his experience rather proving the reverse. Moritz Schmidt thinks they favor new formations,

because they always induce a low state of resistance or a local vulnerability.

The Tendency to Malignancy.—It has been held that operative interference has a tendency to convert benign growths into malignant ones.

This belief grew out of the fact that cases operated upon and thought to be benign were shown to be malignant in the recurrent state. Sir Felix Semon has shown that unoperated cases show even a greater percentage of converted malignancy than the operated ones. The following are his figures:

In a total of 10,747 benign cases reported in the literature, 45 afterward became malignant. They were divided as follows:

In 8216 operated cases, 33, or 1 in 249, became malignant.

In 2531 non-operated cases, 12, or 1 in 211, became malignant.

It is thus shown that a greater percentage of the non-operated cases become malignant. These figures go a long way toward disproving the old notion that operative interference is an active factor in converting non-malignant neoplasms into the malignant variety. At the same time we must reckon the immense benefits derived by operations upon cases which do not become malignant, but continue to be troubled by the benign neoplasms.

Neoplasms of the Subglottic Space.—Ferreri states, with reason, that subglottic polypi often cause greater obstruction to respiration than polypi of the supraglottic space. They do not, however, cause a change in the voice until they come in contact with the vocal cords, whereas, tumors of the supraglottic region cause it from the beginning.

The development of subglottic polypi is insidious, hence they are not usually diagnosticated until well advanced, a fact which explains why they are usually larger than supraglottic polypi.

The most common form of benign subglottic tumor is the fibroma. Myxoma does not occur quite so frequently, but it is not uncommon to find it associated with fibroma in the form of a myxofibroma. Ferreri also says that, exceptionally, cysts, chondromata, and circumscribed keratosis have been observed in the subglottic space. Papilloma is rarely found in the subglottic region. When present they are difficult to remove by the intralaryngeal route, except by direct laryngoscopy. Thyrotomy (laryngofissure) may therefore become necessary, or infrathyroid laryngotomy may be the chosen method of operation.

The endolaryngeal methods of operating are with forceps, the snare, or the galvanocautery, either by direct or indirect laryngoscopy. Attacks of suffocation may render tracheotomy imperative, in which case the growth may be removed through the tracheal wound.

Papilloma.—**Etiology.**—According to Jonathan Wright, this type of neoplasm occurs more frequently in the larynx than any other variety. According to the table of Moritz Schmidt fibroma occurs more frequently. They are closely related to various inflammatory growths which accompany syphilis, tuberculosis, and pachydermia. In view of this fact, many laryngologists regard chronic inflammation as an etiological factor. As already stated in General Etiology,

this is still a mooted question. According to Jonathan Wright, they are usually classified as papillary fibromata. This may account in part for the discrepancy between Schmidt and other writers. Schmidt may have classified as fibromata what others call papillary fibromata. Schmidt observed papilloma in about 9 per cent. of his cases, Schrötter in about 18 per cent., and Moure in about 50 per cent. Schmitzler and Killian say they occur more frequently in children, and that fibromata occur more frequently in adults.

Symptoms.—Papillomata are usually attached to the anterior third of vocal cords, or at the anterior commissure, though they may spring from any portion of the larynx. They may be diffuse, sessile, or pedunculated. If pedunculated, the attachment may be below the cords, while the tumor is above them, or *vice versa*. They may be congenital, in which event the child is often aphonic from birth. Hoarseness with increasing aphonia is suggestive of papilloma. In children the tumor can easily be felt by digital examination when it is above the cords. They vary in size from a grass seed to a hickorynut. They occur both as single and multiple tumors. When removed they often recur, though not necessarily at the old site.

Microscopically they have a stratified epithelial covering over a core of more or less vascular connective tissue. The outward growth of the epithelium is in contrast to the involuted growth of carcinoma. True nests or pearls of epithelial tissue have been found.

Treatment.—The treatment ranges anywhere from non-interference to tracheotomy or laryngofissure. Spontaneous cures have been reported.

The growths may sometimes be removed by indirect laryngoscopy with laryngeal forceps after anesthesia with a 10 to 20 per cent. solution of cocaine. The removal by direct laryngoscopy is a much better procedure.

OPERATION BY INDIRECT LARYNGOSCOPY.

In describing this operation for the removal of papilloma, it must be taken as a type of surgical procedure used in the removal of nearly all varieties of benign laryngeal neoplasms. Each case will, of course, require some modification of the various steps in the operation.

Technique.—The Preparation of the Patient.—(*a*) The throat should be gently sprayed with Seiler's or Dobel's solution. The fauces and the larynx should then be sprayed with a 2 per cent. solution of cocaine to reduce the reflex irritability.

(*b*) The larynx is then swabbed with a 10 per cent. solution of cocaine. This should be repeated at intervals of five minutes until anesthesia is induced. If this does not produce anesthesia after several applications, one or two applications of a 20 per cent solution should be made. This strength of solution should be used sparingly and with caution, although in my experience the larynx has been quite tolerant of cocaine.

(*c*) The laryngoscopic mirror is introduced into the oropharynx with its reflecting surface directed downward and forward so as to reflect the

rays of light from the head mirror to the growth, the tongue being gently rolled forward on the forefinger of the left hand. The epiglottis is thereby lifted, exposing the larynx to view.

Fig. 300

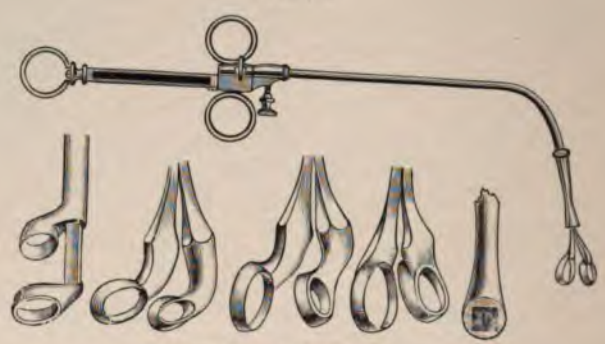

Krause-Heryng laryngeal forceps.

Fig. 301

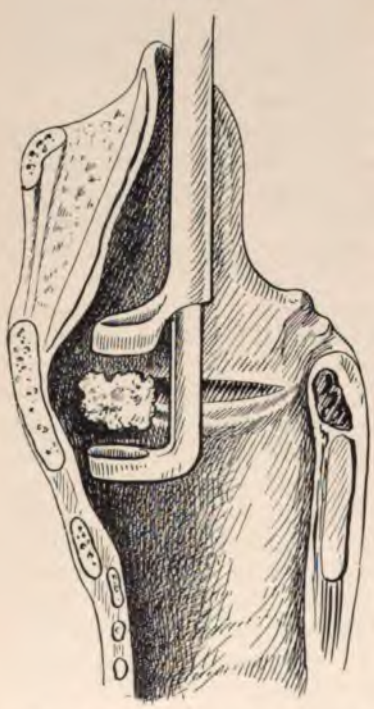

Detailed drawing showing the laryngeal forceps placed to remove the neoplasm.

(*d*) Next introduce the curved laryngeal pincette or double cutting forceps (Fig. 300) into the upper space of the larynx until its cutting extremity touches the growth (Fig. 301). It must be borne in mind that the image in the mirror is reversed, hence the movements of the instrument should be directed in an exactly opposite direction from what appears to be necessary according to the image in the mirror. For instance, if the tip of the instrument seems to need a more forward position, so manipulate the handle as to move the tip backward, *i. e.*, lower the handle. If the tip of the instrument seems to be too near the posterior portion of the image, it is in reality too near the anterior portion. A little practice upon a model or upon a patient, will familiarize the student with this procedure. The surgeon soon learns to intuitively move the instrument in the proper direction.

It is of great aid to first firmly fix in the mind the anatomical relations of the various parts of the larynx. For example, that the epiglottis stands at the anterior commisure of the larynx, and the arytenoid prominences at the posterior commissure.

These simple anatomical guides, if impressed upon the memory of the operator, will, all unconsciously, lead him to intuitively guide the laryngeal instrument in the proper direction.

(*e*) Having located the growth with the laryngeal forceps or pincette, so manipulate the handle of the instrument as to separate the tips, and then with a slight downward movement of the instrument close the forceps upon the neoplasm and remove it, *en masse* or in part. If the growth is large or multiple, several repetitions of the foregoing procedure may be required. The growth should be removed with as little trauma to the surrounding tissues as possible.

OPERATION BY DIRECT LARYNGOSCOPY.

(See Direct Laryngoscopy.)

MALIGNANT NEOPLASMS OF THE LARYNX.

The Lymphatic Drainage of the Larynx.—The lymphatics of the larynx are of clinical importance in malignant neoplasms and infectious diseases of the larynx. According to Most, Cunes, Boubland, and Green the following summary gives the essential facts:

The lymphatic trunks which take their source from the larynx are derived from a network of radicles which extend throughout the larynx beneath the mucous membrane. This network is divided by a horizontal plane at the level of the vocal cords into a supraglottic and an infraglottic portion. The supraglottic portion includes the lymphatics of the epiglottis, arytenoids, ventricular bands, ventricles, and vocal cords. The network of vessels is continuous throughout these areas. Over the upper portion and posterior surface of the epiglottis the network is fine and the meshes are far apart. In front and lower down, especially at the sides, the meshwork is denser and the strands thicker. Over the arytenoids, ventricular bands, and throughout the ventricular pouches the lymph channels are thick and closely woven. In the vocal cords, however, the network is very fine and more sparse than in any other part of the larynx. The infraglottic network is finer than that above the vocal cords, but by no means as fine as that of the cords themselves. The lymph from these radicles is collected into trunks which leave the laryngeal cavity at certain definite places.

In the upper part of the larynx the only place of egress is through the thyrohyoid membrane. The lymph vessels of the upper network assemble in the vicinity of the aryepiglottic folds into several trunks, three to six in number, which leave the larynx through the above-mentioned membrane near the superior thyroid artery, a corresponding group being on either side of the larynx.

These trunks course outward and backward, more or less in relation to the superior thyroid artery, to the carotid region, terminating in nodes which lie along the surface of the internal jugular vein at the level of the

bifurcation of the carotid. The upper trunk of this group often runs backward, after emerging from the thyrohyoid membrane, along the hyoid bone to the tip of the lesser, and thence outward to a node lying on the inferior aspect of the posterior belly of the digastric muscle. The lower trunks of this group may run by a lower course, outward and downward, into glands in the chain lying on the surface of the internal jugular vein, below the lower border of the lateral lobe of the thyroid gland (Fig. 302).

The collecting trunks of the infraglottic network are divided into an anterior and a posterior division. The anterior division consists of three or four small trunks, which pierce the cricothyroid membrane in the median line and terminate in small glands which lie in the median line at uncertain locations. The uppermost of these is fairly constant and lies in the V-shaped space on the cricothyroid membrane formed by the inner borders of two thyroid isthmuses, and a third on the anterior surface of the trachea. These two are denominated respectively the prethyroid and the pretracheal glands. They may receive trunks from the anterior infraglottic group. Efferent trunks from these glands run to the before-mentioned chain of glands lying on the anterior external surface of the internal jugular vein.

Fig. 302

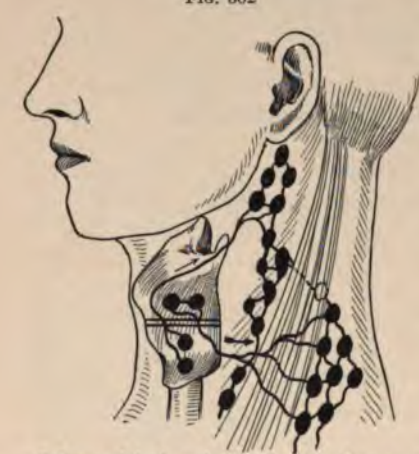

Schema of the lymphatic flow from the supraglottic and the infraglottic regions of the larynx. The glands of the supraglottic region flow into the posterior chain, while the infraglottic glands flow into the anterior cervical chain of glands. This is of diagnostic significance in determining if a cancer is supraglottic or infraglottic.

The posterior division of the infraglottic collecting trunks, three to five in number, penetrate the cricotracheal membrane at or near the line of junction of the cartilaginous and membranous portions of the trachea and run into a chain of glands, two or five in number, which lie along the course of the recurrent laryngeal nerve known as the recurrent chain. From these glands run vessels communicating with the lowermost glands of the internal jugular chain and a few to the supraclavicular group of glands.

The lymphatic drainage from all parts of the larynx thus eventually leads into the chain of glands lying under the sternomastoid muscle, along the surface of the internal jugular vein, or into the supraclavicular glands. The prelaryngeal, prethyroid, and pretracheal glands are merely intercepters of the current on its way to the deeper glands.

The spread of infection or of malignant neoplasms from either the supracordal (glottic) or infracordal region is to the deep lymphatic nodes along the internal jugular vein beneath the sternomastoid muscle, or, in other words, to the same lymphatic system into which the tonsils

drain. In infectious and advanced malignant processes of the larynx the deep cervical glands along the internal jugular vein and beneath the sternomastoid muscles are enlarged. In malignant tumors of the larynx such enlargement of the glands constitute a contraindication to operative interference.

Varieties.—Epithelioma, adenocarcinoma, and sarcoma. Of these, the epithelioma occurs the most frequently. Ziemssen reported 57 epitheliomata in 68 malignant cases, while 9 were sarcomata. Bosworth collected 334 cases, of which 204 were carcinomata and 130 sarcomata. Sir Felix Semon, in 1899, gathered the statistics of all laryngeal growths, amounting, all told, to 10,747 non-malignant cases and 1550 malignant cases, 1 in 7 being malignant.

General Facts.—It may be stated, with some confidence, that malignant neoplasms may be cured if operated sufficiently early. This is not so often done as it should be, hence the mortality rate is still frightfully high. The crying need of the hour is "an early diagnosis." How sad the comment upon medical attainments is the "fact" that but few practitioners are able to diagnosticate laryngeal cancer until the patient is *in extremis*. Yet how easy it is to learn one or two simple indications that should at least put them on their guard, and save their self-respect, their reputation, and the lives of their patients.

What, then, are the early indications of laryngeal cancer? The early signs of cancer of the larynx are:

(*a*) Continued hoarseness without cough, and without other known cause.

(*b*) Sharp, sudden pains in the larynx, the ear, or the pharynx.

(*c*) Age, the fortieth year and upward, though cancer, especially sarcoma, may occur at a much younger age.

(*d*) A laryngoscopic examination may show loss of movement of one of the vocal cords.

The above symptoms are not conclusive, but they should arouse suspicion of malignancy. The practitioner may, upon the foregoing data, make a tentative diagnosis of a malignant growth in the larynx, and be right in nearly every instance.

It amounts to this: A patient forty or more years old, complaining of continued hoarseness without cough, and with sharp, sudden pains through the larynx, pharynx, or ear, should be suspected of having a malignant growth in the larynx.

What other diseases cause this symptom complex? Perhaps laryngeal tuberculosis, syphilis, perichondritis, or rheumatic laryngitis may approximately duplicate it. There are other peculiar symptoms of these diseases, however, which readily distinguish them from malignant neoplasms. In rheumatism there may be sharp pains and hoarseness, but the symptoms are fugitive; they do not persist as in malignant neoplasms. In tuberculosis and syphilis a casual examination should readily enable the practitioner to make the differentiation.

The extreme simplicity of the symptom complex of the early stage of malignant growth of the larynx encourages me to emphasize the symp-

toms, as I have, in the preceding paragraphs. I wish to urge every practitioner of medicine and surgery to indelibly impress upon his mind the few facts just given. Cancer of the larynx is not a rare disease, but, on the contrary, is quite common, more than 1500 cases being on record in 1889, and since then as many more have been diagnosticated and treated, though many have not been published. Inasmuch, therefore, as the disease is comparatively common, I desire to make plain the tentative diagnosis, and divest it of all complex considerations. It may be reduced to (*a*) age, forty years or more; (*b*) continued hoarseness without cough; and (*c*) sudden, sharp pains in the larynx, pharynx, or ears.

Etiology.—The exciting cause of malignant neoplasms of the larynx is not clearly understood. Chronic inflammation of the larynx seems to be a factor, as the statistics show that families having a history of malignant growths are more often attacked in the larynx when subject to chronic inflammations. Tobacco seems to act as an exciting cause.

Virchow tersely says that healthy tissues continually subjected to irritations may be the seat of heteroplastic growths, and that the larynx, above all other organs, where no trace of heredity or predisposition exists, is apt to be the site of malignant growths.

Age.—The age at which malignant growths of the larynx appear varies somewhat with the variety of the cancer. Sarcoma often occurs in the very young. The author had a case of sarcoma in a child eighteen months old, which pursued a very rapid course with a fatal termination. It is, however, more frequent in young adult life. Epithelioma occurs in middle adult life and in old age; carcinoma chiefly between the ages of forty and sixty.

Malignant growths of the larynx, without reference to the variety, according to the following table from Gerhardt, occur with greatest frequency between the fiftieth and sixtieth years.

	Cases.
20 to 30	4
30 to 40	18
40 to 50	49
50 to 60	76
60 to 70	30
70 to 80	10
Total	187

Schrötter observed carcinoma in a child of three and one-half years and in a girl of ten and one-half years.

Sex.—Sex influences the formation of malignant growths to a marked degree. Gerhardt found carcinoma three times as prevalent in males as in females, while Semon found them in males four times as frequently.

Social Standing.—The conditions in life seem to influence the occurrence of malignant growths of the larynx, the well-to-do being more often afflicted than the poor.

Pathology.—The pathological anatomy of laryngeal cancers is quite similar to that found in carcinoma and sarcoma elsewhere in the body, and will not be described in detail. Under Symptoms will be

found a brief characterization of malignant epithelial neoplasms, to which the reader is referred.

Symptoms.—The chief clinical symptoms: (*a*) Continued hoarseness without other known cause. (*b*) Sharp, lancinating pains in the ear and pharynx. (*c*) Forty or more years of age. (*d*) Loss of movement of the vocal cord on the affected side.

Continued hoarseness may be the only symptom for several months, the pain and the loss of movement of the cord coming on at a later period; hence, continued hoarseness, without other known cause, should, in a patient forty or more years of age, be sufficient to arouse suspicions as to the presence of a malignant growth in the larynx. While it may be said that a positive early diagnosis is difficult to make, it is, on the other hand, easy to make a provisional diagnosis and place the patient under observation so as to give him the advantage of the earliest possible diagnosis. I make a plea, therefore, with Sir Felix Semon, von Bergmann, Chevalier Jackson, Otto Stein, and others for an early diagnosis. This alone offers a reasonable hope for the successful treatment of this disease.

The hoarseness grows progressively worse, and the voice may finally become aphonic.

As the edema develops, and the growth encroaches upon the lumen of the glottis, dyspnea, of greater or less intensity, may embarrass the patient.

Cough, increasing with the progress of the disease, is usually present. The expectoration is at first similar to that in chronic laryngitis, and later is admixed with purulent secretion, and with blood in the ulcerative stage.

Dysphagia, or difficult deglutition, is a late symptom in the intrinsic variety of the disease. If, however, the primary cancer is in the pharynx or the esophagus, it may appear at a much earlier period.

The enlargement of the lymphatic glands of the neck is a late symptom, only occurring after ulceration of the tumor has taken place. Epithelioma is often attended by a very tardy enlargement of the glands. In intrinsic tumors of the larynx two sets of glands are secondarily affected—namely, the group at the angle of the jaw and those behind the sternocleidomastoid muscle. The subglottic glands of the larynx empty into those at the angle of the jaw, while the supraglottic glands empty into those posterior to the sternocleidomastoid muscle. If, therefore, the glands at the angle of the jaw are enlarged, it should arouse suspicion, at least, of a subglottic cancer (Fig. 302).

The late involvement of the lymphatic glands in intrinsic laryngeal cancer is another argument in favor of an early diagnosis, as the tumor can then be easily removed *in toto*. Should the diagnosis be made only after glandular enlargement has taken place, the operation is a much more formidable one, as it necessitates the removal of the glands. Furthermore, the probability of total resection of either tumor or glands is greatly lessened in the advanced stage of the disease, recurrence being the rule.

Laryngoscopy.—The laryngoscopic examination often presents a picture so characteristic as to at once confirm the suspicion aroused by the other symptoms present. When only one side is affected, the abductors, and possibly the adductors, are paralyzed on the affected side. Both sides are paralyzed when the entire larynx is involved.

Sir Felix Semon and Rosenback have shown that the abductor nerve fibers degenerate earlier than the adductor nerve fibers, hence the abductor muscle (crico-arytenoideus posticus) is paralyzed earlier than the adductor (crico-arytenoideus lateralis). This phenomenon is usually referred to as "Semon's law." If, therefore, the case is seen early the abductors may be paralyzed. If, however, the case is examined at a later period, the degeneration will have extended to both the abductor and the adductor nerve fibers, and the paralysis will affect both the abductor and the adductor muscles. This causes the so-called "cadaveric" position of the vocal cords.

Fig. 303

Fig. 304

Fig. 303.—Carcinoma of the right ventricular band of the larynx. It was removed by the intralaryngeal route by the author, returned in one year, was re-operated by the same route without relief, the patient dying two months later. (Author's case.)

Fig. 304.—Paralysis of the thyro-arytenoidei externi and the arytenoideus in attempted phonation, more pronounced on the left side. Drawn from author's case of subglottic carcinoma of the larynx.

By reference to Figs. 303 and 304, illustrating two of the author's cases, the laryngeal image in unilateral cancer of the larynx is shown.

The microscopic diagnosis is not always reliable, especially if the tissue is removed by the endolaryngeal route (W. J. Terry), as the cancerous growth may be deeply seated beneath the mucous membrane. If, however, the specimen for examination is removed by laryngofissure, it can be obtained from the deeper structures, and should, therefore, afford an accurate means of diagnosis. B. Fraenkel maintains that the microscopic diagnosis is of fundamental importance. Negative results should not, however, be taken as final, especially, if the specimen is obtained by the endolaryngeal route. A positive finding, however, is dependable if made by a competent pathologist. A globular collection of epithelial cells is suspicious only. Epithelial cells must be found where they do not belong. The irregular structure of the epithelium, such as is found in typical epithelial nests, is characteristic of cancer.

When the microscopic findings include the foregoing points, a positive diagnosis of cancer of the epithelial variety may be made.

Diagnosis.—Cancer of the larynx should be differentiated from (*a*) chronic laryngitis, (*b*) syphilitic laryngitis, (*c*) tuberculous laryngitis, perichondritis, and (*d*) benign neoplasms of the larynx.

(*a*) Chronic laryngitis: hoarseness, while present in both chronic laryngitis and carcinoma, is more persistent in carcinoma. In chronic laryngitis the voice is husky upon arising, but becomes clear during the day. In chronic laryngitis of the hypertrophic variety there are discrete enlargements of the mucosa, but they do not have the distinct nodular surface present in carcinoma. In chronic laryngitis the vocal cords are freely movable in both abduction and adduction, whereas, in carcinoma one or both cords are immovable.

(*b*) In syphilitic laryngitis the hoarseness is low-pitched, and brassy or raucous in character. In carcinoma of the larynx it is higher pitched, and softer in character; indeed, it may become aphonic in the later stages. The cords are freely movable in syphilitic laryngitis, and the history of the case usually clears the diagnosis.

(*c*) Tuberculous laryngitis is characterized by hoarseness and pain, and when perichondritis is present, by fixation of one or both vocal cords. The history and the examination of the sputum render the diagnosis so plain that there can be but little room to suspect malignancy.

(*d*) Benign neoplasms of the vocal cords (the most frequent site of intrinsic malignant neoplasm) are characterized by hoarseness, though pain and paralysis of the laryngeal muscles are absent.

Prognosis.—The general prognosis of malignant growths of the larynx is bad. This would not be so if an earlier diagnosis were made. In other words, the prognosis depends in a large measure upon the early recognition and surgical removal of the diseased tissue. Sir Felix Semon claims 90 per cent. of cures by thyrotomy. All, or nearly all, of his operated cases were diagnosticated and operated in the early stage, hence the high percentage of cures. Jackson, in a total of 9 complete laryngectomies, including the epiglottis, had but 1 death immediately following the operations. The others lived eight or more months after the operations.

Gluck in his first 10 cases reported 2 as cured (three years without recurrence). In his last series of 22 cases 1 died, making a percentage of recoveries higher than Semon's. Of a total of 23 complete laryngectomies he claims 3 good results. In 1903, out of 125 cases, he claimed he could show 38 living cases, the oldest still alive and in good condition thirteen years after the operation.

Of those dead, some lived eleven, eight, six and one-half, five and one-half, four and one-half, and three and one-half years. Some died of illness other than recurrence.

Kocher in 12 cases had 6 recurrences. White and Powers, after reviewing a large number of cases, conclude that in complete laryngectomies the death rate is 35 per cent., while in partial laryngectomies it is about 27 per cent.

Werckmeister collected 297 cases of complete laryngectomy, of which 36 were fatal, by which he probably means that 36 died during or soon after the operations. How many died later from recurrence is probably not shown in these figures.

In a collection of 105 cases operated by laryngofissure, 4 died of pneumonia within eight days. The low death rate from this cause stamps the procedure as safe from a surgical standpoint. The voice after laryngofissure varied with the extent of the operation. In benign tumors it usually remains fair or good. In malignant neoplasms, as they generally affect the integrity of one or both cords, it is not so good. If only one cord is involved, a useful voice is retained in simple laryngofissure and in hemilaryngectomy.

In summing up the prognosis under operative treatment, it may be said: (*a*) That in those cases diagnosticated and operated in the early stage, before ulceration and extension to the neighboring parts, the prognosis is good. (*b*) In those cases operated in the late stages the prognosis is bad. (*c*) The personality of the operator and the fortunate opportunity of seeing the cases in an early stage favor a better prognosis. (*d*) Laryngofissure gives a better chance of recovery when the disease has not extended to the extrinsic parts of the larynx. (*e*) Total laryngectomy is attended by greater shock and a higher mortality than the more limited operations. It should be remembered, however, that this method of operating is usually adopted in the more advanced and hopeless cases. (*f*) Keishaber has divided cancer of the larynx into two clinical groups, which, from the standpoint of prognosis and treatment, is important, namely: (1) Intrinsic cancer of the larynx, and (2) extrinsic cancer of the larynx. Intrinsic cancer has its origin in the vocal cords, the ventricular bands, and the ventricular pouches. Extrinsic cancer of the larynx arises from the arytenoid cartilages, the epiglottis, and other parts contiguous to the larynx. In intrinsic cancer the growth develops slowly and extends with extreme reluctance by metastasis to the lymph glands behind the sternocleidomastoid, and to the neighboring tissues surrounding the larynx.

In the extrinsic variety the reverse of the above facts is true. In other words, the prognosis in intrinsic cancer of the larynx is naturally much more favorable than it is in the extrinsic variety. To make accurate deductions from the statistics of cancer of the larynx it is necessary to know whether it is intrinsic or extrinsic, sarcomatous (for it is much more favorable in this variety) or carcinomatous; whether operated in the early, middle, or late stage; whether by laryngofissure, partial laryngectomy, hemilaryngectomy, complete laryngectomy, or by ligation and resection of the external carotid arteries and their branches as advocated by Dawbarn.

The foregoing data fairly represents the prognosis under existing methods and conditions, though I mistrust it presents it in a too favorable light.

Frank Hartly, in 1902, reviewed the literature from 1833, when Brauers performed the first thyrotomy, and the first laryngectomy by Watson

in 1878, down to the more improved methods of operating in 1900. The death rate within the first days after the operation, up to 1889, for laryngectomies was 44 per cent., and of those remaining cured for three years, prior to 1889, it was 7 per cent. Since 1889 the death rate within the first ten days has been 8.5 per cent., in those remaining cured, 15 per cent. The following tabulation shows the improvement in the immediate and the remote death rate and the net gain in the mortality:

Death rate in laryngectomies for every one hundred operations.

	Immediate deaths. Per cent.	Remote deaths. Per cent.	Total deaths. Per cent.	Living. Per cent.
Prior to 1889	44.0	52.0	96.0	4.0
1889 to 1900	8.5	47.5	56.5	44.0

The present total death rate, before the end of the third year, is 56 per cent., as against 96 per cent. prior to 1889. The tremendous improvement in the mortality rate is encouraging, and stands as the strongest argument in favor of still further improving the surgical technique for the cure of this dread disease. It should be remembered, however, that the improved mortality rate following the surgical treatment is largely due to the more intelligent selection of cases, as well as to the improved technique and asepsis now in vogue. In the period prior to 1889 the failure to elect the proper method of operating probably largely contributed to the high death rate. There is still room for improvement in this regard, and it is to be hoped that in the near future a still lessened mortuary report will be given.

Pean reports a case of extirpation of the larynx and part of the esophagus for a cancerous tumor diagnosticated by laryngoscopic examination. Although apparently limited to the left side, it was found to extend to the right side, and to the upper portion of the esophagus, the hyoid bone, and the base of the tongue. The whole mass was removed, and, to compensate for the extensive loss of substance, the esophagus was drawn up and stitched to the skin in the upper angle of the wound. The trachea with a cannula inserted in it was also secured by suture to the skin. An artificial larynx was supplied, which not only enabled the patient to swallow, but also allowed him to inhale air physiologically prepared in passing through the nose.

Pean draws the following conclusions from the case:

1. That it is impossible, prior to operation, to be certain of the extent of the disease when no subjective symptoms are present.

2. That the surgeon must never promise beforehand to limit the operation to the removal of only a part of the larynx.

3. That an extensive operation, including the removal of the hyoid bone and the base of the tongue, may be undertaken with safety and success.

4. That after such operations, important modifications of the anatomy of the parts operated on always follow, the abnormal openings of the trachea and the esophagus being raised, and the epiglottis and the root of the tongue being lowered.

5. That, thanks to suitable mechanical appliances, the functions of the parts can be, to a large extent, restored, even after the most extensive operations.

Treatment.—The various methods of treating laryngeal cancer may be appropriately studied under the following heads:

1. The endolaryngeal route.
2. Laryngofissure or thyrotomy.
3. Subhyoid pharyngotomy.
4. Partial laryngectomy or hemilaryngectomy.
5. Complete laryngectomy.
6. Ligation or injection of the external carotids and their branches.
7. Tracheotomy.

Each of the foregoing methods of treatment has its advocates and, in selected cases, its advantages. I shall endeavor to point out the most prominent indications for each in such a way as to enable the surgeon to elect the one best suited to the case in hand.

1. **The Endolaryngeal Operation.**—The endolaryngeal operation for cancer of the larynx is not unlike that described for papilloma of the larynx (pp. 521 and 522). The responsibility attending it is, of course, much greater on account of the gravity of the disease. The most distinguished advocate of this method of operating is B. Fraenkel, who cured three cases by operating on them by the endolaryngeal route at intervals covering a period of five years. At the time of his published report there had been no recurrence after two years of quiescence. I have operated on a few cases by this method, in 1 of which there was recurrence in ten months, with pronounced hoarseness, dyspnea, pain and cachexia. The second operation did not relieve him as did the first. He gradually grew worse, and died two months after the second operation. The second operation was performed twelve months after the first. The case (Fig. 303) should have been subjected to hemilaryngectomy or complete laryngectomy at the time of the first operation, notwithstanding the fact that the tumor was apparently accessible to the double cutting forceps *via* the mouth. It is quite probable that I did not succeed in removing all the cancerous tissue, which I could have done had I resorted to an operation by the external route. Notwithstanding the brilliant results reported by B. Fraenkel, I think the endolaryngeal operation should rarely be the operation of choice. It may be chosen when other methods are refused. Direct laryngoscopy promises better results than are obtained by the indirect method. Laryngofissure may be performed, a pathologist being present to make an examination of the specimen by the freezing method, which only requires a few minutes. In Figs. 305 and 306 is shown the author's cases of pedunculated carcinoma of the larynx. This is a rare condition, and I know of only two similar cases on record (B. Fraenkel). The glands of the neck were large and firm. A gland was first removed and submitted to microscopic examination and carcinoma was reported. The laryngeal neoplasm was then removed with a snare. As the patient swallowed the growth, warm salted water was given and the tumor ejected. The patient, aged forty-five years,

died eighteen months later, metastatic carcinomata being found post-mortem in the liver, spleen, and stomach.

The operation may then be completed by the method thought best in view of the macroscopic and microscopic findings. The precise location and extent of the growth, whether intrinsic or extrinsic, should also be determined after the larynx is opened by laryngofissure.

In order to render the thorough examination of the parts through the laryngofissure possible, the interior of the larynx should be brushed or sprayed with a 5 per cent. solution of cocaine to abolish the reflexes. Adrenalin, 1 to 1000, may be used to shrink the mucous membrane, and thus bring the limitations of the growth into greater prominence.

FIG. 305

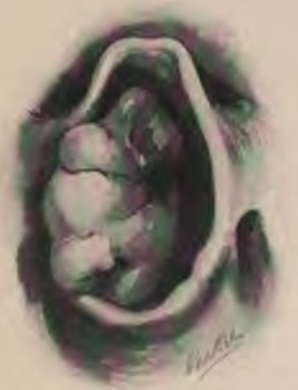

FIG. 306

FIG. 305.—The author's case of pedunculated carcinoma of the larynx growing from the left ventricular band. The tumor was distinctly movable. It was removed with a cold-wire snare through the mouth. The patient swallowed it, was given warm salt solution, after which he ejected it, and the rare specimen was thus preserved. A gland was previously removed from the corresponding side of the neck, and upon microscopic examination by the Columbus laboratories it was pronounced carcinoma. The laryngeal tumor was likewise submitted and pronounced carcinoma. Peculiar interest attends the case on account of the distinct segregation of the tumor from the surrounding tissues and its pedicle attachment.

FIG. 306.—View of the inferior surface of the author's case of pedunculated carcinoma of the larynx in a man aged forty-five years. The peduncle was tubular and composed of mucous membrane, and was attached to the ventricular band of the left side. The tumor was freely movable in the larynx, occasionally obstructing the breathing. The tumor presented the appearance of a gland dislocated beneath the mucous membrane.

2. **Laryngofissure or Thyrotomy.**—This operation is one that should be chosen more often for obtaining a specimen for examination and for the removal of cancerous and benign growths.

The indications: (*a*) For the removal of foreign bodies lodged in the ventricular pouch which cannot be removed by either the direct or indirect endolaryngeal route.

(*b*) For the removal of benign neoplasms which cannot be reached successfully by the endolaryngeal route.

(*c*) To obtain a specimen from a suspected malignant neoplasm of the larynx, for microscopic examination, especially when the one removed by the endolaryngeal route gives a negative result.

(*d*) To expose the interior of the larynx to view in order to determine the gross appearance, site, and extent of a laryngeal neoplasm, preliminary to the election of the method of removal.

(*e*) As a method of election for the removal of an intrinsic malignant growth of the larynx.

When should laryngofissure be the method of choice or election in malignant neoplasms?

(*f*) When, upon laryngoscopic examination, the growth is found to be limited to the soft parts or to a small area, and can be removed through the laryngofissure, with the sacrifice of but little or none of the cartilaginous framework of the larynx.

(*g*) When, upon laryngoscopic examination, the growth, while somewhat extensive, does not appear to involve the deeper tissues, and can in all probability be entirely removed by laryngofissure.

(*h*) When the growth is somewhat more extensive than in (*f*) and (*g*), but is still circumscribed within a fractional part or one-half of the larynx, having its origin from one cord, or the ventricular pouch or band, is not ulcerated, and there is no enlargement of the glands posterior to the sternocleidomastoid muscle.

(*i*) When the growth is intrinsic, the vocal cord, the ventricular pouch, or the ventricular band, even though it is quite large, and the lymphatic glands posterior to the sternocleidomastoid muscle are not enlarged, it is barely possible that operation by laryngofissure may be successfully done. If the growth has involved the cartilaginous framework of the larynx to such an extent as to necessitate the removal of a considerable portion of it on one side, laryngofissure should not be the method of choice. Hemilaryngectomy or incomplete laryngectomy should be chosen after a preliminary laryngofissure.

Axiom: Laryngofissure should be the operation of choice when the malignant neoplasm is intrinsic, and when diagnosticated in the early stage.

Laryngofissure or thyrotomy has been frequently referred to as a method of removing growths, foreign bodies, and obstructive lesions of the larynx. It will be described in this connection and cross-reference made to it wherever the author thinks it is the proper procedure for other affections.

Technique.—The operation consists in splitting the larynx in the anterior median line and removing the growth through the fissure thus made. It is not a formidable procedure, and should be done much oftener than it is.

(*a*) The preparation of the patient: In this, as in all cases where a general anesthetic is to be administered, the patient should be placed in a hospital twenty-four to forty-eight hours before the time of operation. Broken doses of calomel, followed by a saline cathartic the following morning, should be administered in time to produce a free evacuation of the bowels a few hours before the operation. The patient should be given no food within nine hours of the operation.

(*b*) The preparation of the field of operation: The neck should be

scrubbed and shaved twelve hours prior to the operation, and a moist carbolic dressing placed over the laryngeal region and held in position with a bandage. The scrubbing should be repeated after the patient is under the influence of the anesthetic.

(*c*) Anesthesia: Rectal anesthesia, as practised by Cunningham, of Boston, and Stucky, of Lexington, is performed by the administration of the vapor of ether with Cunningham's apparatus. It combines simplicity and safety, a small amount of ether being used, and there is no nausea and vomiting following its administration. The method is especially useful in operations about the head, as the anesthetist is removed from the field of operation. In throat operations it is especially recommended, as the anesthesia may be administered throughout the operation and the secretions are not stimulated by its administration.

Fig. 307

The line of incision for the complete or partial removal of the larynx.

(*d*) The cutaneous incision: The incision should be made in the anterior median line, and should extend from the os hyoides above to the ensiform cartilage below (Fig. 307). There are but few structures of importance encountered in this region, excepting a small amount of areolar tissue and the anastomosis of the inferior laryngeal arteries in the median line. These arteries are encountered at either the inferior border of the thyroid cartilage or the superior border of the cricoid cartilage, hence it may not be necessary to cut them, as they can be pushed aside. There are no serious objections to severing them, but if this is done it is better to locate them and tie them off with absorbable catgut on either side of the median line before dividing them. The venous oozing may be controlled by pressure, or, if too profuse, the venous trunks should be ligated.

(*d*) The incision of the thyroid cartilage: This should be done in the median line with knife or scissors (Fig. 308). The knife is preferable unless the cartilage has become ossified, as the dissection can be carried to the mucous membrane without cutting it. This is important, as the incision through the membrane at the anterior commissure of the glottis should be exactly in the median line. If it is not, one of the cords will be injured.

(*e*) The incision through the mucous membrane: First locate the median line at the anterior commissure. If in doubt, begin the incision at the upper limit of the wound, and cut downward to the anterior commissure. The knife should then be inserted through the incision and between the cords, and the incision at the commissure made from within

outward. In this way the cords will not be injured. The incision is then extended to the lower limit of the thyroid cartilage.

(*f*) The larynx should then be opened by retracting the two thyroid cartilages from the median line (Fig. 309). This is done by the assistants with retractors.

FIG. 308

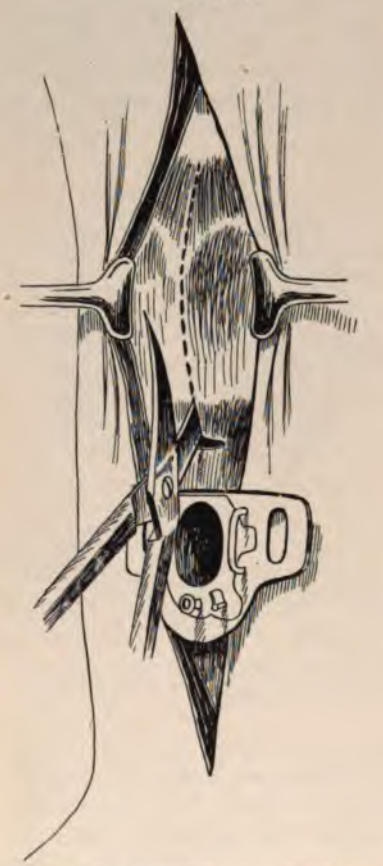

FIG. 309

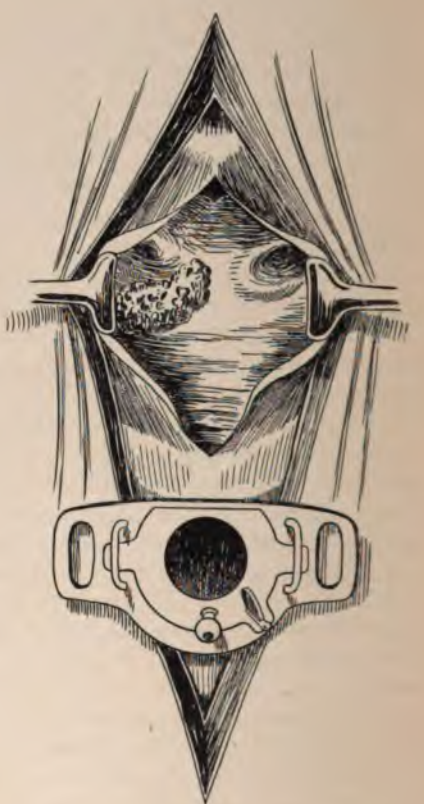

FIG. 308.—Laryngofissure. Tracheotomy has been performed, a cross-puncture at the lower border of the thyroid made, and the scissors blade introduced through it preparatory to making the incision through the anterior commissure of the thyroid cartilages. (After Moure.)

FIG. 309.—Laryngofissure (thyrotomy) completed, the tumor exposed ready for removal. (After Moure.)

(*g*) The removal of the growth: Having completed the laryngofissure, and having separated the incised thyroid cartilages, the location and character of the growth should be studied. The growth may be removed through the laryngofissure with a snare, scissors, or knife. The better surgical procedure is with the knife or scissors, as with either of these instruments the scope of the operation is entirely under the control of the operator, whereas with the snare the depth of the cut cannot be accurately controlled.

(*h*) Hemorrhage: The hemorrhage in the preliminary part of the operation, *i. e.*, the laryngofissure, is comparatively slight, as it is controlled by pressure and ligatures as the bleeding points appear. In the removal of the growth, however, there may be considerable hemorrhage both during and after the operation. This is easily controlled with artery forceps or with the actual cautery applied to the bleeding areas. The hemorrhage occurring after the patient becomes conscious is expectorated, and causes little or no trouble. During the operation the patient's head should hang over the end of the table, the table also being lowered at the head end, to prevent the blood being aspirated into the lungs.

(*i*) The closure of the laryngofissure: Having removed the neoplasm (or foreign body), the thyroid cartilages are reunited with an absorbable ligature. The coaptation of the cut edges of the cartilages should be carefully done. If, for instance, one side is higher than the other the vocal cords at the anterior commissure will not approximate on the same level, and vocalization will be somewhat modified.

(*j*) The closure of the cutaneous wound: This should be done with simple sutures about one-fourth of an inch apart, and the whole covered with plain sterile gauze. At the end of from three to six days the stitches should be removed. At this time the wound should be thoroughly healed, little additional attention being required.

3. **Subhyoid Pharyngotomy.**—Subhyoid pharyngotomy for the removal of malignant neoplasms of the larynx is rarely used. There are cases, however, when it should be elected for this purpose in preference to any other method.

The indications: The indications for subhyoid pharyngotomy are few, and are chiefly in connection with extrinsic malignant neoplasms of the larynx, and in cases complicated by extension to or by origin in the pharynx. They are as follows.

(*a*) When the growth is situated in the epiglottis or other of the higher portions of the larynx, and which for any reason cannot be thoroughly removed by the endolaryngeal route.

(*b*) When the growth is situated in the upper portion of the larynx and has extended to the pharyngeal wall.

(*c*) When the malignant growth begins in the pharynx and extends to the supraglottic (extrinsic) portion of the larynx.

Technique.—(*a*) Place the patient under chloroform or ether anesthesia per the rectum or mouth after the usual preliminary preparations.

(*b*) Prepare the neck and face by scrubbing, etc.

(*c*) Elevate the shoulders of the patient by placing a sand pillow under them, and draw the head well backward so as to bring the hyoid region into easy access. Also elevate the foot of the operating table to prevent blood and secretions entering the trachea while the reflexes are abolished by the anesthetic.

(*d*) Make a transverse incision through the skin after Kocher's method, beginning about ½ inch below the inferior border of the hyoid bone, extending it from the anterior border of the sternocleidomastoid muscle to the corresponding point on the opposite side of the neck.

The incision should be from 2½ to 3 inches in length. Then make a perpendicular incision in the median line, beginning above at the transverse incision, and extending downward to the prominence of the thyroid cartilage.

(*e*) Divide the superficial fascia, in which the anterior jugular vein is found. The jugular vein should be ligated in two places on each side of the neck and severed between the ligatures.

(*f*) Sever all the muscles, including the sternohyoid, on either side of the median line, and just beneath them, the thyrohyoid muscles thus exposing the thyrohyoid membrane to view.

(*g*) With the finger applied to the membrane explore for the epiglottis, so as to avoid injuring it in the next step of the operation.

(*h*) Incise the thyrohyoid membrane, thus exposing the diseased area to inspection.

(*i*) Carefully inspect the deeper field, beginning at the anterior surface of the epiglottis, for evidences of malignant growth.

(*j*) Seize the epiglottis with toothed forceps, and gently draw it outward through the wound, securing it with either a suture through its tip or with locked forceps.

(*k*) Traction upon the epiglottis opens the wound and exposes the deeper parts to view.

(*l*) Through the opening all diseased tissue is removed with scissors, knives, and double cutting forceps, some of the surrounding healthy tissue being also included.

(*m*) The wound is now closed by suturing the thyrohyoid membrane, the muscles, and the superficial fascia with absorbable catgut, and the skin with non-absorbable ligatures.

(*n*) The external wound should be dusted with iodoform 1 part and boric acid 4 parts, and a gauze dressing applied.

(*o*) The dressing should be removed in three to five days and renewed. The stitches in the skin should be removed on about the fifth or sixth day.

(*p*) At the end of ten or twelve days the patient should be up and able to leave the hospital.

4. **Partial Laryngectomy.**—This operation is often spoken of in literature as synonymous with laryngofissure, which is but the preliminary step in partial and hemilaryngectomy. Partial laryngectomy is a more extensive operation than simple laryngofissure. In laryngofissure only the soft parts and the growth are removed, whereas in partial laryngectomy a portion of the cartilaginous framework is removed with the growth.

Indications.—The indications for partial laryngectomy are somewhat different from those for laryngofissure. For example, it is not indicated for the removal of foreign bodies in the larynx, benign neoplasms, or in cancerous growths which only involve the soft structures. The following are the chief indications:

(*a*) In malignant growths seeming to be limited to the soft parts on one side of the larynx, and in which it is suspected the cartilage is also involved, a partial laryngectomy may be done.

(*b*) In malignant growths limited to one side, and which involve a portion of the cartilaginous framework of the larynx. The removal of the growth and the portion of the cartilage involved is regarded as sufficient to obliterate all traces of the growth. If partial laryngectomy will not obliterate the growth, complete laryngectomy should be performed.

(*c*) If, for any reason, there is a suspicion of involvement of the deeper structures, partial laryngectomy is indicated.

Technique.—The technique is so little different from that given in laryngofissure that a detailed description is unnecessary. The chief difference consists in the removal of the affected portion of the cartilaginous framework in addition to the procedures practised in laryngofissure, in which only soft tissues are removed. The additional fact that partial laryngectomy is usually indicated in extrinsic cancers also implies a more serious condition, with earlier glandular involvement. Hence, the anxiety and desire to be certain to include all the diseased tissue, even at the expense of some healthy tissue.

5. **Complete Laryngectomy.**—The removal of the larynx is a formidable and sad procedure. The death rate in the hands of the average operator is high. The condition of the patient, should he recover from the operation, is often pitiable indeed, though this fact does not always appear in the published reports. However, from the patient's point of view he would rather be alive without his larynx than dead with it. Complete laryngectomy may, therefore, be done when simple and less radical measures hold out little or no hope of success.

Indications.—In a general way it may be said that the total removal of the larynx is indicated in those cases in which the disease involves a large portion of the structures, soft and cartilaginous, in both lateral halves of the larynx. It may also be indicated when one side is involved in its entirety and there is a strong suspicion that it has also invaded the opposite side. The following classification fairly represents the chief indications for complete laryngectomy:

(*a*) The involvement of one-half of the larynx, with a strong suspicion that it has invaded the opposite side, the glands of the neck not being involved.

(*b*) The involvement of both sides of the larynx, especially if the cartilaginous framework is included in the process, the glands of the neck not being involved.

(*c*) The involvement of the extrinsic areas of the larynx on both sides. If the intrinsic portions only, as the vocal cords, are invaded by the cancerous growth, it might be successfully operated by laryngofissure.

(*d*) The involvement of the extrinsic portions of the larynx on both sides, together with the contiguous tissues, as the pharynx, calls for the total extirpation of the larynx together with the other structures that are cancerous.

(*e*) When both sides are extrinsically more or less involved, together with the glands of the neck, total laryngectomy and the ablation of all the lymphatic glands on both sides of the neck are indicated, though a fatal result will probably follow.

Technique.—The method of W. W. Keen is probably the simplest, safest, and most thorough yet devised, and is the one used by me. It is given in the following analysis:

(*a*) The preparation of the patient for the operation bears an important relation to the success or failure of the surgical procedure If the patient's general health is bad the prognosis is correspondingly bad. It is essential, therefore, that the general condition of the patient be improved by a short course of forced feeding and tonic remedies. The operation should be performed in the morning, when the vital forces are at their best. On the evening prior to the operation a

Fig. 310

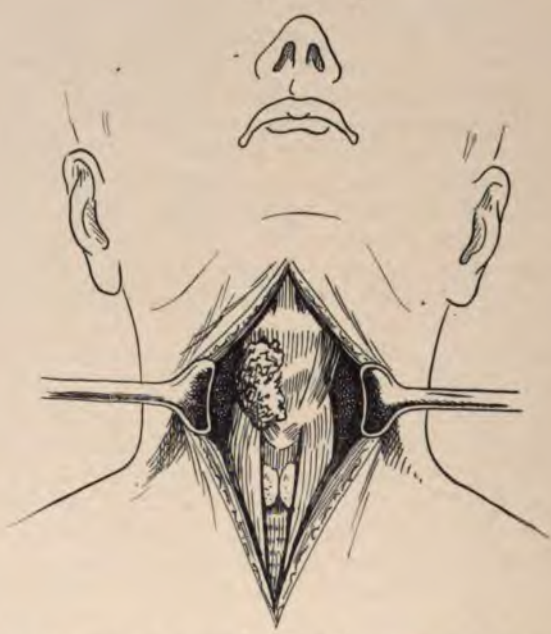

The superficial soft tissues dissected from the larynx preparatory to the complete removal of the carcinomatous larynx. The remaining soft tissues should be dissected from the larynx before separating the posterior wall of the larynx from the esophagus.

cathartic should be given, and, if necessary, a saline given early the following morning. The face (adult male) and neck should be shaved and scrubbed the day before the operation, and a moist carbolic acid dressing applied.

(*b*) On the following morning the patient should be placed upon the operating table in the Trendelenburg position, with the foot of the table raised to prevent the aspiration of blood into the trachea. The patient should be kept in this position throughout the operation, and for three days after it.

(*c*) Ether vapor, per rectum, as recommended by Cunningham and

PLATE VIII

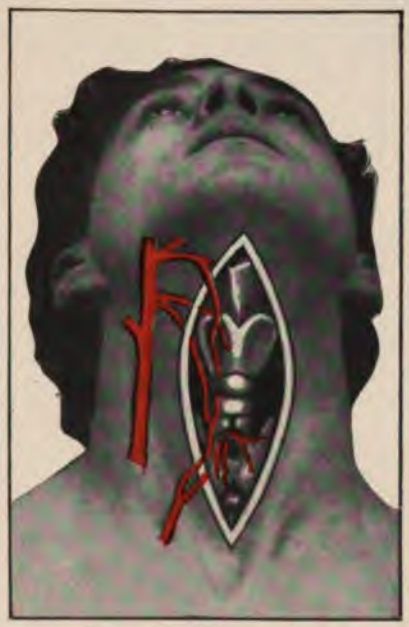

Arteries of the Larynx. The Superior Laryngeal and the Inferior Laryngeal arteries, branches of the superior and inferior thyroid arteries, respectively, supply the walls, glands, muscles, and mucous membrane of the larynx.

Stucky, is, perhaps, the best method of inducing anesthesia, as the anesthetist and his apparatus (Cunningham's) are removed from the field of operation.

The anesthetic may be administered by the mouth or the tracheotomy tube (in case a preliminary tracheotomy has been performed), or, if tracheotomy is performed during the operation, it may be given by the mouth until tracheotomy is performed, and then through the tracheotomy tube.

If tracheotomy is not done either before or during the operation, the anesthetic may be given by mouth until the trachea is severed from the cricoid cartilage, and then through the stump of the trachea.

(*d*) The incision should be made in the median line, beginning at the hyoids and extending downward to the ensiform cartilage (Fig. 307).

Fig. 311

Fig. 312

Fig. 311.—Carcinoma of the larynx removed by complete laryngectomy. Posterior view. (Author's case.)

Fig. 312.—Carcinoma involving all of one and part of the other half of the larynx. Complete laryngectomy was performed by the author by Keen's method without tracheotomy. Anterior view. (Author's case.)

The only vessels of any consequence encountered are the superior and inferior laryngeal arteries and their branches. The arteries and veins should be ligated as they are exposed (Plate VIII). The venous hemorrhage may be controlled by pressure, or the larger trunks may be tied.

(*e*) Separate the soft structures (Fig. 310), including the muscles in the median line, and dissect them from the larynx down to the esophagus on the posterior wall of the larynx.

(*f*) Introduce a heavy anchor suture between the first and second cartilaginous rings of the trachea on either side, and pass one end of the suture through the adjacent skin, as shown in Fig. 313. This is done to prevent the trachea dropping into the mediastinum when it is severed from the larynx.

(*g*) Tie the anchor sutures described in the preceding paragraph, and sever the trachea from the cricoid ring of the larynx with a sharp scalpel. If the anesthetic has been given by the mouth, it should be transferred to the trachea.[1]

(*h*) Dissect the posterior wall of the larynx from the esophagus with the finger or blunt instrument, as shown in Fig. 313. This is often a

Fig. 313

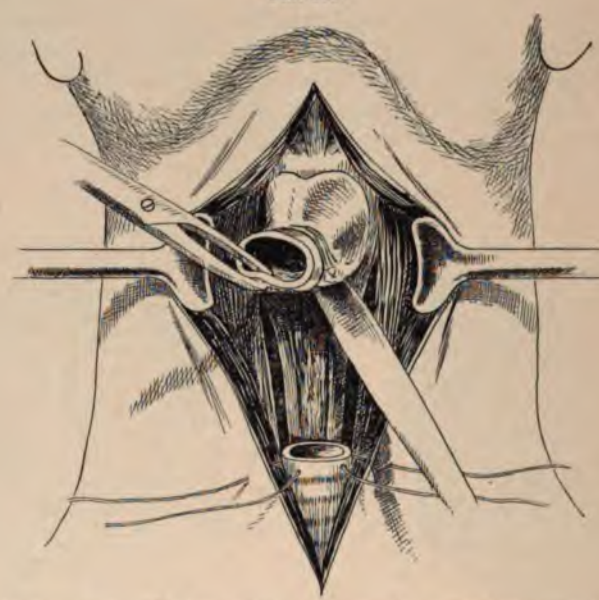

Complete laryngectomy. The larynx has been severed from the trachea at the junction of the first ring and the cricoid cartilage. The larynx is being separated from the anterior wall of the esophagus by blunt dissection.

difficult task, as the adhesions are firm. Every effort should be made to avoid tearing the wall of the esophagus, as it is difficult to repair it by suture.

(*i*) Having separated the esophagus from the larynx as high as the arytenoid cartilages, it should be severed from the larynx by transverse incision (Fig. 315).

(*j*) The only attachment remaining is the thyrohyoid membrane in

[1] In this description it is presumed that the removal of the larynx is done without tracheotomy either prior to or during the operation, as suggested by Dr. W. W. Keen. I performed the operation in this manner in August, 1905, with satisfaction. The larynx and carcinoma thus removed are shown in Figs. 311 and 312. The patient died six days after the operation from exhaustion. He rallied after the operation, progressed very favorably for five days, took food per rectum for four days, and by mouth for one. He was then unable to retain food on his stomach. Rectal feeding was again tried, but was not retained. Death occurred the following day. The patient was fifty years old, and had been a heavy whisky drinker for twenty-five years. The carcinoma was extrinsic and large, and while chiefly limited to the right half of the larynx, it had extended to the left side of the epiglottis. There was no enlargement of the glands of the neck. Only one enlarged lymphatic gland was found, and that was in the glosso-epiglottic space.

front. This should also be severed by a transverse incision (Fig. 315). The larynx and the neoplasm are thus extirpated, leaving the pharynx open in front.

(*k*) The lower pharyngeal membrane should now be sutured to the thyrohyoid membrane below the hyoid bone, as shown in Fig. 315, thus closing the wound in the anterior wall of the pharynx.

(*l*) The soft tissues should be brought together in the median line by buried absorbable catgut sutures.

(*m*) The stump of the trachea should be securely sutured to the skin, as the breathing must in future be carried on through it.

(*n*) The skin should be closed by sutures except around the stump of the trachea, as shown in Fig. 316.

FIG. 314

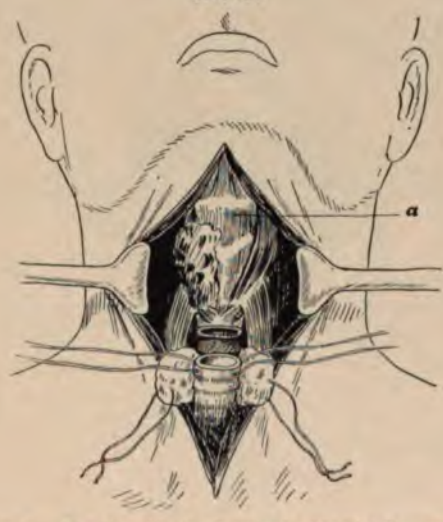

Complete laryngectomy. The thyroid glands turned aside with ligatures through them. The trachea severed below the cricoid cartilage preparatory to dissecting the larynx from the esophagus and other deep soft tissues. Anchor sutures passed through the upper ring of the trachea to prevent the trachea dropping into the mediastinum. *a*, thyrohyoid membrane.

(*o*) A dressing should be applied over the line of skin sutures. A thin dressing of gauze should be placed over the tracheal stump to filter the air inspired through it. This portion of the dressing should be frequently changed, as it becomes soiled by the secretions coughed out through the trachea.

After-treatment.—Keep the foot of the bed elevated a foot or more for three days, to favor the drainage of the trachea, or until the patient can take food by the mouth. Sustain the patient by rectal feeding at intervals of three or four hours for four days. At the end of this time the pharyngeal wound is usually united, and food may be given by mouth. In from twelve to fourteen days the patient should be able to leave the hospital, if he is not dead.

Axioms.—1. Early diagnosis and an early operation in laryngeal cancer means a probable cure.

2. An early provisional diagnosis of cancer may be made if three clinical facts are borne in mind, namely, a patient forty or more years old, complaining of continued hoarseness without cough, with sudden sharp pains in the larynx, pharynx, or ears.

3. The operation of choice should be the one that will ensure the complete removal of malignant tumor with the least destruction of normal healthy tissue and the least damage to function of the larynx.

Fig. 315

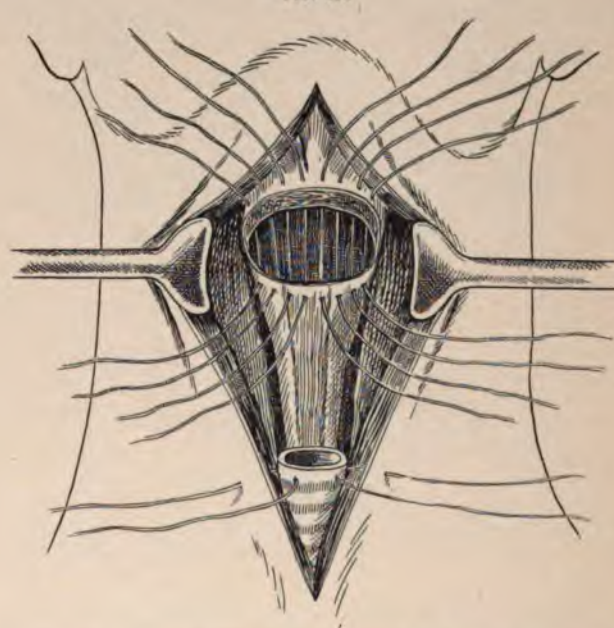

Complete laryngectomy. The larynx has been removed, leaving an opening in the anterior wall of the pharynx. The sutures are in position ready to close the wound.

4. Intrinsic cancer of the larynx is successfully operated by laryngofissure, a simple and comparatively safe method.

5. Complete removal of the larynx is a formidable and dangerous operation, only suited to extensive involvement of the soft and the cartilaginous portions of the larynx in both lateral halves.

6. Extensive involvement of the larynx and of the adjacent structures means certain death without an operation, and probable death with an operation.

7. If the diagnosis of cancer of the larynx is only made at an advanced stage, the physician is guilty of "ignorance," when it is easy to be "wise."

Postoperative Considerations.—The surgeon's responsibilities are by no means ended when the operation is completed. There are several

conditions present or liable to arise that demand his thoughtful attention. Among them are the following:

1. *Shock and Sudden Death.*—Stoerk attributes death by shock to the severing of the fibers of the inhibitory cardiac branches of the pneumogastric nerve. They are given off, and pass forward to the larynx, thence downward back of the trachea, where they are liable to injury in separating the esophagus from the larynx and the trachea. It is, therefore, well to keep close to the posterior wall of the trachea, and to avoid undue manipulation and traumatism in making the separation.

Crile, by experimentations upon lower animals, arrives at the conclusion that sudden death in laryngectomy and intubation, is due to an irritation of the middle and the upper portion of the larynx, the irritation

Fig. 316

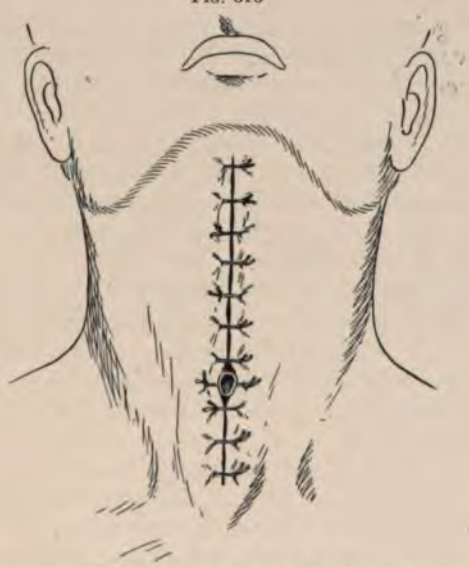

The incision after complete laryngectomy. The end of the trachea is sutured to the skin.

exciting a reflex inhibition of the cardiac branches of the pneumogastric nerve. He therefore recommends a preliminary incision through the cricoid membrane, through which the interior of the larynx may be brushed with a 5 per cent. solution of cocaine. After that is done the operation of election is continued. He also suggests that an injection of atropine helps to prevent the reflex influence upon the heart. He makes the following distinctions between asphyxia and reflex action on the respiratory organs and the heart:

(*a*) In asphyxia there are more or less violent efforts at breathing, the heart momentarily beating stronger; whereas,

(*b*) In reflex disturbances the breathing stops suddenly and the heart immediately becomes weak.

The above distinctions are peculiarly applicable to impending death

during intubation in diphtheria and pseudomembranous croup. During intubation the patient is suddenly asphyxiated, or is thrown into a state of shock, the characteristics of each being given in the above paragraph.

Treatment of Cardiac Reflexes.—(*a*) Instantly lower the head without further manipulation of the larynx.

(*b*) Slap the chest with a cold wet towel, then immediately dry the surface and repeat the cold applications.

(*c*) Artificial respiration should, in the meantime, be kept up.

Treatment of Asphyxia.—(*a*) Remove the intubation tube or the obstruction to the larynx and clear it of membrane.

(*b*) The patient will then, in all probability, cough out more membrane or obstructing secretions, thus clearing the lumen of the trachea.

(*c*) Re-introduce the cannula (in diphtheria), and no further trouble will likely occur.

While the foregoing remarks upon shock and sudden death do not, in all respects, have a direct bearing upon the operation for cancer of the larynx, they nevertheless have an indirect relationship, and may prove of value in the study of this subject.

2. *Inspiration pneumonia* is a common sequel of the operative treatment of laryngeal cancer, and is a frequent cause of death. In laryngofissure, one of the simplest external laryngeal operations, the death rate is about 4 per cent. In complete laryngectomy the mortality from pneumonia alone is much greater.

3. *Rectal Alimentation.*—After complete laryngectomy the patient should be sustained by rectal alimentation for three or four days, after which he may be given food by the mouth. In the simple operations the rectal feeding may be discontinued somewhat earlier, proportionate to the extent of the operation. Indeed, in simple laryngofissure it may be dispensed with altogether.

4. *The Voice.*—After laryngeal operations the voice may be good, provided the cords are not greatly damaged in the removal of the growth or the larynx is not removed in its entirety. If the tumor arises from the cords, and has penetrated deeply into their substance, they are necessarily removed, and the voice is consequently weak and otherwise impaired. After laryngofissure for laryngeal cancer the voice is usually more or less impaired, while in benign growths it is usually very good. After hemilaryngectomy and partial laryngectomy, one cord remains, and gives a husky though useful voice. In complete laryngectomy, when the trachea is stitched to the skin, there is no voice except in rare cases, where the tissues around the tracheal opening are thrown into vibration. When the trachea is stitched to the pharyngeal wound there may be more or less voice, or what passes for it. This is obtained by the peculiar conformation of the parts after the healing process is complete. The larynx being removed, the base of the tongue drops backward and downward, approximating the posterior wall of the pharynx. The cavity below the base of the tongue forms an air chamber, which is utilized to force air through the constriction formed by the base of the tongue and the pharyngeal walls, thus throwing the tissues at this point

into vibration. The union of the trachea to the pharyngeal wound is not often practised, as the tension is so great that the tissues tear apart, slough away, or undergo gangrenous degeneration..

5. *Recurrence.*—Recurrence of the cancerous growth is common on account of failure to make an early diagnosis. Intrinsic growths are less malignant than the extrinsic, hence recurrence in this variety is not so common.

It may be said, then, that recurrence of laryngeal cancer is largely dependent upon the following factors:

(*a*) Intrinsic cancers of the larynx do not recur as frequently as the extrinsic.

(*b*) Conversely, extrinsic cancers more often recur than the intrinsic.

(*c*) Extralaryngeal cancers, involving the larynx, have a still greater tendency to recurrence.

(*d*) An early diagnosis and operation by laryngofissure, in intrinsic cancer of the larynx, should give a death rate of only 10 per cent., 5 of the 10 dying of pneumonia rather than of recurrence.

(*e*) Complete laryngectomy in cancer of the larynx was, up to 1889, attended by a death rate of 44 per cent., but since antiseptic surgery and an improved technique have been attained, it is reduced to about 15 per cent. When I speak of a death rate of 15 per cent., I mean death within three years after the operation. Quite a number die within a few months from pneumonia, septicemia, gangrene, exhaustion, or other sequelæ. In still others recurrence brings on a fatal issue.

CHAPTER XXXI.

FOREIGN BODIES IN THE LARYNX, TRACHEA, BRONCHI, AND ESOPHAGUS.

Etiology.—The lodgement of foreign bodies in the air passages is most common in infants and young children, as they have an instinctive desire to test all substances with their mouths. Coughing, laughing, crying, and ineffectual attempts to swallow draw the foreign body into the lower air tract. The smaller caliber of the larynx and air tubes in infants and young children renders the liability to the lodgement of foreign bodies greater. The smaller size of the larynx and air tubes in infants and young children renders the obstruction greater than in older subjects from the same foreign bodies, hence the danger is often correspondingly greater in young subjects.

The nature of the foreign bodies ranges anywhere from particles of food to marbles, coins, safety pins, burrs, and false teeth.

Symptoms.—The symptoms of a foreign body in the respiratory passages are those of obstructed breathing, laryngeal, tracheal, bronchial, or pulmonary irritation, and inflammation. The patient is suddenly seized with a violent choking and suffocative attack, characterized by cyanosis, aphonia, beads of perspiration on the forehead, and a weak pulse. These symptoms usually subside within a few minutes, to return again in a few hours or days. After the foreign body remains in the larynx for several weeks the spasmodic symptoms cease and the cough, etc., become more constant, often leading to a diagnosis of tuberculosis. A negative finding upon examination of the sputum clears the suspicion as to tuberculosis A positive finding does not, however, exclude a foreign body. A history of spasmodic cough and dyspnea and hoarseness followed by a persistent cough should excite suspicion of a foreign body in the respiratory tract if the patient is a small child. If the foreign body lodges in the ventricle of the larynx or in the subglottic space, hoarseness or aphonia is usually present. When the foreign substance changes its position, or an accumulated irritation arises, new suffocative attacks are excited. If the foreign body lodges in the trachea, bronchus, or one of the bronchioles, the voice remains clear. Bronchial rales or pneumonia may subsequently develop. In some instances the movements of the foreign body when in the bronchus may be detected by auscultation (Halstead). Dyspnea, attended by an elevation of temperature, often leads to an erroneous diagnosis of tracheal diphtheria. A laryngoscopic examination may not reveal the foreign body, even though it lodged in the ventricle of the larynx. By direct laryngoscopy (Fig. 324), a better view of the larynx may be obtained. To Gustav

Killian belongs the credit of devising an apparatus whereby almost all of the respiratory tract may be clearly inspected for foreign bodies.

Indications.—The indications are to remove the foreign body as soon as possible, as it may become dislodged and migrate to a new and more dangerous location. The continued presence of the foreign body may also give rise to considerable local irritation and subsequent edema or septic inflammation. Pneumonia is a rather frequent complication. In prolonged cases serious septic absorption may occur. Cases are recorded wherein the foreign body remained in the air passages for years without causing death. It should not be deduced from this fact that the early removal of the foreign body is not desirable. The risks attending its continued presence in the air passages are infinitely greater than those incident to its early removal.

The indications are, therefore, to institute proceedings for its removal, either by (*a*) holding the child's head downward and thumping it on the back (a dangerous procedure), the surgeon being prepared to perform a tracheotomy should suffocative symptoms supervene; (*b*) the titillation of the larynx with the finger, in the hope of dislodging the foreign body or of exciting a coughing spasm, during which it may be expelled (a dangerous procedure); (*c*) the direct removal with instruments by the aid of a laryngoscopic mirror; (*d*) tracheotomy to relieve the suffocative dyspnea; if cyanosis is marked, tracheotomy may also be done to establish a new avenue of inspection and to establish a new avenue for the instrumental removal of the foreign body; (*e*) and, finally, the indications are to use the Röntgen rays. If the foreign body is metallic or a bony substance, its location is easily shown, whereas if of vegetable matter it is less easily shown on a skiagraphic plate.

Having located the foreign body, practice bronchoscopy or tracheoscopy and remove it with suitable instruments, by either upper or lower bronchoscopy, upper bronchoscopy being preferable when practicable.

Treatment.—It is generally understood among the laity that pounding a child on the back, especially when held head downward, will often dislodge a foreign body from the respiratory tract. These procedures have, therefore, usually been performed before a physician is called, provided it is known that a foreign body has been inhaled. Even though the foreign body is not thus removed, the suffocative symptoms often subside within a few minutes and the incident is often forgotten. When the symptoms recur a few hours or days later, without the marked strangulation and coughing seizures characterizing the initial attack, the family often sees no connection between this attack, and fails to report the occurrence of the first one to the attending physician. If the foreign body assumes a new location, the violent spasmodic seizures are repeated.

If suffocation is imminent, tracheotomy should be performed at once, for, as Chevalier Jackson says, if this is not done the child may never breathe again. When this is done the breathing is immediately relieved, provided the foreign body is in the larynx. If it is in the trachea or bronchus, it may not relieve the distress unless the foreign body is expelled through the tracheal wound. As a matter of fact, it is frequently thus

expelled the moment the edges of the severed tracheal rings are retracted. If it is not voluntarily expelled, the lining mucous membrane of the trachea should be titillated, a procedure that sometimes causes its expulsion. Having performed tracheotomy, which is not attended by voluntary expulsion of the foreign body, proceed to pass a probe upward through the tracheal wound into the larynx, to locate it if it is there. If lodged in the ventricular pouch or in the subglottic space, its location is not difficult. Having located it, introduce slender forceps, seize it, and remove it through the tracheal wound.

If the foreign body is lodged in the trachea at its bifurcation, it may be easily seen through a tracheoscopic tube introduced through the tracheotomy wound (Plate IX). For illumination a Kierstein head lamp (Fig. 317) or a small electric lamp at the distal end of the tube, as

Fig. 317

Kierstein's lamp.

devised by Jackson (Fig. 318), may be used. If a Killian or Jackson tube is not available, the foreign body may be detected with a probe introduced through the wound, after which slender forceps may be introduced through the wound without a tracheoscope for its removal. This method is inexact and crude, and should only be used as an emergency measure.

If the foreign body is in one of the bronchi, its removal is more difficult. Indeed, if it is not voluntarily expelled upon making the tracheal opening, or upon titillating the tracheal mucosa, a bronchoscope should be introduced through the mouth.

I am greatly indebted to Dr. Chevalier Jackson for personal instruction and for the description of the technique of tracheobronchoscopy given in his classical treatise upon this subject. In describing the technique of the various procedures for the removal of foreign bodies from the upper respiratory tract, I have adhered to his methods and largely to the instruments devised by him. In so doing I am not unmindful of the fact that the greatest credit is due to Prof. Gustav Killian,

PLATE IX

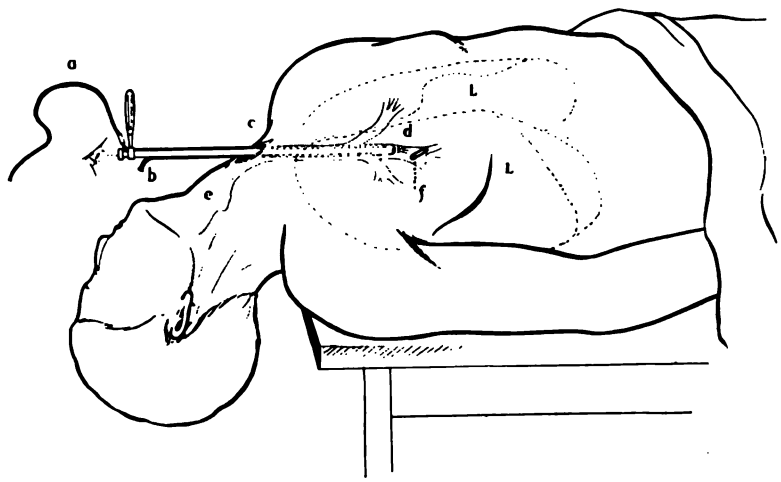

Lower Bronchoscopy. *a*, the electric wire supplying the lamp at the distal end of the bronchoscopic tube; *b*, the conduit for aspirating the secretions and blood from the distal end of the tube; *c*, the tracheotomy wound; *d*, the distal end of the tube; *e*, the larynx; *f*, the foreign body; *ll*, the lungs.

of Freiburg, who was the first to remove a foreign body from the bronchus by upper bronchoscopy, and who has, through his writings and demonstrations, made bronchoscopy available to every specialist throughout the world. Jackson's illuminated bronchoscopic tubes are, however, easier for the inexperienced surgeon to use, and for this reason I recommend them in this work.

Much credit is also due to Dr. Ingals, one of the first Americans to adopt bronchoscopy, for his writings, wherein he reports thirteen foreign bodies searched for or removed by bronchoscopy. Two deaths have followed the removal of the foreign body in his practice, the cause of death being attributed to reflex irritation of the vagus nerve.

Fig. 318

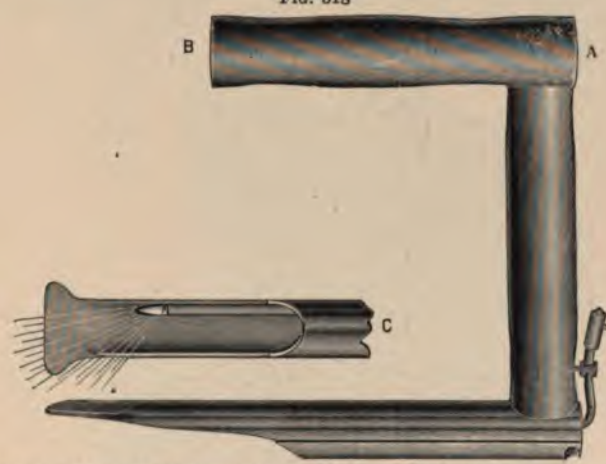

Jackson's split-tube spatula for direct laryngoscopy. The handle *B* gives great leverage and greatly aids in overcoming the resistance of the muscles at the base of the tongue when the epiglottis and tongue are lifted forward.

Tracheoscopy and Bronchoscopy.—*The Preparation of the Patient.*—If a general anesthetic, preferably ether, is used, the patient should be prepared as for a surgical operation. The morning hour before the patient has had breakfast is therefore the most favorable time, though in many cases the imminent danger in which the patient is placed leaves no choice in this respect. If time permits, the bowels should be emptied. If the tracheobronchoscope is to be used through a tracheal wound, the neck should be shaved and scrubbed. This route, as suggested by Jackson, is more septic than the other, as the instruments may be introduced through a sterile wound; whereas if they are passed through the mouth, the danger of septic infection of the deeper air passages is more liable to occur. In spite of this fact, upper bronchoscopy should be practised when feasible.

The Anesthetic.—Stolid adults tolerate the introduction of the tubes under cocaine anesthesia, whereas more excitable ones, and children, require a general anesthetic. The larynx, trachea, and right bronchus

may be cocainized by cotton-wound applicators before the introduction of the tubes, whereas the left bronchus and secondary and tertiary broncheoles can only be reached after the tube is introduced (Jackson). Ether is the best anesthetic. Ethyl chloride and chloroform should not be used, as they are not well tolerated by the lower respiratory tract. Profound anesthesia may be induced, though it is an advantage to retain enough of the reflexes for the patient to aid in disposing of the secretions, thus preventing the occurrence of pneumonia.

Fig. 319

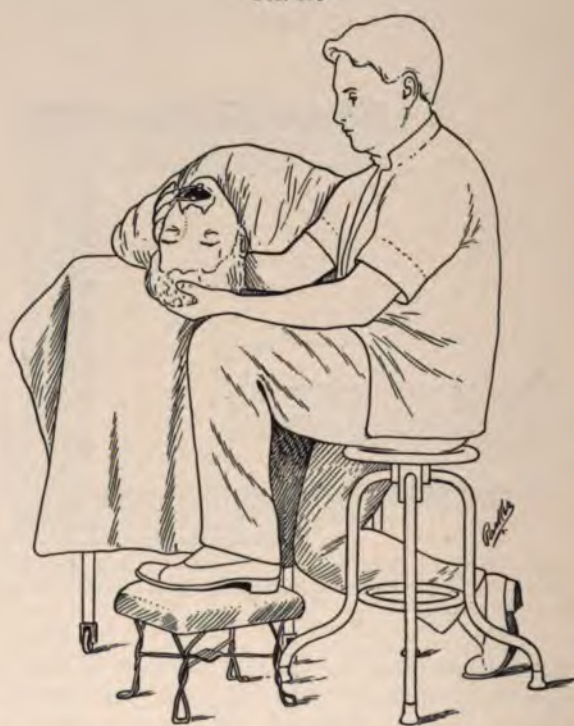

The position of the patient and assistant in upper tracheobronchoscopy. (After Jackson.)

Position of the Patient.—Killian usually passes the tubes under local anesthesia with the patient in the upright position. Jackson prefers general anesthesia, with the patient in the recumbent posture (Fig. 319), as it is less tiresome for the operator to sit than to stand during what is often a prolonged ordeal. The head of the patient is also steadied more readily in this position. Jackson prefers the recumbent posture, also because the patient is in position for tracheotomy should suffocation occur during the attempted upper bronchoscopy. The head should hang over the end of the table, in Rose's position, and should be firmly grasped by an assistant, as shown in Fig. 319. The head should be slightly turned to one side, so as to bring the angle of the mouth parallel

with the trachea. The tube when introduced will then rest in the angle of the mouth. If the tube is to be introduced through the tracheal wound, the head should still be held in much the same position.

Introduction of the Tube.—A tube should be selected of the proper length and size to reach the required depth and to correspond with the caliber of the respiratory tract to be explored. The length of the tube will depend somewhat upon whether it is to be introduced through the mouth or through the tracheal wound. The shorter the tube the clearer the field of inspection, though with Jackson's illuminated tubes the length of the tube makes but little difference. The size of the tube will depend upon the age of the patient and whether the trachea, bronchus, or one of the bronchioles is to be explored. The secondary and tertiary bronchi may only be explored with small tubes. Having selected a tube of the proper size and length, an assistant should cover it with sterile vaseline

Fig. 320

Battery for illuminating Jackson's tubes.

and hand it to the operator. The moment the tube is engaged in either the larynx or the tracheal wound the assistant should remove the obturator to allow free respiration. The tube should then be passed to the desired depth. Another assistant should have entire charge of the chloride of silver battery (Fig. 320) which furnishes the energy for the electric light at the distal end of the tube. He should now turn on the light while the operator inspects the field at the bottom of the tube. A third assistant should have sole charge of the pump or suction apparatus (Fig. 321) with which the secretions are withdrawn from the tube, and should apply the suction at the suggestion of the operator. There is a suction tube in the wall bronchoscope through which the secretions are removed. The use of a cotton-wound applicator will often clear the field better than the suction apparatus. The fourth assistant should hold the patient's head in position. The

anesthetist should closely observe the pulse and respiration, as they are liable to stop through reflex irritation excited by the presence of the bronchoscope in the trachea.

Fig. 321

Jackson's exhaust pump for removing secretions in tracheobronchoscopy.

Inspection.—The tumor or foreign body should be sought for at the depth of the tube by direct inspection through it. The illumination is brilliant, and a clear view may be obtained in most subjects if the secretions are removed by the pump and cotton-wound applicators.

Fig. 322



Long forceps for the removal of foreign bodies by bronchoscopy.

The Removal of a Foreign Body or Growth.—Long shanked hooks and forceps(Fig. 322) are introduced through the tube, the growth or foreign body seized and withdrawn. It often requires patience and perseverance to accomplish the purpose in hand. If the tube has been either carelessly or roughly introduced, the mucosa may be injured, the blood proving a worse obstacle to the view than the secretions. It is sometimes necessary to spend an hour or more in exploring the deeper air tract for a foreign body. Even then it may not be located.

Having completed the exploration successfully, the tracheotomy wound, if present, may be allowed to close at once, even though the obstruction to breathing is not completely relieved. The embarrassment still remaining is usually due to the congestion of the respiratory tract in the region formerly occupied by the foreign body, and will disappear in from three to seven days. If the foreign body is not found, or, if found, is not removed, the tracheotomy tube may be left in place indefinitely, or until such time as the foreign body is found or is expelled voluntarily.

Complications and Sequelæ.—When tracheoscopy and bronchoscopy are performed through the mouth under a general anesthetic, pneumonia is occasionally a serious sequela. If performed through the mouth under partial general anesthesia, or under cocaine anesthesia, such a sequela does not so often occur. When performed through a tracheotomy wound under strict aseptic precautions, pneumonia rarely follows except as a result of a septic condition established by the presence of the foreign body. That is, bronchoscopy *per se*, when performed under good surgical conditions, does not often cause pneumonia.

General Considerations.—According to Killian, foreign bodies lodging in the larynx, trachea, and bronchi may be divided into (1) hard and (2) soft varieties. He still further subdivides them for clinical purposes into (*a*) slender, (*b*) flat, (*c*) round, (*d*) cubical, (*e*) irregular, (*f*) metallic, (*g*) non-metallic (*h*) friable, and (*i*) those liable to swell. These subdivisions are of clinical significance, because the size, shape, consistency, and chemical composition have much to do with the location and the technique of removing the foreign bodies.

(*a*) Slender objects, as needles, pins, nails, splinters, etc., usually lodge with the point turned upward, and they lie diagonally across the lumen of the tube. Needles and pins usually cause little inflammation, hence mucus and large granulations are not present to obstruct the view. Slender foreign bodies should be grasped with forceps (Fig. 322) near the point buried in the tube wall, pushed downward to disengage the buried point, and then removed through the bronchoscopic tube. Small nails may be removed with a rod-magnet introduced through the bronchoscopic tube.

(*b*) Flat objects, as coins, buttons, pebbles (flat), usually lodge in the trachea, though small buttons may enter the bronchi. Coins are usually found in adults, as they are too large to enter the lower air tubes in infants and children. Children from three to six years old have a fascination for small flat pebbles. They usually lodge in the trachea near the bifurcation. Flat objects usually stand diagonally across the lumen of the trachea or bronchus, and are easily grasped with forceps. They may be removed by upper bronchoscopy in nearly all cases.

(*c*) Round objects, as glass beads, cherry stones, coffee beans, etc., are frequently coughed up before assistance is called. They remain movable for quite a while, changing position from time to time. As Killian says, they are difficult to grasp with the forceps on account of their shape and the ease with which they elude the forceps, as it pushes the foreign body before it. A bead or other round object is, therefore, more easily

removed if it is first pushed down to the bifurcation of the trachea, where it may be grasped with the forceps. Oval seeds, as prune stones, are rough and are easily grasped with the forceps. When present in children, prune stones are usually near the bifurcation of the trachea, as they are too large to enter the bronchi.

(*d*) Cubical foreign bodies are difficult to grasp with forceps on account of their width. Killian recommends the use of his hook or hook forceps for this purpose. He also recommends lower bronchoscopy (through a tracheotomy wound) after failure by upper bronchoscopy.

(*e*) Irregular objects, as bone fragments, are usually found in adults. When present in children they lodge in the trachea. If small, the fragments may enter the right bronchus. As the bone fragment is usually rendered sterile by cooking, the infection attending its presence is somewhat delayed. If allowed to remain in the bronchus or trachea too long, bronchitis, bronchiectasis, pulmonary abscess, or gangrene may develop. The bone fragments are irregularly flat, and vary in size from 14 to 16 mm. long by 8 to 9 mm. wide.

Carious teeth are occasionally aspirated into the trachea or bronchi, and when present quickly excite infective reaction. They should, therefore, be removed as quickly as possible.

Collar buttons are difficult to remove, especially when the larger flat end is turned upward. When the button lies crosswise of the air tube it may be grasped by its neck with forceps or a hook and removed.

False teeth are usually too large to pass below the vocal cords, though Wild reports a case in which a plate with two false teeth entered the left bronchus. It was removed eleven days after the accident by lower bronchoscopy, after being observed by upper bronchoscopy.

(*f*) Metallic substances may be clearly demonstrated by skiagraphy, whereas (*g*) non-metallic substances are less clearly defined. The skiagraph may, therefore, be used to locate the foreign body in many subjects.

(*h*) Friable substances, as a fragment of an apple or a swollen and partially disintegrated bean, are difficult to remove, as they break into smaller fragments when seized with forceps. When thus broken the smaller particles are often coughed up, though it is somewhat dangerous to depend upon this mode of ejection, as the particles may be aspirated into one of the secondary or tertiary divisions of the bronchus. Should this accident occur, one lobe of the lung may be deprived of air and rapidly undergo retrograde changes, and become the seat of infection and inflammation. Furthermore, the foreign body is less accessible and more difficult to remove when in one of the smaller bronchi. Killian has constructed a forceps, modelled somewhat after an obstetric forceps, with which friable substances, as a swollen bean, fragments of apple, etc., may be grasped and removed without leaving fragments in the air tube.

Barbed cereal spikes of wheat, rye, etc., are often difficult to remove, as the barbs usually point upward and engage in the mucous membrane when attempts are made to remove them. They have a tendency to gradually descend to the deeper tubes. A forceps that will grasp the entire length of the spike should be used, to prevent fragmentation of the spike.

(*i*) A swollen bean, or other substance liable to swell from the absorption of the moisture of the lower respiratory tract, may gradually close the lumen of the bronchial tube (secondary) and thus shut off the air supply to a portion of the lung. The secretions are retained and undergo decomposition, and finally cause serious inflammatory reaction, as violent fever, pneumonia, and atelectasis. According to Killian, 39 per cent. of these cases have died.

Killian has collected 164 reported cases of foreign bodies in the lower respiratory tract which were treated by bronchoscopy. Of these, 8 coughed the foreign body up. The result is unknown in 5, leaving 159 cases in which the results are known.

Twenty-one (13 per cent.) died, 2 from cocaine poisoning, 2 from stenosis, 16 from pulmonary complications, 5 with the foreign body *in situ*, and 11 in spite of removal.

Upper bronchoscopy was fully successful in 54 cases.

Lower bronchoscopy was fully successful in 63 cases.

Of the 18 cases occurring in Prof. Killian's practice, one died six months after the removal of the foreign body from severe pulmonary complications.

In two he failed to find the foreign body.

Upper bronchoscopy was performed in 12 cases.

Upper and lower bronchoscopy in 5 cases.

Lower bronchoscopy in 1 case.

Direct Laryngoscopy.—Direct laryngoscopy should be done as a routine procedure in the examination of the larynx, as by it a better view of the parts is obtained. It may be done in the office under cocaine anesthesia, though it is a very disagreeable procedure. Foreign bodies and neoplasms may also be removed by direct laryngoscopy; indeed, this should be the method of choice, especially in papilloma of the larynx, as repeated operations are often necessary to eradicate the disease.

Anesthesia.—Cocaine anesthesia is usually sufficient for office examinations and for the removal of growths and foreign bodies from the supraglottic portion of the larynx. First brush the larynx with a 4 per cent. solution of cocaine to lessen the reflex irritability, and after waiting a minute swab the larynx with a 20 per cent. solution of cocaine, under the guidance of a laryngeal mirror. One to three such applications at intervals of from three to five minutes generally induce local anesthesia profound enough to permit of an operation. Cocaine is not well tolerated by children, and should be used with caution.

Posture of the Patient.—The sitting posture is generally used. The patient should be seated upon a stool 8 inches high; an assistant, sitting behind the patient, should hold his head retracted backward to bring the mouth in line with the axis of the trachea. The assistant should also steady the mouth gag in the patient's mouth and retract the upper lip with the index finger to prevent its being injured between the upper teeth and the tube spatula (Figs. 323 and 324). The surgeon should stand in front of and over the patient, with his eye in line with the tube spatula and the larynx (Fig. 323).

Introduction of the Tube Spatula.—Pass the instrument into the throat until the distal end of the instrument is behind the tip of the epiglottis. Then draw the epiglottis forward against the base of the tongue, as shown in Fig. 324. If the spatula is placed too low, against the cricoid ring, the patient has a pronounced sense of suffocation; whereas if the instrument is withdrawn a little higher the dyspnea disappears and the patient breathes with a "brassy" tubular sound.

Examination through the Tube Spatula.—Forcibly draw the epiglottis forward against the base of the tongue to bring the anterior portion of the larynx into view. This is very difficult to do in some patients and comparatively easy in others. If an illuminated instrument is used, the light should be turned on before introducing it into the mouth. If a non-illuminated tube is used, a Kierstein head lamp (Fig. 317) should be utilized to illuminate the larynx.

Fig. 323

The non-illuminated separable tube spatula.

Upper Tracheobronchoscopy.—Upper tracheobronchoscopy is used for diagnostic and therapeutic purposes. By it the condition of the trachea, bronchi, and bronchioles may be observed, and treated by cotton-wound applicators moistened with the medicine. Jackson has observed and successfully treated ulcers of the trachea by upper tracheobronchoscopy. Persistent cough that resisted all other methods of treatment rapidly disappeared when the diseased tracheal mucous membrane was brushed with a mild solution of the nitrate of silver *via* the tracheobronchoscope. Foreign bodies in the trachea, bronchus, or one of the smaller bronchioles may be diagnosticated and removed through the tracheobronchoscope.

Preparation of the Patient.—If a general anesthetic is to be given, the patient should be prepared as for a major surgical operation if time permits.

Anesthesia.—A general anesthetic, preferably ether, should be administered. The larynx, trachea, and bronchi should also be brushed with a 20 per cent. solution of cocaine. The larynx may be brushed with cocaine before the introduction of the bronchoscope, and the trachea and bronchi as the tube is passed downward. The anesthetic should not be carried to its full effect, as it is safer to preserve the reflexes, so that the patient will aid in disposing of the secretions. Otherwise,

FIG. 324

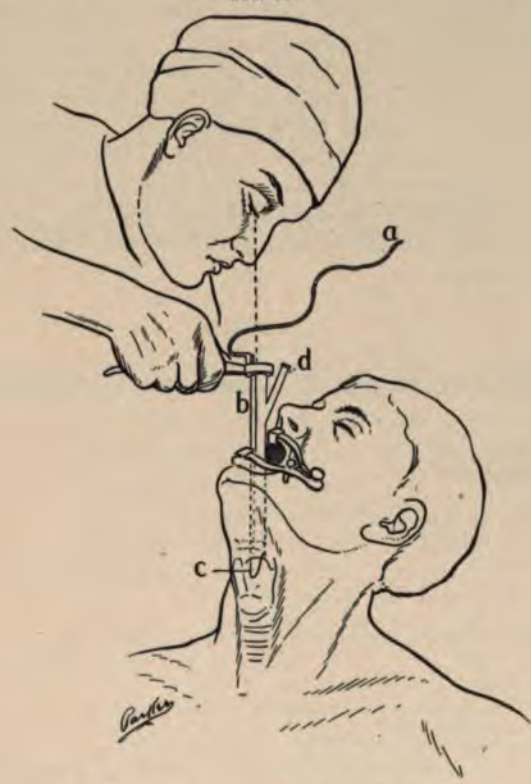

Direct laryngoscopy with Jackson's self-illuminated tube spatula. *a*, electric cord supplying the lamp at the distal end of the spatula; *b*, the conduit for the electric cord; *c*, the tip of the tube spatula holding the epiglottis forward against the base of the tongue; *d*, the conduit for the removal of the secretions and blood from the larynx during examinations and operations by direct laryngoscopy.

aspiration pneumonia may result. The use of cocaine in the larynx and trachea prevents the reflex phenomena due to irritation of the vagus nerve. After the bronchoscope is introduced the anesthetic should be given through the tube or by rectum after Cunningham's method.

The Position of the Patient's Head.—After fixing the mouth open with a Furguson or Furguson-Pynchon mouth gag, have an assistant seated on a stool at the right side of the head of the patient, with his left foot on a low stool. The patient's head and neck are drawn beyond the end of

the table, and are supported and controlled by the assistant. His right arm is passed beneath the neck of the patient, the hand grasping the mouth gag and side of the face. The assistant's left arm rests upon his left knee, and his hand supports the patient's head. The head and neck are thus under the complete control of the assistant (Fig. 319). By raising his right arm the neck is raised, and by raising the left hand the head is raised, and by reversing the movements of the arm and hand the opposite effects are produced. With the right and left hands the head may be rotated on its vertebral axis. The foot of the table should be fifteen inches lower than the head.

Introducing the Split-tube Spatula.—The split-tube spatula should be introduced to expose the chink of the glottis while the tracheobronchoscope (Fig. 325) is being introduced. This procedure is identical with that described in the section on Direct Laryngoscopy, the only difference being the recumbent posture of the patient and the use of the split-tube spatula. Jackson's split-tube spatula (Fig. 318) is so constructed that it may be easily removed after the tracheobronchoscope has entered the trachea.

Fig. 325

Jackson's self-illuminated tracheobronchoscope.

Introducing the Tracheobronchoscope.—Having properly introduced the split-tube spatula and exposed the cords of the larynx to view through it, the tracheobronchoscope is introduced through the tube spatula to the larynx. The light is turned on by an assistant, and the operator's eye is placed at the proximal end of the tracheobronchoscope to watch the respiratory movements of the vocal cords. The tracheobronchoscope should be passed through the glottis during an inspiratory movement of the vocal cords, as they are separated at this time.

Having passed the vocal cords and a short distance into the trachea, the split-tube spatula should be separated and removed from the mouth.

The tracheobronchoscope resting in the angle of the mouth and trachea should be pushed downward (cocaine being applied to the mucous membrane with a long cotton-wound probe) until it reaches the foreign body, morbid process, or the bifurcation of the trachea. The tracheobroncho-

scope should rest in the left angle of the mouth if the right bronchus is to be entered; if the left bronchus, the right angle of the mouth. The assistant should constantly guard the upper lip of the patient with his index finger to prevent it being pinched between the upper teeth and the bronchoscope.

Fig. 326



Jackson's safety-pin closer.

Having entered the right or left bronchus, the tube is passed downward, the operator watching for the secondary bronchi, morbid lesion, or the foreign body. By using the smallest-sized bronchoscope the terminal bronchioles may be explored for abscess or other morbid lesion, and if the diseased area is not accessible to bronchoscopic treatment it may be accurately diagnosticated and located and operated through the chest wall by a general surgeon.

Fig. 327



Mosher's safety-pin holder.

The Removal of the Secretions and Blood.—The secretions and blood may be removed with Jackson's pump or aspirator (Fig. 321), which is attached to the conduit for this purpose. An assistant should have entire charge of the aspirator, and use it as directed by the operator. Long cotton-wound applicators may also be used to remove the secretions. According to Ingals, the preliminary use of atropine prevents excessive secretions. It also guards against reflex shock.

The Removal of Foreign Bodies.—Variously shaped forceps, hooks, screws, etc., are used to remove foreign bodies (Figs. 326, 327, 328 and 329).

Topical Applications.—Ulcers and other local morbid lesions of the mucous membrane of the trachea and bronchi may be brushed with a weak solution of the nitrate of silver through the tracheobronchoscope.

Remarks.—The trachea and bronchi are elastic and expansile, and tolerate the straightening and dilatation with the bronchoscope.

The illuminated tubes should not be boiled unless the electric light is removed. They should be immersed in alcohol. Likewise the unilluminated tubes should not be boiled, as the lustre of the interior of the tube is thus destroyed and its capacity to carry the reflected rays from the head lamp is diminished.

Do not use instruments in lower bronchoscopy that have just been used in upper bronchoscopy. Have freshly sterilized instruments ready for the purpose. Have sterile lamps in a sterile tube ready for use should a lamp burn out.

The patient's head and face should be prepared as for a major operation about the head. The teeth and mouth should be scrubbed with soap and alcohol. The operator and assistants should be dressed in sterile gowns and caps, a precaution especially necessary in handling the long instruments.

The patient should be allowed to sit up as soon as possible, to prevent the occurrence of pneumonia.

Fig. 328

Jackson's forceps, curved jaws.

Fig. 329

Jackson's forceps, cupped jaws.

Lower Tracheobronchoscopy.—Lower tracheobronchoscopy consists in introducing the tracheobronchoscope through a tracheotomy wound, as shown in Plate IX.

Indications.—Lower tracheobronchoscopy is indicated when direct laryngoscopy or upper tracheobronchoscopy fails. A larger tube may be used in lower bronchoscopy, an advantage in removing large foreign bodies.

Position of the Patient.—Primary lower bronchoscopy should always be done in the dorsal position, as tracheotomy is to be performed. The patient should be placed in Rose's position, with the head extended beyond the end of the table.

Low Tracheotomy.—Low tracheotomy should be performed, as the chin is thus farther removed from the operative field and is not so much in the way of the long instruments. The tracheobronchoscope may, however, be introduced through a high tracheotomy wound.

Stop all bleeding before introducing the tracheobronchoscope.

The trachea should be swabbed with a 20 per cent. solution of cocaine through Trousseau's dilator (Fig. 330).

If the right bronchus is to be entered, have the patient's head turned to the left, and *vice versa.*

Introduction of the Tracheobronchoscope.—Jackson's illuminated short tracheobronchoscope should be introduced through the tracheotomy wound, the operator's eye being at the proximal end of the tube watching for the bifurcation of the trachea (Plate IX). The end of the bronchoscope usually lodges against the bifurcation, so that both bronchi

Fig. 330

Trosseau's dilator.

are visible. Lateral pressure in either direction will allow the tube to pass into one of the bronchi. The moment the tube enters the bronchus cough is excited. A cotton-wound applicator moistened with a 10 per cent. solution of cocaine should be applied through the tube and the tube passed to the secondary bifurcation (Fig. 331 *SL*). When a secondary bronchus is entered cough is again excited, and cocaine should be applied

Fig. 331

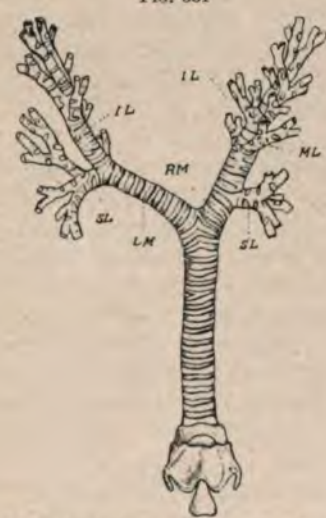

Tracheobronchial tree. *LM*, left main bronchus; *SL*, superior lobe bronchus; *ML*, middle lobe bronchus; *IL*, inferior lobe bronchus. (Jackson.)

as before. It is impossible to maintain anesthesia deep enough to entirely abolish the cough reflex for any length of time, unless rectal anesthesia is used, and even then it is not advisable to abolish all the reflexes, as the patient is thereby subjected to the danger of aspiration pneumonia.

Having introduced the tracheobronchoscope, the foreign body and morbid lesions should be studied, treated, or removed.

After-treatment.—The tracheotomy wound should not be sutured except at its upper and lower angles. The tracheotomy tube should be worn for a few days, but should be abandoned before the patient leaves the hospital. The tracheotomy wound should be cleansed every three hours with a warm 1 to 5000 bichloride solution. The wound should heal from the bottom, beginning with the severed tracheal rings. If the fleshy portion of the wound tends to heal first, it should be prevented.

ESOPHAGOSCOPY; FOREIGN BODIES IN AND STRICTURES OF THE ESOPHAGUS.

The examination of the esophagus through the mouth is now an established procedure, and should be considered in connection with bronchoscopy, as foreign bodies may lodge in either tube. The differential diagnosis between a foreign body in the trachea or bronchi and the esophagus must, therefore, be made. Not only this, but the foreign body should be removed, whether it is in the bronchi, the trachea, or the esophagus. A brief description of esophagoscopy will, therefore, be given in this work.

The sizes of tubes required, according to Chevalier Jackson, are, for infants, 7 mm., and for adults 10 mm. in diameter.

The normal appearance of the esophageal lumen with the Jackson self-illuminated tubes is a whitish grayish pink, in stong contrast to the red color of the tracheal membrane.

Examination of the Upper End of the Esophagus.—This is the easiest of all the examinations with the straight tubes, and is accomplished by the same technique described under Direct Laryngoscopy (p. 359). According to Jackson, the split tubular speculum (Fig. 318) should be passed back of the base of the tongue until the epiglottis appears, after having cocainized the *introitus esophagi* with a 10 per cent. solution. Having engaged the tip of the epiglottis, a straight cotton-wound applicator, dipped with a 10 per cent. solution of cocaine, should be passed through the tubular speculum and applied to the epiglottis, the laryngeal and the esophageal orifices, waiting a few minutes for anesthesia to supervene. The tubular speculum is then passed down back of the epiglottis and the cricoid cartilage, and lifted forward against the base of the tongue. The larynx and the esophageal depression are thus brought into view. The spatular end of the tubular speculum is inserted into the esophageal depression to a point below the arytenoid cartilages, and far enough to engage the posterior portion of the cricoid cartilage. The cartilage should then be lifted forward, thus exposing the pyriform fossæ and the esophageal lumen.

ESOPHAGOSCOPY.

Dr. Chevalier Jackson gives the following description:

"Preliminary to passing a tube into the lumen of the esophagus the upper end of the esophagus should be examined, as described in the preceding section, to learn the pathological conditions present in this region. This procedure will prevent the making of a false passage through an ulcerated surface and will locate a foreign body if present at the entrance of the esophagus. In passing the long tube extreme gentleness should be practised. If the tube does not readily pass, it is either not correctly placed or it is improperly directed. The tube should be lubricated with sterile vaseline. The proximal end should be held lightly with the right hand, the handle directed horizontally to the right. The forefinger of the left hand is passed into the right glosso-epiglottic fossa, posteriorly to the lateral glosso-epiglottic fold and posteriorly to the tense pharyngo-epiglottic fold, and, if possible, into the right pyriform sinus.

"The tube should then be made to follow the same route, while the finger slides toward the median line and lifts the tongue and anterior pharyngeal tissues upward (dorsal decubitus). When the cricoid cartilage can be reached, which is possible only in children, it is better to lift upon it directly rather than upon the soft tissues. When possible, as it usually is in adults, the cartilage should be lifted indirectly by traction upon the tissues at the extreme point reachable with the finger, often the right glosso-epiglottic fossa."

The head of the patient should be held in extreme extension with the mouth widely open, as shown in Fig. 319.

"After the *introitus* is passed the obturator is removed, and the cord is attached to the light carrier by the bayonet fitting. The tube must be guided by the eye so as to follow the esophageal lumen by sight. After passing the *introitus* the head of the patient should be raised slightly to prevent the tube pressing on the trachea."

The entire lumen of the esophagus may be examined for stricture or other pathological lesion, and for foreign bodies. When a foreign body is found it may be removed as by bronchoscopy. By using a longer tube almost the entire surface of the stomach may also be inspected with great clearness of illumination with Jackson's self-illuminated gastroscope.

In one of my cases the skiagrapher reported the foreign body, a penny, to be located at the bifurcation of the traceha. As it was impossible for me to get to the studio to examine the plate, I acted upon his diagnosis and attempted to locate the foreign body in the trachea. At one time I passed the tube into the esophagus and heard a slight metallic click. Further search failed to elicit the metallic sound. When I viewed the skiagraphic plate a few days later I found the shadow of the penny on a level with the cricoid cartilage, instead of at the bifurcation of the trachea, as reported by the skiagrapher. Nine days after the attempted removal

by bronchoscopy the penny was passed per rectum, thus showing the penny to have been in the upper portion of the esophagus, from where it probably was dislodged at the time I heard the metallic click. Another point of diagnostic interest in this case was the position of the penny. Its flat surface stood at right angles to the vocal cords, a fact which immediately attracted my attention when I saw the plate a few days later.

Fig. 332

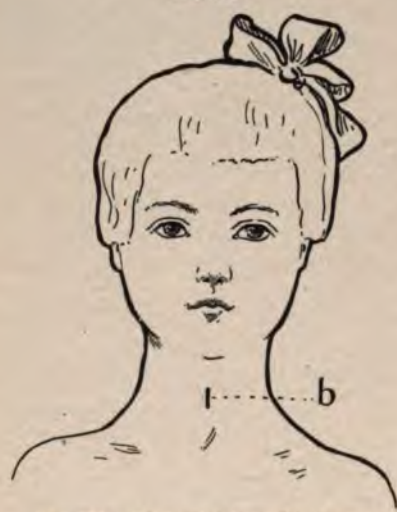

Fig. 333

Fig. 332.—The probable position assumed by a penny when lodged in the subglottic space.
Fig. 333.—The position assumed by a penny, as shown by skiagraphy, when lodged in the mouth of the esophagus of a child, aged three years. (Author's case.)

Had the penny been in the subglottic space, its edge probably would have presented anteriorly. The location and position of the penny led me to inform the parents that it was not in the trachea, but was in the upper part of the esophagus at the time the skiagraphic plate was made. This diagnosis was later verified by the passage of the penny (Figs. 332 and 333).

PART IV.

THE EAR.

CHAPTER XXXII.

THE CLINICAL ANATOMY AND PHYSIOLOGY OF THE EAR.

THE organ of hearing is divisible into (*a*) the external ear, (*b*) the middle ear, and (*c*) the internal ear.

THE EXTERNAL EAR.

From a clinical point of view the auricle is of interest on account of the destructive inflammatory processes which attack its cartilaginous framework and the perichondrium covering it. Perichondritis and chondritis of the auricle occurring in the insane from traumatism has been frequently observed and reported (Fig. 348). Perichondritis following the mastoid operation occasionally occurs. I have seen but one case in my practice, and it developed several weeks after the mastoid operation, the exciting cause undoubtedly being the influenza bacillus as it followed an attack of la grippe. In performing the plastic operation upon the meatus, that is, in making the Koerner, Panse, Siebenmann, or the Ballance incisions, the cartilage of the auricle is included; hence it is necessary to exercise great care as to surgical cleanliness, otherwise infection of the perichondrium and cartilage may occur.

The *external auditory meatus* is divisible into a cartilaginous and an osseous portion. The cartilaginous portion of the meatus (the auricular extension) is attached to the osseous or deeper portion by bands of fibrous tissue. The superior and posterior walls of the cartilaginous meatus are thinner than the anterior and inferior walls. The inferior wall extends deeper along the floor of the meatus than the other walls, and is known as the processus triangularis. The anterior wall of the cartilaginous meatus is crossed by two or three fissures, which are filled with connective tissue and a few muscle fibers. These fissures are called the fissures of Santorini, and they render the auricle more movable. They are of clinical importance, first, because they afford an outlet for the discharge of pus into the meatus in deep abscess of the parotid gland, and secondly because they permit the auricle to be turned over on the cheek during the mastoid operation.

In the newborn the meatus is fibrous throughout its entire length, and its walls are collapsed and in apposition. Bone salts are gradually deposited and the canal assumes its open condition.

The sebaceous glands are limited to the cartilaginous portion of the meatus, hence furunculosis of the meatus is confined to this area. The beginner in otology is sometimes confused in making a differential diagnosis between acute suppurative mastoiditis, with bulging of the post-superior wall, and furunculosis of the cartilaginous meatus. In the first instance the bulging is in the bony meatus close to the drumhead, and the auricle is not tender or sensitive upon manipulation. In the second instance the bulging is more external in the cartilaginous meatus, and the auricle is extremely sensitive upon manipulation. The sensitiveness of the auricle in furunculosis is due to the fact that the inflammatory reaction attending the furuncle or boil has extended by continuity of tissue from the cartilage of the meatus to the cartilage of the auricle, and thereby renders the nerve fibers of the auricle exquisitely sensitive.

THE MIDDLE EAR.

The drumhead or eardrum forms the outer wall of the middle ear. It is a composite membrane of three layers, the outer one being a reflection of the skin of the meatus, the middle one being fibrous tissue, and the inner a reflection of the mucous membrane of the middle ear. The handle of the malleus is embedded within these structures, hence the sound waves impinging upon the eardrum are transmitted to the handle of the malleus, and from thence to the incus and stapes where the foot plate transmits them to the sound perception apparatus.

The membrana tympani is of clinical importance chiefly on account of the various changes in its appearance in diseased conditions of the middle ear. These changes are, therefore, of diagnostic value. In order to fully appreciate the abnormal appearances of the eardrum, it is first necessary to know the normal characteristics. A normal drumhead is characterized by the presence of the handle of the malleus, the short process of the malleus, the triangular cone of light, the anterior and posterior folds, and a faint view of the long process of the incus seen through the semitransparent eardrum.

When the Eustachian tube is closed the air within the middle ear cavity becomes rarefied by the gradual absorption of the oxygen into the blood of the surrounding tissues. As a result of the negative pressure thus brought about, the eardrum is pushed inward—that is, the eardrum is retracted. This changes the contour of the eardrum as viewed through the external auditory meatus. The cone of light is broken or altogether lost, the handle of the malleus is drawn inward and is foreshortened, the short process of the malleus projects more prominently toward the observer's eye, and the anterior and posterior folds which arise from the short process are accentuated.

In retraction due to obstruction of the Eustachian tube the membrana

tympani is regular or uniform throughout its entire area, with the exception of the part containing the malleus. If the retraction is due to an adhesion to the inner wall of the tympanic cavity the membrane is irregularly retracted. The membrana tympani, upon suction with Siegle's otoscope, remains fixed at the point of adhesion, and is distended in other areas, giving a blistered appearance.

PERFORATION OF THE MEMBRANA TYMPANI.

The clinical significance of perforation of the membrana tympani when due to middle-ear disease is somewhat dependent upon whether it is marginal or central in location. When marginal it usually signifies bone necrosis, and when central (away from the margin) it signifies a simple middle-ear suppuration without bone necrosis.

Its significance is still further differentiated by noting its exact location; that is, if it is marginal the bone necrosis is in the immediate vicinity of the marginal perforation. If, for instance, the perforation is in the margin of Shrapnell's membrane (membrana flaccida), immediately above the short process of the malleus, the attic wall is necrotic; if it is in the postsuperior margin of the eardrum (the part nearest to the antrum) the mastoid antrum is necrosed.

The point to be borne in mind is that the perforation is secondary to the bone necrosis, the necrotic process extending from the ear cavities to the eardrum. Its clinical significance is, therefore, an index to a preëxisting morbid process in the tympanic cavities, the focal point of which is in the neighborhood of the perforation. Leutert, Zaufal, and others have called attention to the significance of the foregoing facts.

The further elaboration of the clinical significance of perforations of the eardrum is given in Fig. 377.

THE EUSTACHIAN TUBE.

The second and most common avenue of approach to the middle-ear cavity is through the Eustachian tube. It is through this channel that nearly all middle-ear diseases effect an entrance into the middle-ear cavity. The tube is about 36 mm. long, the pharyngeal opening being about 25 mm. lower than the tympanic opening. The tympanic opening corresponds to the anterosuperior quadrant of the eardrum, hence it is not in the most dependent portion of the cavity. This does not interfere with drainage under normal conditions, as the ciliæ of the epithelium of the tympanic cavity sweep the secretions to the opening of the tube and on through it to its pharyngeal opening. If, however, the ciliæ are impaired in their functional activity by an inflammatory or other morbid process, the elevated position of the tympanic orifice of the tube materially interferes with the drainage. Under these conditions the secretions are retained, decomposition follows, and further irritation of the mucous membrane results.

The tympanic end of the tube has an osseous framework, and is about 8 mm. long. The pharyngeal end of the tube has a cartilaginous and membranous framework, and is about 15 mm. long. The tube is trumpet-shaped at both extremities, and is narrowest at the junction of the osseous and cartilaginous portions. This is known as the isthmus. The framework is lined with mucous membrane which is covered with ciliated epithelium, which carries the secretions toward the pharyngeal orifice.

Under ordinary conditions the membranous walls of the tube are in a state of collapse, and only open when certain palatal muscles are contracted. Yawning and swallowing cause these muscles to contract, and air is thus admitted into the tympanic cavity.

The muscles regulating the patency of the pharyngeal orifice of the tube are the tensor veli palati and the levator palati; they also elevate the soft palate and assist in approximating it against the posterior wall of the pharynx in the act of swallowing. As the superior ends of the muscles are attached to the cartilaginous lip and to the membranous portion of the tube, and the inferior end to the soft palate, it is obvious that the contraction of the muscles will produce a twofold result, namely, the pharyngeal orifice of the tube is opened and the soft palate is elevated.

When, for any reason, the act of swallowing does not open the tube sufficiently to admit air into the tympanic cavity, the oxygen is absorbed from the contained air by the blood in the surrounding tissues, and a partial vacuum, or negative pressure, results. The blood in the surrounding tissues is attached to the parts by the negative pressure, and congestion results. The retained secretions undergo decomposition and irritate the lining mucous membrane. The hyperemia induces overnutrition. As a result of the combined irritation and increased nutrition the mucous membrane becomes thickened, either by hypertrophy or hyperplasia. The secretions are not only retained in excessive quantity but are changed in character. This condition is known as middle-ear and tubal catarrh.

Anything that obstructs the flow of secretions of the Eustachian tube predisposes the mucous membrane of the tube and middle ear to infection and inflammation. The two great underlying principles relating to the etiology of inflammation of mucous membrane-lined cavities are: (*a*) The exciting cause of inflammation is almost always a pathogenic microörganism. The microörganism is powerless to grow upon healthy tissue, hence the second great underlying principle relates to the conditions which favor infection. (*b*) The predisposing cause is usually an obstructive lesion interfering with the drainage and ventilation of the cavity, whereby the resistance of the tissues is lowered. When the resistance of the tissues is lowered the pathogenic microörganisms flourish, and with their toxins excite the reactions of inflammation.

The action of the tensor and levator veli palati muscles is so intimately associated with that of the muscles of the palate and pharynx that it is somewhat difficult to estimate the influence of the other muscles on the patency of the tubes. The pharyngopalatinus (posterior pillar of the fauces) has its upper attachment in the soft palate, and it contracts

during deglutition, and thus indirectly exerts a tensive action upon the tubal muscles. In inflammatory processes involving the tonsils and the faucial pillars the swollen condition of the palatopharyngeus muscle indirectly interferes with the action of the tubal muscles. In this way disease of the tonsil causes tubal and middle-ear disease; that is, drainage and ventilation are interfered with. Whatever may be the explanation, it is a common clinical observation to see tubal and middle-ear catarrh improved by the removal of the tonsils.

The anterior wall of the tube is membranous, while the upper and posterior walls are cartilaginous. The tensor and levator veli palati muscles are attached to the membranous portion of the tube, hence when they contract the tube is opened to its isthmus.

Much has been written concerning the normal patency of the Eustachian tube, and the preponderance of the evidence is in favor of the view that it is closed except during the act of deglutition. Politzer's experiment, consisting of a vibrating tuning fork held in front of the nose, shows that it is but faintly heard except during deglutition, thereby proving that the tube is closed under ordinary conditions and is open during deglutition. This permits of the interchange of air between the pharynx and the middle ear, and maintains an equilibrium of pressure on the inner and the outer surfaces of the membrana tympani.

The pharyngeal end of the tubal cartilage (posterior and superior walls) forms a projecting lip or tubal prominence on the lateral wall of the epipharynx. Just behind this is a groove known as Rosenmüller's fossa. The fossa and tubal prominence are the landmarks used in the introduction of the Eustachian catheter. The tip of the catheter is first lodged in the fossa of Rosenmüller, then drawn forward, gliding downward and inward over the prominence, and thence upward and outward into the tubal orifice.

To inflate the tube and middle ear, the compressed air should be applied at the beginning of the act of deglutition, as the tubal muscles are then contracted and the tube open. The Eustachian tube of an infant is shorter, straighter, and more easily inflated than that of an adult. In an adult the tube is sharply bent at the isthmus, whereas in an infant the tube is nearly straight. A lower degree of air pressure should, therefore, be used in tympanic inflation of infants than in adults. Earache in infants and young children is often quickly relieved by inflation, as it is due to tubal congestion.

THE TYMPANIC CAVITY; TYMPANUM; CAVUM TYMPANI.

The tympanic cavity is the air space between the tympanic orifice of the Eustachian tube and the mastoid antrum. Its lining mucous membrane is continuous with that of the Eustachian tube, and extends to the antrum and mastoid cells. It is covered with ciliated epithelium whose wave-like motion carries the secretion to the Eustachian tube.

The upper wall (tegmen tympani) of the tympanic cavity is close

to the cranial cavity; the outer wall is the eardrum; the inner wall is contiguous to the labyrinth; its posterior wall to the mastoid cells, its anterior wall to the carotid artery and its lower wall to the jugular bulb. The facial nerve runs across the upper and posterior wall and is usually enclosed in a bony covering, though numerous instances are on record in which the bony covering was absent.

The Contents of the Tympanic Cavity.—The tympanic cavity contains the chain of ossicles, the tympanic muscles, and the chorda tympani nerve. The handle of the malleus is attached to the membrana tympani, and the foot plate of the stapes is attached to the membrane of the oval window. The incus is suspended between the malleus and stapes, and completes the anatomical connection between the membrana tympani and the labyrinth. The chain of ossicles transmits the sound waves from the membrana tympani to the labyrinth, though there is little doubt that some waves are transmitted through the air in the tympanum to the round or oval window without the intervention of the ossicles. I recall one patient on whom I did a radical mastoid operation, removing the malleus and incus, who heard whispered speech at ten feet, showing that good hearing is possible without the ossicles.

The Chain of Ossicles and the Membrane of the Oval Window.—It is shown by the case just cited that all the receiving apparatus may be removed except the contents of the oval window without greatly impairing the hearing. Orientation of hearing is greatly diminished, as is also the faculty of keying the perception apparatus to catch sounds more accurately. The tensor tympani and the stapedius muscles are rendered ineffective in the removal of the malleus and incus, hence the ear has lost its focusing apparatus. The membrana tympani receives a larger number of sound waves than the foot plate of the stapes, hence the hearing is more acute with the eardrum and the ossicles intact than it is with them absent.

A Physiological Law.—It may be laid down as a physiological law that *anything that interferes with the normal tension existing between the membrana tympani, ossicles, and the contents of the oval window will cause tinnitus and deafness.* Hence pathological changes in the eardrum, thickening or other change in the mucous membrane covering of the ossicles, ankylosis of the ossicles, especially of the foot plate of the stapes, as in spongifying of the bony capsule of the labyrinth, etc., result in tinnitus and deafness. Catarrhal inflammation of the mucous membrane of the middle ear and Eustachian tube induces a negative pressure in the tympanic cavity, and disturbs the normal tension between the eardrum and the oval window; the mucous membrane of the walls of the tympanic cavity and of the ossicles is thickened, and tinnitus and deafness follow. The inflation of the tympanic cavity in tubal and middle-ear catarrh restores (in a degree) the normal tension and decreases the congestion of the mucous membrane, and thereby lessens the tinnitus and deafness.

The heads of the malleus and incus and their ligamentous attachments to the walls of the tympanic cavity divide the cavity into two

compartments, namely, the atrium, or middle ear proper, and the attic. When there is a suppurative process in the attic or the antrum and mastoid cells for a considerable time, adhesive bands form and still further increase the barrier between the atrium and the attic. The drainage of the secretions is blocked, and gives rise to retention and decomposition of the secretions and to pressure symptoms, as pain and tenderness. Necrosis is also augmented by the increased pressure from the retained secretions. Attic suppuration, and suppuration in the antrum and mastoid cells in old chronic cases, is, therefore, a more serious condition than suppuration with its focal centre in the atrium.

The *chorda tympani* nerve passes through the upper portion of the atrium between the handle of the malleus and the long process of the incus, and is usually severed or destroyed in the radical mastoid operation. As a consequence, the sense of taste at the base of the tongue and the neighboring parts of the fauces is impaired; indeed, it is perhaps best to destroy the nerve as the irritation during the application of post-operative dressings excites a disagreeable sense of taste.

The Walls of the Tympanum.—The superior wall, the tegmen tympani, is a thin plate of bone forming a portion of the middle fossa of the skull, and it is frequently the seat of necrosis in suppurative inflammation of the middle ear. The necrotic process often extends through it, and thus exposes the dura to the infective bacteria present. Ordinarily a wall of granulation tissue is formed in Nature's effort toward repair and protection. Such a perforation may, therefore, exist for years without involving the cranial contents. On the other hand, if the secretion is blocked by the ossicles, their ligaments, and the adhesive bands at the floor of the attic, the infective bacteria may be forced through the granulation tissue into the cranial cavity and excite meningitis or brain abscess.

One of the strongest arguments against curettage of the attic through the external auditory meatus is, that the granulation tissue may be removed and the dura exposed to the pathogenic bacteria. The same objection does not hold to its removal during the radical mastoid operation, as in this case all morbid material is or should be removed and perfect drainage is established.

The inferior wall or floor of the tympanic cavity is of clinical interest, on account of its proximity to the jugular bulb. It is only in exceptional cases, however, that the floor is thin, hence the jugular bulb is ordinarily in no danger in the curettage of the floor. Occasionally the floor is so thin that in curetting granulations from it there is danger of injuring the jugular bulb and causing serious or even fatal hemorrhage. When the jugular bulb is thrombosed, necrosis of the floor of the tympanic cavity may occur, and granulations spring from this point. Granulations on the floor of the tympanum in cases of lateral sinus thrombosis are significant of involvement of the jugular bulb.

The outer wall of the tympanum is chiefly composed of the membrana tympani, though at its upper and lower portions it is composed of bone. The bony wall at its upper portion forms the outer wall of the

attic, or the recessus epitympanicus (Fig. 334). The handle of the malleus is embedded in the membrana tympani, as is also the short process, located at the upper extremity of the handle.

The inner wall of the tympanum is of interest because it also forms the outer wall of the labyrinth, and because of the presence of important structures concerned in the function of sound conduction (Fig. 334). The most important of the structures concerned in sound conduction are the oval window (fenestra vestibuli), the stapedius muscle, the tensor tympani muscle, and the round window (fenestra cochlea). The other important structures are the promontorium, a projection due to the beginning of the basil turn of the cochlea; the prominentia canalis facialis, which forms the upper and posterior border of the fossula fenestræ cochleæ; and the prominentia canalis semicircularis lateralis. The prominences of the facial nerve canal and of the lateral semicircular canal form the median boundary of the attic (recessus epitympanicus), and they lie in close relation to the deep portion of the postsuperior wall of the external auditory meatus. The removal of this wall in the radical mastoid operation is liable to result in injury to these two structures. The Stacke protector is sometimes used to protect these structures by passing it from the middle ear upward and backward into the epitympanic space.

The facial nerve is usually covered by bony tissue, though in exceptional cases it is not. In necrotic processes it is frequently exposed, hence extreme caution is necessary in removing the postsuperior wall of the meatus, lest the nerve be injured. The nerve comes sharply outward from the cranium and then turns downward, forming a rather sharp knee, without coming near the mastoid surface. Hence, the outer portion of the postsuperior wall of the meatus may be removed freely without danger of injuring the facial nerves. T. Passmore Berens reported a case in which the facial nerve came near the surface and in which it would have been injured if the posterior wall of the meatus had been removed as completely as usual. The posterior wall should therefore be removed in shavings, the operator constantly watching for the dense bone surrounding the nerve. The bone of the postsuperior wall of the meatus is often spoken of as a "wedge of bone," from the fact that when removed it is triangular in shape. The point of the wedge is at its deepest portion, while the pole is the external portion. The point of the wedge forms the outer wall of the aditus ad antrum, the constriction which marks the boundary between the attic and the antrum. In removing the postsuperior wall of the meatus (wedge of bone) it should be remembered that the outer or more superficial portion may be freely chiselled away, but that as the inner or deeper portion is approached, the upper and lower lines of incision should be gradually approximated. In this way the channel of communication (aditus ad antrum) between the antrum and the attic (epitympanic space) is enlarged.

The malleus and incus are also removed in the radical mastoid operation, and the obstruction to the drainage of the mastoid cells and the

antrum is thus completely removed. The chief objection to the removal of the malleus and incus (ossiculectomy) for the cure of chronic suppurative ear disease is that neither is free drainage thereby established, nor is all the morbid material removed; that is, the necrosis and granulations are usually present in the antrum and cells as well as in the attic, hence the removal of the malleus and incus does not relieve the trouble except in the attic. Only the radical mastoid operation does this. If the disease is limited, or focalized in the attic, ossiculectomy may be all that is necessary to do. (See Mastoid Operations.)

The Antrum.—The antrum is embryologically a part of the middle ear, while the mastoid cells are not. It communicates with the attic through the aditus ad antrum. The mastoid cells drain into it. The ciliated epithelium lining the cells, antrum, tympanum, and the Eustachian tube propels the secretions successively through these parts to the pharyngeal orifice of the tube. In severe acute inflammation, and in prolonged chronic inflammation, the epithelium is denuded in certain areas of its ciliæ, and the drainage of the secretions is interfered with. The superficial destruction of tissue thus started may extend to the deeper tissues, as the epithelium, mucous membrane, periosteum, and the bone. Necrosis may be thus established. When such extensive destruction has become established there is little probability of a cure except by the radical or the Heath operation.

The Mastoid and Temporal Bone Cells.—A knowledge of the possible distribution of the mastoid and temporal bone cells is sometimes a matter of extreme importance in the successful treatment of mastoiditis. In many chronic cases it is absolutely necessary for the surgeon to remove all morbid tissue, and to establish free drainage of the remotest air spaces in the temporal bone. The pneumatic cells are not always confined to the mastoid process, but may be in the posterior root of the zygoma, the squamous plate of the temporal, or even in front of the external auditory meatus. I have seen cases in which pus-discharging cells were in front of the meatus with a canal of communication leading to the antrum. Had they not been opened and exenterated in the course of the radical operation, the operation would have been a failure. Hence it is necessary in all chronic cases to make careful search for pneumatic cells in other regions than the mastoid process. In one of Dr. Wale's specimens the mastoid cells seemed to communicate with the sphenoid sinus.

One object of the radical mastoid operation is to convert the middle ear, antrum, and mastoid (and other pneumatic cells of the temporal bone) into one irregular but freely opened cavity; another object is to remove all the morbid tissue from these and other areas of the temporal bone. If this is done, and the parts are kept in an aseptic condition during the healing process, a cure will follow. To neglect either of the three cardinal principles is to invite failure. I have heard the fallacious statement made that no operator can be sure that all cells are reached in the operation. An experienced and intelligent operator can determine the extent of the disease in all cases by exercising care in the study of the bony tissue as it is exposed. He can open the root of the zygomatic

process above the antrum and the meatus, and if there are diseased cells there he can remove them; he can extend the operation from there to the squamous portion of the temporal bone, and to the region in front of the external auditory process. The cells in the mastoid bone are more easily exposed, and there is no excuse for overlooking any of them.

When the petrous portion of the temporal bone is involved, the functional tests of hearing show a loss of hearing by bone conduction, or the hearing may be entirely lost on the affected side. Furthermore, an inspection of the promontorium of the inner wall of the middle ear may show an area of necrosis and granulation tissue, which should be thoroughly scooped out with a curette. If this is done a cure will probably follow, as the petrous portion of the bone is so dense there is little likelihood of the diseased process extending farther after thorough curettement. (See Surgery of the Labyrinth.)

The Arteries of the Middle Ear.—The middle ear receives its chief blood supply from branches of the internal carotid. The branches pass backward through the canaliculus carototympanici to the mucous membrane of the middle portion of the tympanic cavity. The middle meningeal artery sends a branch to the upper portion of the middle ear, while the A. stylomastoidea sends a branch to the postinferior portion and to the mastoid cells. As all these branches are quite small, they bear no special clinical significance so far as hemorrhage during an operation is concerned.

The External Landmarks of the Temporal Bone.—A study of the external contour and anatomical markings of the temporal bone in each individual case operated upon yields much valuable information concerning the deeper structures of the bone. The antrum can be fairly well located by observing the mastoid fossa with its numerous perforations, which give it a sieve-like or wormeaten appearance (Fig. 393). The initial opening through the bone should be made in this fossa. As the outer wall of the antrum is approximately one-half inch below the surface, it is still necessary to determine its position in relation to the postsuperior wall of the meatus. It is usually situated close to this wall; hence it is necessary to determine the direction it pursues from the surface of the mastoid process to the fundus of the ear. This is readily done by the introduction of a straight probe into the meatus against the postsuperior wall. Its direction is usually forward, downward, and inward. Whatever the direction, the opening in the mastoid fossa should be extended inward parallel with the probe as it stands against the postsuperior wall of the meatus. I have never known these guides to fail in locating the antrum. The suprameatal triangle (Fig. 393) is another fair guide to the antrum, though not as good as the mastoid fossa.

The location of the sigmoid sinus in its relation to the mastoid cortex and to the posterior wall of the external auditory meatus may be rather accurately determined by noting the contour of the mastoid process and the relation of its surface to the external auditory meatus. According to Whiting, the following landmarks are of great value in locating the lateral sinus:

A broad flat mastoid process sloping gradually toward the brow of the meatus, with the posterior wall of which it unites at a very slight angle, indicates that the sinus is not near the meatus. The gradual mergence of the surface of the mastoid surface into that of the posterior wall of the meatus also indicates that the sinus is deeply situated.

A convex rounded mastoid process is indicative of a superficially located lateral sinus. Caution should be exercised in opening such a mastoid process, lest the sinus be wounded.

A wide meatus entering the bone almost vertically to the mastoid surface is an indication that the sinus is located well forward close to the posterior wall of the meatus.

A dolichocephalic skull is indicative of large pneumatic cells, hence in such a skull the pneumatic cells of the temporal bone are liable to be widely distributed. In a case described by Whiting they extended toward the occiput and over the root of the zygoma as far forward as the apex of the glenoid fossa.

THE PHYSIOLOGY OF THE EAR.

I. **Membrana Tympani.**—The eardrum is stretched across the inner end of the external meatus, and is elastic enough to undergo considerable movement when the air in the meatus is alternately condensed and rarefied with Siegle's otoscope. The membrane is attached to a groove in the annulus, the sulcus tympanicus, by an extension of the periosteum of which the middle or fibrous layer is composed. The annulus tympanicus does not extend completely around the meatal opening, but is absent at the upper portion, the Rivinian segment. The part of the membrane attached to the annulus is known as the pars tensa or the membrana tensa. The part attached to the Rivinian segment is not stretched, but is loosely drawn, and is known as Shrapnell's membrane, the pars flaccida or the membrana flaccida. This portion of the membrane forms the outer wall of Prussak's space, while the pars tensa forms the lower portion of the outer wall of the tympanic or middle-ear cavity.

The membrane is not placed perpendicularly across the opening of the meatus, but forms an angle of about 140 degrees with the postsuperior wall, and one of 45 degrees with the antero-inferior wall. This is of clinical importance in the removal of foreign bodies from the meatus.

The function of the membrana tympani is to receive and convey sound-waves to the chain of ossicles, and thence to the labyrinth. That it is not absolutely essential to fair hearing is shown by the fact that good hearing is often present when the membrane is perforated or entirely absent. The eardrum also protects the tympanic membrane from the deleterious effects of the air and from the entrance of morbific germs and foreign bodies.

When the normal tension of the drumhead is distributed there is an impairment of hearing, hence any morbid condition of the Eustachian tube which interferes with the ventilation of the tympanic cavity, or any

inflammatory disease of the mucous membrane which interferes with the mobility of the ossicular chain, or any morbid condition of the drumhead itself which interferes with its elasticity or motility, will cause more or less deafness.

II. **The Eustachian Tube.**—The function of the Eustachian tube is twofold, namely, (*a*) to ventilate, and (*b*) to drain the tympanic and mastoid cavities. When these spaces are healthy, the Eustachian tube is adequate for the purpose. When, however, the spaces are inflamed, and the secretions are greatly increased in quantity, it is not large enough to accommodate the passage of the secretions into the epipharynx. When its capacity is thus overtaxed, the retention of the secretions causes pressure necrosis in the direction of least resistance, namely, the membrana tympani. Perforations thus arise in the course of infective inflammations of the tympanic cavity, the antrum, and mastoid cells. The Eustachian tube is generally large enough to carry off the secretions from the tympanic cavity, even when in a diseased state, but when in addition the antrum and mastoid cells are involved it is not capable of disposing of the secretions, retention occurs, and the pressure symptoms (pain, tenderness and swelling) of mastoid inflammation ensue. If the excess of secretions from the antrum and the mastoid cells are diverted from the tympanic cavity, the morbid process in it tends to get well because the tube is large enough to drain the secretions from the tympanic cavity. In other words, the retention of the secretions in any cavity tends to foster inflammatory processes in the mucous membrane, which may, in time, extend to the periosteum and the bone to which it is attached. (See Diseases of the Nasal Accessory Sinuses, the Clinical Anatomy of the Tonsils, and Heath's Mastoid Operation.)

The Tympanic Cavity.—The function of the tympanic cavity and its contents is to transmit sound waves to the labyrinth. It also forms a channel of communication between the Eustachian tube and the epipharynx, on the one hand, and the antrum and mastoid cells on the other. The cavity is divided into two spaces by the interlocking heads of the malleus and incus. The lower space is called the atrium, or the middle ear proper, while the upper is called the attic. The attic is still further subdivided by the heads of these bones into an inner and an outer attic. The outer space is divided into an upper and a lower space by the external ligament of the malleus (Fig. 334). The lower space is called Prussak's space, which, when it becomes the seat of suppurative inflammation, is difficult to cure. (See Suppuration of Prussak's Space.)

The inner wall of the tympanic cavity presents two anatomical features of physiological and clinical interest, namely, the oval and round windows. The oval window, the fenestra vestibuli, receives the foot plate of the stapes, which is surrounded by the annular ligament, and communicates with the vestibule of the labyrinth. The round window opens into the cochlea, and the membrane closing it forms an elastic valve to relieve the shock to the cochlea in the presence of excessive sound waves.

The Tegmen Tympani.—The roof of the attic, the tegmen tympani, consists of a thin bony wall which separates the tympanic cavity from

the cranial cavity. When there is a retention of purulent secretions, the periosteum and the bone it covers may undergo caries and necrosis, and thus expose the meninges and the brain to infection. (See Intracranial Complications and Sequelæ to the Middle Ear and Mastoid Diseases.)

The Tegmen Antri.—The tegmen antri, or roof of the antrum, is a little thicker than the roof of the attic, and is often the seat of necrosis and perforation in spite of this fact. This is probably due to the small size of the aditus ad antrum. Being small, it is easily occluded by the inflammatory swelling of its lining mucous membrane, and the usual destructive processes attending the blockage of mucous membrane-lined cavities ensue; that is, the infectious inflammatory process is perpetuated and is attended by the destruction of tissue in the direction

Fig. 334

Coronal section through the tympanum. *a*, extremity of the upper; *b*, extremity of the lower bony wall of the meatus; *d*, tegmen tympani; *e e*, attic, external portion, internal portion; *f*, malleus and superior ligamentum mallei; 2, incus; *h*, stapes within the fenestra vestibuli; *i*, promontory; *k*, Prussak's space; *m*, hypotympanic recess (cellar); *l*, scar in the lower half of the drumhead in apposition with the promontory; 2, incudostapedial junction. (After Brühl-Politzer.)

of least resistance, namely, the tegmen antri and the postsuperior wall of the inner end of the external meatus. Bulging and redness of the postsuperior wall of the meatus near the drumhead is, therefore, a common symptom of antral suppuration.

The Intrinsic Muscles of the Ear.—The tensor tympani muscle pulls the *handle of the malleus inward*, thus increasing the tension of the drumhead. This movement of the malleus is communicated to the long process of the incus, which in turn acts upon the stapes and compresses it into the oval window. Prolonged retraction of the membrana tympani is attended by a shortening of the tendon of the muscle, a condition which materially interferes with the cure of the deafness resulting from these conditions. The stapedius muscle acts in antagonism to the tensor tympani, and counterbalances the compression of the foot plate of the

stapes in the oval window. The membrana tympani, the circular ligament of the oval window, and the interposed chain of ossicles are thus poised to receive the sound waves and transmit them to the cochlea, where the impression is received by the delicately attuned organ of Corti of the cochlea, which in turn transmits the impression to the auditory centre of the brain, where it is perceived as sound.

It is apparent from the foregoing physiological data that it is of great therapeutic value to maintain free drainage and ventilation of the middle ear and its accessory cavities, and to prevent the morbid changes incident to the inflammatory processes of the middle ear.

The Physiology of the Sound-perceiving Apparatus.—The sound-perceiving apparatus is composed of the terminal nerve filaments of the labyrinth, the acoustic (auditory) nerve, and the auditory centre in the brain.

The Auditory Nerve.—The auditory nerve arises between the facial and glossopharyngeal nerves in the medulla oblongata, and passes into the internal auditory canal, in the fundus of which it divides into two branches; the vestibular branch (nerve) enters the vestibule, where it sends twigs to the utricle and the superior ampullæ of the semicircular canals; the cochlear branch (nerve) passes into the cochlea and gives off twigs to the saccule and to the ampulla of the superior semicircular canal.

The distribution of the auditory nerve in the cochlea forms a spiral ganglionic ribbon, the ganglionic cells being connected by medullated nerve fibers, the whole being supported on the membranous cochlea, which is attached to the osseous cochlea by fibrous bands. The membranous labyrinth is filled with a fluid called endolymph, and is surrounded by a fluid called the perilymph. The cochlear distribution of the auditory nerve is called the organ of Corti.

The Function of the Vestibular Apparatus.—Within the vestibule (saccule and utricle) the otoliths, acting upon the delicate hair-like prolongations, preside over the sense of the position of the head (body) in space. The angle of the impact of the otoliths upon the hair-like processes (the relative bending) creates a sensation which, being interpreted by the brain centres, gives conscious knowledge of the relative position of the head (body) to the line of gravity and consequently to the plane of the earth. In other words, they aid in the maintenance of equilibrium.

The Function of the Semicircular Canals.—These canals are the organs of coördinated movements, or statical sense, hence they are also a part of the apparatus presiding over the sense of equilibrium.

The Function of the Cochlea.—Corti's cells constitute the true terminal acoustic (auditory) nerve apparatus. They are about 2000 in number and are ciliated. The function of the cochlear apparatus is to perceive and differentiate sound waves, and convey them to the auditory nerve trunk, thence to the acoustic centres of the brain, where they are perceived as sound.

Shambaugh controverts the theory of Helmholtz that the basilar membrane is the resonator of the internal ear. According to Helmholtz, the fibers of this membrane vibrate in sympathy with the sound

PLATE X

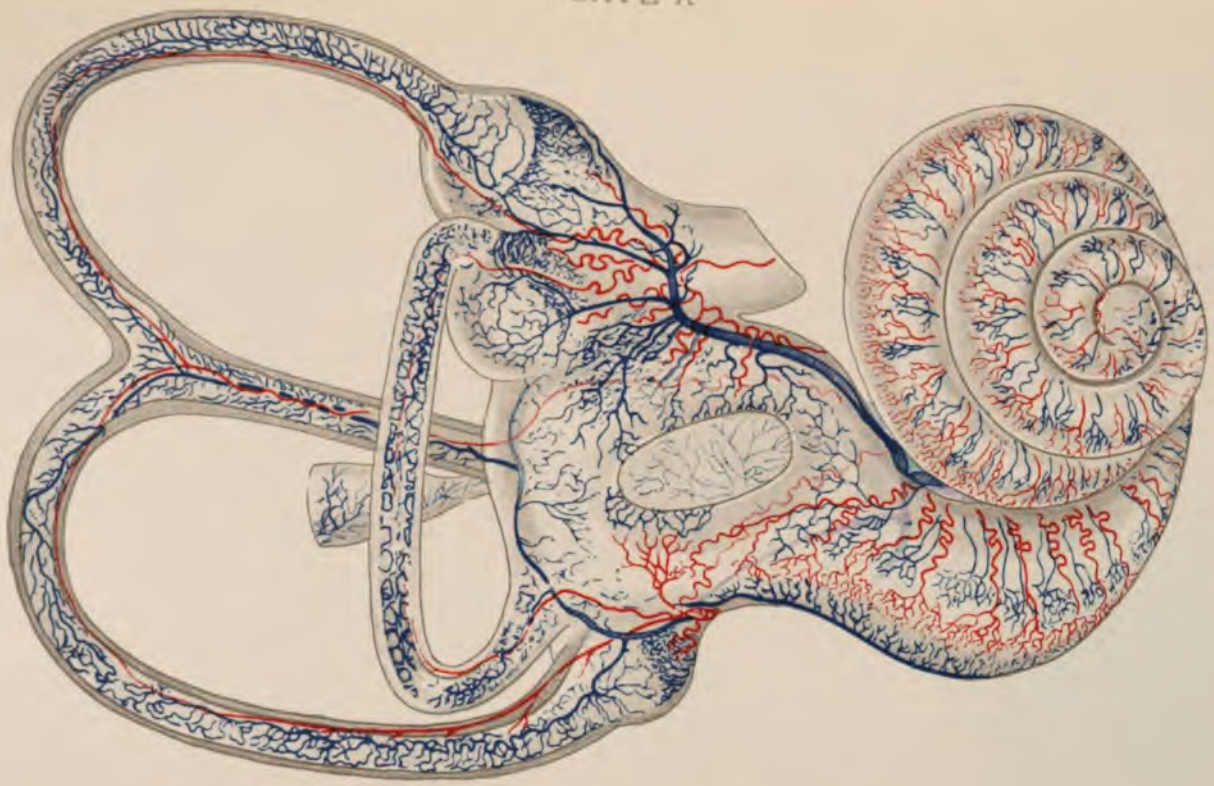

The Circulation of the Labyrinth. (Shambaugh.)

waves as they react upon the labyrinth and thus stimulate the hair cells of the organ of Corti. Shambaugh's conclusions are ingenious, and are as follows (Plate X):

1. "The hair cells of the organ of Corti are the real end organs wherein the physical impulses of sound waves are transformed into the nerve impulses, which result in tone perception.

2. "The perception for the various tones takes place in different parts of the cochlea, those of higher pitch being taken up by the hair cells located near the beginning of the basal coil, those of lower pitch by the cells near the apex of the cochlea.

3. "The stimulation of the hair cells is effected only through the medium of their projecting hair.

4. "The hypothesis that each hair cell acts as its own agent in selecting its stimulus from the impulses passing the endolymph is shown to be untenable for a number of reasons, chiefly, however, because the relation existing normally between the hair cells and membrana tectoria will not permit of these impulses in direct contact with the hair cells. I have shown conclusively that the hairs of the hair cells project normally into the under surface of the membrana tectoria.

5. "The stimulation of the hair cells is accomplished only through an interaction between the hairs of the hair cells and the membrana tectoria.

6. "The hypothesis of Helmholtz that this stimulation is brought about through the vibration of the fibers of the membrana basilaris is untenable, especially for the following reasons: In tracing the membrana basilaris toward the beginning of the basal coil in the vestibule this structure is found at a considerable distance from the lower end of the coil, and where a perfectly formed organ of Corti is still present to become so stiff and rigid as to render it incapable of vibrating. Even a complete absence of a basilar membrane in this locality is sometimes noted. The logical conclusion is that since the stimulation of the hair cells in this locality is accomplished without the intervention of a vibrating membrana basilaris, therefore the stimulation of the hair cells throughout the cochlea is not dependent on the vibration of this membrane.

7. "The logical conclusion is that the stimulation of the hair cells is accomplished through vibrations of the membrana tectoria transmitted to it by impulses passing through the endolymph.

8. "The membrana tectoria is shown to be so constituted anatomically as to be capable of responding to the most delicate impulses passing through the endolymph. Furthermore, the great variation in size of this membrane from one end of the cochlea to the other, together with its lamellar structure, suggests the probable physical basis which rênders it capable of acting the part of resonator by responding in one part to impulses of a certain pitch, and in another part to impulses of another pitch (Fig. 335).

9. "Finally, the pathological phenomena of 'tone islands,' 'diplakousis binauralis of dysharmonica,' and of 'tinnitus aurium' are all plausibly accounted for in this conception of the physiology of tone perception.

10. "To restate briefly the process by which the phenomenon of tone

perception is accomplished: The sound waves conducted from the air impinge upon the membrana tympani, producing vibrations in it. These vibrations conducted along the chain of ossicles transmit impulses to the intralabyrinthine fluid through the medium of the foot plate of the stapes. The impulses originating in the fluid in the vestibule pass directly into the scala vestibuli and through the membrane of Reissner

Fig. 335

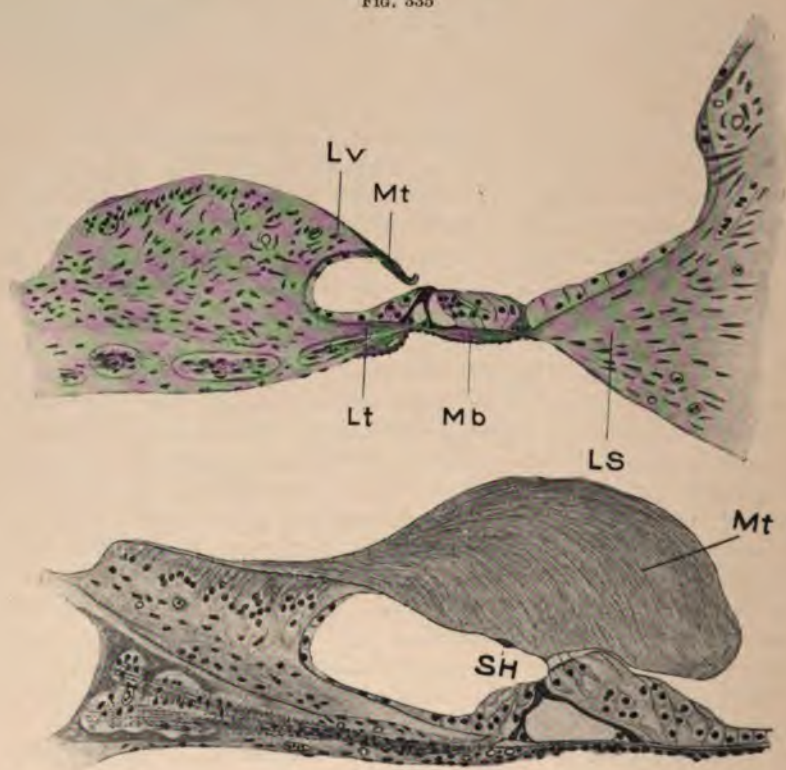

Lv, labium vestibularis; *Mt*, membrana tectoria; *Lt*, labium tympanæ; *Mb*, membrana basilaris; *LS*, ligamentum spiralæ; *SH*, striefen of Hensen.

to the endolymph, where sympathetic vibrations are imparted to the several parts of the membrana tectoria, depending on the pitch of the tone. The vibrations in turn stimulate the hairs of the hair cells which normally project into its under surface. The nerve impulses originating from all the hair cells thus stimulated by a particular tone come together in the brain centre in the cortex when the tone picture forms the final step in the process of tone perception."

CHAPTER XXXIII.

THE FUNCTIONAL TESTS OF HEARING.

THE value of the functional tests of the organ of hearing as aids in diagnosis and prognosis in diseases of the ear have for more than three generations been a controversial subject. In spite of this fact, they are still recommended by the great authorities on otology. Much discussion has arisen because of certain exceptions to the general rules laid down by various writers, or on account of an imperfect understanding of the principles underlying the physiological experiments. The fact that they have been used by three generations of otologists, and that they are now more generally used than ever before, is a fair indication of their utility and of their fixed place in otological practice.

I can do no better than quote Prof. A. Politzer in this connection: "The tests for hearing are of the greatest importance in the diagnosis of the diseases of the ear; for they serve not only to determine the extent of the disturbance of hearing, but not infrequently also to localize the affection, inasmuch as in cases in which the other objective methods of examination give a negative result we are enabled to judge whether the anatomical cause of the functional disturbance has its seat in the apparatus for the conduction of sound or in the nerve apparatus. But they are also of special value because by means of them, while the patient is under observation, we can note the course of the disease and also the result of treatment."

Some Physiological Facts.—(*a*) The normal range of hearing, in man, for musical tones is from 16 to about 48,000 vibrations per second. After the fiftieth year the upper limit of hearing is somewhat lowered. Persons seventy or more years old do not usually hear tones of more than 37,000 vibrations per second.

(*b*) **Paths through Which the Sound Waves Reach the Labyrinth.**—1. Sound waves reach the labyrinth chiefly through the tympanic membrane, the ossicles, and the oval window into which the foot plate of the stapes is inserted. The foot plate does not form a bony union with the oval window, but is attached to it by a fibrous membrane or ring. This allows it to vibrate in the window. Politzer demonstrated that the malleus performed the greatest excursions, the incus less, and the stapes least of all. Helmholtz found the greatest excursions of the stapes to be $\frac{1}{18}$ to $\frac{1}{14}$ mm. It is obvious that slight interference with the movements of the foot plate either by adhesive bands or ankylosis at the window will materially interfere with the transmission of sound waves to the labyrinth, and thus impair the function of hearing.

2. Sound waves also reach the labyrinth through the fenestra cochlea

(round) window, hence the function of the ear is not altogether destroyed when the foot plate is fixed.

3. Sound waves are also carried to the labyrinth to a considerable extent through the bones of the skull (Fig. 336). This explains the somewhat startling fact that deaf persons hear tolerably well if the speaker places the tips of his fingers against the forehead of the listener. Weber's well-known experiment demonstrates that when a tuning fork of 512 vibrations is placed upon the skull and the external meatus is artificially closed with the finger, the vibrating fork is heard much better on that side. In other words, bone conduction is thus increased. Though it is thus increased in intensity, it is still less than by air conduction.

Fig. 336

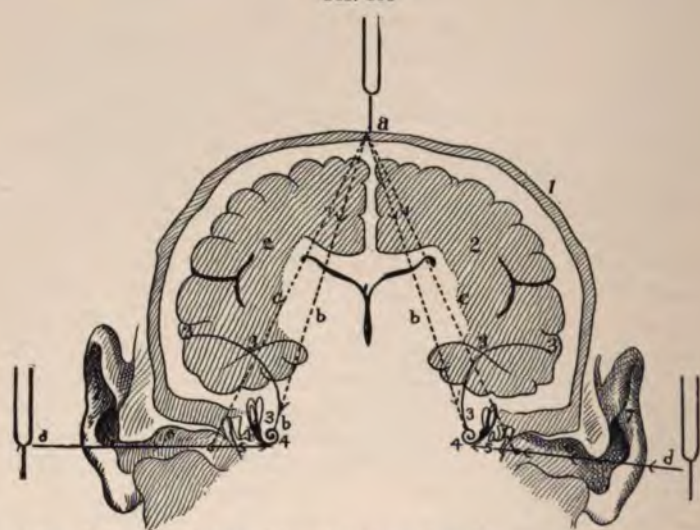

Air and bone conduction (schematic). 1, cranium; 2, cerebrum; 3, auditory nerve going to temporal lobe; 4, labyrinth; 5, tympanum and auricles; 6, auditory meatus; 7, pinnæ; *a*, tuning fork placed on the vertex; *a b*, osteal bone conduction; *a c*, craniotympanal bone conduction; *d*, tuning fork held in front of the ear; *d c*, air conduction. (After Brühl-Politzer.)

In the normal ear hearing by bone conduction for tuning forks is a little more than one-half of that for air conduction. The relative duration of hearing by bone and air conduction varies greatly with different forks of the same number of vibrations. It will also vary with the point of contact made with the fork. For example, it is heard a little longer when placed over the mastoid antrum than when placed on the tip. It is customary with most otologists to place it between these two points, just posterior to the external meatus. Politzer has called attention to the varying results obtained by forks of the same number of vibrations. Each set of forks should therefore be carefully and repeatedly tested upon normal cases, so as to establish their normal register. By *normal register* is meant the length of time the fork is heard in normal ears by bone conduction when placed over the mastoid just back of the external

auditory meatus, and the time it is heard by air conduction when held as near as possible to the auditory meatus. Gradenigo, at the London International Congress of Otologists, gave a scheme for the uniform record of the functional tests, in which he gives the registers of the forks used. This should be done by all observers. In this way the records will be of uniform standard and value.

(*c*) The tensor tympani and the stapedius muscles have long been regarded as the tension regulators of the ossicular chain, the stapedius counterbalancing the tensor tympani. A few years ago Dr. T. F. Rumbold wrote an article to the effect that they were the tone-selecting muscles of the ear, just as the ciliary muscles are the viewpoint selectors of the eye. In other words, that they are the focusing muscles of the ear. He says that through their action the ear is enabled to select a particular voice from a multitude of voices; and that they attune the drumhead to catch and transmit to the labyrinth the sound waves selected at will by the listener.

(*d*) The normal ears of a given subject perceive sound in its actual pitch. Both ears perceive it exactly alike. They perceive sound coordinate in pitch, timbre, and intensity. In certain pathological states one or both ears may get "out of tune."

Principles Underlying the Tests of Hearing.—1. The normal range of hearing is from 16,000 to 48,000 double vibrations per second.

2. When the conduction apparatus is diseased or obstructed, the power to hear high tones is impaired or lost.

3. When the perception apparatus is diseased, the power to hear high tones is lost.

4. The normal ear hears about twice as long by air conduction as by bone conduction. That is, a fork heard by bone conduction for twenty seconds will be heard about forty seconds when held close to the ear.

5. When the conduction apparatus is diseased or obstructed, bone conduction is increased and the time left in which the fork should be heard by air conduction is diminished; or bone conduction may be so much increased that the fork is heard longer than by air conduction.

6. When the perception apparatus is diseased, bone conduction is diminished or shortened, so that the relative time of hearing by air conduction is exaggerated.

The Practical Application of the Functional Tests.—We are now ready to discuss the application of some of the most approved physiological experiments pertaining to the ear, with the hope of arriving at some conclusion as to their value as aids in diagnosis and prognosis. It is not assumed by the writer that a correct diagnosis cannot usually be made, or at least fairly accurately *guessed at*, without the use of the functional tests. We grant as much. The only question herein discussed is as to the reliability of the tests in those cases in which there is some doubt as to the diagnosis. The otologist should, however, make constant use of the tests, in order that he may become skilful in their application and in his deductions therefrom. It is necessary, therefore, to make it a routine practice of applying them to all or nearly all cases

coming under the observation of the physician. The writer has for several years made this his practice in both private and clinical work, and he feels that he has been well rewarded for his trouble. The convictions herein expressed are based upon this experience.

The Watch Tests.—This instrument has long been used to test the acuteness of hearing, and is of more or less value. The patient may be able to hear the watch distinctly at about the normal distance, and yet not understand conversation, or *vice versa*. While it may not afford an accurate means of diagnosis, it is often the means by which comparisons may be readily made from time to time during the progress of treatment. In catarrhal inflammation of the middle ear, and especially of the Eustachian tube, the watch may be heard distinctly one day, and indistinctly, or not at all, another day. This variation is rather diagnostic of this type of ear disease, and is accounted for by the intermittent stoppage of the lumen of the tube and the subsequent absorption of the oxygen from the middle ear. When the tube becomes clear again air is restored to the tympanic cavity, and the normal tension of the drumhead and the ossicular chain is restored. I use two watches, one a high-pitched ticker, the other a low one. The low-pitched ticker is the one dollar Ingersoll watch, which can be heard at a distance of one hundred and twenty inches, while the high-pitched ticker (a Paillard's non-magnetic Swiss) can be heard at five feet.

Prout's method of recording the result of the test is used, *i. e.*, the number of inches the watch is heard by the normal ear is used as the denominator, and the distance at which it is actually heard as the numerator. Thus, if the Paillard, or high-ticker, is used, and is heard at ten inches, the fraction $\frac{10}{60}$ expresses the result. If the loud-ticker is used, and is heard at thirty inches, the fraction $\frac{30}{120}$ expresses the result. There are five ways of using the watch, namely: (*a*) Finding the distance at which it is heard upon approaching the ear; (*b*) placing it in firm contact with the auricle; (*c*) placing it against the mastoid process; (*d*) placing it between the teeth and noting in which ear it is heard the plainer, as in the Weber experiment; and, finally, (*e*) after first finding the distance at which the watch is heard upon approach, and then noting how much farther it can be heard upon withdrawing it from the ear. As before stated, Rumbold uses the latter test to ascertain a tonicity of the middle ear muscles. The writer has also used it for the same purpose for the last eight years and finds improvement in atonic cases following the administration of strychnine and iron, and rest and outdoor exercise. Whether this is due to increased tonicity of the muscles or other causes I will not attempt to state.

The Voice Test.—In 1871, Oscar Wolf published his conclusions as to the voice as a means of testing the organ of hearing. He found the letter R to be the lowest in the scale, having 128 vibrations per second, while the highest number of vibrations was given by S which gave from 5400 to 10,840 vibrations per second. Hence, by the use of these consonants we may test the hearing for the lower and within two octaves of the highest musical tones. With marked limitations this experiment may

be used to differentiate between disease of the middle ear and of the labyrinth. In other words, he found speech to be confined within about $6\frac{1}{2}$ octaves. The greatest strength and timbre belong to the vowel A which can be heard 252 m., and the smallest to the consonant H, which can be heard 8.4 m. distance. He classifies the various sounds and letters so that they may be used for testing purposes. There are several objections to this method of testing, in spite of the great amount of scientific investigation bestowed upon it by Wolf, Clarence Blake, and others. If words are used, the patient often hears the vowel sounds distinctly, and if numerals, he experiences the same difficulty with the additional one of attempting to infer the number by sequence. Then, too, there is the difference in quality, *timbre*, pitch, and carrying quality of the voices of different observers. This difference is less pronounced in the whispered voice, especially if it is given out with the residual air. In fact, when the whispered voice is used it should be given only with the residual air, thus rendering all voices more nearly alike. An intelligent application of this method will aid in diagnosis, and in noting the progress made under treatment.

Fig. 337

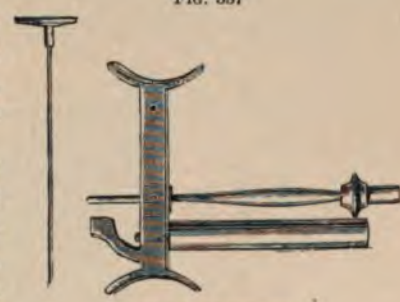

Politzer's acoumeter.

Dr. Harry Kahn recently called attention to Politzer's method of lengthening the room when it is too short to test he hearing by the voice. The examining surgeon, when at the extremity of the room, by turning his back to the patient increases the distance by one third. If the distance is still too short, it may be increased to two-thirds by turning the patient's bad ear to the opposite wall.

The Politzer Acoumeter.—This instrument (Fig. 337) was designed to take the place of the watch, or at least to supplement it, and can be heard at about 40 feet. All of the instruments are supposed to be of the same pitch and timbre, but in the mad rush of American dealers I fear little attention has been given to their exact construction. It is, however, a valuable adjunct to the watch tests, and may be applied in the same way, 40 feet being taken for the denominator, and the actual number of feet at which it is heard as the numerator. Politzer and Lucae claim it more nearly corresponds with the voice test than either the watch or the distance test with the tuning forks.

Many ingenious physiological tests of more or less value have been devised, but, after all, the most valuable are those made with the tuning forks and the whistles. We will now proceed to discuss some of the more valuable ones.

The Range of Hearing.—As already stated, the normal range of hearing for adults under fifty years of age is from 16 vibrations to 48,000 per second. After the fiftieth year this may be reduced to 37,000 per

second. In other words, the upper register is lowered by the changes incident to senility. The range of hearing varies in different individuals according to age and the pathological condition of the auditory apparatus. The lowest tones perceived are between 16 and 23 vibrations per second (Pyer), while the highest audible tone is e^8, with 40,960 vibrations (Landois and Stirling). In youth the upper limit is about one octave lower, or e^7, with 20,480 vibrations per second. In beginning senility it is about a^6 or 13,653 vibrations, while in very old persons it is near g^6 or 12,288 vibrations per second (Zwaardemaker).

The foregoing data should be borne in mind in estimating the probable significance of tests of the range of hearing, as it is apparent that there is no fixed upper limit of hearing, since it varies in the same individual at different periods in his life. There is also quite a distinct variation in different individuals of the same age. Any marked variation, however, from the above figures would in most instances indicate the presence of some pathological process within the auditory apparatus.

Fig. 338

Testing the hearing with the Galton-Edlemann whistle at eighteen inches

By referring to the third principle (p. 585) we find that high tones are diminished or lost in disease of the perception or nerve apparatus, hence, in applying this principle, the age of the patient should be taken into account. The upper limit of hearing is also lost in certain conditions of the middle ear, notably in marked retraction of the membrana tympani, whereby the foot plate of the stapes is forced inward against the labyrinthine fluid. This increased pressure so affects the terminal endings of the auditory nerve as to interfere with the perception of high tones. This condition can usually be differentiated from true labyrinthine or nerve deafness by inflation of the middle ear. This procedure usually restores the normal tension to the membrana tympani and the ossicles, and thereby relieves the increased intratympanic tension. The upper limit of hearing being restored, the diagnosis can easily be made.

The best outfit for making a complete test of the range of hearing is the Bezold-Edlemann set of forks and whistles. With these every musical tone from 16,000 to 48,000 vibrations can be tested. This is

very important in certain cases, especially in deaf-mutes. It is a well-known fact that a large percentage of so-called deaf-mutes are not totally deaf, but only to such an extent that they do not hear well enough to acquire speech. Then, too, some of them have oases of hearing, only perceiving certain tones in the entire range of hearing. In such cases these tones should be ascertained, and the patients should be trained to distinguish sounds, musical tones, and speech at these pitches. The information gained by this simple method may be made the avenue through which some of these poor unfortunates are brought within the range and influence of the greatest pleasure in life, namely, social conversation with their fellows. Hartmann's set of tuning forks (Fig. 339), while it is very abbreviated, answers very well for the ordinary examinations. It is not, however, free from overtones, and does not measure the lower range of hearing. The Galton whistle gives the upper range of hearing.

By referring to the second principle (p. 585), we find that in disease of the conduction apparatus the power to hear tones of the lower register is

Fig. 339

Hartmann's set of tuning forks.

impaired or lost. Loss of hearing for low tones is, therefore, usually a sign of tubal catarrh, middle-ear disease, or obstruction of the external meatus. It must not be forgotten, however, that the portion of the nerve apparatus concerned in the perception of low tones may be diseased, while the other parts are not affected. In this case the loss of low tones would not signify middle-ear disease. These cases are exceedingly rare, and would not, therefore, often confuse the observer.

The Weber Experiment.—This is one of the best-known and most reliable tests made with the forks. Weber's experiment consisted in placing the tuning fork c^2, 512 v., on the median line of the skull, and then closing the external meatus of one ear with the finger, under which condition he found the sound lateralized toward that ear. Clinically it has been shown that when the middle ear is diseased, or the external meatus is obstructed by cerumen or other morbid conditions, the sound for the vibrating tuning fork (when on the median line of the skull) is

lateralized to the affected ear; and that when the labyrinth is affected the sound is lateralized toward the unaffected ear. This rule, like all rules, has exceptions. If the middle ear and the labyrinth are both affected, there are manifestly two opposing conditions, one increasing and the other decreasing bone conduction (Figs. 340 and 341).

Fig. 340

Fig. 341

Fig. 340.—The Weber experiment with the c^2 tuning fork. The patient is deaf in the left ear and the sound lateralizes to the left ear, thus indicating disease of the sound-conduction apparatus of the left ear.

Fig. 341.—The Weber experiment with the c^2 tuning fork. The patient is deaf in the left ear and the sound lateralizes to the right or good ear, thus indicating disease of the perception apparatus (labyrinth) of the left ear.

In such cases dependence must be placed upon a much more extended examination. Indeed, dependence should rarely, if ever, be placed upon a single test.

Another exception to the rule, which has been noted by several observers, is often found in cases in which both middle ears are affected, but unequally. Ordinarily the fork is lateralized toward the side most affected, but the opposite is often true. Hence, in bilateral deafness the Weber experiment is not so reliable as in unilateral deafness.

In simple or uncomplicated *labyrinthine* disease, however, the fork is almost universally lateralized toward the good ear. Jacobson and Politzer have never seen an exception to this rule in undoubted cases. The test seems, therefore, to be a reliable one in this class of cases.

The *accuracy* of the Weber test will depend very much upon the fork used. In nearly all cases the best results are obtained with fork c^3, 512 v. Occasionally better results may be had with lower ones. Forks of more frequent vibrations should not be used, as they often give exactly the opposite result. They are, therefore, useless for making this test. In exceptional cases a c^2, 512 v., fork may not be at all adapted for this test. When we remember that a fork of a higher pitch should never be used, we can readily understand why a c^2 fork with marked overtones should not be used. The high overtones might so counterbalance the true tone of the fork that it would be a question as to which was referred to by the patient in response to the test.

According to Politzer, when the patient is in doubt as to which ear perceives the sound, the sound will be lateralized if ear specula are inserted in both external meatuses. He also calls attention to the fact that in double chronic middle-ear disease the sound of the fork may be lateralized to one side when placed on the vertex, and to the other when placed on the maxilla or the bridge of the nose.

The Weber test is, therefore, found to be the more reliable in unilateral middle-ear disease, somewhat less reliable in labyrinthine disease, and still less reliable in double chronic middle-ear affections.

The Schwabach Test.—The Schwabach test is made with a vibrating A fork, by first placing it upon the vertex of the examining surgeon until it ceases to be heard, and then transferring it to the vertex of the patient, note being made of the relative length of time the fork is heard by the surgeon and the patient. It has been shown by Siebenmann, Bezold, Hollinger, and others that in hyperostosis of the bony capsule of the labyrinth (spongifying), bone conduction for this fork is greatly prolonged, *i. e.*, ten to sixty seconds. In view of this fact, the Schwabach test is often of great assistance in diagnosticating this disease.

The Rinné Test.—In this test only the difference between bone and air conduction is recorded. For instance, if bone conduction is twenty-five seconds and air conduction is fifteen seconds, it is recorded negative Rinné, or Rinné—10″. If air conduction is ten seconds longer than bone conduction it is recorded positive Rinné, or Rinné+10″. If hearing by air conduction exceeds that by bone when applied to the deaf ear, there is nerve deafness; and when bone conduction exceeds that by air when the fork is applied to the deaf ear there is middle-ear deafness. This test is not so reliable as the Weber, but is nevertheless one that should always be used in conjunction with the other tests (Figs. 342 and 343).

According to Lucae the Rinné test is only reliable when hearing for whispered conversation is reduced to 1 m.

If there is *increase of bone conduction* to such an extent that a negative Rinné is obtained, the test is reliable. If, however, bone conduction is

only increased to a moderate extent and a plus Rinné is obtained, it does not afford much information. The more profound the deafness from the middle-ear disease the more reliable is the test.

If there is a *correspondence* between the results of the range of hearing, Weber, and the Rinné tests, the latter is additional proof of the pathological condition present. Thus if a patient complains of deafness in the right ear, and the Weber test lateralizes the sound to the right side, and the Rinné—10″, the Rinné corroborates the other tests and confirms the other signs pointing to middle-ear disease. There are many cases in which the diagnosis is in doubt when the information afforded by the various physiological tests renders the diagnosis clear. When, however, there is a minus Rinné, with duration of bone conduction also shortened, there may be some doubt as to the significance of the negative or minus Rinné. In such cases there may be present both middle and labyrin-

Fig. 342

Fig. 343

Fig. 342.—Showing the Rinné a' fork in position on the mastoid process in the Rinné test.
Fig. 343.—Showing the Rinné a' fork held close to the ear in Rinné's test.

thine disease. This apparently anomalous result is often very significant, and should lead to most careful investigation and to a very guarded prognosis as to the hearing. It is often the case that, through the very contradictions arising from the tests, we are enabled to arrive at a correct idea as to the location and extent of the pathological process.

In middle-ear disease, affecting one side only and of moderate degree, the Weber is the more reliable test.

In the *aged* the Rinné test is not so reliable, on account of the diminished bone conduction incident to senility.

In *marked deafness*, when the Rinné gives a positive result (plus Rinné), it is a fairly reliable sign of nerve involvement.

The tuning fork best suited for making this experiment is a', although it may be made with higher pitched forks. With higher forks than a' it is, however, difficult to eliminate hearing by air conduction. Unlike the

Weber, the lower forks are not suited to this test, as upon the mastoid the patient cannot so easily distinguish between the mechanical vibrations and the tone of the fork.

The fork used should have its *register* established by numerous experiments upon normal ears, and in publishing reports of cases this register should be named (unless the Bezold-Edlemann forks are used).

The Gellé Test.—This test is based upon the physiological experiment of compressing the air in the external auditory meatus, while the vibrating fork is upon the vertex. At the time of compression the perception for the tone of the fork is greatly diminished in a normal ear. This is due to the increased pressure within the labyrinth. According to Gellé, if there is ankylosis of the foot plate there will be no change in the tone; he therefore claims it is of value in diagnosticating this condition. On the other hand, if there is marked deafness and the tone is greatly diminished with each compression of the air in the meatus, it signifies that the foot plate is freely movable and that deafness is due to labyrinthine disease. The compression should not be made with the finger inserted into the meatus, but should be done with a Delstanche masseur and Siegle's otoscope, or some other contrivance which will drive the drumhead and the ossicles inward compressing the labyrinthine fluid, and even then it often fails to afford information.

Bing Test, No. 1.—This test is also used to differentiate between middle-ear and labyrinthine affections. The experiment is based upon the fact that when the tuning fork upon the mastoid ceases to be heard, it is heard anew when the external meatus is closed with the finger. In cases with pronounced deafness, if closing the meatus does not develop the tone anew, it is, according to Bing, a sign of middle-ear disease, whereas if it is heard again (in cases of pronounced deafness), it is a sign of labyrinthine disease. This test seems to be of value only in very severe deafness.

Bing Test, No. 2.—This test is usually referred to as the "entotic" use of the speaking tube. The purpose of the test is to differentiate between ankylosis of the foot plate of the stapes and adhesive bands or other pathological conditions which hinder the malleus and the incus in transmitting sound waves. The test is made by comparing the hearing of a patient through a speaking tube applied to the external meatus and one applied through the Eustachian catheter. If the patient hears better through the speaking tube by way of the catheter than he does through the external meatus, the inference is that the foot plate is freely movable, while the malleus and the incus are fixed or hindered in their vibrations. If such is the case, a rational treatment is at once suggested, *i. e.*, either the freeing of the malleus and the incus from the adhesions or other hindrances, or the removal of one or both ossicles, preferably only the incus. The sound waves might then reach the foot plate through the vibrations of the air in the tympanic cavity and hearing be materially improved.

CHAPTER XXXIV.

THE GENERAL ETIOLOGY OF DEFECTIVE HEARING.

DEFECTS of hearing may arise from any condition that affects the functional integrity of the conduction or the perception apparatus of the organ of hearing. It may be stated as a general law that the deeper (nearer the acoustic centre) the lesion the more profound will be the disturbance of hearing.

A. **Defects of Hearing Due to Lesions of the Auricle.**—This division of the subject may be passed by without analysis, as there is but slight impairment of hearing, even from the total loss of the auricle.

B. **Defects of Hearing Due to Affections of the External Meatus.**—(*a*) Inspissated cerumen. (*b*) Furunculosis. (*c*) Dermatitis. (*d*) Eczema. (*e*) Foreign bodies, animate and inanimate. (*f*) Exostosis of the meatus. (*g*) Collapse of the cartilaginous meatus. (*h*) Congenital atresia of the meatus. (*i*) Congenital absence of the meatus. (*j*) Cholesteatomatous material.

A glance at the foregoing analysis makes it apparent that hearing is diminished on account of the obstruction to the transmission of sound waves through the external auditory meatus and by the congenital absence of this canal. Congenital absence of the external auditory meatus is nearly always attended by absence of the middle and the internal ears, hence the deafness may be attributed more to the latter than to the former.

Cholesteatoma within the meatus is usually concomitant with the same process in the middle ear and the pneumatic cells of the mastoid, hence the defect of hearing is largely due to the condition of the middle ear and the mastoid spaces.

With these exceptions the obstructions in the meatus account for deafness. It should be said, however, that inspissated cerumen in the meatus is often a sign of middle-ear catarrh and the deafness may be partially due to this condition.

Collapse of the cartilaginous meatus is usually found only in the aged, and the deafness may be due in part to senile changes in the middle ear and labyrinth.

C. **Defects of Hearing Due to Affections of the Drumhead.**—(*a*) Perforation. (*b*) Thickening. (*c*) Calcareous deposits. (*d*) Cicatricial tissue. (*e*) Cicatricial bands extending to the ossicles and the wall of the middle ear. (*f*) Retraction. (*g*) Bulging or pouching. (*h*) Inflammation (myringitis). (*i*) Herpes. (*j*) Traumatic rupture. (*k*) Fracture of the handle of the malleus. (*l*) Atrophy (lack of normal tension).

It may be stated as a general acoustic law that anything which dis-

turbs the normal tension existing between the drumhead, the ossicles, and the labyrinthine fluid will result in an impairment of hearing. It should be noted that in nearly all of the foregoing conditions the normal tension is disturbed, hence the deafness.

In a number of the catalogued drumhead lesions there are, of necessity, pathological changes in the middle ear which in part account for the deafness. For example, perforation of the drumhead is nearly always attended by either chronic suppuration or cholesteatoma of the middle ear, and possibly of the attic, the antrum, and the mastoid cells. In thickening, scars, cicatricial bands, calcareous deposits, retraction, and atrophy, middle-ear disease, usually of a chronic inflammatory nature, is present, and in a large measure accounts for the defective hearing.

In simple myringitis, herpes, traumatic rupture, and fracture of the handle of the malleus, the middle ear is not usually involved and the deafness is transitory.

D. **Defects of Hearing Due to Affections of the Middle Ear.**—(*a*) Simple catarrhal otitis media. (*b*) Catarrh with adhesions. (*c*) Sclerosis of the mucous membrane. (*d*) Cholesteatoma. (*e*) Acute suppuration. (*f*) Chronic suppuration. (*g*) Ankylosis of the ossicles. (*h*) Ankylosis of the foot plate of the stapes to the oval window (fenestra of the vestibule). (*i*) Adhesive bands uniting the ossicles to each other, to the walls of the tympanum, and to the drumhead. (*j*) Atrophic otitis media. (*k*) Anemia of the mucosa occurring with general anemia and debility. (*l*) Loss of tonicity of the stapedius and the tensor tympani muscles. (*m*) Congenital defect or absence of the middle ear. (*n*) Granulations in the middle ear. (*o*) Serous and mucous accumulations. (*p*) Caries of the ossicles. (*q*) Caries of the walls of the tympanum. (*r*) Polypus. (*s*) Rarefying osteitis or spongifying of the bony capsule around the oval window.

In the foregoing conditions we find the commoner causes of deafness. The acoustic law given in the preceding section (C), namely, that the condition which disturbs the normal tension between the drumhead, the ossicles, and the labyrinthine fluid will cause deafness, applies with especial force to the affections in this section. All or nearly all the pathological lesions named do materially interfere with this tension, and thereby interfere with the transmission of the sound waves to the labyrinth. A study of these lesions will verify the general law enunciated at the beginning of this chapter, that as a general thing the deeper the lesion the more profound the deafness. For instance, a lesion affecting only the drumhead does not produce as profound deafness as occurs with ankylosis of the foot plate of the stapes

Sclerosis of the mucosa of the middle ear is often complicated with the same process in the bone beneath it. Chronic suppuration of the middle ear is also often attended by sclerosis (eburnation) of the bone.

This process may extend to the mastoid or to the bony capsule of the labyrinth, and thus augment the deafness.

The author has often seen cases in which the deafness was improved only after the administration of iron and arsenic. These were anemic

and suffering from general debility of a chronic type. Whether the improvement was due to an increased tone of the stapedius and the tensor tympani muscles, or to an increased tone and vital energy of the whole organ of hearing, would be difficult to determine. T. M. Rumbold inclined to the belief that the trouble was in the muscles. This may be true, as there may be a lack of muscular tonicity here as well as elsewhere in the body. It may be said with equal certainty that all the tissues of the body, including those of all parts of the auditory apparatus are lowered in tone and vital energy. We therefore incline to the opinion that the deafness due to or concurrent with general anemia, accompanied by seeming loss of muscular tone of the tension muscles of the middle ear, is probably due to a lowered vitality of all the parts concerned in audition.

Granulations and polypi in the middle ear not only interfere with the transmission of sound waves through the middle ear, but they often obstruct the external meatus also. They usually signify necrosis of the bony walls of the tympanum and an involvement of either the cranial cavity, the mastoid cells, the sigmoid sinus, the jugular vein, or the labyrinth.

Ankylosis of the foot plate of the stapes is a serious condition, inasmuch as it is very difficult to permanently overcome. The deafness and the tinnitus are pronounced and exert a depressing influence upon the patient. Great care should be exercised by the otologist in giving the prognosis in this class of cases. He should not hold out false hope of ultimate recovery, but he should so couch his language that the patient will not entirely abandon hope. It is the physician's office to cheer as well as treat his patients. This is doubly true in hopeless ear cases, as they are often despondent to the point of suicidal mania. Fixed attention arouses the benumbed organs, and even though a course of office treatment is not advisable, the patient should be told to observe under what conditions he hears most clearly and to seek to adapt himself to his environment. Expectant attention is thus aroused and the usefulness of the auditory apparatus is maintained at as high a level as is possible. In addition to the above, rest and the organic salts of iron should be administered.

E. **Defects of Hearing Due to Affections of the Eustachian Tube.**—(*a*) Catarrh. (*b*) Fibrous thickening of the mucosa. (*c*) Fibrous bands across the lumen of the tube. (*d*) Fibrous rings or stricture of the tube. (*e*) Lymphoid hypertrophy within the tube. (*f*) Hypertrophy of the mucosa. (*g*) General sclerosis of the mucosa. (*h*) Paralysis of the palatine muscles which regulate the patency of the mouth of the tube.

The chief function of the Eustachian tube being to maintain the equilibrium of air pressure between the air in the middle ear and that external to it, an obstruction to the normal passage of air destroys the equilibrium. The normal tension of the drumhead, the ossicles, and the labyrinthine fluid is disturbed, and deafness and tinnitus result.

It is not usually recognized that lymphoid hypertrophy plays a prominent part in Eustachian obstruction. This must be true, however,

as there is a considerable quantity of such tissue in the mucosa of the tube, especially near its pharyngeal end. The same pathological processes which cause hypertrophy of the pharyngeal and the faucial tonsils will also cause hypertrophy of the tubal lymphoid tissue. We may, then, speak of a tubal or "Eustachian tonsil" as a cause of Eustachian obstruction.

In long-continued catarrhal or suppurative inflammations of the middle ear, fibrous thickening or fibrous bands may form in the Eustachian tube and give rise to persistent deafness and tinnitus unless relieved by suitable treatment. Air not being admitted to the middle ear in sufficient quantity, the drumhead becomes retracted on account of rarefaction of the air within the middle ear, the handle of the malleus is drawn inward and rotated on its axis, and the chain of ossicles is forced inward and compress the labyrinth fluids. Perhaps a more correct statement would be to say that the normal tension between the drumhead and the labyrinth is lost, and deafness and tinnitus result.

Tubal catarrh (salpingitis) is much more common than is generally supposed, and no doubt many of the so-called cases of middle-ear catarrh are in reality of this type.

Since the normal patency of the tubes is controlled by the palatine muscles, any condition which affects their innervation or motility will cause defective hearing. These conditions will be considered in the next section.

F. **Defects of Hearing Due to Affections of the Epipharynx and the Fauces.**—(*a*) Postnasal adenoids. (*b*) Epipharyngeal catarrh. (*c*) Polypi or other neoplasms. (*d*) Disease of the faucial tonsils. (*e*) Adhesions of the anterior and the posterior pillars of the fauces to the tonsils. (*f*) Suppurative inflammation of the epipharynx. (*g*) Paralysis of the palatine muscles (*e.g.*, postdiphtheritic). (*h*) Infections occurring during the course of the exanthematous fevers.

In this category are conditions which are fruitful sources of ear diseases and which are attended by impairment of hearing. All inflammatory conditions which involve the mucosa about the pharyngeal orifices of the tubes sooner or later extend within their lumens and cause more or less obstruction. If the inflammation is of a suppurative type, the germs enter the tube and the middle ear, and may eventuate in an acute suppurative otitis media. This may become chronic, and cause permanent damage to the entire middle-ear apparatus.

Postnasal adenoids are recognized as frequent antecedents of tubal and middle-ear catarrh and deafness.

The discussion has often run high as to whether adenoids extended over the mouths of the Eustachian tubes. The free extremities of the lateral adenoid masses do, no doubt, often occlude them. Perhaps a more important pathological factor is that postnasal adenoids are usually attended by pronounced postnasal catarrh, which in many cases becomes purulent in character. This often causes obstruction of the tubes and thus give rise to pronounced disturbances of hearing as well as to structural changes in the middle ear and its appendages.

The etiological relationship existing between hypertrophy of the faucial tonsils and disease of the Eustachian tube and the middle ear has long been recognized, although not as fully as it should be. Their relationship cannot be considered apart from that of the postnasal space, however, as the same conditions which affect one affect the other also. Thus the presence of enlarged faucial tonsils is usually attended by postnasal adenoids. Both being lymphoid tissue, they respond to the same irritation and enlarge simultaneously. Notwithstanding this fact, there are some conditions of the faucial tonsils which cause tubal obstruction independent of any effects due to postnasal adenoids (C. R. Holmes).

The presence of diseased or enlarged tonsils produces chronic hyperemia of the mucosa of the epipharynx, and oftentimes a chronic catarrhal or suppurative inflammation is present. Enlarged and diseased tonsils do not always stand out beyond the pillars of the fauces. A normal tonsil can neither be seen nor felt. Many of the pathological tonsils are flat and lie hidden behind the anterior pillar. Pynchon has called them "submerged tonsils." He has also suggested that if they are examined "on the gag," they will bulge forward and inward and come into full view. When thus examined they are seen to be broad and flat with an irregular surface. In some cases the lacunæ are filled with debris, epithelium, bacteria, and pus, while in others no such accumulations are to be seen. This does not prove that they are not present in the pockets or lacunæ, as upon introducing a tonsil hook into them yellowish round masses may be removed. In others the masses are encysted, probably from inflammatory closure of the mouths of the lacunæ. The point I wish to make is that, even though the tonsils do not project beyond the pillars and are not apparently much diseased, they may be the seat of foci of infection, irritation, and septic material, which give rise to chronic catarrh of the epipharynx and the Eustachian tubes. The material in the lacunæ affords a good medium for the growth of bacteria, the toxins of which enter the lymphatic and the blood-vascular systems and cause disturbances in remote parts of the body.

G. **Defects of Hearing Due to Mastoid Affections.**—As these conditions are secondary to and associated with pathological changes within the middle ear, they will not be discussed.

H. **Defects of Hearing Due to Labyrinthine Affections.**—(*a*) Extra tension of the labyrinthine fluid from great retraction of the drumhead. (*b*) Inflammation of the labyrinth. (*c*) Congenital defects. (*d*) Hemorrhage. (*e*) Drugs. (*f*) Necrosis. (*g*) Tuberculous or syphilitic disease. (*h*) Hyperostosis or spongifying of the bony capsule of the labyrinth. (*i*) Certain neuroses cause more or less pronounced deafness or other disturbances of hearing.

Increased tension of the labyrinthine fluid produces deafness. The increased tension is usually due to extreme retraction of the drumhead, whereby the foot plate of the stapes is forcibly driven inward against the contained fluid within the bony labyrinth. If there are no firm adhesions binding the drumhead and the ossicles in this position, it may

be readily overcome by inflating the middle ear. This at once relieves the deafness and the tinnitus.

Congenital defect of the labyrinth is quite commonly found in deaf-mutes. It has been learned from careful functional examination that while they are deaf to most tones, there will be others which they can hear very well. (See Deaf-mutism.)

True, Ménière's disease is thought to be due to an apoplectic form of hemorrhage into the labyrinth. Few postmortems have been made corroborative to this belief. The clinical history of the cases, however, is in accord with this idea.

Syphilitic and tuberculous inflammations of the labyrinth are destructive, not alone to the hearing, but to the tissues as well.

The excessive administration of quinine is sometimes attended by pronounced deafness which may continue for several months, or even permanently. It is probably due to an anemia or a congestion of the labyrinthine membrane and the auditory nerve endings.

Rarefying osteitis of the bony capsule of the labyrinth causes pronounced deafness, which is usually gradually progressive. It is commonly found in early adult life and does not yield to treatment. (See Hyperostosis of the Bony Capsule of the Labyrinth.)

CHAPTER XXXV.

FOREIGN BODIES IN THE EAR. CERUMINOUS PLUGS IN THE MEATUS.

CHILDREN often introduce foreign bodies into the ear for very different reasons from those which may be ascribed to adults. For example, children in their play and in the spirit of imitation will do what they conceive is being done by others. Their elders, in order to excite wonderment and admiration, will do sleight-of-hand performances, pretending to remove a knife or other object from the nose, mouth, or ears. Children are thus led to introduce various objects into their ears. Peas, beans, beads, gravel, buttons, bits of sealing-wax, chewing-gum, cherry pits, etc., are commonly found in the ears of children. Burnett relates a case of a woman from whom a bead was removed that had been introduced sixty years previously. Children are fond of the sensation of a smooth body, as a bead or bean, rubbed over the skin, and in this way they sometimes accidentally introduce foreign bodies into the external meatus.

These may remain in place for a long time without causing any serious symptoms, and be overlooked by their parents and unnoticed by the child.

In *adults* the introduction of foreign bodies into the external meatus is more apt to be accidental, or the result of some treatment, as the introduction of a bit of cotton which is allowed to remain long after it has served its original purpose. Bits of pencil, toothpicks, twigs, and straw may be introduced into the meatus during efforts to remove cerumen or moisture, and remain in the meatus until symptoms arise which cause them to seek relief from their family physician.

Animate objects, such as roaches, fleas, flies, rosebugs, bedbugs, ixodix honimos, house-fly maggots, Texas screw-worms, and other living parasites are the source of great agony and discomfort when they enter the external meatus, on account of the clawing and twisting motion incident to their efforts to get food or gain egress from the cavity. The mode and place of sleeping influence the introduction of such objects into the meatus, as sleeping outdoors in a hammock or upon the ground, thereby inviting such living insects to make their abode in this cavity.

J. F. Church narrates a case in which a sheeptick had been in a stockman's ear for two years. It was embedded beneath a mass of cerumen and blood, and was still living when removed. The sensation was that of an intolerable scratching, accompanied by excruciating pain and deafness, which would suddenly pass away. There would be intervals

of a month or more in which there would be no pain or discomfort in the ear. At times he removed blood clots admixed with cerumen. When he came under the observation of Dr. Church the pain was severe, and had been for about four days, and extended to the mastoid region. There was a feeling of numbness over the corresponding side of the face. The meatus was filled with cerumen and epithelium, which was removed with a spud and a syringe. This being done, the deeper portion of the meatus was exposed to view, and a moving body was seen, which presented the appearance of a perforation in the drumhead, as he thought, with slender maggots protruding through it.

The Texas screw-worm fly, or Compsomyia (Lucilla) macellaria, has been thought to be of Mexican or South American origin, although Dr. Williston, of Yale College, writes that "It grows especially from Canada to Patagonia." Its chief centre in the United States, however, has been in Texas, hence its name.

Its ravages among cattle are common, and often occasion heavy financial loss by the destruction of its victims. It more rarely invades the human family, but has been known to cause death in a number of instances. Its favorite point of attack in the human is the ear or the nose. This is easily understood when it is known that the insect is attracted by foul-smelling odors. Those, therefore, affected with ozena or chronic otorrhœa are especially liable to be invaded. The worm in the act of invading the tissues performs a sawing motion, and can penetrate bone. Mackenzie reports cases in which the cranial cavity was penetrated by them, causing death from meningitis.

FOREIGN BODIES IN THE EAR.

Treatment.—It is important in this connection that a caution be given as to the great harm that may be done by unwarranted, unskilful, or untimely efforts to remove foreign bodies from the external meatus. It should be remembered that foreign bodies, especially inanimate ones, can do little or no harm so long as they are left undisturbed in the meatus. This, of course, is not true for an indefinite period of time, but it is true in the sense that there is no need of haste on the part of the attending surgeon. More harm has been done to patients by the efforts to remove foreign bodies than has ever been produced by the presence of these bodies by themselves in the meatus. If a foreign body is smooth and is causing no pain or discomfort, there is certainly no occasion for its hasty removal; if it is a rough one, and is causing considerable pain and discomfort, there is more excuse for its immediate removal; but even then it may be much wiser to first allay the irritation and swelling, after which it may be removed with comparative ease with either the syringe, snare, or forceps.

I have seen cases in which the meatus was swollen and red from the unskilled attempts of members of the family to remove an object. While thus swollen it was impossible for me to remove the foreign body with-

out great pain. In such instances I have first used antiphlogistic remedies and soothing applications for a few days, after which it was comparatively easy to remove the foreign body without any great difficulty or pain to the patient. If an insect or other live body gains entrance to the meatus, the first step to be taken is to render it lifeless, after which its removal can usually be effected with a syringe.

Having thrown out this warning against meddlesome or unintelligent attempts to remove inanimate foreign bodies, we will discuss the best methods of procedure for their removal.

1. First inspect the meatus in order to determine whether or not a foreign body is present, and if present, its probable nature. This is important, as the method of procedure for its removal will depend largely upon the character of the body present.

2. Notice whether irritation or inflammation of the parts is present, and whether it is probable that the body will do harm by remaining a few days or hours longer; and also as to whether it is probable that if immediate steps for its removal are taken, the effort would be rewarded by success. If the parts are swollen and inflamed to such an extent as to make it impracticable to remove it at once, it is better to wait until the swelling and inflammation are reduced by the use of hot, soothing lotions, such as boric acid solution, and by the application of leeches to the tragus. After a few hours, or at the most a few days, the swelling and painful condition will have subsided, thereby rendering the removal of the offending object a matter of comparative ease and with little discomfort to the patient.

3. Syringing should first be tried, as the stream of water may be forced into the meatus beyond the foreign body, and forced from the external auditory meatus. The position of the head should be considered in this and other methods of procedure, as the force of gravity will oftentimes materially aid in the removal of the object. The head should, therefore, be inclined toward the affected ear. Zaufal found, in 109 cases of foreign bodies in the external meatus, that he could remove 92 of them with the syringe, thereby demonstrating that nearly 90 per cent. of the foreign bodies in the meatus may be removed by this method. I fear that in the average practitioner's experience 90 per cent. of the removals have been attempted with either forceps or the so-called "ear hook;" whereas the 90 per cent. of successful efforts should have been made with a syringe, while in the other 10 per cent. it may have been proper to resort to the forceps and ear hook.

4. The agglutination method was recommended by Riverias in 1674, and by Celsus in 1806, being revived by Löwenberg in 1872. It consists in applying some heavy glue to the end of a piece of tape or a camel's-hair brush, which is then applied to the foreign body in the external meatus and left there until the glue becomes so firmly fixed as to bring the foreign body with it when traction is exerted upon it. This is probably one of the best methods, for most of the cases after syringing has failed. It is to be recommended on account of the absence of instrumentation, whereby the meatus is so often seriously injured.

A strip of adhesive plaster may be introduced into the meatus, applied to the foreign body and heated by focusing the rays of light upon it with a convex lens. This softens the adhesive material and allows it to become fastened to the foreign body, after which it may be removed by traction upon the adhesive strip.

The agglutination method is not used as often as it should be, as most physicians seem to think that a pair of forceps or the foreign body hook, which usually accompanies the pocket-case purchased upon graduation, are the instruments *par excellence* for this purpose.

5. The foreign body hook is, perhaps, less harmful in the hands of an inexperienced operator than the forceps, and is, therefore, to be recommended as a better instrument for the removal of foreign bodies from the external meatus. It should be so introduced as to allow the short hook to pass inward with its side against the wall of the meatus until it passes beyond the foreign body, when it should be rotated so as to bring the hook back of the foreign body. Slight traction should then be made upon it, with a view of dislodging the foreign body from its position in the meatus. If it fails to do this, it should be withdrawn and re-introduced in another position, hoping thereby to find a point at which the body may be loosened. If the foreign body has passed beyond the isthmus of the meatus and lodged in the recess formed by the membrana tympani and the floor of the meatus, the hook should be introduced above the foreign body, as there is greater space at this point for the outward movement of the impacted mass. The convexity of the floor of the external meatus forms a favorable fulcrum upon which the lower portion of the foreign body rests, while the upper portion makes the outward excursion. If will be necessary, however, in some cases to introduce the hook either posteriorly or anteriorly in order to slowly dislodge the mass from its fixed position. After this has been done the hook should be introduced above the mass, completely dislodging it from its point of impaction. Its removal through the cartilaginous meatus may then be accomplished with ease and little discomfort to the patient.

6. Various foreign body ear forceps have been devised and placed upon the market, none of which serve a very useful purpose. Young practitioners have great satisfaction in the thought that they have a full equipment at their command for the removal of foreign bodies from the ear. Beyond the satisfaction they thus afford, the instruments are of little value. It is with such instruments that untold harm and irreparable damage have been done, and not a few lives have been sacrificed to the enthusiasm of their owners. The foreign body has, in many instances, been forced through the drumhead into the middle ear, where the physician has left it, only to be discovered at a later period during a mastoid operation.

After a time its presence in the middle ear gives rise to necrosis and serious infection, followed by intracranial complications, such as abscess, meningitis, or sinus thrombosis, thrombosis of the jugular vein, labyrinthine necrosis, or transmission of infective thrombi to the lungs, the spleen, or the kidneys.

Having thus briefly, but pointedly, suggested the dangers attending the use of foreign-body forceps, it may be said that they have a useful place, limited though it be, in the armamentarium of the physician.

The cautions given above are not for the purpose of discouraging the practitioner from using the foreign body forceps, but are intended to lead him to use them with great circumspection after having tried all other means for the removal of the foreign body. Those devised by Dr. Samuel Sexton are, perhaps, the best upon the market (Fig. 344). They are so constructed that the toothed tips may be introduced at the sides of the body, while the blades remain practically parallel with the walls of the external meatus; this is a point of no small importance when we remember that most forceps for this purpose are so constructed that when the blades are spread apart the tips are at such an angle as to be easily forced into the meatal walls as they are pushed inward beyond the foreign body. Whatever instruments may be used, great care and delicacy of manipulation should be exercised, so as to avoid serious laceration of the meatus.

Fig. 344

Sexton's foreign-body forceps.

If the foreign body is removed the laceration will be of small moment, as it can be properly treated and quickly healed; if, however, the efforts to remove the foreign body are unsuccessful, the laceration may become a very serious complication, as the parts cannot, for obvious reasons, be properly treated. Swelling, infection, and inflammation may take place, which will still further interfere with the removal of the foreign body. Great discomfort results, and the condition is a serious menace to the well-being of the patient.

7. *Postauricular incision* for the removal of foreign bodies is a very ancient method of procedure, as Paul of Aegina suggested its use. Von Tröltsch, in his text-book on *Surgical Diseases of the Ear*, suggested that in infants the incision is most effective when made above the auricle in the squamous region, as this position is depressed at that age, thus admitting of easy access to the meatus without injuring the postauricular artery. He thinks the injury to the artery should not be

done needlessly, as it is an important source of nutrition to the auricle. With our more improved methods of surgery and asepsis, we do not now fear an injury to this artery, and would not, therefore, make the incision above the auricle with this object in view. The incision in this position is, however, undoubtedly best adapted for the removal of foreign bodies which cannot otherwise be removed from the meatus of an infant on account of the oblique angle it forms with the squamous plate. The roof of the osseous meatus is gradually formed by the development of the squamous bone, and extends inward at an obtuse angle, thus affording a favorable field for the introduction of instruments for the removal of foreign bodies. In adults, von Tröltsch suggests that the incision should be made inferior to the meatus, as its roof is now at right angles to the squamous plate.

With the antiseptic and aseptic methods now in vogue there should be little hesitancy in making a free incision in much the same manner as described for mastoid operations. The wound can be closed at once, union by first intention taking place. The cartilaginous meatus should be separated from the bone as in the mastoid operation and lifted from its position. The foreign body is thus fully exposed to view on all sides, the meatus is shortened and enlarged, and instrumentation for its removal becomes comparatively easy. The patient should be under the influence of a general anesthetic. A portion of the osseous meatus should be chiselled away, if necessary, in order to facilitate the removal of the foreign body.

Urbantschitsch reports a case of an oat husk which entered the Eustachian tube while the patient was chewing an ear of grain. It passed through the tube into the middle ear, and thence into the external meatus.

ANIMATED FOREIGN BODIES IN THE EAR.

Treatment.—Great concern is usually occasioned by the entrance of an insect or other animate body in the external meatus, on account of the clawing and scratching and penetrating movements attending its presence. Great noises of the most distressing and horrifying character are sometimes present, due no doubt to the clawing and scratching against the drumhead. On account of the great mental disturbance of the patient, the physician should have well-formulated ideas as to the proper methods of procedure for the removal of the insect, as he will otherwise be led to resort to methods in his haste and anxiety which will probably be unsuccessful and will only add to the pain and discomfort of the patient. I would, therefore, make the following suggestions:

(*a*) Avoid the use of instruments. It has been found by experience that animate objects are not readily removed by the use of forceps or other instruments. They have the power of clinging tenaciously to the skin of the meatus with little hooklets in the case of maggots, and with the feet in a case of fully-developed insects.

(*b*) Drown the insect. This can usually be done with oil; if oil is not at your command, water may be used instead. If maggots are within the meatus, a 50 per cent. solution of chloroform should be used for this purpose, as oil or water seems to have little power to cause their death.

(*c*) If for any reason it is desired to immediately remove them without waiting to render them lifeless, the syringe should be resorted to, as in this way they may sometimes be removed with great ease. On the other hand, the method is oftentimes not successful until they have been rendered lifeless by drowning in the water. If maggots are present, the fumes of chloroform blown into the ear from the bowl of a pipe will almost instantly render them lifeless. Solutions of chloroform may also be dropped into the ear for this purpose with more certain results. After they are rendered lifeless the insects or larvæ are easily removed with the syringe, and it will rarely be necessary to resort to the use of forceps. Should it become necessary, however, to resort to their use, they should be used with great caution, as otherwise a very serious injury to the meatus and drumhead may be inflicted. The use of chlorinated water is of special value in rendering them lifeless, and especially the larvæ. It is not, however, as efficacious as chloroform.

(*d*) The agglutinative method may be used for the removal of dead insects from the ear, as described under Foreign Bodies in the Ear. Forceps may be used likewise, but are only mentioned in this connection for the purpose of condemning their use, except in very rare instances.

FOREIGN BODIES IN THE EUSTACHIAN TUBE AND MIDDLE EAR.

Mayer[1] reports three cases of foreign bodies in the Eustachian tube: one, a grain of corn, was in the bony portion of the tube, while the others were in the cartilaginous or faucial end. They may enter the tube either through the middle ear or the epipharynx. If there is a perforation in the drumhead, a small grain or other substance may enter the middle ear through it, and thence pass to the Eustachian tube. Foreign bodies which are unskilfully or roughly handled in the effort to remove them from the external auditory meatus may thus be driven into the middle ear, from whence they may gain entrance into the Eustachian tube.

The use of Eustachian bougies has, in the past, been a fruitful source of foreign bodies in the tubes from accidental breaking while being used. Formerly the bougies were armed with feathers, cotton, or hair, for the introduction of medicaments, and were, consequently, more liable to be broken in the tube. Better and smoother instruments are now used, hence the accident occurs less frequently.

Voltolini has recommended the galvanocautery for the removal of firmly embedded organic substances, as beans, etc., from the meatus and the middle ear. At various sittings small portions are thus destroyed,

[1] Monatsschrift f. Ohrenheilkunde, Jahrg. iv, Nr. 1.

until the whole is finally disintegrated and removed. This method of procedure should be attempted with great caution, as there is considerable danger of exciting inflammation of the contiguous parts.

If the foreign body is so deeply and firmly embedded in the middle ear as to render it impossible to remove it by simple and direct methods, the postauricular incision, such as is described under mastoid operations, should be made, and, if necessary, a portion of the bone of the meatus may be chiselled away. Having thus exposed it, an attempt should be made to remove it with a stream of water. Should this fail, forceps may be used.

Foreign bodies in the cartilaginous or faucial end of the Eustachian tube may sometimes be seen with a postrhinoscopic mirror as they protrude from the mouth of the tube. In such cases it is often possible to seize the protruding end with a pair of curved forceps introduced through the mouth and thus remove it. If this cannot be done, the drumhead may be perforated by means of a V-shaped incision, if a perforation does not already exist, and the air forced into the middle ear by means of a Politzer bag or other compressed-air apparatus with a suitable tip, which is applied at the external meatus. In this way the current of air may be made to enter the Eustachian tube and force the foreign body from the pharyngeal orifice.

CERUMINOUS PLUGS.

Cerumen is the product of the ceruminous glands, located chiefly in the cartilaginous portion of the external auditory canal. A few glands are also present at the commencement of the osseous portion of the canal. The cerumen is normally thrown off by the movements of the mandible (inferior maxilla) and by the exfoliation of the epidermis lining the canal. When, however, from any cause the secretion becomes excessive in quantity, more tenacious in quality, or its discharge is mechanically obstructed, ceruminous plugs form in the canal and give rise to more or less disturbance of hearing.

Etiology.—The etiology may be studied under (*a*) diseases of the canal and middle ear; (*b*) obstructive lesions of the canal; (*c*) modifications in the character of the ceruminous secretion; (*d*) foreign bodies in the canal; and (*e*) improper methods of washing the ear.

(*a*) The diseases of the canal and middle ear which cause ceruminous plugs may be subdivided into hyperemia of the skin of the canal, diffuse and circumscribed eczema, and suppurative otitis media.

(*b*) The obstructive lesions of the canal are congenital, as a tortuous canal, and acquired, as membranous bands or rings from inflammatory processes, and hyperostosis and exostosis of the canal.

(*c*) Modifications in the character of the cerumen, as an increased adhesiveness and the admixture of epithelium and hairs cause the retention of the cerumen.

(*d*) Foreign bodies in the external canal form the nuclei of ceruminous

plugs. They may be solid substances, as beads, small stones, etc., or they may consist of dust, sand, or other finely divided particles.

(*e*) Improper methods of washing the ears are often responsible for the presence of ceruminous accumulations in the canal. Irritating soap-suds is introduced, the epidermis macerated in it, and the glands overstimulated. A mild dermatitis results. On top of all this the corner of a towel or a washrag is twisted and screwed into the meatus, causing still further irritation, and oftentimes pushing the cerumen into the osseous portion of the meatus, where it remains, forming a nucleus for still more extensive accumulations.

Symptoms.—The symptoms vary according to the degree of occlusion, the position of the plug, the amount of secondary irritation and inflammation, and the preëxisting or associated lesions in the middle ear and labyrinth.

If the occlusion of the canal is incomplete in an ear which is otherwise normal, there will be but little *impairment of hearing;* if, on the other hand, the canal is entirely closed, there is marked diminution of hearing. If the plug is dislodged into the fundus of the canal against the drum membrane, the disturbance of hearing and the discomfort are much greater. In some cases the plug is accompanied by severe *inflammatory reaction* of the tissue immediately contiguous to it, which adds to the discomfort and the impairment of hearing. Reflex pains in the mastoid region are not uncommon in this condition.

If suppurative inflammation of the middle ear and the mastoid cells is associated with the ceruminous plug, the symptoms are modified accordingly; that is, there is a commingling of the symptoms of the two conditions.

Pain is a symptom which is present only when the cerumen is hard and exerts pressure on the inflamed walls of the canal.

In general, it may be said that the patient complains of a feeling of fulness in the ears and the head, and of dizziness, vomiting, headache, stupor, facial paralysis, trigeminal neuralgia, brain irritation, eclampsia, blepharospasm, pain, etc. One or several of these symptoms may be present at the same time.

The hearing may suddenly change from good to bad, or *vice versa.* When the drumhead is perforated the plug may improve the hearing by acting as an artificial membrane.

Diagnosis.—The diagnosis is made by inspecting the canal, either with a speculum or by simply lifting the auricle upward and backward. The plug appears as a yellow or brownish mass of greasy or granular material, which, upon probing, proves to be either soft, semisolid, waxy, solid, or hard as stone.

It may be mistaken for cholesteatoma, dried blood, a foreign body, cotton stained with secretion, etc. In some cases there is an excessive exfoliation of epidermis, which, becoming admixed with hairs and cerumen, lodges in the canal, thereby causing its occlusion. In those cases we have to deal with a pathological desquamation of epidermis rather than with a hypersecretion of cerumen.

Prognosis.—When there is sudden loss or diminution of hearing following the introduction of water or other liquids into the meatus, the prognosis as to hearing is good, as the disturbance is probably due to the swelling of the plug, which obstructs the canal. Cases complicated by either adhesive otitis or labyrinthine affections are not greatly relieved by the removal of the cerumen.

If we apply the tuning fork to the vertex, as in Weber's test, and the sound lateralizes to the obstructed ear, we gain no information, as the lateralization might be due to either middle-ear disease or to the plug. If, however, it lateralizes to the unobstructed ear, we may suspect labyrinthine involvement on the obstructed side.

Treatment.—The only form of treatment to be recommended is the removal of the cerumen by forcible injections of warm water with a syringe. If the plug has a moist appearance, or is soft to the probe, the injections may be made at once; whereas if it is hard and lustreless, it should first be moistened by instilling a few drops of a solution of bicarbonate of soda and glycerin in water; this should be repeated three or four times daily for about three days. The addition of the glycerin is advantageous on account of its hygroscopic properties, which maintains the plug in a moist state between the instillations.

In rare instances the use of a round-ended probe may become necessary on account of the firm adhesion of the cerumen to the meatus. Persistent injections will ordinarily remove all secretions. Dizziness, or even vomiting, is sometimes induced by the force of the stream, the intralabyrinthine pressure being disturbed by the inward movement of the foot plate of the stapes.

Keratosis Obturans, or Epithelial Plugs in the External Meatus.—In 1874 Wreden described this condition, calling it "keratosis obturans." It is caused by a chronic desquamative dermatitis, in which the epithelium is gradually thrown off and accumulated layer by layer in the fundus of the canal. More or less deafness results, according to the degree of occlusion and the proximity to the drumhead. It is often mistaken for cerumen, as its layers are admixed with and its surface covered by it. A careful macroscopic or microscopic examination will clear the diagnosis. Mr. Richard Lake advances the theory that it is caused by a dry, scaly eczema, which is excited by the ceruminous plug, while Burnett suggests that it is due to an excoriation and slow exudation of dermoid cells, brought on by rough and clumsy attempts to clean the ear.

Pain in the meatus is the most constant symptom. In rare cases it radiates around the ear and over the temporal region.

After syringing the ear the plug becomes whitish or grayish in color, on account of the removal of the outer layer of cerumen, which is readily soluble in water. It is firm and dense and more or less adherent to the walls of the meatus. After its removal, if placed in water, it does not soften and break up as cerumen does under like conditions. Its layers resemble sodden white parchment.

Treatment.—Before proceeding to remove the plug with the syringe, it should first be gently separated from the walls of the meatus with a

flat applicator. This allows the stream of water to pass around and behind it, and facilitates its expulsion. If, however, it does not readily come away, it should be removed piece by piece with a probe or forceps, one hour often being required for its accomplishment. Children do not calmly submit to the procedure, as it is somewhat painful; an anesthetic should, therefore, be given. Recurrences may be expected; hence, frequent examination and treatments may be necessary.

CHAPTER XXXVI.

MALFORMATIONS AND NEOPLASMS OF THE AURICLE.

MALFORMATIONS.

MALFORMATIONS of the auricle are of importance chiefly from a cosmetic point of view. The auricle plays such a small part in the function of audition that its entire absence does not materially influence the acuity of hearing. If, however, the auricle is so shaped as to occlude the meatus, it may materially interfere with the transmission of the sound waves and thus impair hearing. In most cases, however, when there is a very marked defect there is also defective formation of the external auditory meatus, the middle ear, and the labyrinth; hence, diminution in hearing is usually due to other conditions than the changes in the auricle. As stated in the beginning, malformations of the auricle are of interest chiefly from a cosmetic standpoint.

The malformations may assume a great variety of forms, ranging from a plurality of the auricle to its entire absence. Between these two extremes the auricle may be deformed to a slight degree, or it may be overdeveloped or misshapen in almost every conceivable way. It may be either arrested or overdeveloped. One part may be overdeveloped, while in another the development is arrested. It is not uncommon to see in any large company of people ears which project very markedly from the head, and which often give rise, especially among school-children, to their possessors being called "yellow kids." The term "lop ear" is often applied to the same condition.

The defect may be either congenital or acquired. If congenital, it is due to a lack of closure of the branchial clefts and to a disproportionate development of one or more of the six tubercles or centres of development. It may be unilateral or bilateral, usually the former. The bones of the face upon the side affected are usually also arrested in their development.

Stahl, in 1859, called attention to the fact that deformity of the auricular cartilage might be regarded as an indication of arrest of development of the skull, and that it bore a relationship to the development of the skull. Defective formation may consist of the entire absence of the auricular cartilage, although it is probable that in nearly every instance, if a careful examination were made, a small cartilaginous growth would be found beneath the skin. The arrest may take on the form of a simple shrivelling of the whole auricle, or of a portion of it. On the other hand, it may consist of an excessive development of one part and a diminished development of another; or it may assume any irregular type of develop-

ment, as a twisted shell, or it may be hooked, cone-shaped, fissured, or cauliflower-like in form.

Sometimes the upper portion of the auricle is turned downward from above and compressed against the middle portion, as is seen in the old statues of Pan (Politzer); or it may have deep indentations or horizontal fissures and in rare instances, it may be spindle-shaped. The tragus may be twisted inward, so as to close the meatus, or there may be an absence of the auricle with the exception of the lobule. This may be free or adherent to the adjacent skin. The meatus was present in a case of this kind reported by Schwartze. It opened beneath the lobule and led upward and inward to the drumhead.

The auricular appendages or supernumerary auricles, according to Virchow, consist of reticular cartilage, subcutaneous cellular tissue, and skin. They are usually located in front of the tragus, although they may be on the lobule, the side of the neck, or the shoulders. Saissy, in 1829, advanced the theory that malposition of the auricle from an improperly placed head-dress invariably led to arrest of development. He says: "Boys often wear their hats so low upon the head as to either push the ear outward and cause it to project from the head, or to compress it against the head and cause it to assume too close a position. The latter often occurs in females from confining the ears too closely with the head-dress. To remove the deformity, it is only necessary to correct the habit."

Maschziker, in 1864, in his text-book on *The Ear and Its Diseases and Their Treatment*, states that ears are placed in malposition by too tightly drawn caps on children.

I have known mothers to bandage the ears of their little ones to bring them more closely to the head, even when their fathers had widely protruding auricles, and the children had evidently inherited the physical trait. Thus the scientific tradition still holds popular credence, and many a little child is made to suffer in consequence.

Saissy's views on the subject of imperforation of the external meatus were more nearly correct, as he regarded it as usually associated with a congenital and irremediable defect of the middle and the internal ear. The *etiology* of auricular ear deformity is to be found in the disordered development of the organ of hearing. There is insufficient closure of the upper two branchial clefts, which arrests or accelerates development of one or more of the six tubercles or centres of development, as shown by Minot, Talbot, and others.

Classification.—Auricular deformities may be classed as follows:

(*a*) Entire absence of the auricle.

(*b*) Overdevelopment of the auricle (macrotia).

(*c*) Plurality of the auricle (polyotia, supernumerary).

(*d*) Arrested development of the auricle (microtia, shrivelled).

(*e*) Distortions of the auricle (cat-ears—as in the statues of Pan—shell-, scroll-, hook-, spindle-, cone-, fissure-, and cauliflower-like formations).

(*f*) *Fistula in auris congenita* is a remnant of the first branchial cleft, and was first described by Heysinger in 1870. It opens in front of the

ear, either above or below the tragus, and is a blind canal filled with creamy secretion admixed with pus. When its mouth becomes closed the secretion accumulates within the canal, which may be felt as hard nodules beneath the skin. Fistula auris congenita are of slight importance, and may be healed by laying them open with a knife and removing the epithelial lining and bringing the parts together again, after which they unite by first intention, and thus obliterate the canal. Mild caustic applications may be applied within the canal to excite inflammation and adhesions for the purpose of closing the canals.

Fig. 345 illustrates one of my cases of microtia. The drawing is from a plaster cast of the ear. The young man is healthy and has a normal ear upon the opposite side. The cartilages of the fragmentary auricle are not attached to the skull in any way except by the skin. There is an entire absence of the external auditory meatus, and bone conduction is nil upon this side. He came to me to have the ear "opened up," if I thought it advisable. As there was no bony meatus, and the autopsies on similar cases have shown the middle-ear apparatus and labyrinth to be absent or quite rudimentary, I advised him to leave the ear as it was.

Fig. 345

Author's case of microtia. The external auditory meatus, middle ear, and labyrinth are absent.

Treatment. — *Macrotia.* — Figs. 346 and 347 illustrate one of my cases of macrotia. The latter case was referred to me by G. F. Suker, for the reduction of the lop-ear. The boy was eleven years old, and presented numerous stigmata of degeneracy. His schoolmates called him the "yellow kid." It was, therefore, decided to overcome the defect by operating upon the auricles. This was done under general anesthesia.

The skin on the posterior surface of each auricle was incised with a knife, the line of incision extending in a curve from within one-fourth inch of the superior attachment of the auricle to within one-half inch of its inferior attachment. A second incision was begun at the upper point and extended backward and downward over the mastoid process one-half inch posterior to the attachment of the auricle, and made to join the inferior end of the auricular incision (Fig. 346). An ellipse or segment of skin not unlike a segment of orange peel was thus outlined. This was dissected from the auricle and the mastoid process. The second step of the operation consisted in cutting through the cartilage of the auricle, following the line of the auricular skin incision. The cartilage was then severed at the auriculomastoid junction, care being exercised to avoid cutting through the skin on the anterior surface of the auricle. The cartilage was next carefully separated from the anterior skin of the auricle (*a*).

The third step of the operation consisted in closing the wound (Fig. 347). This was done in such a way as to bring the auricle close to the head, as the operation was done principally for this purpose. In order to do this four deep stitches with silkworm-gut were taken, so as to include the auricular skin, the auricular cartilage, the fibrous tissue over the mastoid, and the mastoid skin. These were drawn firmly together and secured. Ochsner's continuous horsehair suture was then used to bring the edges of the skin together.

Fig. 346

Fig. 347

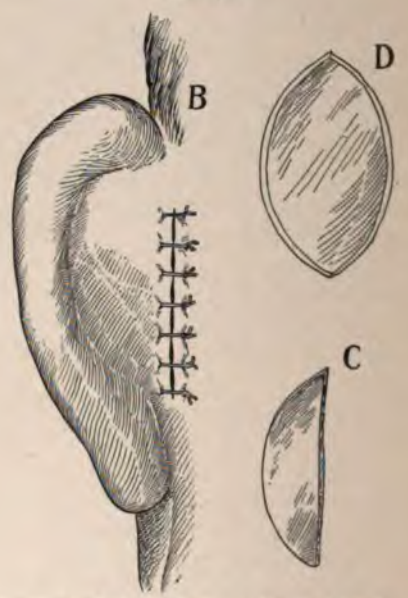

Fig. 346.—*A*, operation for macrotia or lop-ear. An elliptical piece of skin (*a b*) has been removed from the posterior wall of the auricle and mastoid process. *a*, the area of cartilage to be removed from the concha of the auricle.

Fig. 347.—The operation for macrotia, or large projecting auricle. *B*, the sutured incision at the close of the operation; *C*, the cartilage removed from the concha of the auricle; *D*, the skin removed from the posterior aspect of the auricle and the mastoid process.

The superficial sutures were removed on the sixth day and the deep stitches on the ninth day.

The results of the operation were excellent. Before the operation the auricles at Darwin's tubercle were 3.5 cm. from the side of the head, and after the operation they were 1.5 cm. distant. Three months after the operation they were 1.25 cm. from the head.

NEOPLASMS OF THE EXTERNAL EAR.

Othematoma.—**Definition.**—This is a disease of the auricle characterized by an effusion of blood between the perichondrium and the cartilage. It may occur spontaneously or from direct violence. When

it occurs spontaneously it is probably due to degenerative changes in the bloodvessels of the fibrous bands which traverse the cartilage of the auricle. It is also probable that degenerative changes occur in the fibrous tissue.

Etiology.—Dementia seems to have a close relationship to the disease as it is commonly found in the insane. Inhumane treatment of this class of patients has been so often charged, and it is more than probable that traumatism accounts for it among them to a large measure. This is rendered more than probable by the fact that most of the cases have involvement of the left ear, the blow from the right hand of the attendant striking this ear. It must not be presumed, however, that this is the only cause, as the degenerative changes above referred to would be expected in this class of patients. The famous prizefighter, Battling Nelson, has othematoma, caused by numerous blows upon the ear in a series of boxing matches in which he did not have the opportunity of applying hot water.

The condition is common among the wrestlers of Japan, traumatism being the probable cause.

Symptoms.—The tumor forms quickly, thus distinguishing it from perichondritis, angioma, and other neoplasms. The rapid development after an injury is quite characteristic. Its color is bluish, and it is rounded and soft to the touch. It does not have the distinct fluctuation common to fluid sacs beneath the skin, but offers a doughy resistance. If it is due to traumatism it is usually quite large, often involving the whole or the upper portion of the auricle; whereas if it is idiopathic it is often quite circumscribed, being limited to a nodule in the concha or other depression of the auricle. It is most common on the anterior or concave surface of the auricle (Fig. 348).

Pain is present in the traumatic variety, but is absent in the idiopathic. The tumor is opaque by transmitted light, whereas that of perichondritis is transparent. If the auditory meatus is occluded by the swelling, deafness and tinnitus are present. It should be borne in mind that the deafness may be due to the rupture of the ear drum from concussion. In the case of Battling Nelson, the hematoma became organized and caused permanent deformity.

Diagnosis.—The diagnosis is based upon the rapid development of the growth after an injury, the opaqueness by transmitted light, and the absence of febrile symptoms. In the spontaneous variety the rapid development of the tumor mass is quite characteristic.

Prognosis.—The traumatic variety ends by resolution more readily than the idiopathic variety, except when there is extensive damage to the cartilage. If there are no reactive symptoms and the swelling diminishes in size, the prognosis is favorable. Violent inflammatory symptoms, on the other hand, necessitate opening the tumor, thus rendering the prognosis more unfavorable. Some cases recover without visible deformity, while others recover with great shrinkage or other deformity of the cartilage.

Treatment.—The treatment should be symptomatic and modified to correspond with the peculiar pathology of the case. If, for instance, the

othematoma is due to degenerative changes in the bloodvessels and the connective tissue or the cartilage of the auricle, it would be folly to apply massage to promote absorption, as such manipulation would probably provoke more hemorrhage. Such a procedure, if tried at all, should be deferred until regeneration has closed the interior wounds. Pressure bandages are also contraindicated for the same reasons. The application of ice-bags or a Leiter coil may exert a favorable influence in preventing passive inflammatory swelling; and if it is already present, the cold reduces it somewhat. The application of heat is better treatment, as it promotes regeneration. Cooling lotions locally and cathartics may also be used with some advantage. The inflammatory type should be incised and antiseptic dressings applied.

Fig. 348

Othematoma with ossification following a history of dementia and traumatism. (Dr. G. McAuliff's case.)

Politzer recommends the puncture of the tumor in the early stage of its development. If this is not followed by relief it is better to open it thoroughly by free incision, after which the contents can be removed and the cavity packed with iodoform gauze.

Angioma.—Symptoms.—The bright-red or lurid patches which are not elevated above the surface of the skin are not included in this group of tumors. Angioma as used in this connection refers to the cavernous tumors, which are bluish red in color and are made up of a series of venous sinuses or cavities of various sizes and shapes. They are often separated from each other by perforated fibrous septa, thus affording free intercommunication of their blood contents.

They may appear in the auricle, in the meatus, or in both. They may be either primary or secondary extensions from adjacent structures. They vary in size, rarely growing larger than a small hen's egg. They are irregular in shape. Pulsation is occasionally present. Angi-

oma is sometimes congenital, while in other cases it develops after trauma or after the gradual dilatation of the bloodvessels of the simple angioma, the bright-red or lurid patches referred to in the preceding paragraph. Instances are on record of an angioma appearing after the auricle had been frozen.

The presence of pain depends chiefly upon the rapidity with which they grow. If of rapid development and large size, the pain is considerable. Troublesome pulsation is another characteristic of angioma of rapid growth.

Deafness is present in those cases in which the meatus is occluded. Reflex cough may also be present when the meatus is involved.

Diagnosis.—Othematoma is the only tumor which might be confounded with cavernous angioma. The former is of rapid growth, smooth in outline, and opaque to transmitted light; whereas angioma usually develops more slowly, is irregular in outline, and is transparent to transmitted light.

Treatment.—The treatment should be addressed to the reduction of the blood contents of the tumor, which interfere with its circulation. This may be accomplished in various ways. Electrolysis is, perhaps, the best method in growths of small or medium size. The needles connected with the positive pole of the battery should be thrust through the growth, while the negative (sponge electrode) pole is placed on some remote portion of the body. The positive pole liberates oxygen and acids, which coagulate the blood and soft tissues, thus contracting and obstructing the cavernous sinuses of the tumor. Should the negative pole be applied as recommended by Hovell, the results would be less certain, as the negative pole liberates hydrogen gas, which tends to liquefy the solid tissues. The negative pole is better adapted to use in fibrous tumors, on account of its liquefying properties.

Multiple puncture of the surface with needle points and brushing the surface with nitric acid has been recommended in small growths. Both measures produce scar tissue, and thus cause contraction.

Politzer recommends the passage of several silk sutures through the tumor. He first renders them aseptic and then saturates them in a solution of the perchloride of iron. The iron coagulates the blood and the threads act as nuclei for the clot formations.

The galvanocautery and the Paquelin cautery have been used in larger growths. Such treatment is necessarily limited to exceptional cases.

Injections of styptic remedies, as carbolglycerin, iodine, and the perchloride of iron are not safe procedures, as they may cause extensive sloughing and subsequent disfigurement from cicatricial contraction. Suppuration and perichondritis may also follow the injections, the auricle becoming shrivelled and reduced in size.

Fibroma.—*Fibroma* of the external ear consists of spindle cells and connective tissue. It is usually the result of local irritation, as the wearing of ear-rings, and is often found in negresses, who are peculiarly prone to fibromata, not alone here, but in other parts of the body also. They vary in size up to a large walnut, are rounded in form, and may be

pedunculated or sessile. They are usually located in the lobule, as this is the portion in which ear-rings are worn. They may appear elsewhere on the auricle or even at the entrance to the auditory canal (Fig. 349).

Treatment.—If small, a V-shaped incision, including the growth, may be made, and the cut surfaces brought together by skin stitches, thus causing very little disfigurement. If the growth is pedunculated, it is easily removed with scissors, and the base cauterized and dressed antiseptically. Large growths may be removed by excision, the parts being brought together as well as possible so as to avoid disfigurement. If necessary, a subsequent plastic operation may be performed to overcome the deformity.

Cysts.—Like cyst formations in other parts of the body, they are the result of the plastic union of parts which are normally open or separated, *i. e.*, the sebaceous glands of the auricle may become infected, their

Fig. 349

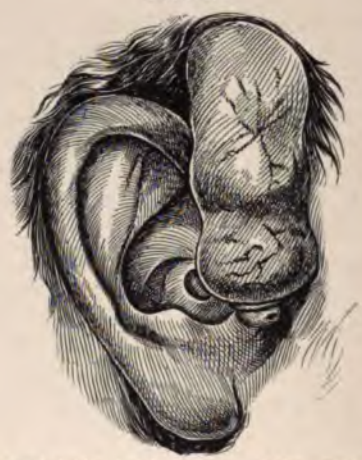

Fibrous tumor (keloid) of right auricle. (After Brühl-Politzer.)

orifices closed, and the secretions retained in the dilated and inflamed glandular sacs. They are variable in size, are soft, and may remain stationary in their development for several years.

Treatment.—The treatment of cysts of the auricle consists in a free incision into the tumor, the evacuation of its contents, curettement, and the application of the tincture of iodine to the surface of the cavity. A suitable surgical dressing should then be applied, and repeated daily while repair is taking place.

Epithelioma.—The growth begins as a hard nodule situated in the skin or the subcutaneous connective tissue; it grows slowly for a time, but later develops quite rapidly. It is in this stage that ulceration is likely to occur. The growth may be an extension from contiguous structures, or it may be primary in the auricle or the meatus. Of the sixty cases reported, nearly all occurred in patients more than forty years of age. Dr. J. S. Brown reports a case in a man seventy-eight years old. Epithelioma may begin as warty or fissured surfaces, which finally ulcerate and

continue to spread by the formation of new tissue at the edge of the ulcer. This tissue rapidly undergoes disintegration, and the ulcerous process may spread until the entire auricle and meatus or even the neighboring structures are destroyed (Fig. 352).

Fig. 350

Fig. 351

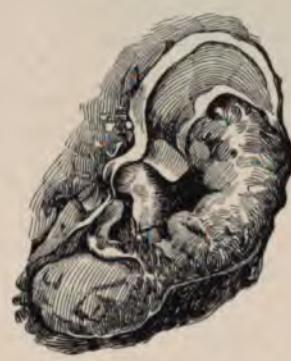

Fig. 352

Fig. 353

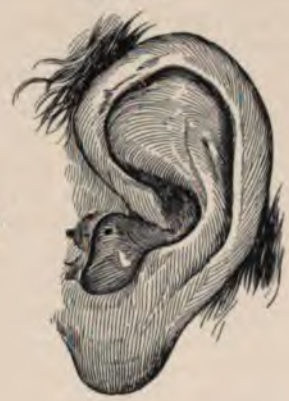

Fig. 350.—Sarcoma of auricle.

Fig. 351.—Lupus vulgaris of auricle.

Fig. 352.—Carcinoma of auricle and temporal bone. Left ear of a man fifty-six years of age who had suffered from aural discharge. The carcinoma extended into the body to the temporal bone.

Fig. 353.—Acquired stricture of external auditory meatus. Left ear of a man who had been run over by a wagon in early childhood. Immediately behind the opening of the auditory meatus there is a connective-tissue septum stretched across the canal like a diaphragm, with a round opening that admits a sound the size of a pinhead. He can hear whispered conversation at a distance of three meters. (After Brühl-Politzer.)

The nodular enlargements on the auricle may be present several months before enlargement of the glands in the neck appears. Pain may not be a symptom until ulceration takes place; hence, in the early stage, epithelioma may be mistaken for fibroma. As the ulceration and the deeper extension of the growth progress, the pain increases, often becoming excruciating in character. The facial nerve may become involved, and facial paralysis develop. The auditory nerve may be affected, or hemorrhages may occur, and glandular enlargements

develop, finally resulting fatally. Death may be due to septicemia, exhaustion, meningitis, thrombosis of the lateral sinus, or cerebral abscess.

Treatment.—The treatment of epithelioma here, as elsewhere in the body, consists in the complete removal of the growth by excision. To accomplish this it may be necessary to remove the auricle in part, or entirely. The disfigurement resulting may be corrected by a subsequent plastic operation or the adjustment of an artificial auricle. While the wound is healing a vulcanized or a silver tube should be worn in the meatus to prevent cicatricial contraction.

Sarcoma.—Sarcoma of the auricle is rare. When present, it may be of the round-cell variety, which develops rapidly and leads to an early fatal issue, or it may be of the fibrosarcomatous type, which grows slowly. This type may exist for many years without giving rise to marked symptoms. The round-cell variety is painful, as its rapid growth stretches the sensory nerves, and it is also often attended by inflammation in the parotid and the mastoid regions.

The appearance of the tumor varies according to the variety and the rapidity of development. If it is of the fibro-sarcoma type, it is smooth and covered with normal skin. If it is of the round-cell variety, its growth is rapid. The skin becomes eroded and the seat of fungous granulations (Fig. 350). The eroded surface secretes an unsightly suppurating material composed of debris, pus, epithelium, leukocytes, and blood corpuscles. The ulcerating surface often bleeds profusely.

The external meatus may be the seat of round-cell sarcoma and, in extremely rare instances, of osteosarcoma.

Diagnosis.—A portion of the growth should be subjected to microscopic examination. The round-cell sarcoma is pale on cross-section and exudes a milky juice; it is composed almost entirely of round cells and thin-walled bloodvessels. The fibrosarcoma has a considerable quantity of intercellular cement substance, and the macroscopic appearance of the tumor is coarse-grained and firm.

Prognosis.—It is obvious that this depends upon the type of the growth, the round-cell variety being comparatively more speedy and destructive. In this type death may result from intracranial extension, hemorrhage, or exhaustion.

Treatment.—Early and complete removal of the growth is the best treatment. This may be done with the knife or the galvanocautery. If the growth cannot be completely removed, the parts continue to discharge offensive material.

The Röntgen-rays have been used with some apparent success in superficial sarcomata, but we are not ready to recommend this method of treatment until further trial has demonstrated its real value. It is unsafe to try it in the round-cell variety, as the early surgical removal offers the only hope in this type of sarcoma. While using the Röntgen-ray treatment extensions may occur, thereby rendering operative treatment hopeless. The rays are of special value, however, after operation, recurrences being less frequent or delayed by their use.

CHAPTER XXXVII.

DISEASES OF THE AURICLE AND EXTERNAL MEATUS.

PERICHONDRITIS OF THE AURICLE.

THIS is a rare affection and resembles othematoma. The upper portion of the auricle is usually involved, as the cartilage is chiefly found there. The lobule escapes, as it is free from cartilage.

Symptoms.—If the inflammation occurs as a complication of furunculosis of the meatus, the pain characteristic of that condition is present; whereas, if it begins in the auricle, the first symptom may be circumscribed redness and swelling, which gradually spreads and becomes more pronounced, until it finally involves the whole of the cartilaginous portion, including the concha, or it may include the meatus. If the meatus is wholly occluded by the swelling, the hearing is impaired. Fluctuation soon appears, and is due to the inflammatory exudate of viscid serum beneath the perichondrium. The natural contour of the auricle is modified by the swollen tissue and its surface is reddened. The perichondrium of the entire auricle may become detached and thus interfere with the nutrition of the cartilage. This is a serious complication, especially if the secretion becomes purulent. Under such circumstances the cartilaginous auricle is apt to shrink or slough, and leave pronounced deformity.

The greatest care should be exercised to prevent additional infection when there is an abrasion of the skin and when an incision is made to evacuate the fluid beneath the perichondrium. Should active infection be present, many weeks or months may be required to check the progress of the disease, and even then the auricle will be greatly deformed. Perichondritis occasionally follows the mastoid operation, especially when the plastic meatal flap includes the concha of the auricle.

FIG. 354

Leiter's coil.

The result of the perichondritis may be so slight as to attract no attention, or it may be so marked as to completely disguise the anatomical characteristics of the auricle.

Treatment.—The treatment should be antiphlogistic in nature, heat being the most serviceable in the early stage. The Leiter coil (Fig. 354) should be applied over the auricle and hot water passed through it. A hot-water bag may also be used. A brisk saline cathartic should be administered and leeches used around the auricle in conjunction

with the heat. If fluctuation is present, an incision should be made to evacuate the fluid. The auricle should be cleansed before making the incision, to prevent the possibility of additional infection. The cavity should be carefully but thoroughly scraped with a dull curette, and then cleansed with an antiseptic solution. If the infection is severe and granulations are present, the cavity should be swabbed with the tincture of iodine or the compound tincture of benzoin. Free drainage should be maintained by the insertion of a gauze wick, over which the usual dressing of gauze and cotton should be placed and held in position with a bandage. The dressings should be changed every twelve hours.

Subsequent operative measures may be undertaken to correct the deformity if it is sufficiently pronounced to produce disfigurement.

HERPES OF THE AURICLE.

The etiology is not always clear, although it seems to be caused by middle-ear disease. It is thought by some to be caused by malaria, and by others to be a neurosis. It is most common in adults.

Symptoms.—The vesicular eruption is sometimes preceded by a stinging or burning pain, especially if the meatus is involved. The eruption is generally on the outer or concave surface of the auricle, which is supplied by the auriculotemporal branch of the fifth nerve. This is of interest, as the distribution of the eruption usually follows the terminal ending of this nerve. It is more rarely on the posterior or convex surface of the auricle, as the auriculotemporal branch of the fifth nerve does not extend to this region.

The course and appearance of the eruption is about as follows:

At first there is a reddened area, which becomes papular, then visicular. The vesicles may become confluent and form bullæ. The contents of the vesicles is first clear serum, which later becomes cloudy and purulent. The duration of the vesicular stage is limited to a few days, after which the vesicles dry up, leaving crusts and an occasional superficial ulcer.

If the meatus becomes involved, more or less deafness and tinnitus is present.

Treatment.—Tonics, purgatives, and outdoor exercise are indicated to improve the general health of the patient. Cool or cold morning baths, or at least sponging of the neck and chest, are indicated to improve the tone of the vasomotor nervous system.

The blisters should be protected by starch or boric acid powder and cotton-wool dressings. The fluid contents of the vesicles should be emptied, care being taken to avoid removing the elevated dermis, and exposing the underlying parts to the air. This accident is attended by considerable pain. Boric acid powder may be applied in suppurative cases. If the meatus is involved, boric acid should be blown into it.

HERPES ZOSTER OF THE AURICLE.

This is a vesicular eruption appearing on a reddened surface, although the area of redness does not extend much beyond the base of the blisters. The vesicles are arranged in groups and are quite painful.

They most often appear upon the posterior surface of the auricle and the lobule, and more rarely upon the anterior or superior surface of the meatus. They still more rarely develop upon the anterior surface of the auricle.

It is a nervous affection of either the trigeminus or the great auricular nerve. In some cases it seems to be of ganglionic origin.

The location of the eruption is determined by the distribution of the nerve affected.

In rare instances the drumhead is involved, although the hearing may be but slightly affected thereby. Within a few days after the formation of the vesicles they burst, emptying their contents, after which crusts form at the site of the eruption.

A few days later new epidermis forms, and unless there is a recurrence of the disease complete recovery takes place.

Treatment.—Although herpes has been recognized as a distinct disease for a long time, the treatment of it has not developed beyond an attempt to relieve the pain and to prevent excoriations after the bursting of the vesicles. The internal administration of arsenic is often recommended with the idea of correcting the nervous disorder which is the chief cause of the trouble. It is doubtful, however, if it has any specific effect as a remedy. Anodyne remedies, such as the 5 per cent. ointment of the hydrochlorate of cocaine, may be applied locally with a fair degree of confidence that it will afford relief. Calomel dusted over the eruptions, especially after they have discharged their contents, induces healthy and speedy epidermization of the denuded surfaces.

DERMATITIS OF THE AURICLE.

Dermatitis may be due to traumatism, exposure to heat or cold, and to a parasitic infection (Politzer). The treatment should consist of the application of solutions of lead.

It occasionally happens that when there is an abrasion of the skin of the auricle or a loss of the integrity of the epidermis due to eczema, etc., erysipelatous infection may occur and lead to a much more severe type of inflammation.

Treatment.—The treatment should be antiphlogistic in character and weak solutions of ichthyol (1 to 5 per cent.) should be applied locally.

Should the deeper tissues become involved and pus accumulate therein, free incisions should be made and the parts treated according to aseptic surgical principles.

Dermatitis from Exposure to Cold.—**Synonyms.**—Frostbite; chilblain; dermatitis congelationis auriculæ.

Etiology.—Exposure to extreme cold or prolonged exposure to moderate temperature, as in the autumn of northern latitudes, also the extreme thinness of the skin and slight amount of subcutaneous tissue separating it from the cartilage of the auricle predisposes to dermatitis.

The disease is characterized by the formation of nodules and excoriations, especially on the elevated portions of the auricle.

In the extreme north, the dermatitis is usually acute in character and is attended by simultaneous freezing of the nose. More or less necrosis and gangrene, and partial loss of the auricle follows.

Ordinary frostbite is characterized by moderate swelling, redness, and circumscribed dermatitis.

The nodules heal slowly or not at all, and become covered by bloody crusts. Even after the crusts disappear the skin continues to exfoliate epidermis for a long time. The affection is most common in young chlorotic girls of northern climates, and always appears at the beginning of cold weather. It is more than probable that insufficient and improper food predisposes to its occurrence. These conditions together with the unstable vasomotor system at the time of puberty may be considered the chief etiological factors.

Symptoms.—In addition to those apparent to the eye, as described above, may be mentioned lancinating pains, sense of heat, itching, etc. These symptoms cause the patient to scratch or rub the parts, thereby increasing the difficulty.

Treatment.—In those cases due to extreme cold, snow or ice-bags should be applied. In the subacute varieties, Goulard's extract is serviceable. The auricle may be painted with iodine collodion, or camphor ointments may be used. For the relief of the intolerable itching the following mixture is of value:

℞—Collodion	ʒj
Ol. ricini	♏xx
Ol. terebinth.	ʒj—M

Sig.—Apply locally to relieve itching.

The frequent application of camphor ointment also relieves the itching.

FURUNCULOSIS OF THE EXTERNAL MEATUS.

Synonyms.—Follicular inflammation of the external auditory canal; otitis externa; follicularis s. circumscripta.

Etiology.—Furunculosis of the external auditory canal is a circumscribed inflammation involving either the hair follicles or the sudoriferous glands. As these organs are limited to the cartilaginous or external portion of the canal, the furuncles are not found in the deeper or osseous portion. The boils may be without known cause, or they may be a part of a general furunculosis. They may occur in the course of

suppurative otitis media and chronic eczema. Traumatism from attempts at cleaning the ears often causes them. It most often appears in the spring and autumn, and is chiefly a disease of adult life. General debilitating diseases or their sequelæ predispose to it.

Symptoms.—The hearing is but slightly affected in most cases, as the lumen of the canal is not completely obstructed. The pain is more or less intense according to the depth of the inflammatory process. The furuncle does not always present the appearance of a boil, as the skin is tense and closely adherent to the cartilaginous meatus, thus preventing the usual elevated appearance. In other words, the swelling is more diffused and but slightly elevated.

The auricle is extremely sensitive to the touch, and the movements of the inferior maxilla in mastication cause pain. The tension of the skin becomes so great that the patient is often unable to sleep. The swelling in the external meatus is more or less diffused on account of the close adhesion of the skin to the cartilaginous meatus, and with the inexperienced may be mistaken for the redness and swelling in the postsuperior portion of the meatus in mastoid inflammation. It is easily differentiated from it, however, by remembering that the swelling due to mastoid disease is limited to the postsuperior wall of the osseous or deeper portion of the meatus, while that due to furunculosis is in the posterior and inferior wall of the outer or cartilaginous portion. The pain is often greater in furunculosis.

The temperature is irregularly elevated during the first few days. Deafness and tinnitus are present if the meatus is occluded, though they may be present without occlusion. When this is the case the inflammation has probably extended to the drumhead and the tympanum.

The more superficial the furuncle the greater the redness and the more circumscribed its area. Pain may or may not be present. If the deep tissues are involved the redness and swelling are more diffused, while the pain is greater. In some cases the surrounding tissues become more or less swollen, as, for instance, when the anterior portion of the meatus is involved, the skin in front of the tragus is swollen and purple in color; whereas if the posterior portion is involved, the mastoid skin may be swollen and simulate mastoiditis. Glandular enlargement in the lateral region of the neck is not commonly present.

Course.—Furunculosis of the meatus is apt to go on to suppuration, which usually takes place in from six to eight days. The deeper the inflammation the more delayed the voluntary escape of pus. The pain and swelling subside immediately after the pus is liberated, especially if it is done by incision. Incisions should be made early, as the progress of the disease is often thereby checked. The meatus should then be irrigated with warm boric acid solution, thoroughly dried and dusted with bismuth, and a gauze wick inserted for drainage. The dressing should be changed daily until the swelling and discharge have materially subsided. If the boil is allowed to rupture spontaneously, granulations may spring from its crater, and be mistaken for middle-ear polyp. Recurrences are to be expected in many cases.

Treatment.—Abortive treatment may be used before the formation of pus has taken place. The best remedy is a 5 per cent. solution of carbolic acid in glycerin. This should be instilled into the meatus, or applied with a cotton-wound applicator if the canal is open. Its early use is often followed by a complete disappearance of the process. The Leiter ice coil gives relief to the pain. Mixtures containing opium, morphine, cocaine, etc., are recommended, but the carbolic-glycerin mixture is not only curative, but analgesic as well. Poultices have been recommended, but their use is irrational and obsolete. Antiseptic solutions are valuable adjuncts in the treatment of furunculosis, and the carbolic-glycerin solution answers this purpose admirably, in addition to its anodyne and curative properties. Should it fail to give the desired relief, the meatus is at least prepared for operative measures.

In a large majority of cases the process has gone on to the suppurative stage before the physician is called in. When pus is present the furunculous area should be freely incised with a narrow bistoury. Pus may not appear at once, but this should not deter the physician from incising each swollen and reddened area. If voluntary rupture has occurred and the flow of pus is obstructed by granulations the area should be opened more freely.

After-treatment.—Immediately after incision the cavities exposed should be cleansed with a 5 per cent. solution of carbolic acid to check the growth of the pus cocci. Frequent instillations of hydrozone should be used to keep the wound and the meatus free from pus.

The ceruminous secretion is often absent after an attack of furunculosis, or, if present, is of a dry, crumbling quality. Intolerable itching usually complicates furunculosis.

Various remedies for the relief of the itching have been recommended. The white precipitate ointment, boric acid 5 per cent. in lanolin, and the glycerin-carbolic acid solution are valuable for this purpose.

The entrance of water into the meatus often leads to a relapse, hence care should be exercised to prevent it.

DIFFUSED INFLAMMATION OF THE EXTERNAL MEATUS

Synonyms.—Otitis externa diffusa.

Etiology.—The causes are (*a*) infections from without and from within the middle ear; (*b*) traumatism; (*c*) excoriation of the cutis of the meatus; and (*d*) the injection of irritating fluids into the meatus.

Symptoms.—Unlike the furunculous type, the symptoms are chiefly limited to the osseous meatus and the drumhead. The cutis is swollen and congested, and after a few days throws off a serogelatinous secretion, which is often so tenacious that it can be removed *en masse* (Politzer). It is charged with pathogenic organisms, thus showing its bacteriological origin.

Great *pain* in the region of the ear is usually present, movements of the inferior maxilla aggravating it. Tinnitus and dizziness are occa-

sionally present. The hearing may be impaired, especially if the drumhead is much swollen, or if there is a large accumulation of thick secretion.

The *duration* of the disease is three or more days. If it runs an uninterrupted course, an acute case may terminate on the third day. The hearing is usually normal after the inflammation ceases. In rare cases an excoriated or ulcerous surface is left, and becomes the seat of a granulation tumor, which, when removed, checks further pus secretion.

Periostitis and *hyperostosis* may be left as sequelæ in rare cases.

Prognosis.—In the simple forms complete recovery usually occurs, while in those cases complicated by excoriations, injuries, etc., constriction of the meatus from periostitis, hyperostosis, and dermoid thickening are liable to affect the function of the ear.

Treatment.—It should be borne in mind that the disease is usually of bacteriological origin, and remedies applied accordingly. The carbolic-glycerin mixture (5 per cent.) is, perhaps, one of the most reliable remedies. It should be instilled into the meatus two or three times daily and cotton-wool introduced into the cartilaginous canal. The Leiter coil, and leeches to the tragus and the mastoid region are of great value when there is swelling and pain. Antiseptic solutions of all kinds have been recommended, but it is doubtful if any of them are of especial value. It may be said of aqueous solutions in general that their utility is questionable. Remove the secretions from the meatus with hydrozone and a cotton-wound applicator and then apply the carbol-glycerin mixture.

If ulcers form and show no tendency to heal, they should be cauterized with a 90 per cent. solution of the nitrate of silver.

HEMORRHAGIC INFLAMMATION OF THE MEATUS.

Synonym.—Otitis externa hemorrhagica.

This is a form of hemorrhage beneath the superficial layer of the skin of the osseous meatus, and in most cases is probably a complication of influenza otitis media. The hemorrhagic areas appear as bluish swellings on the inferior or the posterior wall of the meatus. To the probe they are soft and often rupture upon very slight pressure. The vesicles may remain for several days, and when they disappear others may come to take their place. In from one to two weeks they disappear altogether, complete recovery taking place. The hearing, if affected, returns to normal.

Treatment.—The hemorrhagic vesicles should be opened with a probe and gauze drainage applied to the meatus. The dressing should be removed daily. Politzer recommends dusting the meatus with boric acid powder in addition to the gauze drainage.

CROUPOUS INFLAMMATION OF THE MEATUS.

Synonym.—Otitis externa crouposa.

This is a very rare condition, and usually occurs in connection with influenza otitis media or furunculosis of the meatus. The false membrane is limited to the osseous portion of the meatus and to the outer surface of the drumhead, being in this particular similar to the diffuse inflammation of the meatus. It sometimes appears with a similar process on the tonsils (Gottstein). The membrane forms in from one to two days and is firmly attached; it may, however, be removed by forcible syringing. It may form a cast of the osseous meatus and the drumhead. The microscope shows it to be composed of a fibrous network infiltrated with round cells, nuclei, epithelium, staphylococci pyocyaneus, and streptococcus pyogenes (Politzer).

The formation of the membrane is attended by some pain, which disappears when it is cast off. Recurrences are common.

Prognosis.—The prognosis is favorable. In rare cases the cartilage of the meatus becomes necrotic or gangrenous.

Treatment.—The treatment consists in removing the false membrane with forceps or by antiseptic solutions applied with a syringe. Dry the meatus and dust with an antiseptic powder.

EXOSTOSIS AND HYPEROSTOSIS OF THE MEATUS.

These two terms are often used synonymously, although, according to strict pathological interpretation, they should be used to describe different lesions of the bony tissue.

Exostosis refers to a bony tumor growing from the wall of the meatus, and it may be either sessile or pedunculated. Hyperostosis is a diffuse thickening of the bony tissue, or a true hyperplasia.

Etiology.—The cause of these pathological changes is often unknown, but in many instances they are due to conditions which may be easily recognized. Among them may be mentioned:

(*a*) Traumatic fracture of the walls of the meatus, whereby a circumscribed periostitis is excited, finally resulting in the formation of a bony mass or tumor.

(*b*) They may be due to developmental causes, particularly in those cases wherein the middle and the inner section of the osseous meatus on each side is the seat of the growth. When it is due to faulty development the growths are usually small. They may be either sessile or pedunculated.

(*c*) Chronic suppuration of the middle ear may excite a secondary inflammation of the membranous canal, and cause a fibrous or connective-tissue thickening, which, after a long period of time, may be metamorphosed into osseous tissue.

(*d*) There are some cases in which heredity seems to be a factor in the

production of the growths, as the same condition may be traced through a few generations.

(*e*) Syphilis is undoubtedly a cause of the growths, although not in a very large number of cases.

(*f*) Gout has been thought to be another cause, but it is doubtful if this condition directly leads to their formation.

It is more probable that the gouty diathesis causes an inflammatory process of the skin and the periosteum, which finally undergoes a retrograde change and becomes the seat of lime deposit.

Symptoms.—The symptoms are chiefly those recognizable by the aid of the eye and the probe, although in some cases in which the lumen of the ear is completely occluded the function of hearing may be affected. If the growth is an exostosis, it appears as a rounded, elevated mass, with a tense, whitish skin covering. The lumen of the meatus is reduced to a crescentic or slit-like opening. The swelling or growth is composed of very dense tissue. If it is sessile, it will be difficult to differentiate between it and a hyperostosis, but if it is pedunculated the differential diagnosis may be more easily made, as this type of growth is more often an exostosis. A favorite seat for the growths is at the junction of the osseous and the cartilaginous portion of the meatus. They may, however, form in any portion of the canal. Deafness may be present, although it is not marked, unless there is concurrent disease of the middle ear or the labyrinth, except in those cases in which the growth completely obstructs the lumen of the canal. Secondary inflammation of the cutaneous meatus may be caused by the pressure of the growth against the opposing walls. In such cases there will be more or less secretion from the dermatitis thus excited. Cases have been reported in which the pressure of the growth was so great that necrosis of the surrounding bone tissue resulted, thereby complicating the case.

Treatment.—The treatment is necessarily limited chiefly to surgical procedures, except for the relief of those symptoms which are due to secondary inflammatory processes. If the growth is large enough to in any way interfere with the function of audition, it should be removed. In some cases this can be done through the external auditory meatus without lifting the auricle forward, as is done in the mastoid operation. The skin and periosteum over the growth should be excised and elevated, and the bony mass removed or reduced with a small chisel or gouge or with a dental burr or trephine. If the growth is sessile or diffused, and involves the entire length of one wall of the meatus, it would, perhaps, be futile to attempt to remove it through the external auditory meatus. A better and much simpler procedure would be to first lift the auricle forward, as in the mastoid operation, thus exposing the entire canal to view and affording easy access with instruments. When this is done the skin of the osseous portion of the meatus should be carefully elevated with a small periosteum elevator, so that the healing process may be more certain and rapid after the operation. The exposed tumor should then be removed with a very sharp gouge, or, perhaps better still, by the use of a dental burr. This method of pro-

cedure is also productive of better results in many of the pedunculated growths, as the base can thus be completely removed.

The *indications* for operative interference should be based upon the amount of deafness present and upon the concurrent middle-ear disease, if present. For example, if there is chronic suppurative ear disease, with impairment of hearing, it is quite essential to the proper treatment of the case that the external auditory meatus be completely freed from the obstructive lesion, so as to afford better drainage and opportunities for treatment.

Another indication is the presence of dermatitis with secretions, while a still more urgent indication is secondary pressure necrosis of the contiguous tissue.

It seems irrational, in view of the present status of surgery, to resort to the use of laminaria tents for the dilatation of the canal, as the process must necessarily be a long and painful one. This method was formerly in vogue and is still recommended in some of the modern text-books on otology.

STRICTURE OF THE EXTERNAL MEATUS.

Etiology.—Obstructive lesions of the external auditory canal are due to the inflammatory swelling of the skin lining its walls, as described under dermatitis, furunculosis, perichondritis, eczema, etc. It may also be due to new-growths, exostosis, and fibrous thickening of the deeper dermic tissue. It is to the last-named condition that permanent obstruction of the lumen of the canal is usually due.

Cicatricial rings or bands are produced by prolonged inflammation of the meatus in the course of chronic otorrhea. In rare instances they are due to syphilis, diphtheria, etc., or to the use of the cautery and acids in the meatus. Partial closure of the canal sometimes follows the mastoid operation, especially if the plastic meatal skin flap is not properly sutured and the wound is tightly packed with gauze. (See Mastoid Operation.) In the aged the cartilage supporting the skin of the meatus undergoes atrophic changes, which allows the walls to collapse and obstruct the meatus.

In some cases the obstructing lesion is ring-like, while in others it may be limited to one wall of the meatus. If it is due to an exostosis, there is a tumefaction on one side of the canal. The tumor is hard to the probe touch, and may either partially or wholly obstruct the meatus. Exostosis sometimes follows the exfoliation of necrosed bone, while in other cases it develops from the periosteum or from the bone beneath as a hyperostosis.

Treatment.—As the origin of the obstruction is various, so should the treatment be varied. If inflammatory, suitable treatment should be instituted. If it is cicatricial in character, laminaria tents and the subsequent introduction of hard-rubber tubes may be used. In this way the structure is dilated, and maintained in this condition by the rubber tubes. Electrolysis may also be used with advantage, from

five to six sittings being required to reduce the fibrous constrict on. The needles connected with the negative pole of the galvanic battery should be inserted into the fibrous ring, while a large sponge electrode connected with the positive pole is placed in contact with the body. The amount of current necessary to soften the tissue varies from 25 to 50 ma., and each seance should last from five to twenty minutes, according to the amount and the density of the fibrous tissue.

Another method of dealing with fibrous strictures is to split the canal longitudinally in several parallel lines and introduce sponge tents. After thorough dilatation the hard-rubber tubes should be used to maintain the patency of the meatus.

Jansen resorts to a surgical procedure which is probably the most successful mode of treatment, whether the stenosis is cicatricial or osseous in character. He detaches the auricle as in the mastoid operation, and then dissects away the fibrous ring, osteoma, or hyperostosis. To cover the bony wound, he makes a pedunculated flap from the skin over the mastoid process and inserts it through the line of incision made in detaching the auricle.

Should the stricture be of long standing and accompanied by suppuration of the middle ear, a radical mastoid operation should be done, during which the canal may be enlarged.

DIPHTHERITIC INFLAMMATION OF THE EXTERNAL EAR.

Etiology.—It is obvious that diphtheritic inflammation of the external ear can only occur when there is a denuded surface or a preexisting inflammation. Croupous inflammation or excoriations from suppurative otitis media predispose the skin of the meatus and the auricle to receive the infection of diphtheria. It may appear primarily on the external ear during an epidemic of diphtheria, although it is usually associated with diphtheria of the fauces. If it is primary on the external ear, it may extend secondarily to the fauces.

Symptoms.—The appearance and the characteristics of the membrane are the same as those found in the faucial type. It is of a dirty grayish color, closely adherent to the surface beneath, which, when the membrane is forcibly removed, bleeds. There is more or less pyrexia, pain, tinnitus, and deafness. The cervical and the postauricular glands are swollen and slightly painful.

The *course* of the disease is not unlike that of croupous inflammation of the same parts. The membrane may reform a number of times, thus indefinitely prolonging the disease. If deep ulceration occurs, and the disease is prolonged, the canal is more or less obstructed and may ultimately lead to serious stenosis; on the contrary, if only the superficial parts are involved, the obstruction is temporary.

Diagnosis.—The diagnosis here, as in faucial diphtheria, is clinical and microscopic. The membrane is closely adherent, and the surface from which it is removed bleeds freely. The microscope reveals the presence of Klebs-Loeffler bacilli.

Prognosis.—The absorptive power of the skin of the meatus is not great when compared with that of a mucous membrane. Diphtheria, when limited to the external ear, is not a grave disease. If, however, it is complicated by middle-ear or faucial diphtheria it is correspondingly more serious. If the middle ear is involved, there may be great destruction of the drumhead with necrosis of the ossicles, the tympanic walls, and the labyrinth, thereby causing serious impairment of the function of hearing.

Treatment.—The treatment is somewhat simpler than that of faucial diphtheria on account of the greater vulnerability of the tissue affected, and its lesser absorptive power; also by the ease with which local remedies may be kept in constant contact with the diseased surface. Burckhardt-Merian and Gottstein recommend filling the external meatus with lime-water at frequent intervals, leaving it there for fifteen or twenty minutes. It is supposed to loosen the membrane and favor its discharge. The author has used lime-water extensively for this purpose in this and faucial diphtheria, and regards it very favorably. After using it the parts should be covered with a powder composed of equal parts of the subnitrate of bismuth and salicylic acid. Nearly all the antiseptic powders and solutions have been used for this purpose, but none of them has equalled, in the author's experience, the lime-water and bismuth-salicylic acid treatment.

The usual constitutional remedies and the administration of antitoxin should be used as in the faucial disease.

MYCOSIS OF THE EXTERNAL MEATUS.

Synonyms.—Parasitic inflammation of the external auditory canal; otomycosis.

Etiology.—The source of the mycotic infection is often unknown. Living in damp surroundings or in the presence of yeast spores seems to favor it; hence it is rather common among bakers. The habit of instilling warm oil into the ears to relieve earache favors the growth of the spores, as the oil is a good soil for their development. The spores most commonly causing the disease are the Aspergillus niger, flavus, and fumigatus. Several other varieties are occasionally found.

It usually occurs in adults, rarely in children or in the old. As the sanitary and hygienic conditions surrounding the poor are bad, it is common among them. The fungus growth may, in rare cases, extend to the middle-ear cavity or even to the mastoid cells.

Symptoms.—The manifestations of the infection depend largely upon whether the spores have attacked only the epidermis or also the deeper living structures of the skin or the drumhead. If only the epidermis is affected, there may be no symptoms, even when the drumhead is covered with the false membrane; on the contrary, if the true skin is involved deafness and tinnitus are more or less pronounced as a result of the swelling and inflammation excited. This type of inflammation is

known as *otitis externa parasitica,* and is characterized by shooting pains, itching, tinnitus, and deafness.

The appearance of the mycotic membrane is black or grayish in color, velvety in texture, and distributed chiefly over the osseous portion of the canal, although the drumhead and the cartilaginous portions of the canal may also be covered by it. It can be removed by the syringing. The underlying skin is red, slightly swollen, and largely denuded of epidermis.

The *course* of this type of inflammation, if not properly treated, may extend over several weeks. Under treatment its duration may be much shortened.

The pains and other subjective symptoms are usually greatly relieved immediately after the removal of the membrane.

Treatment.—Almost the entire list of antiseptic mixtures and powders have been used for the relief of these cases, but the remedy *par excellence* is alcohol, which should be instilled into the meatus once or twice daily, two to four days usually being sufficient to effect a cure. The alcohol should be used at intervals every two weeks for a few months to prevent recurrences.

ACUTE ECZEMA OF THE EXTERNAL EAR.

The superficial layers of the skin are involved, and, in the beginning, there is marked redness and swelling of the skin; nests or colonies of fluid-filled vesicles soon make their appearance.

Etiology.—It is not always possible to ascribe a cause for the eruption, although it is usually due to one or more of the following factors: viz., neuroses, scrofula, rickets, pus discharge from the middle ear, irritating remedies, cold douches, and exposure to heat. Other causes exist in selected cases. It may be a primary affection or it may be secondary to a similar process on some other part of the body.

Symptoms.—The onset of the disease is characterized by burning and itching, which is soon followed by pain. Deafness and tinnitus are present in those cases in which the meatus and the drumhead are involved, especially when epidermis and secretions obstruct the lumen of the canal. If the disease is limited to the auricle, the hearing is not affected. There is some elevation of the temperature, especially in children. The pain and the pyrexia give rise to restlessness and inability to sleep.

The disease may terminate in one of three ways, namely: (*a*) In the mild form the vesicles dry up and the epidermis peels off on the second or third day, leaving the natural cuticle. (*b*) In a large number of cases the blisters discharge their contents and after a few days the surface becomes covered with yellow crusts. In time these disappear and recovery takes place. (*c*) The third and more aggravating mode of termination is the persistence of a clear or purulent secretion for several weeks, after which the parts become covered with epidermis.

In some cases the eczema may persist in isolated areas for many weeks

and leave more or less scar tissue and contraction, or it persists and becomes typically chronic in character.

The *treatment* will be considered under Chronic Eczema.

CHRONIC ECZEMA OF THE EXTERNAL EAR.

Symptoms.—Owing to the involvement of the deeper structures of the skin there is greater thickening and rigidity of the auricle. The crusts usually form in the hollows of the auricle and in the posterior groove, while beneath them is secreted a serous or purulent matter. The meatus may be obstructed by the thickening of its integument. The whole auricle, and in some cases the meatus, is the seat of a desquamative process. The process of desquamation and crust formation varies in different cases, although the desquamation is usually predominant.

Exclusive of the appearance of the skin, the itching is the most pronounced symptom. The patient is overcome with an irresistible desire to rub or scratch the parts, and thus produce deeper lesions of the skin.

Tinnitus and deafness may result from desquamative plugs in the meatus and from secondary hyperemia of the mucous membrane of the middle ear. It is barely possible that in rare cases hyperemia of the labyrinth may be induced.

The course of chronic eczema is quite different in individual cases, some getting well under treatment in a few weeks, while others obstinately refuse to recover under any form of treatment. Boils in the meatus may complicate the condition.

Treatment.—The general treatment should be addressed to the correction of constitutional dyscrasias and neuropathic states which so often underlie the condition. Iron, arsenic, strychnine, iodine, and the bitter tonics should be given in suitable combination for this purpose. The administration of saline cathartics and an occasional dose of calomel will often aid in overcoming the eczema.

Perhaps one of the best measures for its relief is negative in character, namely, the avoidance of the local application of water, which greatly aggravates the eczema. If it is desirable to use water for toilet purposes, the patient should be instructed to add boric acid or even a teaspoonful of common table salt to the quart of water. The irritating qualities of the water are thus reduced.

The local treatment is somewhat different in the acute and the chronic forms, hence they will be considered separately.

Local Treatment of Acute or Subacute Eczema.—The remarks concerning the avoidance of plain water are especially applicable to this type of eczema. If proper care is exercised, some cases will get well with no local or constitutional treatment whatever. Others will persist in spite of any mode of treatment, and gradually pass into the chronic form. A soothing ointment composed of one dram of the oxide of zinc to the ounce

of lanolin or vaseline is very sedative, especially if the disease is due to an irritating discharge from the middle ear. The addition of one grain of the acetate of morphine will increase the sedative action of the ointment. Calomel dusted on the excoriated or fissured surfaces acts well in some cases. Lotions of liquor plumbi subacetatis and resorcin are indicated when there are large vesicated surfaces. As their application excites pain, the parts should previously be painted with a 5 per cent. solution of cocaine. Ichthyol in aqueous solution (2 to 50 per cent.) has proved a valuable remedy. The parts should be painted once or twice daily. Cotton pads may be applied over the painted surface to prolong the therapeutic effect of the remedy and protect the diseased area from the air.

When the case is in the crust-forming stage proceed as follows:

(*a*) Remove the crusts by first softening them for twenty-four to forty-eight hours by local applications of oil, vaseline, lanolin, balsam of Peru, or Burow's mixture, 10 per cent. strength. If the oily preparations are used, cotton should be saturated with them and applied over the scabs, and protected by another pad of gauze lightly held in position by a bandage. If Burow's mixture is used, the pads of cotton saturated with it should be covered with oiled silk or rubber cloth to prevent evaporation. Change every two hours.

(*b*) At the end of twenty-four hours the crusts may be removed with a probe or forceps. Great care should be exercised to avoid inflicting injury to the underlying surface, as to do so causes a larger crust to appear.

(*c*) The parts are now ready for the medicated ointments referred to above. They should be changed every day. The parts should be carefully cleansed each time by wiping them with cotton pads, water being carefully avoided. In obstinate crust formation the parts should be painted with a 1 to 3 per cent. solution of the nitrate of silver before reapplying the salve.

(*d*) When epidermization is established the new skin should be protected from mechanical or chemical (water) irritants by the use of simple ointments for several weeks. If this is not done recurrences are apt to take place and the hyperemia present in this stage exaggerated.

Local Treatment of Chronic Eczema.—It is rather difficult to outline a definite line of procedure in chronic squamous eczema, as so many remedies are recommended, none of which may be depended upon except in selected cases.

Those remedies which soften the scaly epidermis and reduce the hyperemia of the skin afford the best results.

To soften the scaly epidermis, vaseline, lanolin, or olive oil should be rubbed in once or twice daily; or a 10 per cent. solution of Burow's mixture may be applied as described above.

After thus softening and removing the horny layer, the parts should be painted with a 10 to 20 per cent. solution of the nitrate of silver. The author has used this method after the suggestion of Politzer, with the

greatest satisfaction. An immediate cure should not be expected, as several weeks are often necessary to effect it.

Fissures or cracks at the external auditory orifice are best treated with solid nitrate of silver or salicylic acid ointment.

Nearly all the ointments in the Pharmacopœia have been used in eczema, but further mention of them need not be made here. If the treatment according to the above principles fails, the case is probably one which will resist all treatment. In the event of failure take especial care to thoroughly soften the scaly epidermis and to remove it, and then use the silver solution again. Many of the failures are due to the non-observance of this procedure.

CHAPTER XXXVIII.

MALFORMATIONS AND DISEASES OF THE MEMBRANA TYMPANI.

In early life the upper portion of the membrana tympani may be absent, with no history of previous suppuration. This is explained by the fact that in the embryo this is the last portion of the membrane to form, and, the process not being complete, a perforation or opening persists. Von Tröltsch suggested that some of the perforations just above or behind the processus brevis mallei, such as are seen in otorrhea, are congenital, becoming enlarged by a subsequent suppuration within the tympanum. This observation may be questioned in certain particulars in view of the fact that the location of the perforation is usually indicative of the character and seat of the middle-ear involvement. For instance, a perforation in the region of the processus brevis mallei usually indicates a necrosis of the malleus, and possibly, also, of the tegmen tympani. We find that the perforation appears as readily in other portions of the membrana tympani if the focus of the middle-ear lesion is in other locations. Nevertheless, it may be said that a certain number of perforations in the region of the short process of the malleus may be of congenital origin, and that this portion of the membrana tympani is thereby rendered more vulnerable.

INJURIES OF THE MEMBRANA TYMPANI.

While injuries to the membrana tympani are comparatively rare, nevertheless, when they do occur it is important to know the proper method of procedure. They may be due to either direct or indirect violence.

Etiology.—*Injuries by direct violence may* be due to (*a*) attempts to remove the cerumen from the meatus with a pin, a hairpin, a toothpick, an earspoon, etc.; (*b*) the accidental thrust of any long slender instrument, tool, or splinter of wood; (*c*) the introduction of a caustic or a hot fluid into the meatus; (*d*) the fracture of the bone supporting the membrana tympani; (*e*) and, finally, sneezing, inflation of the ear, etc., may also rupture the membrana tympani.

Injuries by indirect violence may be due to (*a*) the violent and sudden compression of air in the meatus by a blow on the ear with the palm of the hand, or it may be due to (*b*) the concussion of the atmosphere during a violent explosion or discharge from a large cannon. In view of the more or less familiar occurrence of windows being blown inward at the time of an explosion, it may be readily appreciated how the membrana tympani may be ruptured by such an atmospheric disturbance.

Symptoms.—Pain is a prominent symptom in those cases in which there is severe reactionary inflammation, while it may be absent if there is little or no inflammation following the injury. In some the pain is only present at the time of injury. Hemorrhage, more or less severe, may immediately follow the injury, or in rare cases it may continue for an indefinite period. Faintness, giddiness, staggering gait, convulsions, and nausea characterize those cases in which the foot plate of the stirrup is forced inward, and in which the trauma irritates or otherwise injures the labyrinth. The loss of hearing may be partial or complete and temporary or permanent. The tinnitus at first appears as a loud noise, and then subsides until it is only moderate in severity or entirely disappears. The effects upon the hearing are various. Deafness may be so pronounced that the watch can only be heard by contact, or, on the contrary, the patient may suffer from hyperesthesia acoustica. When the labyrinth is injured the deafness may be pronounced or absolute. If the injury involves the semicircular canals, the equilibrium may be disturbed for a few days or weeks.

If the injury occurs in an ear in which the drumhead is adherent to the promontory, it may overcome the adhesions and thus affect the hearing favorably. In some cases the sense of direction of tones is lost, while in others there is simply a sense of fulness in the ears.

The rupture is usually located in the postinferior quadrant of the membrana tympani, the periphery not usually being involved, as the membrane is thicker and firmer near its border. The appearance of the rupture is usually a mere slit (dark line), varying in extent and shape. In other cases it may appear as a round perforation with ecchymotic spots scattered over the membrane. If the injury is inflicted by a blunt instrument the perforation is irregular or ragged in outline.

Cases have been reported in which there was an escape of cerebrospinal fluid from the ear, the foreign body having entered the labyrinth. The fluid may also escape into the middle ear when there is a fracture through the petrous portion of the temporal bone.

The ossicles of the middle ear, more particularly the malleus, are sometimes fractured. While the fractured parts reunite, they do not usually do so in their normal position. The author once saw a case in which the handle of the malleus was fractured about 1 mm. below the short process, the parts reuniting in nearly or quite their normal position.

Prognosis.—The prognosis is usually good, as the injury ordinarily consists of a simple laceration or perforation of the membrane. In those cases in which the labyrinth is involved the prognosis should be guarded. If the injury to the labyrinth consists of a perforation of its outer wall, a good result may be expected after the lapse of a few weeks. The giddiness and nausea may persist for one or more weeks. If the osseous walls of the middle ear are fractured, or if the ossicles are injured, the hearing may be permanently impaired. Should purulent inflammation complicate the case, the prognosis becomes more grave. The functional tests of hearing should be used in all cases of fracture or injury, as by them the

surgeon is enabled to draw conclusions as to the extent and location of the injury and as to the probable outcome of the case.

Treatment.—In nearly all cases no treatment should be used other than the introduction of a cotton or gauze tampon into the meatus to prevent infective matter entering through the wound. If, in spite of this simple precaution, marked inflammatory symptoms develop, leeches should be freely applied over the mastoid region and in front of the tragus, to promote the reaction of inflammation and thus aid in destroying the bacteria. Great care should be exercised in the treatment of these cases lest infection be carried into the wound and the case become complicated by suppurative inflammation of the middle ear and mastoid cells, hence meddlesome treatment is to be condemned.

MYRINGITIS; INFLAMMATION OF THE MEMBRANA TYMPANI.

Etiology.—Myringitis may be primary or secondary. The primary form is rare, and when present it is usually due to an injury by a foreign body, instrumentation, or the introduction of caustic fluids into the meatus. Secondary inflammation of the membrana tympani is more common, and is due to an extension of an inflammatory process from the auditory meatus or the cavum tympani. Thus, in the various forms of dermatitis and acute otitis media catarrhalis it is often present.

Symptoms.—The chief symptoms are pain, more or less severe in character, with a slight rise in temperature. Deafness and tinnitus are present in proportion to the local injury and the swelling of the membrana tympani and the nature of the associated middle ear disease.

Objective Symptoms.—The membrana tympani is usually most affected in its upper portion and especially along the line of the handle of the malleus. In this region it is yellowish red in color, from the congestion present. In a few days or hours the handle is lost to view, owing to the intense congestion and infiltration of the membrane, the upper portion of which bulges outward into the canal. The epidermic layer may become separated from the fibrous or middle layer of the eardrum by the serous or seropurulent fluid which accumulates between them. Blisters or blebs sometimes form. The inflammatory process may involve the osseous portion of the canal and thus obliterate the line of demarcation between the eardrum and the canal.

The *mode of termination* is by slow resolution, the signs of inflammation often persisting for many weeks. In some cases fatty degeneration or even calcareous deposits may be left in the wake of the disease.

Abscess of the membrana tympani may occur in the course of an acute otitis media. The process is confined chiefly to the fibrous and the mucous membrane layers, in contradistinction to the blisters which may form under the dermic or outer layer.

Vesicular or *herpetic eruptions* sometimes complicate myringitis, as referred to above.

Hemorrhagic eruptions similar to those described under Otitis Externa Hemorrhagica are occasionally present.

Diagnosis.—The chief diagnostic point is to be found in the *slight disturbance of hearing.* The ear appears to be extensively and seriously involved, while the hearing is but slightly impaired. The appearance is much like that of acute suppurative otitis media, but the loss of hearing is slight as compared with that found in the latter disease. Moreover, in suppurative otitis media the drum membrane bulges more markedly into the canal.

Prognosis.—The prognosis must be based upon a knowledge of the eitology of each case and upon the destructive or degenerative changes occurring in the membrana tympani. If the myringitis is due to a severe injury, or if fatty degeneration and calcareous deposits are in the substances of the membrana tympani, the prognosis is less favorable than when the case is simple in origin and of slight severity. On the other hand, if perforation takes place and chronic suppurative otitis media supervenes, the prognosis is still more unfavorable.

Treatment.—The treatment is (*a*) general, (*b*) local, and (*c*) surgical. The general treatment should consist in the administration of tonics, the iodides, and cod-liver oil if the patient is the subject of any of the dyscrasias; saline cathartics should also be administered. The local treatment should consist of the application of natural or artificial leeches to the mastoid process, to increase the hyperemia and leukocytosis, *i. e.*, promote the reaction of inflammation. The instillation of solutions of cocaine are advised, but are of doubtful utility unless used in the following combination:

℞—Cocaine hydrochloratis,
Menthol crystals,
Carbolic acid crystals, ... āā ʒj—M.

Sig.—One or two drops in the fundus of the auditory meatus will relieve the pain in from five to fifteen minutes.

The parts are at the same time anesthetized and prepared for the opening of the abscess in the membrana tympani if it is present. The remedy should be used with some caution, as it is liable to be absorbed in sufficient quantity to cause toxic symptoms. The instillation of alcohol into the meatus dilutes the solution and facilitates its removal if it should become necessary.

The *surgical treatment should* consist in the incision of the outer or dermic layer of the membrana tympani. In those cases complicated by abscess care should be exercised to avoid perforating the inner layer, as infection might thus be carried to the middle ear. Gruber recommends making incisions in the osseous portions of the auditory meatus near the membrana tympani. The incisions should be about ⅛ inch long and parallel with the circumference of the drumhead, so as to incise the arterial branches at its circumference. The hemorrhage thus induced promotes the reaction of inflammation and favors resolution.

After the abatement of the acute stage a serous discharge is given off from the membrana tympani and the painful symptoms subside. The ear should now be irrigated with a warm boric acid solution, dried, and the meatus closed with absorbent cotton.

The cavum tympani (middle ear) may be inflated by the Politzer method, the diagnostic tube being used to determine if a perforation is present. The membrana tympani should also be inspected for the same purpose. If a perforation is present the diagnostic tube conveys the whistling sound characteristic of a perforation to the examiner's ear. The membrana tympani may be so swollen that the perforation cannot be seen. The pus discharging into the meatus is another index as to the presence of a perforation. This is rendered all the more probable if the discharge contains strings of mucus. The presence of a perforation and chronic otitis media render the prognosis more serious.

PERFORATION OF THE MEMBRANA TYMPANI; ULCERATION OF THE DERMIC LAYER; CHRONIC MYRINGITIS; CHRONIC INFLAMMATION OF THE DRUMHEAD.

Etiology.—The causes leading to perforation of the membrana tympani may be either *external* or *internal*. One of the *external* causes is acute myringitis, with local fatty degeneration and subsequent sloughing of the substance of the drumhead, the degenerative process beginning with the outer layer and extending inward. Another external source is acute dermatitis of the external meatus. This may extend to the drumhead and result in the same degenerative and perforative process. In many instances the fatty degeneration is not followed by perforation, calcareous changes occurring instead.

In some cases the destructive process is limited to a simple ulceration of the dermic layer, which may appear as a simple circumscribed roughness of the surface or as a reddened area where the epidermis is removed.

The *internal* causes of perforation or chronic inflammation are either the acute catarrhal or the acute suppurative forms of otitis media. The mucous layer of the drumhead first undergoes the ulcerative process, the fibrous and the dermic layers giving way at subsequent periods. The membrana tympani may long remain the seat of chronic inflammation, the bloodvessels being injected and radiating from the margins of the ulceration or perforation.

Symptoms.—If the lesion is simple—a superficial dermic ulcer—the symptoms are slight, tinnitus and a moderate disturbance of hearing being present. If the ulcer is phlegmonous in type, pain and increased deafness are present. The secretions and the exfoliation of epidermis form crusts on the surface of the membrana tympani and obscure the real lesion until they are removed. Granulations may spring from the bottom of the ulcer.

In those cases in which there is perforation the tinnitus and the deafness are more pronounced. If the middle-ear cavity is not primarily infected, it becomes so through the perforation. Pus is discharged through the opening into the external auditory meatus. If the ear is inflated by the Valsalva, the Politzer, or the catheter method, a whistling

noise may be heard through the diagnostic tube. Inspection, after removing the debris from the auditory meatus, usually reveals the perforation. It is often oval, though it may be round, pear- or kidney-shaped. Its location generally indicates the focal centre involved within the middle ear or the accessory mastoid cavities.

Course.—The duration of chronic inflammation of the membrana tympani, with or without perforation, is usually quite prolonged. The dermic layer often undergoes repeated or continuous desquamation, or there may be foci of fatty degeneration with calcareous deposits. In some cases there is an atrophic process which renders the membrane thin and parchment-like, its function being thereby impaired. In still other cases of external origin perforation occurs, and is followed by infection and suppuration within the middle ear. This may continue indefinitely, or until ulceration and necrosis of the bony walls of the middle ear and the pneumatic spaces of the mastoid process occur.

Treatment.—In those cases in which there is an active desquamation or dermic ulceration, the crusts should be softened with a warm solution of bicarbonate of soda, and then removed by syringing with a warm solution of boric acid. The author's experience has justified the local application of a 10 gr. solution of the nitrate of silver or of the compound tincture of benzoin. The nitrate of silver stimulates healthy granulation and regeneration, and the compound tincture of benzoin is astringent and stimulates the process of repair.

If perforation has taken place and the cavum tympani is not yet infected, an endeavor should be made to bring about regeneration of the membrana tympani, thus closing the perforation. This may be done by maintaining the external auditory meatus and the membrana tympani in an aseptic condition, stimulating applications being made to the margins of the perforations, with the view of favoring granulation at the margins of the perforation until the opening is completely filled in. Various devices and procedures have been employed for this purpose, the best one being the local application of a 20 per cent. solution of trichloracetic acid.

For the treatment of the middle-ear complications see Suppurative Diseases of the Middle Ear.

INCISION OF THE MEMBRANA TYMPANI.

This mode of treatment is coming into vogue more than formerly, as clinical experience has demonstrated that when it is done at the proper time the attack of acute inflammation of the middle ear is aborted. Its effects are due to the promotion of the reaction of inflammation and the facility with which drainage of the tympanic cavity is accomplished. The presence of the inflammatory exudate within the cavum tympani is a source of irritation because of its chemical composition and on account of the pressure it exerts upon the swollen and inflamed mucous membrane. It is, therefore, important that free drainage be established at a very early period in the course of the disease. Formerly, it was recommended

that simple puncture of the drumhead be made for this purpose. Hovell advocates this procedure. I cannot recommend so slight an incision, as I find that a free incision is attended by more immediate and better results. Little harm results from free incision of the membrana tympani, as union often takes place before it is desirable that it should do so. Even when union does not occur early, only a very slight amount of scar tissue is left behind.

Fig. 355

Right membrana tympani, showing the division into *A*, postsuperior quadrant; *B*, anterosuperior quadrant; *C*, antero-inferior quadrant; *D*, postinferior quadrant.

One *should not wait* until there is bulging of the membrana tympani, but should make an incision whenever he finds there is marked redness and thickening. The membrana tympani may be so swollen and red that the outline of the malleus cannot be distinguished. If the incision is delayed until bulging of the drumhead occurs, serious and extensive pathological changes may take place; whereas if it is done early the

Fig. 356

Ear instruments.

progress of the disease is checked and the process of resolution is established. The incision increases hyperemia and leukocytosis, and thus raises the resistance of the tissue and destroys the microörganisms.

The *most suitable place for the incision* is in the posterior inferior quadrant (Fig. 355), as this is generally the most accessible, owing to the curvature of the anterior wall of the external auditory meatus, which obstructs the view of the anterior portion of the membrana tympani.

The best instrument for this purpose is a curved bistoury (Fig. 356). The lance-shaped or the spear-pointed knives are not well adapted for this purpose, as they are made for simple paracentesis. The point of the knife should be introduced only far enough to penetrate the thickness of the membrana tympani, as to pass it deeper might subject the inner wall of the cavum tympani to injury. It should be remembered that the distance from the outer to the inner wall is only about $\frac{1}{12}$ to $\frac{1}{6}$ inch. The incision should be curved or V-shaped (Fig. 357), so as to allow a wider opening between the lips of the incision. In this way free drainage is established. The incision should be from $\frac{1}{4}$ to $\frac{3}{8}$ inch in length.

Immediately after the incision a bead of viscid mucus may be seen protruding through it. The contents of the tympanic cavity are not discharged at once unless they are of a fluid nature. To hasten the discharge of the viscid mucus, a solution of boric acid or bicarbonate of soda may be dropped into the meatus to liquefy it.

Fig. 357

Showing a long, curved incision through the membrana tympani for the evacuation of inflammatory secretions. With such an incision the anterior flap is forced aside by the secretions as indicated by the dotted line, thus providing free space for drainage. A simple puncture or paracentesis as shown by the short line is inadequate and should not be practised.

Previous to the incision the external auditory meatus should be cleansed with a 1 to 4000 solution of bichloride of mercury to render the membrana tympani and the auditory meatus sterile. Anesthesia of the membrana tympani may be obtained by dropping a small quantity of a solution composed of equal parts of hydrochlorate of cocaine, menthol, and carbolic acid into the auditory meatus. In from five to fifteen minutes complete anesthesia is produced, and the incision may be made with comparatively little or no pain. Complete absence of pain is not always obtained, however, as it should be remembered that the parts contiguous to the membrana tympani are often inflamed and sensitive.

Immediately after the incision the auditory meatus should be dried with a cotton-wound applicator and then loosely packed with sterilized gauze. The end of the strip of gauze should be made to touch the incised portion of the drumhead, while the balance is placed loosely in the meatus. It should be left in place until it becomes saturated with the secretions, when it should be removed and a fresh one introduced.

During the first two or three days it may be necessary to pack the meatus two or more times a day. The patient should be kept in bed during this time, as much more favorable and rapid progress may be made under such conditions. After the first few days it is not necessary to dress the meatus so often, once a day being quite sufficient. A little later every other day will be all that is necessary. The dressings should be discontinued when the discharge through the incision ceases and it has closed.

After the incision is made the use of the syringe with any sort of solution is not allowable, as infection may thereby be conveyed through the opening into the tympanic cavity. When the acute inflammation has somewhat subsided, inflation by the Politzer method through the Eustachian catheter should be performed, as the drainage is thus facilitated.

Spontaneous perforation of the drumhead may take place in the course of the disease from softening of the tissues by maceration or from pressure necrosis. As already stated, this should be anticipated if possible, either by instrumental perforation of the drumhead or by one or more of the remedies which have been recommended. Should spontaneous perforation occur the treatment instituted should be similar to that recommended after incision of the membrana tympani.

Paracentesis is an almost obsolete from of incision, and is not given as synonymous with incision, as by the latter expression is meant a larger and more extensive opening in the drumhead than is implied by the former. By paracentesis is meant a mere puncture through the membrane with a double edged or spear-pointed knife. What follows, therefore, refers to some form of incision and not to a mere puncture of the drumhead.

The *general purposes* of incision of the membrana tympani are: (*a*) To relieve pain; (*b*) to establish drainage for excessive secretions (catarrhal and suppurative); (*c*) to open the middle ear for certain operations; (*d*) to relieve intralabyrinthine pressure; (*e*) to allow sound waves to reach the oval and round windows; and (*f*) to promote the reaction of inflammation.

The indications for incision, as briefly outlined in the preceding paragraphs, may be amplified as follows:

1. In otitis media with excessive secretion it may become necessary to make a free incision to prevent pressure necrosis of the drumhead and the tympanic mucosa. The secretion is often so thick and tenacious that it will not discharge through the Eustachian tube. Retention also causes pain and favors decomposition and infection. The incision also promotes the reaction of inflammation (see Inflammation), and thus favors speedy resolution.

One should not wait until pronounced pain develops, bulging of the membrane being ample justification for the procedure. Should pain persist without bulging, the incision should be made, as it promotes the reaction of inflammation and thus favors resolution.

2. In acute myringitis abscess formations sometimes occur between the layers of the membrana tympani. They should be opened, care being taken not to open the inner or mucous layer. To open this exposes

the middle ear to the dangers of infection from the abscess. If the abscess is not evacuated in this way, there is danger of perforation of the inner layer and infection of the middle ear.

Pearly gray blisters sometimes appear on the membrana tympani, and they should be pricked, for if left to discharge spontaneously the danger of infection is prolonged.

Inflammation of the deeper layers with bulging and purplish swelling should be scarified to relieve the pain and the tension. Incisions through the entire thickness should not be attempted, for the reasons already stated.

3. Tenotomy of the tensor tympani muscle is sometimes performed to relieve deafness and tinnitus. (See Tenotomy of the Tensor Tympani Muscle.) The preliminary step in the operation is an incision of the membrana tympani.

4. A *thickened* membrana tympani from hyperplasia in chronic catarrhal otitis media is often present; obstruction of the Eustachian tubes is also present. The rarefaction of the air within the tympanum gives rise to retraction of the membrana tympani and pressure upon the labyrinthine fluid by the foot plate of the stapes. The drumhead may be incised as a temporary measure, or a portion of the drumhead may be removed with a knife or cautery to admit air into the middle ear when the Eustachian tube is obstructed. All such measures have met with but partial or temporary success, the opening usually closing within a few days.

The relief is often pronounced while the perforation remains open, but quickly disappears after it closes.

Malherbe has written extensively upon what he terms "Evidement of the Mastoid," whereby a channel of communication between the tympanic antrum and the external acoustic meatus is established, thereby permanently overcoming the disturbance due to the closure of the Eustachian tube.

5. *In acute catarrhal otitis media* attended by pain, bulging, and marked inflammatory infiltration, incision or scarification is often indicated to promote the reaction of inflammation and to establish drainage. If there is persistent pain with or without bulging of the membrana tympani, incision is indicated. The relief which follows may be due to the hemorrhage, for in many cases there is no discharge of secretions for several hours after the incision, though it is more probably due to the promotion of the reaction of inflammation. (See Inflammation.)

When there is a livid, boggy appearance of the membrane it should be freely scarified, limiting the incisions to the outer layer. Circumscribed red spots sometimes appear in the course of the disease. They should be opened to hasten the process of resolution.

The most bulging portion of the membrana tympani may appear yellowish green in color, even though the secretion is but little admixed with pus. Free incision should be made to establish drainage and to relieve the pressure necrosis which is beginning on the inner surface of the membrana tympani.

6. *Acute suppurative otitis media* affords the most common opportu-

nity for incision of the membrana tympani, although it is often postponed until voluntary rupture occurs. The presence of pus within the middle-ear cavity when the drumhead is still intact is an imperative indication for incision. It is not necessary to wait for pain and bulging of the membrana tympani; in fact, it is *culpable negligence* to do so, as every hour adds to the destruction of tissue. *Incise the membrana tympani at once when the presence of pus is suspected in the middle ear*, as it is of the greatest importance to promote the reaction of inflammation to combat the bacteria and their toxins.

The perforation in acute suppuration is usually small, hence it should often be enlarged by radiating incisions toward the periphery (Fig. 358).

Persistent pain without bulging or profuse discharge of pus is an indication of retained pus within the antrum and mastoid cells. The incision in these cases should include the pars flaccida (Shrapnell's membrane), so as to afford a direct outlet from the attic and to increase the reaction of inflammation.

Fig. 358

Showing two perforations of the membrana tympani and the incisions for facilitating drainage through them. The incisions should extend at an angle to the axis of the perforation so as to form movable flaps, which may be pushed aside by the secretions.

7. *Adhesive processes in the middle ear* sometimes give rise to conditions which can be more or less relieved by incising the membrana tympani. The adhesive process may interfere with the vibratory action of the ossicles without the foot plate of the stapes being ankylosed. The opening in the drumhead admits sound waves into the tympanum where they strike the foot plate of the stapes, and fairly good hearing results. The tinnitus which is associated with the deafness is also relieved to some extent. As it is not practicable to maintain the opening for any considerable length of time, the procedure has almost fallen into disuse.

Calcareous deposits in the membrana tympani are often found associated with adhesive processes. They act as foreign bodies and impair the vibratory function of the membrana tympani, and an opening, as above stated, admits sound waves directly to the oval window. Besides this, the equilibrium of air pressure is thereby established and the pressure on the labyrinth by the ossicles is somewhat lessened.

Through the opening it is sometimes possible to sever fibrous bands which extend from the malleus and incus to the walls of the tympanum. While the beneficial effects thus obtained are not long continued, the

temporary relief is marked and extremely gratifying to the patient. They are much depressed in spirits, and the temporary respite adds to their happiness. It should be frankly explained that the beneficial result will in all probability not be permanent.

8. Atrophy and relaxation of the membrana tympani from too frequent inflation or other causes may be improved by light scarification with a sharp-pointed bistoury. Only the outer and the middle layer should be cut through. In this way scar tissue and blood supply will be increased, and the tension and tone of the membrane raised, with benefit to the hearing.

9. Exploration of the middle ear and the attic sometimes becomes necessary in chronic suppuration. This is best done when the opening in the membrana tympani is high, as the roof or tegmen is usually necrosed. If, therefore, the perforation is small or in the lower portion of the drumhead, it may be necessary to extend it by incision in an upward direction. Having done this a small curved ear probe may be introduced into the attic for exploratory purposes.

Preliminary examination of the function of hearing should be made before incising or removing a portion of the drumhead to improve hearing in adhesive processes of the middle ear. Unless bone conduction for the watch and the c_2, 512 v., fork is good, but slight improvement will follow the operation.

The middle and the lower portion of the posterior half of the membrana tympani is less sensitive than the upper portion, the sensitiveness gradually increasing as the upper limit is approached. Blake takes advantage of this fact and punctures the membrane in its least sensitive area, then applies cocaine to the cut surfaces, waits a few minutes, and extends the incision slightly upward, applies more cocaine, and so on until the incision is extended the desired length.

He also recommends the injection of a 2 per cent. solution of cocaine through the Eustachian catheter into the middle ear, as a means of producing anesthesia of the membrana tympani in middle-ear operations.

Dupuy recommends the following mixture as a reliable local anesthetic in eardrum and middle-ear operations:

℞—Aniline oil,
Alcohol . . . . . āā ʒj
Cocaine hydrochlorate . . . . . gr. vj—M.
Sig.—Drop into the meatus and middle ear.

This mixture does not always produce local anesthesia, as in a number of cases it has failed in my hands, notably in aural polypi.

More or less cyanosis occasionally attends its use, hence it should be used with caution.

The following mixture is more reliable and less dangerous:

℞—Cocaine hydrochlorate,
Menthol crystals,
Carbolic acid crystals . . . . . āā ʒj—M.
Sig.—Drop into meatus or middle ear, and in twenty minutes anesthesia is complete.

Methods of Operating.—The electrocautery may be used in adhesive non-inflammatory cases. The opening thus made persists longer than one made with a knife. The points to be observed are the following:

(*a*) Preliminary local anesthesia should be produced by the injection of a 2 per cent. solution of cocaine into the middle ear through a Eustachian catheter or the above formula may be used.

(*b*) The electrode should be a simple straight, pointed one with the shank so bent that the electrode handle and the hand of the operator will not obstruct the view.

(*c*) The current should be turned on until the point is instantly raised to a bright-red heat. If the platinum point heats too slowly the adjacent parts may be injured by the radiation of heat. The pressure exerted by the electrode should be slight, as otherwise there is danger of injuring the mucous membrane of the inner tympanic wall.

(*d*) Contact should be made with the drumhead before the electric current is turned on.

(*e*) Usual time of heat contact, one second.

Incision with a Lancet.—Preference should be given to Hartman's curved lancet (Fig. 356), the spear-pointed instruments formerly used being of little value except for simple puncture.

The most favorable or available location for incision in adults is the posterior half of the drumhead. In children the external meatus is shallow and straight, so that all portions of the drumhead are accessible.

Other things being equal, the most bulging portion (fluid being present) should be incised, because it is the point of least resistance and because the parts are not so sensitive in this area. Indeed, if bulging is pronounced, the incision can often be made without the use of a local anesthetic.

The length, direction, and character of the incision should depend upon the purpose for which it is made. If it is done to establish *free drainage*, it should be long and curved, or angular (Fig. 359). If it is to expose the contents of the middle ear, as for operations upon adhesive bands and upon the stapes, the incision recommended by Blake (Fig. 360) should be made. If it is for the purpose of admitting air to the middle ear, a round or triangular opening may be made. The cautery is well adapted for this purpose. If it is done preliminary to tenotomy of the tendon of the tensor tympani, or for plicotomy, a short straight incision (Fig. 361) is all that is necessary.

Postoperative Considerations.—(*a*) When the *incision* is made to evacuate mucus or mucopus, a pulsation synchronous with swallowing and articulation will occur at the point of incision. Pus and mucus rarely appear immediately after the incision. This is quite disconcerting to the inexperienced aurist, as he may have unwittingly promised an immediate evacuation of the secretions. A little experience will, however, convince him that on account of the thick and adhesive character of the secretions they will only appear several hours after the incision is made. The expulsion of the secretions can be hastened by instilling a warm solution of bicarbonate of soda into the middle ear. The soda overcomes the adhesive property of the mucus and thereby facilitates its discharge.

Sometimes the mucus is so thick and tenacious that it can be seized with forceps and thus removed. It may also be removed by suction with the Delstanche masseur.

(*b*) Closure of the incision in non-suppurative cases usually occurs in from one to three days. In suppurative cases it may remain open a few days or be indefinitely prolonged.

FIG. 359

FIG. 360

FIG. 361

FIG. 359.—Showing a long, curved incision of the membrana tympani extending into the superior wall of the meatus (white line). As there is a plexus of bloodvessels around the margin of the membrana tympani greater reaction of inflammation is produced by extending the incision through it, hence the improvement of the inflammation is more prompt than in simple incision of the membrane. (See Reaction of Inflammation.)

FIG. 360.—Incision for stapedectomy, showing the inendostapedial articulation. The stapedius muscle should be severed to prevent the dislocation of the stapes, the inendostapedial articulation broken, and the stapes removed from the oval window. This operation is rarely justifiable.

FIG. 361.—Showing an incision through the posterior fold of the membrana tympani to relieve the tension of the membrane in adhesion processes.

(*c*) The *dressing* should consist of a strip of sterilized gauze placed loosely in the meatus but touching the drumhead. If the discharge is profuse a pad of the gauze may be placed over the auricle and held in position by a bandage. The meatus and the auricle should first be cleansed with a 1 to 3000 bichloride solution before introducing the gauze dressings.

CHAPTER XXXIX.

THE DISEASES OF THE EUSTACHIAN TUBES.

THE RELATIONSHIP OF THE EUSTACHIAN TUBES TO HEARING AND MIDDLE-EAR DISEASES.

THE Eustachian tube is the chief source of communication between the epipharynx and the middle ear. Through it the tympanic cavity is ventilated and the normal tension of the drumhead and the ossicular chain is maintained, thereby facilitating the transmission of sound waves to the internal ear. The pharyngeal end of the tube is supported by cartilage, while the tympanic end has an osseous framework. At the union of the cartilaginous and the osseous portions the tube becomes narrow, forming what is known as the isthmus. The throat end is subject to the diseased processes peculiar to the epipharynx, while the tympanic end is affected by the changes peculiar to the tympanic cavity. In other words, the throat end is subject to pronounced catarrhal and suppurative inflammations and to hypertrophy of the lymphoid tissue lining the mucous membrane, and the tympanic end to catarrhal and adhesive changes in addition to the suppurative process. The adhesive process is, therefore, chiefly found in the less accessible portion of the tube—namely, beyond the isthmus, and consequently difficult to reach with electrolytic bougies or those used for the purposes of simple dilatation.

The relationship of the Eustachian tube to the diseases of the tympanic cavity is twofold—namely: (*a*) Obstruction of its lumen by catarrhal congestion, hypertrophy, cicatricial contraction, and mucous plugs; and (*b*) as an avenue through which infective material may gain entrance to the middle ear. The obstructive lesions or accumulations prevent the proper ventilation of the tympanic cavity, and the contained air becomes rarefied through gradual absorption of the oxygen, thus causing retraction of the drum membrane and engorgement of the bloodvessels of the mucous membrane.

The retraction of the drumhead increases the tension of the ossicular chain, and interferes with the normal transmission of sound waves to the labyrinth. Tinnitus and deafness thus result. The obstruction to drainage lowers the resistance of the tissues and predisposes to infection and inflammation.

Infectious material may gain entrance into the middle ear during acts of yawning, coughing, sneezing, or swallowing. The tube is lined with ciliated columnar epithelium, having a wave-like motion toward the pharyngeal orifice. In the healthy state it is not probable

that bacteria travel toward the middle ear on the mucosa. If, however, the catarrhal inflammation of the lining membrane of the tube is severe or prolonged, the epithelium may lose its cilia, and it is not improbable that germs do sometimes reach the middle ear without the tube being opened by the acts of coughing and sneezing.

Tubal tonsils, or *hypertrophy* of the lymphoid tissue in the mucous membrane of the cartilaginous portion of the tube is another possible source of obstruction. A study of the histology of this structure shows lymphoid tissue to be present in considerable quantity, and it is more than probable that hypertrophy of this tissue is often responsible for tubal and middle-ear disturbances heretofore ascribed to catarrhal or other diseases.

TUBAL CATARRH; CATARRHAL INFLAMMATION OF THE EUSTACHIAN TUBE; SALPINGITIS.

Etiology.—Owing to the intimate anatomical connection of the mucous membrane of the Eustachian tubes with that of the epipharynx, it is easy to understand why they are usually involved in the course of an attack of epipharyngeal inflammation. If the epipharyngitis is chronic in character, the tubal disease is likewise chronic. While tubal catarrh is usually secondary to a like process in the epipharynx, it is not always so, especially in children, in whom it is sometimes primary. In young children the pharyngeal orifice is narrow and easily retains the secretion and foreign matter. For this reason local inflammation may occur in the tubes independently of the epipharynx.

Adenoid growths are often associated with a chronic epipharyngitis, which extends by continuity of tissue to the tubes. The adenoids do not often afford a mechanical obstruction to the patency of the tubes, as they grow from the posterior and superior walls of the epipharynx, and, therefore, do not involve the regions of the Eustachian orifices on the lateral walls. In some instances, however, they overlap the mouths of the tubes and thus obstruct them. Tuberculosis may be associated with adenoid growths and predispose to tubal inflammation.

Pathology.—Congestion and round-cell infiltration characterize the early and acute stages of the disease. At a later period the epithelial covering becomes thickened, and fibrous tissue is deposited in the subepithelial layers. Hypertrophy of the mucous membrane occurs when the inflammation continues for a long time. If the inflammation is severe or prolonged the cilia are exfoliated, thus leaving the membrane denuded in places. The catarrhal inflammation may extend to the middle ear, although it has a tendency to limit itself to the pharyngeal or cartilaginous portion of the tube.

Symptoms.—The subjective symptoms are a feeling of fulness in the ears, which may be constant or intermittent, accompanied by certain subjective noises and deafness. Pain is not usually severe, although it may be if the inflammation is pronounced. If there is marked retraction of the drumhead, giddiness and nausea may be complained of. The

sense of deafness is often out of proportion to the actual deafness. The patients apply for relief with the statement that the external canal is filled with cerumen. During mastication and swallowing they often experience marked, though brief, relief from the symptoms. This is explained by the incidental, but incomplete, ventilation of the tympanum during the act of swallowing. Upon *posterior rhinoscopy* the mucous membrane of the epipharynx and the Eustachian orifices appears reddened, swollen, and covered with a thick mucous secretion. The mouths of the tubes are contracted by the swollen membrane, and may contain a thick, tenacious mass of mucus. If adenoids are present, the furrows between the lobules are more or less filled with a slimy secretion admixed with pus. The ethmoidal and sphenoidal sinuses may also be the seat of inflammation. With good illumination it is possible to see the enlarged and tortuous bloodvessels in the inflamed area.

The drumhead is more or less changed in its position and appearance by the rarefaction of the air in the tympanic cavity. It is more cupped, the handle of the malleus is foreshortened, and the short process and the posterior fold extending from it are more prominent. The angle formed by the handle of the malleus and the posterior fold becomes more acute with the increased retraction. The cone of light is diminished, broken, or altogether wanting. If the drumhead is extremely retracted, the promontory and the long process of the incus become visible through it.

Prognosis.—The prognosis is good in those cases in which adenoid growths are removed, especially in children. It is also good in the early, or congested stage of the simple catarrhal type. In the hypertrophic stage it is not so good, as the obstruction is more permanent in character.

Treatment.—The treatment of tubal catarrh should be largely addressed to the antecedent nasal and epipharyngeal conditions. If there is pronounced nasal catarrh, sinuitis, nasal obstruction, or epipharyngitis, it should receive appropriate treatment; likewise adenoids should be removed. Removal of the adenoids is usually followed by pronounced and immediate relief. Having corrected the nasal and the epipharyngeal disorders, the tubal inflammation often subsides without further treatment. Such a favorable result does not always follow, however, especially if the mucosa has become hypertrophic or hyperplastic in character. In many cases there is a mixture of turgescence and hypertrophy, local medical applications only being capable of removing the congestion and limiting the further development of the hypertrophic process.

Perhaps the most useful mode af applying remedies to the vault of the pharynx and the Eustachian orifices is in gargling after the von Tröltsch method. The patient should lie on his back while gargling to allow the fluid to enter the epipharynx. This is not difficult, as the head can be turned to one side in taking the fluid into and in ejecting it from the mouth. By following this method of gargling the whole of the epipharynx, including the Eustachian orifices and the nasal chambers, may be subjected to the influence of astringent and antiseptic remedies, with very favorable results. The deafness and tinnitus are often relieved.

The injection of from 1 to 4 minims of weak astringent solutions into the Eustachian tubes through a catheter is recommended. Care should be taken to avoid injecting it into the middle ear, as reactionary inflammation might follow. The syringe should be so gauged as to fill the catheter and leave a surplus of from five to ten minims. The extra solution is to allow for the inevitable escape of fluid into the epipharynx. The nose and the epipharynx should be sprayed with a 2 per cent. solution of cocaine to reduce the sensibility of the parts before introducing the catheter. The solutions most often used are (*a*) the iodide of potassium, 10 gr. to the ounce; (*b*) the bicarbonate of soda, 3 to 5 gr. to the ounce; (*c*) the sulphate of zinc, 1 gr. to the ounce; and (*d*) the nitrate of silver, 2 to 5 gr. to the ounce.

Various vapors of iodine, ammonia, menthol, camphor, eucalyptol, etc., have been recommended. Iodine and ammonia are readily volatile, and the fumes therefrom may be sufficiently generated in a Buttles-Pynchon inhaler, as shown in Fig. 362. The inhaler should be connected with the catheter and air forced through it into the Eustachian tube.

Fig. 362

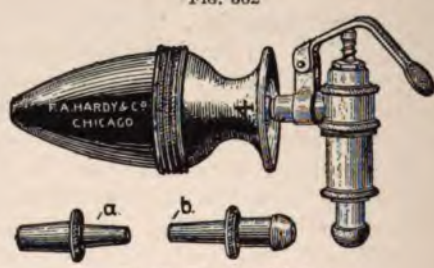

Buttles-Pynchon inhaler.

A piece of sponge or cotton should be moistened with the desired solution and placed in the chamber of the inhaler. Another way of using the vapors of the foregoing drugs, either singly or in combination, is with a nebulizer. Either the nebulizer may be attached to the Eustachian catheter, or the vapors may be driven into the middle ear by the modified Politzer method, in which the nebulizing device takes the place of the rubber bag used by Politzer, the balance of the procedure being done according to the directions given under the Politzer method The author has often put a few drops of the desired volatile solution into the Politzer bag and then practised inflation in the usual manner, the fumes being carried into the tubes and the middle ears.

The value of the foregoing topical remedies does not consist alone of the medicinal properties of the drugs, but includes the mechanical effects of inflation. The current of compressed air directed into the orifice of the Eustachian tube removes the secretions and temporarily unloads the congested vessels and establishes normal glandular activity.

The principles to be observed in the treatment of tubal catarrh may be summarized as follows:

(*a*) The correction of obstructive nasal lesions, and of inflammatory diseases of the nose and accessory sinuses.

(*b*) The removal of neoplasms and inflammatory conditions in the epipharynx.

(*c*) The topical application of antiseptic, astringent, and stimulating remedies to the mucosa of the Eustachian tubes.

(*d*) The mechanical effects of inflation.

(*e*) The administration of remedies to give tone and vigor to the general system.

It should be said, in reference to the latter principle, that in many cases of deafness from tubal catarrh the administration of tonics and other constructive remedies is often followed by an improvement in hearing. This is especially true in those cases in which there is no pronounced nasal or epipharyngeal disease to account for the trouble. It is usually best to begin the treatment with a 2 to 3 gr. dose of calomel at bedtime, followed by a saline cathartic the following morning. After this, laxative doses of cascara may be given twice daily. The patient's alimentary tract is thus kept in a condition to care for and distribute the constructive remedies. These remarks are equally applicable to all the catarrhal affections of the upper respiratory tract.

The Relation of the Eustachian Tube to Mastoiditis. — The Eustachian tube is adequate to drain all secretions from the middle ear, but it is often inadequate to drain the combined secretions of the middle mastoid antrum and cells, hence retention, pressure necrosis, and all the phenomena peculiar to mastoiditis. If the secretions from the antrum and mastoid cells are diverted from the middle ear, the Eustachian tube effectually drains the middle ear, and the diseased process rapidly improves. (See Heath's Mastoid Operation.)

OBSTRUCTION OF THE EUSTACHIAN TUBE.

Partial Obstruction.—Etiology.—Obstruction of the Eustachian tube may be due to a variety of conditions, namely: (*a*) Hypertrophy of the mucous membrane, especially that in the pharyngeal or cartilaginous portion, the hypertrophy being an extension of the same process from the nose and the epipharynx. (*b*) Repeated inflammations, giving rise to a hyperplastic thickening and consequent obstruction. (*c*) Adhesive bands or constrictions forming in either the tympanic or the pharyngeal end of the tube, especially if the same pathological process is going on in the tympanic cavity. (*d*) Syphilis, tuberculosis, and diphtheria at the pharyngeal orifice, causing cicatricial contractions which more or less obstruct the opening. (*e*) Adenoids, while they do not grow from the Eustachian orifice, may be so large as to overlap and thus close it. (*f*) Paralysis of the palatal muscles from diphtheria and mixed infection, or from degenerative changes of the muscular fibers from repeated inflammations coincident with tonsillar inflammation, giving rise to collapse of the muscular and other soft tissue at the

pharyngeal orifice and thus causing its occlusion. (*g*) Adhesions of the posterior pillars to the tonsils by interfering with the muscular movements contribute to the collapse of the Eustachian orifices. (*h*) Certain anatomical features give rise to obstruction, as exostoses and hyperostoses of the walls of the tubes; there may be a sudden bend in the direction of the tube, or the carotid canal may encroach upon it and thus obstruct it.

Diagnosis.—The diagnosis may be made by observing the characteristic retraction of the drumhead, foreshortening of the handle of the malleus, and the prominence of the short process and the posterior fold of the tympanic membrane. Postrhinoscopic examination may show either cicatricial contraction, overlapping adenoids, or collapse of the Eustachian orifice. The pillars (glossopalatine and pharyngopalatine arches) of the fauces may be adherent to the tonsils, and cause more or less atony of the palatal muscles. The diagnostic tube used during inflation gives the strident or rough murmur characteristic of tubal obstruction.

Complete Obstruction.—This condition may be due to any one or more of the causes given under Partial Obstruction, although it is usually due to syphilitic, tuberculous, or diphtheritic cicatricial contraction at the mouth of the tube. The symptoms are the same as in partial obstruction, excepting that tympanic inflation gives no rale or murmur through the diagnostic tube.

Undue Patency of the Eustachian Tubes.—This condition is nearly always associated with atrophic changes in the entire mucosa of the upper respiratory tract, especially of the nose, epipharynx, and oropharynx. The process may not involve the entire Eustachian tube, but may be limited to the pharyngeal orifice. Urbantschitsch reports a case of this kind in which the end of the little finger could be inserted into the orifice.

The characteristic symptoms are the inward and outward movements of the drumhead synchronous with the respiratory movements, the soft blowing murmur being heard through the diagnostic tube, even without inflation. There may be autophony or the ringing of the patient's voice in his own ears. The voices of others sometimes give rise to the same disagreeable sensation. The symptom is somewhat different from hyperesthesia acoustica, in which there is a painful distinctness of hearing; whereas in autophony the patient's own voice seems to ring or roar in his head.

Treatment of Obstruction and Undue Patency.—The treatment of partial obstruction varies with the lesion causing it. If there is catarrhal congestion of the mucous membrane at the pharyngeal orifice relief may be afforded by the judicious use of antiseptic and astringent sprays in the nose and epipharynx. If, however, the hyperemia is due to anterior nasal obstruction, this should be corrected. The removal of postnasal adenoids is indicated to relieve the epipharyngitis and the resulting tubal catarrh, as well as to overcome the mechanical obstruction they may form at the mouth of the tube.

It is difficult to overcome cicatricial contraction, especially if it is due to syphilis. If due to diphtheria and tuberculosis, electrolysis may be of value. An olive-tipped electrode with the curvature of a Eustachian catheter, should be introduced through the nose after the manner of introducing a catheter. The tip should be made to enter the Eustachian orifice, the postrhinoscopic mirror being used to make sure of its position. The shaft of the electrode should be covered with some insulating substance. The strength of current should vary from 5 to 30 ma. according to the density and resistance of the tissue. Seances should last for from five to twenty minutes. The negative pole of the battery should be connected with the Eustachian electrode, as the tissue to be reduced is dense and fibrous. If it is a simple hypertrophy, the positive pole should be used. If the lumen of the tube is constricted higher up by adhesive bands, a small, gold-tipped electrode should be introduced through the Eustachian catheter until it comes in contact with the constriction, as recommended by A. B. Duel. A current of from 5 to 25 ma. should be turned on for from five to fifteen minutes. It is claimed for electrolysis in these cases that the obstruction disappears and the hearing and tinnitus are improved. Others have found it of no practical value. The status of electrolysis at best is open to criticism. The benefits derived from it within the Eustachian tube may well be attributed to the dilatation and inflation which are incidental to the procedure. Theoretically electrolysis is an ideal treatment for fibrous constriction, while practically it has been disappointing.

The use of bougies in reducing tubal stenosis has long been recognized as of considerable value in those cases in which the stricture is not composed of connective tissue. If it is due to turgescence or simple hypertrophy, the results are often good. The bougies may be made of silkworm-gut, whalebone, or celluloid. Those made of silkworm-gut may be impregnated with astringent remedies, as silver nitrate, sulphate of zinc, etc., which often adds to the therapeutic effect. The whalebone bougie is easier to introduce on account of its polished surface. Celluloid bougies are also smooth and easy to introduce, but are more liable to break.

Suarez di Mendoza has devised a metal catheter which may be removed, leaving the bougie in the Eustachian tube. The catheter is divided longitudinally into two parts, and it can be separated and removed, leaving the bougie in position. It is then cut off even with the nose and left in position for twenty-four hours. By this method great dilatation is obtained.

Caution.—The introduction of bougies into the Eustachian tube may injure the mucosa, hence emphysema of the submucous tissue may occur if inflation is practised immediately afterward. This procedure should, therefore, not be done immediately after passing the bougie into the tube. It should rather be done when the patient returns two days later for another treatment. The introduction of bougies may be practised two or three times a week. In favorable cases the rough strident murmur heard through the diagnostic tube during inflation will have been replaced, after a few treatments, by a soft, full, blowing murmur.

In some cases great difficulty is experienced in passing the bougie beyond the pharyngeal orifice, as it bends and returns to the pharynx with a sharp tingling or smarting sensation in the lateral walls of the pharynx. The Eustachian catheter should be given a larger and sharper curve, so as to direct the tip of the bougie more in the direction of the lumen of the tube.

The bougie should be made to persistently press against the constriction until it passes it, or until the hope of doing so is abandoned. Larger bougies may be successively introduced until inflation gives a free, full, blowing murmur. After this they should be passed at longer intervals for several weeks or months.

Fig. 363

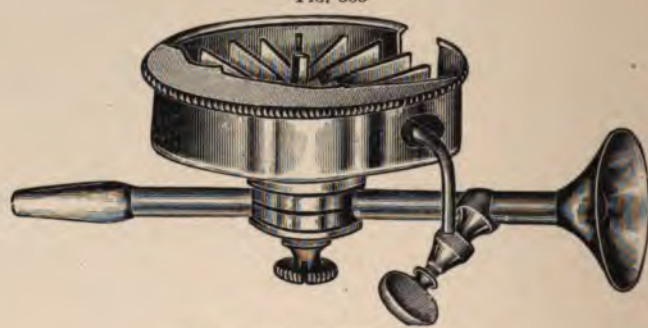

Weaver's intratympanic masseur.

Massage of the Eustachian tube may be accomplished by the Weaver masseur (Fig. 363). The masseur is attached to the catheter and the current of air from the compressed-air tank turned on, the turbine wheel interrupting the current of air. The mucous membrane lining of the tube is thus rapidly and intermittently dilated. The bloodvessels and lymphatics are unloaded, and the glandular elements are stimulated to greater activity. The tympanic cavity is also inflated and the air tension restored. In turgescence and hyperemia of the tubal membrane this mode of treatment is highly commended.

It should be said in conclusion that no one mode of treatment is applicable to all cases. Each should be carefully studied and all the facts considered before determining the line of treatment. The nasal and epipharyngeal condition, as well as the general health, should be regarded as essential factors in determining the course of treatment in each individual case.

CHAPTER XL.

THE PRINCIPLES AND METHODS OF TYMPANIC INFLATION.

THE data of an anatomical, physiological, and clinical character, upon which the principles of tympanic inflation should rest is as follows:

(*a*) The Eustachian tube extends from the lateral wall of the epipharynx to the cavity of the middle ear in an upward, outward, and backward direction. If the head is rotated to the right, and then inclined forward, the right Eustachian tube will stand perpendicular to the plane of the earth, thus favoring the drainage of the right middle ear.

(*b*) The pharyngeal orifice of the Eustachian tube is trumpet-shaped, hence when a current of air is forcibly thrown into it the contained secretions are "dished" out and carried into the epipharynx, while the residual air passes on through the tube into the middle ear.

(*c*) The walls of the Eustachian tube are covered with ciliated epithelium, the cilia creating a current toward the pharyngeal orifice. If the secretions are thick and become dried in the orifice, the sudden impact of air during inflation dislodges the mass and clears the way for the successful inflation of the middle ear.

(*d*) The walls of the tubes are approximated when in the normal state of rest, and are only opened during inflation of physiological or artificial origin.

(*e*) The drumhead, being the only yielding wall of the tympanic cavity, is pushed outward toward the external meatus during inflation.

(*f*) The handle of the malleus is carried outward also, as it is in intimate relationship with the drumhead.

(*g*) The incus and the stapes follow the outward movement of the malleus to only a limited extent, as the articulations are such as to permit the malleus to swing in this direction without marked movement of the other ossicles. The inward movement of the handle of the malleus is, however, accompanied by a corresponding, though more limited, movement of the incus and the stapes in the same direction.

It is obvious, therefore, that in adhesive processes affecting the motion of the malleus inflation exerts more or less influence in breaking them down; whereas if the adhesions affected the incus and the stapes, but slight influence is exerted.

(*h*) The mucosa of the tympanic cavity is supplied by numerous bloodvessels, capillaries, and lymph channels, which upon inflation (in catarrhal inflammation) become less engorged and return to their normal state of fulness. In other words, inflation is followed by an active hyperemia and an approach toward normal physiological

activity of the tissues composing the mucous membrane. The secretions become more normal and thinner in character. They are, therefore, more easily carried toward the Eustachian tube by the wave-like motion of the ciliated epithelium.

(*i*) The oxygen is gradually absorbed from the air within the tympanic cavity, hence after several hours rarefaction takes place, thereby again giving rise to retraction of the drumhead. This does not occur in normal conditions, as air is admitted to the middle ear during each act of deglutition and yawning.

(*j*) The palatal muscles have more or less control over the patency of the tubes, hence it is important that they be free to act to their full capacity. Repeated inflammation of the tonsils and fauces gives rise to adhesions to the pillars of the fauces (glosso-and pharyngopalatine arches) and to degenerative changes in the muscular tissue. The action of the palatal muscles is thereby interfered with and the regulation of the patency of the tubes is impaired. The ventilation of the tympanic cavity cannot be fully accomplished, hence more or less deafness and tinnitus follow.

(*k*) Passive congestion of the mucosa also results from the rarefaction of the air in the middle ear, and leads to abnormal activity of the mucous glands, as well as to a change in the character of the secretion. A true catarrhal state is thus induced. Repeated inflations, together with other appropriate treatment of the nose and throat, will, in many cases, be followed by a lessened congestion, a restoration of the glandular activity, and a return to the physiological ventilation of the tympanum.

(*l*) Thick, tenacious secretion is not easily forced from the middle ear through the Eustachian tube by inflation. The circulation and the glandular elements of the mucous membrane become impaired. Nevertheless, the thick tenacious secretion is gradually absorbed or discharged.

(*m*) The transmission of sound waves through the ossicular chain to the labyrinth is only perfectly performed when the tension existing between the drumhead, the ossicles, and the intralabyrinthine fluid is normal. If the tension is disturbed, more or less impairment in hearing results. Tympanic inflation restores the normal tension, unless adhesive bands prevent the drumhead springing into position.

(*n*) When the drumhead is perforated, the secretion flows from the middle ear into the external auditory meatus.

The foregoing data show that the objects of intratympanic inflation are as follows:

1. To restore the normal tension between the drumhead, the ossicles, and the labyrinth.
2. To restore the normal circulation in the bloodvessels and the lymph spaces.
3. To render the secretions more nearly normal.
4. To remove the morbid secretion from the Eustachian tube and the tympanic cavity.
5. To break down newly formed adhesions.

By establishing the foregoing conditions tinnitus is relieved, hearing

improved, catarrhal inflammation checked, and the suppurative processes ameliorated.

Methods of Inflation.—Valsalva's Method of Inflation.—While this method is not of such general utility as either Politzeration or catheterization, nevertheless it has a place in otological practice which is not filled by either of the other methods. Although its therapeutic effects are rather limited, it is of diagnostic value.

The method consists in compressing the air in the middle ear by a forcible expiratory effort while the mouth and the nose are closed. The method is successful in proportion to the dynamic power of the muscles of the individual and the character and degree of the obstruction in the Eustachian tube. The muscular power in children and women is less than in adult males, hence it is proportionately less successful in the former.

The *hindrances* to the successful performance of inflation are: (*a*) Thick, tenacious secretions in the mouth and the lumen of the tube, as well as in (*b*) the tympanic cavity. Plugs of tenacious mucus sometimes lodge in the tube and greatly interfere with the procedure. (*c*) When the tympanic cavity is in a state of partial vacuum from the absorption of the oxygen from the contained air, the tube is collapsed by the suction thus created. Inflation is thereby rendered difficult, greater force being required for its performance. (*d*) Fibrous adhesive bands resulting from chronic inflammation of the tubal membrane may stretch across the lumen of the tube and obstruct it. (*e*) The mucous membrane in a state of catarrhal inflammation is congested or even hypertrophied, thus interfering with tympanic inflation. (*f*) The mucous membrane of the Eustachian tube is supplied with lymphoid tissue, which under favorable conditions undergoes an hypertrophy akin to the same process in adenoids and tonsils, thereby diminishing the lumen of the tube. (*g*) Thick, tenacious secretions in the middle-ear cavity also offer resistance to tympanic inflation. (*h*) The fact that there is no exit other than the Eustachian canal for the air entering the middle ear is another factor of some importance. It does not seem to the author, however, that it plays the major role assigned to it by some authors, notably Politzer, who thinks the drumhead offers considerable resistance, whereas it is only necessary to open the Eustachian tube, when the air will rush in from the epipharynx to equalize the pressure on the two sides of the drumhead. This is the result of physical laws, and requires no force or artificial intervention other than a patent Eustachian tube. After this is accomplished the air in the middle-ear cavity may be compressed even beyond the line of equilibrium, in order to stretch or break down adhesive bands, or to expel the secretions.

The *diagnostic value* of this method is inferior to the others, inasmuch as it is less sure of being successful. Its successful performance in normal cases is attended by a soft blowing sound. Politzer ascribes the sound to the outward bulging movement of the drumhead. The author is inclined to take the view that it is due to the friction of the current of air in its passage through the collapsed Eustachian tube. If the

tube is filled with secretions, as in moist tubal catarrh, the sound is changed to a moist bubbling murmur.

The *prognostic value* of the method is considerable, in view of the fact that in those cases of catarrhal otitis media in which it can be successfully performed the prospects of cure or relief are good.

Caution.—A word of *caution* should be given in regard to the evils attending its use as a therapeutic measure. When the hearing, the tinnitus, and the "stuffed-up" feeling in the ears are relieved by this method, the patient is tempted to resort to its use so frequently and for so long a period of time that there is great danger of overstretching the membrana tympani, thereby rendering it atrophic. The author never recommends the method for therapeutic purposes, but, on the contrary, often discourages its use by those who have already adopted it.

The method, therefore, is of value chiefly as a diagnostic and prognostic procedure.

Catheterization.—This method was first brought to the attention of the Paris Academy in 1724 by a postmaster named Guyot, but its therapeutic value was not clearly stated until a century later by Saissy, in his treatise on the *Diseases of the Internal Ear*, 1819.

Fig. 364

Bulbous-tipped silver Eustachian tube.

The Binnafont or Kramer Method consists in introducing the catheter (Fig. 364) through the inferior meatus of the nose into the epipharynx, where it is turned outward and upward into the mouth of the Eustachian tube. The curved tip of the catheter should be kept on the floor of the nose at the junction of the floor and the septum. When the tip touches the posterior wall of the pharynx it should be rotated outward into Rosenmüller's fossa, then rather quickly drawn forward over the bulging posterior lip (plica salpingopharyngeus) of the Eustachian orifice into the pharyngeal mouth of the tube. The eyelet of the catheter indicates the direction of the curved tip, which, when in the mouth of the tube, is generally turned in an upward and outward direction, toward the outer canthus of the eye. In some cases, however, the tip enters the orifice when directed horizontally outward.

It may be necessary to change the angle of the curvature of the tip to suit individual cases. Saissy recommends an angle of 130 degrees, while Politzer advises 145 degrees.

The best instruments are made of pure silver, as they can be easily changed in shape and may be sterilized in boiling water. This is of no little importance when the liability to infection is taken into consideration. Before the days of sterile surgery hard-rubber catheters were largely used, and they are still recommended by some authors. Saissy,

however, nearly one hundred years ago, recommended silver, which is today preëminently the best material for the purpose.

The Lowenberg Method.—The Lowenberg method consists in turning the tip of the catheter, after it has entered the epipharynx, toward the median line, until the metal ring on the outer extremity assumes the horizontal position and then drawing it forward until it touches the posterior extremity of the septum. In making the forward movement the outer extremity should be slightly removed from the septum, so as to bring the curved tip beyond the median line, thereby making sure that it catches on the septum. The outer end of the catheter should then be moved toward the nasal septum, and held near the tip with the fingers of the left hand. It should then be rotated downward and outward more than 180 degrees, or through more than half a circle, into the pharyngeal orifice of the Eustachian tube. If there are no malformations and the velum palati is not so tense as to displace the tip backward, it will enter the orifice, where it should be held during inflation.

Fig. 365

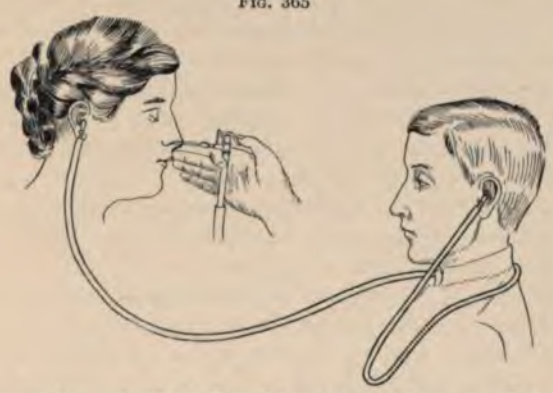

Inflation of the cavum tympani with the Eustachian catheter and compressed air. The diagnostic tube extends from the ear of the surgeon to the ear of the patient. (American method.)

The fixation of the catheter, after it has been properly introduced into the pharyngeal orifice of the Eustachian tube, is most easily accomplished by grasping the free end between the thumb and the forefinger, while the other fingers rest across the bridge of the nose.

The Auscultation or Diagnostic Tube (Fig. 365) should be used to determine whether the catheter is in place. The statements of the patient on this point are not trustworthy, as the sensation produced by inflation often gives rise to a feeling of fulness in the ears when the auscultation tube does not confirm the patient's statement. The physician should make a common practice of using the auscultation tube when inflating the ears, not alone to judge whether the procedure is successful, but to enable him to determine the condition of the Eustachian tube and the middle ear. If there is a soft blowing murmur the tube is normally open, although it may be normally inflated and the murmur not heard. This is exceptional, however, and the fact of inflation can be demonstrated

by using the manometer tightly fitted into the external auditory meatus. The U-shaped tube of the manometer should contain a few drops of colored fluid, which will be seen to rise in the outer arm of the manometric tube when inflation is accomplished. If the Eustachian tube is obstructed by catarrhal swelling or hypertrophy of the mucous membrane, the character of the sound during inflation becomes sibilant and rough. The presence of mucus in the tube is indicated by moist bubbling rales. It occasionally happens that at the beginning of inflation there are signs of obstruction, which after a few moments suddenly disappear. In these cases it is probable that a thick plug of mucus at first obstructs the tube, which soon becomes dislodged. In atrophic otitis media the Eustachian tube is correspondingly open and of a soft blowing character.

Other Methods of Catheterization.—There are several other methods of catheterizing the Eustachian tubes not commonly used, that in exceptional cases may be resorted to.

(*a*) Catheterization from the opposite nasal cavity may be done with the ordinary catheter in those cases in which there is a narrow pharyngeal vault by introducing it along the floor of the nose in the usual way until it reaches the posterior wall of the pharynx, then rotating the curved tip toward the opposite Eustachian orifice until the ring on the outer end of the catheter stands horizontally, or points toward the median line. The outer end of the catheter should now be removed from the septum, thus bringing the tip in approximation with the pharyngeal opening of the tube. Gentle pressure in a backward direction will bring it well into the opening. Inflation can now be practised in the usual manner.

This method may be used when there are obstructive lesions in the nose upon the side to be catheterized and in those cases in which there is congenital occlusion of the posterior nares on that side.

(*b*) Catheterization through the mouth may be done by using an instrument with a longer curve than is ordinarily used through the nose, the postrhinoscopic mirror aiding in placing the tip in the mouth of the tube. When there is cleavage of the palate it may be done with the ordinary catheter, as the soft palate is out of the way, thereby enabling the operator to reach the mouth of the tube with the shorter curved tip. It can also be done in many cases without the use of the postrhinoscopic mirror, as the pharyngeal openings may be seen with the unaided eye.

The Diagnostic and Therapeutic Value of Catheterization.—There are various methods of forcing air through the catheter into the middle ear, all of which are of value, the choice of method depending largely upon the mechanism afforded by the local instrument dealers rather than upon the peculiar merits of any individual method. (*a*) The Politzer bag, as shown in Fig. 366, is connected directly with the Eustachian catheter, and is, perhaps, the most familiar apparatus for this purpose, owing to the distinguished reputation of its inventor. It is admirably adapted to the use of general practitioners on account of its simplicity and the slight expense of the appliance.

(*b*) The equipment of a modern American otologist, however, usually

affords appliances which are even more convenient, and perhaps more scientific in their application in office practice than the Politzer bag. Many offices in the large cities now have compressed air piped through the building, and with a gauge the desired pressure can be established for each individual case. The shut-off should be applied to the expanded end of the catheter after it is properly adjusted, and inflation accomplished by liberating the air by means of the lever, as is done in spraying the nose or throat. The exact amount of air pressure can be accurately estimated by the pressure gauge. The author uses the regulator attached to the compressed-air tank devised by Edwin Pynchon. It is so arranged that the amount of air pressure can be quickly adjusted to the needs of the case. The author has found that a pressure of from seven to twenty-five pounds is all that is ordinarily required for the inflation of the middle ear. In some cases a pressure as low as five pounds is quite adequate for the purpose. It appears, therefore, that in offices equipped with compressed air, which is piped all over the building and can be tapped as is illuminating gas, an arrangement of this kind is admirably adapted to the purposes of the otologist, and renders the work of inflation more exact and scientific in its application.

(*c*) The nebulizing inflator is an instrument whereby inflation can be performed through the catheter in a very simple and easy manner. The tip of the nebulizer is made to fit into the expanded end of the catheter, and the medicated nebula is driven through the catheter into the middle ear. The impact of the medicated air thus released passes through the tube and the catheter to the middle ear. This appliance affords a convenient and simple means of applying medicated vapors to the middle ear.

The diagnostic tube should be used in connection with this method, and the character of the sounds transmitted through it noted for diagnostic and prognostic purposes.

(*d*) The Victor electric pneumomassage apparatus shown in Fig. 15 may also be used to inflate the middle ear through the Eustachian catheter by attaching the rubber air hose to the expanded end of the catheter and setting the pump in motion as for massage through the external meatus. The pump may be adjusted so as to produce continuous compression of the air. The pressure is discontinued by elevating the lever, which raises the contact wheel, thus instantly stopping the action of the pump. After a few moments the lever may be lowered, bringing the wheel into contact with the one attached to the revolving armature of the machine, thereby starting the air pressure again. This may be repeated as often as is necessary according to the judgment of the operator.

Politzer's Method.—In 1863, Politzer[1] introduced a method of inflating the middle-ear cavities which still proves of the greatest utility in aural practice. It is performed with a pyriform rubber bag (Fig. 366), of about ten ounces' capacity, to which is attached a nozzle suitable for

[1] Wiener med. Wochenschrift, Nr. 6.

introduction into the anterior nares. The patient is seated in front of the operator, the nozzle inserted well into one nostril, while the opposite nostril is firmly closed. The index and the middle fingers of the operator's left hand should engage the tip of the nose, while the thumb completes the closure of the nostrils. The patient is then instructed to swallow, and as the laryngeal box is observed to rise the bag is forcibly compressed with the operator's right hand. The nozzle and the operator's fingers completely close the anterior nares, while the act of swallowing brings the muscles of the soft palate and of the posterior wall of the pharynx into apposition, thus completely walling off the respiratory path in that direction. The compressed air thus confined finds the point of least resistance *via* the Eustachian tubes. The impact of air is conveyed to the middle ear and inflation accomplished. The method is simple,

Fig. 366

Politzer's bag and tips.

the instruments of simple construction and slight expense, and the procedure is easily performed. The act of swallowing, if performed more than once or twice, becomes quite difficult for the patient unless aided by the use of a sip of water.

Miot introduced a simple expedient which in some respects is more convenient than water. Sugar lozenges are kept on the treatment table, and one given to the patient before performing inflation. As the lozenge is dissolved in the mouth of the patient the act of swallowing is easily and naturally performed as often as necessary without the inconvenience attending the use of water.

The author, in using the Politzer bag, places a piece of soft-rubber tubing, one foot long, between the tip of the bag and the nozzle (Fig. 367). By this measure the liability of mechanical injury to the mucous membrane of the nose in the act of forcibly compressing of the bag is avoided.

The bag in the hand of the operator has great freedom of movement about a circle the radius of which is approximately twenty-four inches.

Auscultation during the use of the Politzer method shows two sets of sounds, one due to the entrance of air into the middle-ear cavity, the other to the escape of air in the epipharynx. The former is a soft blowing murmur when the drumhead is intact, while the latter is rough, loud, and gurgling in character. After a little experience the tympanic sounds may be readily distinguished from the rough pharyngeal noises; indeed, the latter are soon disregarded altogether. If for any reason the tympanic murmur is not heard, the use of the manometric tube should be resorted to in order to determine whether the air is forced into the middle ear.

Inspection of the drumhead during inflation may not show any appreciable movement of the same. Here, again, the manometric tube may be used to more accurately demonstrate the actual amount of inflation.

It sometimes happens that inflation cannot be performed by Politzer's method, in which event the use of the catheter is usually indicated.

Fig. 367

Politzer's bag and tube for use with a Eustachian catheter or nasal tip.

A Modified Politzer Method.—*The American Method.*—The author uses a modification of Politzer's method whereby the rubber bag is discarded and the compressed-air apparatus is substituted therefor. It is not only a more convenient, but also a more sure method of inflation. A suitable nose-piece adapted to receive the tip of the shut-off of the air tank tube, such as is used with spray bottles, comprises the outfit. Pynchon has modified Buttles' inhaler in such a way as to unscrew the acorn-shaped nose-piece at about its middle portion (Fig. 362), thus affording an easy means of introducing pieces of sponge, gauze, felt, or cotton-wool upon which volatile medicaments may be dropped and blown into the tympanic cavity. The Buttles-Pynchon inhaler is so constructed as to be used with the ordinary shut-off of a compressed-air apparatus, and for office use should take the place of the Politzer bag, as it is more convenient to use, is indestructible, and is a ready means of conveying medicated vapors to the tympanic cavity. By means of the compressed-air tank with a pressure regulator the exact amount of air pressure needed to inflate the ear may be estab-

lished for each at the time of the primary examination. This should be made a part of the record, and utilized in the future treatments. If it is found after a few treatments that inflation is accomplished with less air pressure than was at first required, a favorable prognosis may be given. This method appears to be founded upon a more accurate basis than Politzer's, in which the amount of pressure used cannot be accurately estimated or regulated. There are few offices that are not provided with a compressed-air apparatus; hence, the Politzer bag might well be superseded by a simple nose-piece and the compressed-air tank and gauge regulator in office practice. For bedside practice and for home use the Politzer bag still holds a distinct and useful place in otological practice.

External Mechanical Massage.—In the hands of the author external mechanical vibration below the angle of the inferior maxilla has proved a valuable adjunct to the inflation of the middle ear. In some cases which resisted successful inflation mechanical massage applied in this region with the vibrator was followed by successful inflation. The mechanical vibration thus imparted probably lessened the passive congestion of the mucosa of the pharynx, tonsils, and faucial pillars, and thus favorably influenced the mouth and the lumen of the Eustachian tube.

Comparative Value of the Methods.—It may be said that no one method should be used to the exclusion of all others. Each will, under certain circumstances, answer the purpose better than another. The conditions favorable to the employment of any method cannot always be foreseen, but can only be ascertained by trial. The author has often found it impossible to inflate by catheterization when he could do it readily by the Politzer method, or *vice versa*. He has also found the Politzer method inadequate in some instances in which the modification described by the author, using the compressed-air tank and a nose-piece, did the work satisfactorily.

Valsalva's method is commended on account of its simplicity and the absence of instruments of any kind in its performance. On the other hand, it is to be strongly condemned on account of the ease with which it may be abused. It is done entirely by the patient, and the relief it affords may tempt him to resort to its use much oftener than is necessary or safe. There are few cases requiring inflation oftener than once on each alternate day for a period of six weeks. With Valsalva's method the patient often inflates his ears several times daily for many weeks or months, thus producing pressure atrophy of the drumhead. When this condition arises the state of the patient's ears is worse than before treatments were given.

Catheterization is regarded by many as the most effectual method of inflation yet devised. In the author's experience, a louder tympanic murmur is heard by this than by any other method. He believes, therefore, that where it can be used without great discomfort to the patient it should be given preference. However, there are certain nasal deformities which may prevent, or at least greatly hinder, its successful use. Some other method, preferably the tank and nose-piece, should then be

used. Politzer himself claims more for his method than for any other, not excepting catheterization.

The Politzer method is extensively recommended and used on account of its simplicity and the ease with which it is practised. In those cases in which the catheter cannot be used, as in marked nasal obstruction, hypersensitiveness of the mucosa, timid patients, and children, it should be elected as preferable to catheterization.

Unless the diagnostic (auscultation) tube is used, the operator is never certain of the results obtained by any method whatsoever, the patient's statements often being untrustworthy.

The modified Politzer method, in which the compressed-air tank takes the place of the rubber bulb, is ordinarily preferable to the Politzer method, as it can be accurately regulated to suit each case, and has a wider range of atmospheric pressure. The tympanic murmur is louder and is heard much longer and more continuously on account of the constant air pressure than with the short puff obtainable with the Politzer bag. The author believes, however, that where catheterization can be done with little discomfort to the patient it should be given preference.

Recapitulation.—1. Catheterization is the most effectual method of inflation in most subjects.

2. The compressed-air tank and nose-piece are preferable if, for any reason, catheterization cannot be performed.

3. The Politzer method should be used in bedside practice and as a "home treatment," and in all other instances in which the compressed-air apparatus and nasal tip are not available.

4. Valsalva's method should only be recommended when the others are not available, and then only with strict instructions as to its possible evil results if the directions as to the frequency and period of use are strictly followed.

CHAPTER XLI.

INFLAMMATORY DISEASES OF THE TYMPANUM.

ACUTE CATARRHAL OTITIS MEDIA.

ACUTE catarrhal otitis media comprises about 13 per cent. (Hovell) of all ear diseases; it is, therefore, a very important division of otology, and should be considered in some detail, especially in view of the fact that the general practitioner is so frequently called upon to treat it.

General Etiology.—The causes of simple catarrhal otitis media are numerous, and may be considered under three different headings, namely:

1. *Exciting causes*, or pathogenic microörganisms.
2. *External influences*, or those conditions external to the body which act as predisposing causes.
3. *Internal influences*, or those conditions within the body which predispose to otitic inflammations.

1. **Exciting Causes.**—The exact relation of *microörganisms* to the inflammation of the middle ear is not yet fully determined. That they are found in healthy ears is probable, as the investigations by Zaufal have shown them to be present in the ears and epipharynx of rabbits. We know that the various infectious fevers, as scarlet fever, measles, diphtheria, etc., are often accompanied by acute catarrhal otitis media, although complications from these sources are very prone to take on the suppurative type. There is no special bacteria which causes catarrhal inflammation of the middle ear, but there is usually a combination of two or more, such as the Diplococcus pneumoniæ and the Streptococcus pyogenes. The Staphylococcus pyogenes albus and aureus, and the Bacillus pyocyaneus are next most frequently found in the middle ear. Friedlander's bacillus is less frequently found in combination with the Staphylococcus cereus albus, Bacillus pyocyaneus, and the Micrococcus tetragenus. These and other microörganisms may be present in the tympanic cavity without exciting inflammation. It is necessary that the conditions of the secretions and the tissues be favorable for their rapid propagation before they are able to excite an inflammatory process. It has been found that the invasion of a new microörganism is sufficient, under certain circumstances, to excite inflammation. After the inflammation has subsided the invasion of another type of microörganism may cause a recurrence of the inflammation. The question of microörganisms in their relation to inflammatory processes is still involved in so much speculation and doubt that it is impossible to give any definite statement as to the exact influence they have as etiological agents in

catarrhal inflammations. It seems that after the primary irritation of the tissues has subsided, the soil is prepared for other germs, so that upon their entrance there is a recrudescence of the inflammatory process.

It is well known that pathogenic microörganisms are more virulent at times than at others, hence the presence of microörganisms *per se* is not sufficient to cause acute inflammation. They must be of the proper virulency, the soil must be prepared to favor their activity, and the cellular structures must be so modified in their functional activity as to be unable to resist their influence. Even the tuberculous bacillus may be found in the secretions of the middle ear without giving rise to pathological changes.

Channels of Invasion.—Microörganisms nearly always gain access to the tympanum through the Eustachian tube. There are several other routes, however, through which they may enter it. The bloodvessels may carry them to the mucous membrane of the tympanum, where they may be thrown out with the serum and mucus, and thus give rise to inflammation. They may also gain access through the drumhead, when it is perforated, either from congenital or pathological states. In rare instances they may gain entrance from the cranial cavity through the bony walls, or through the internal auditory canal and labyrinth.

As has been stated, they most frequently gain entrance through the Eustachian tube. This may occur in spite of the fact that the tube is lined with ciliate columnar epithelium, whose ciliæ create a current toward the epipharynx. The Eustachian tube is patent as it momentarily opens to admit air into the tympanum, and the microbes may be swept inward with the current of air to the middle ear. During paroxysms of sneezing or vomiting the microbes may also be carried from the epipharynx into the tympanum. Hence there is no absolute physiological barrier offered by the ciliated epithelium of the tube to the entrance of microörganisms into the middle ear.

The microörganisms excite catarrhal inflammation which may assume the suppurative type. They may also be present without exciting any pathological reaction.

2. **External Influences.**—The external causes of otitis media cannot be considered without also taking into account the internal conditions which predispose to it. It is convenient, however, for purposes of study to consider the external causes separately, and in so doing we shall have to take into consideration the local conditions of the upper respiratory tract, as well as certain constitutional states which will be considered in detail under the second type of general causes.

Exposure to the weather is a fruitful predisposing cause of otitis media, especially when the tone of the system is not up to the normal standard. It the patient has chronic rhinitis or obstructive disease of the nasal cavities, or has adenoids and epipharyngeal inflammation, exposure to the inclemencies of the weather is especially liable to result in acute catarrhal inflammation of the middle ear. Certain other factors enter into this proposition, as clothing, climate, zone, age, sex, and the occupation of the patient.

It seems appropriate, therefore, that these etiological factors should be considered under this heading, rather than under separate paragraphs. It is evident that the effect of exposure to the weather will depend very largely upon the amount and kind of clothing worn, and the climate and latitude in which the patient lives, as well as upon his occupation. Age and sex will, also, largely determine the amount of exposure to which the individual is subjected. The character and amount of clothing worn does not *per se* determine the influence that exposure to the weather will have upon the patient, as the habits of the individual and the character of the house in which he lives modify his susceptibility to such exposure. If he lives in a house that is but partially heated, and has been accustomed to sleeping in a bed-room which was never heated, the exposure to the inclemencies of the weather will not affect him as much as it will one who lives in a well-built house which is uniformly heated.

Many of our country homes are so loosely constructed that they are well ventilated through the crevices about the windows and doors. There is not, therefore, the extreme difference between the condition indoors and outdoors as is found in the better portions of large cities.

Those living in country houses are, therefore, subjected to a more even temperature and atmosphere, within and without the house, than those who live in closely built and better heated houses. They are, therefore, not so susceptible to changes of weather, and the amount of clothing they wear, when exposed, need not differ so much in quantity and character from that worn while indoors. On the other hand, those living in the city need to give more attention to the variations of their clothing for indoor and outdoor wear.

I have known patients who were accustomed to country life, who were exposed to the inclemencies of the weather a hundred times more than they were in after years when living in the city, who were entirely free from catarrhal conditions of the nose and ears while living in the country, and who rapidly developed them after removing to the city.

The catarrhal inflammation developed, in spite of the fact that they were taking extraordinary precautions, in the way of *additional clothing*, to protect themselves while outdoors. It seems, therefore, that the habits of life which tend to lower the cellular vitality have more to do with the predisposition of the upper respiratory tract to catarrhal inflammations than the amount or character of clothing worn. Our modern dwellings, with their superb heating plants, storm windows, etc., are, perhaps, less of a boon to humanity than is generally supposed. The more primitive style of living seems to accustom the system to the variations in the temperature and hygroscopic conditions of the atmosphere. It is not reasonable, however, to expect that we will return to that mode of living. We can only say in this connection that in the construction of our houses more attention should be given to the question of ventilation. It has been said that good ventilation and cheap heating do not go hand in hand. Within certain limits this is undoubtedly true. Nevertheless, the architect can do much toward the proper ventilation of dwelling houses without materially increasing the expense of heating.

The attention of the public should be frequently called to this fact until they are educated up to the point that they will demand that this problem receive appropriate attention at the hands of the architect.

The *climate and latitude* in which one lives influence, in a marked degree, the character and amount of exposure to which one is subjected. In the temperate zone the climate is usually variable and subject to very rapid changes in temperature and hygroscopic conditions of the atmosphere, and is, therefore, one of the factors in the etiology of acute inflammations of the upper respiratory tract and middle ear. Those living in the more frigid and torrid zones are less exposed to sudden changes in the temperature and atmosphere, and are, consequently, less subject to catarrhal inflammations. Those living near large bodies of water, as the ocean, or the chain of Great Lakes between Canada and the United States, are especially affected by climatic conditions, as the atmosphere is moist and penetrating. The skin is thereby chilled and the vasomotor nervous centres are disturbed, and many of the functions of nutrition and metabolism are modified in such a way as to excite inflammatory processes in the mucous membranes, especially those of the respiratory tract.

Certain *occupations* give rise to greater exposure than others, consequently *sex*, which largely determines the nature of one's occupation, must have some influence in the etiology of this disease. A greater proportion of *males are exposed* to the inclemencies of the weather, hence catarrhal inflammation of the mucosa is more common with them than with females.

Age also determines, to some extent, the amount of exposure. Young male adults in the vigor of life, full of ambition and enterprise, more often subject themselves to the inclemencies of the weather in the pursuit of their vocations than those who are younger or older. Hence we find catarrhal inflammation of the middle ear and upper respiratory tract more common in young adulthood than at any other period of life.

A careful study of the above facts will demonstrate that *exposure to the weather* is a question of considerable complexity, as the effects of the exposure are largely determined by the mode of life, clothing, zone, age, sex, and occupation of the patient. It is not sufficient, therefore, for one to say to the patient, "You should not expose yourself to the inclemencies of the weather." All the facts pertaining to his mode of life should be taken into consideration, and advice given accordingly. It has become quite the fashion nowadays to tell patients that they should take a cold plunge bath each morning, and that they should walk at least five miles a day. This advice with certain limitations is sound, and is based upon the data given above. The attempt is made by this procedure to bring the patient for a brief time each day back to the primitive methods of living. It is well known that life in the *open air and sunshine*, and a certain amount of exposure of the body to varying degrees of heat and cold, are favorable to the well-being of the system.

More attention should be given to this subject than is now done. The *influence of sunshine* upon the cellular vitality is greater, perhaps,

than is generally appreciated. We know that many women work indoors all day, are constantly making physical exertion, and who are anemic and poorly nourished in spite of the fact that they have plenty of wholesome food. The same amount of exercise taken in the sunshine would transform them into robust, red-blooded women. It appears, therefore, that sunshine is one of the most potent therapeutic agents for the upbuilding of the system. I wish, therefore, in this connection to emphasize the importance of outdoor exercise.

3. **Internal Influences.**—The internal conditions which predispose to catarrhal inflammation of the middle ear and upper respiratory tract have a more intimate clinical relationship to acute catarrhal otitis media than the external influences. It is well established that middle-ear disease is almost invariably preceded by some form of nasal or epipharyngeal disease. Whatever causes the preëxisting infection and inflammation of the nasal mucous membrane or the mucosa of the epipharynx will also directly or indirectly lead to a similar condition within the Eustachian tube and middle ear. This is easily accounted for when we remember that the mucous membrane of the Eustachian tube and middle ear is a continuation or reflection of that lining the nose and epipharynx. It is quite similar in physiology and structure, and inflammations therefore readily extend from one part of it to another. If there is a difference in the structure of the mucous membrane, as in the mesopharynx, where the epithelium is squamous, the inflammatory process does not readily extend to the part. The mucosa of the nose, epipharynx, Eustachian tube, and middle ear are lined by columnar ciliated epithelium, hence there is no bar to the extension of the inflammatory process from one to the other.

I shall in this connection briefly refer to the diseases of the nose, epipharynx, and fauces which cause inflammatory diseases of the Eustachian tube and middle ear:

(*a*) *Nasal diseases* which cause pathological processes within the middle ear are either inflammatory or obstructive in character. The inflammatory diseases are acute rhinitis, acute fibrinous rhinitis, diphtheritic rhinitis, syphilitic rhinitis, tuberculous rhinitis and catarrhal and suppurative sinuitis. The inflammation may extend to the middle ear through the Eustachian tube by continuity of tissue, or the pathogenic bacteria may invade the ear through the Eustachian tube or through the blood and lymph channels. They also influence the inflammatory changes in the middle ear by causing the closure of the Eustachian tube, thereby interfering with the ventilation of the tympanum. The oxygen is gradually absorbed from the middle ear, thus gradually rarefying the air. The blood within the vessels of the mucosa of the middle ear rushes in to fill the partial vacuum thus created, and congestion and engorgement of the mucous membrane follow. This leads to changed nutrition of the parts and to a disturbed relationship of the cellular structures, which after a time predisposes to an inflammatory process.

Nasal obstruction is also a fruitful source of ear disease. The presence of spurs, ridges, thickening, and deflections of the septum cause

stenosis of one or both nares. As the nasal cavities are the natural channels for the inspiratory and expiratory currents of air, any interference with their patency results in physiological disturbances of a very pronounced character. When the diaphragm contracts, the thoracic cavity is enlarged and the air from without rushes in to fill it. If the nasal chambers through which the air enters the respiratory tract are obstructed, the contraction of the diaphragm acts as the valve in a syringe when it is forcibly pulled out; the air is thus rarified posterior to the point of obstruction. The partial vacum thus created induces the rush of the blood to the vessels of the mucosa. This condition after a time leads to tissue changes and predisposes to inflammatory processes. The patency of the Eustachian tubes is thereby diminished, which still further impairs the middle ear. Hence nasal obstruction is a constant menace to the middle-ear cavity.

All cases should be carefully examined for any diseased state of the nose, as the subsequent treatment of the case will depend very largely upon the successful treatment of these conditions.

Ethmoiditis and sphenoiditis are a fruitful source of middle-ear inflammation. The morbid secretions from these cells flows into the epipharynx and excites an inflammation which in time extends by continuity of tissue to the Eustachian tube and middle ear.

(*b*) *Epipharyngeal diseases predisposing* to middle-ear catarrh may be studied under two headings, namely, postnasal adenoids, or neoplasms and epipharyngitis. The presence of postnasal adenoids in the vault of the pharynx gives rise to epipharyngitis, either of the catarrhal or suppurative type. For reasons already given, this inflammatory process may give rise to middle-ear inflammation. Postnasal adenoids may be so situated as to close the mouths of the Eustachian tubes, which, as has already been explained, is a common cause of middle-ear catarrh.

(*c*) *Enlarged* or *diseased faucial tonsils* have for many years been recognized as one of the principle etiological factors in the production of middle-ear disease. This relationship is readily understood when we remember that the tonsils are situated between the anterior and posterior pillars of the fauces (glosso- and pharyngopalatine arches). The posterior pillar embraces the palatopharyngeus muscle, which has some influence in controlling the patency of the Eustachian tube. It is apparent that when the tonsils are diseased the pillars are congested or inflamed, and in time their muscular fibers undergo more or less degeneration and atrophy.

(*d*) *Tubal disease*, while intimately associated with middle-ear disease in nearly every case coming under observation, may be present without giving rise to any evidence of middle-ear complications. In other words, there is a time when the inflammation extends from the epipharynx into the Eustachian tube, and does not yet involve the middle ear. I have already referred to the fact that congestion or obstruction of the Eustachian tube is a fruitful source of inflammatory diseases in the middle ear. I need not dwell upon it at greater length in this place.

(*e*) Constitutional disorders, as anemia, scrofula, syphilitic and tuberculous affections, lower the vitality of the cellular structures, and thus predispose the middle ear to inflammatory attacks. This has already been referred to under the external causes of otitis media.

After all that has been said as to the causes of otitis media, we may go back to the primary statement that those influences external to the body which, under varying circumstances, affect the vasomotor system, and certain diseased states of the epipharynx, cause obstruction of the Eustachian tube and subsequent infection and inflammation of the middle ear.

Pathology.—The cavum tympani contains serum admixed with mucus in varying proportions. Epithelial cells are also found in the secretion. They show evidence of having undergone degenerative changes peculiar to inflammatory processes. While the secretion cannot be said to be suppurative in character, it may contain a number of pus corpuscles. The mucous membrane of the middle ear, unlike that of the nose, has very few glands; hence, the mucus is formed from the chalice or goblet cells of the mucosa. In the nose the mucous is chiefly formed by the cells lining the glands, only a few goblet cells participating in its production. There is, therefore, in the middle ear a very rapid degenerative process (mucoid degeneration) going on during the acute inflammatory process. The intercellular spaces are filled with fluid, while the bloodvessels are very much congested, thus rendering the membrane very much swollen and thickened. The surface of the mucous membrane is denuded of epithelium in patches. Hovell calls attention to the fact that leukocytes are found mingled with the secretion in the immediate region of these patches.

Pronounced destructive processes are not commonly present in this type of middle-ear disease. In rare instances, the drumhead is perforated, while there is more or less maceration of the mucous membrane lining the tympanic cavity. After a few days the morbid changes described above rapidly disappear, the mucous membrane returning to its normal condition. There seems, however, to be a peculiar susceptibility to recurrent inflammations. This may be due to the fact that microörganisms of the proper virulency gain entrance to the cavity and, finding the soil prepared by the primary inflammatory process, readily excite a recurrence of the same.

General Symptoms and Diagnosis.—1. Acute otitis media is usually due to a bacterial infection *via* the Eustachian tubes, though it occasionally enters *via* the blood current. The exudate may be simple or purulent. In simple catarrhal inflammation the drumhead rarely ruptures, no matter how intense the inflammation may be. If the exudate is purulent there is a tendency to rupture at the point of greatest bulging. Severe simple catarrhal cases begin with the same constitutional disturbances present in severe purulent cases, namely, chills, fever, vomiting, and prostration. It is often quite difficult to differentiate between acute non-suppurative and acute suppurative otitis media, until the drum membrane ruptures. Indeed, both types of inflammation are due to

infection, one undergoing resolution before suppuration, and the other passing into the suppurative stage.

Intracranial complications never occur in acute non-suppurative otitis media, and somewhat rarely in the acute suppurative variety. Such complications occur more often in the chronic type, with acute exacerbations.

The exudate has a tendency to become organized into adhesive fibrous bands, hence it is very important that their absorption should be hastened as much as possible. The air douche, by means of the Politzer bag and the catheter, should be used to clear the middle-ear cavity of the exudate, or at least to spread it over a larger surface, thereby reducing the amount of exudate at any one point. The inflations should be repeated from time to time until the ear is free from the exudate, as shown by the auscultation tube.

Infants often have acute otitis media of very short duration, probably of pneumococcal origin. Intestinal disturbances in infants are often accompanied by ear infection, and an examination of the ear should always be made. The exanthematous fevers of childhood are common causes of middle-ear infections, which in later years result in many deaths from meningitis, sinus thrombosis, brain abscess, etc. Great pains should be taken in these diseases to keep the nose and epipharynx clean during the fever. Scarlet fever and measles are especially destructive in this way. Diphtheria seldom invades the middle ear.

Acute tuberculous otitis media is seldom accompanied by pain. This is in striking contrast to other types af acute infection. If an acute tuberculous otitis media begins with pain and other symptoms peculiar to the ordinary acute suppurative otitis media, the prognosis is much more favorable than in the non-painful variety.

Acute otitis media occurring during diabetes is not of diabetic origin. The occurrence of the two diseases is accidental. The diabetic disease, however, gives rise to constitutional disturbances which favor the long continuance of the ear discharge.

Neglected cases of chronic catarrhal otitis media result in shrinking and atrophy of the mucous membrane, or adhesions may form, thus causing permanent loss of hearing. Ankylosis of the ossicles, or adhesive processes may bind the ossicles together, or to the contiguous walls of the cavum tympani.

Symptoms.—The symptoms of this disease vary according to the period of time which has elapsed since the onset. At the beginning they are much more pronounced than they are after a few days, when the more acute inflammatory process has begun to subside.

1. The onset of acute otitis media is usually signalized by a slight chill, which is quickly followed by a temperature ranging from 99° to 102°. The fever is, however, of such slight character in most cases that the attention of the patient is not usually attracted to it. The symptom which quickly develops, and which should demand the attention of the attending physician, is the *pain*, which may be characterized as a dull, boring, aching sensation, or it may assume a more acute type, and

become excruciating in its intensity. It is usually intermittent or throbbing in character, synchronous with the pulse beat at the wrist. It is due to the great swelling of the drumhead and mucous membrane of the middle ear, whereby the sensitive nerve filaments are injured by being put on the stretch with each arterial pulsation. It may also be due to the bulging of the drumhead outward into the meatus. There is a great amount of intercellular fluid thrown out at this stage of the disease, which together with the congestion of the bloodvessels renders the mucous membrane and drumhead very much thicker than normal. The contiguous parts are thereby brought into apposition.

In the first stage the *drumhead* is very red and thickened, the *handle of the malleus* being thereby hidden from view. Its surface may present the appearance of a piece of raw beefsteak, except that it is more velvety in its texture. The drumhead may or may not bulge into the external meatus. This depends upon the amount of secretion within the middle ear.

If the middle ear is filled with exudate, the drumhead is of necessity pushed outward. If, however, it is only partially filled, it may remain in its normal position or even be retracted.

Auricular tenderness is sometimes present, especially over the tragus. The mastoid process may or may not be tender upon percussion or pressure. Pressure over the mastoid antrum nearly always elicits tenderness, though it may be slight.

Bone conduction is increased on the affected side. The lower tone limit is lost, while the upper tone limit is not affected except in those cases in which the labyrinth is involved. If the disease is unilateral, the Weber experiment lateralizes to the affected side. The Rinné test is usually negative in character. By the term negative I do not mean that it shows nothing, but that bone conduction for the tuning fork over the mastoid process is longer than by air conduction when the fork is held near the external auditory meatus. If the labyrinth is involved, bone conduction is diminished, and the Weber test shows the sound lateralized to the unaffected ear, while the Rinné test gives a positive sign. Labyrinthine involvement is, however, very rarely present in simple catarrhal otitis media.

2. The second stage of this disease is characterized by the disappearance of the pain, fever, and redness of the drumhead. The entire congestive phenomena are lessened in intensity, hence the drumhead and mucous membrane are less thickened and swollen. The drumhead, instead of being beefy, or purplish red in color, is yellowish or greenish in tint. The change in color may be explained by the fact that there is less blood in the drumhead, and the pale, slightly greenish secretion in the middle ear is seen through it. The greenish, yellowish color often gives rise to the idea that there is pus in the middle ear. This error need not be made if the two conditions are carefully studied.

Another symptom of considerable significance is the presence of a *dark wavy line* (Fig. 368) extending in a nearly horizontal direction across the drumhead. This line, which is 1 to 2 cm. in thickness, is due to the

peculiar refraction of light at the junction of the viscid secretion and the air in the tympanic cavity. If it is below the umbo, it is usually concave on its upper surface; whereas if it extends above the umbo, it is usually composed of two concave surfaces. The line will be higher or lower on the face of the drumhead according to the amount of secretion in the middle ear. If the middle ear is completely filled, the line will not be visible.

The *position of the head* determines the direction of the line, as the fluid gradually seeks the level of the new position (Fig. 369). The viscid nature of the secretion and the narrowness of the tympanic cavity interferes with the rapid change in the position of the secretion. The line is not visible, as a rule, on account of the great thickness and congestion of the drumhead.

Another symptom is the presence of *oval* or *round rings* (Figs. 368 and 369), which are due to the air bubbles in the viscid mucus. They may extend above the dark line, heretofore described, or they may be within

Fig. 368

Fig. 369

Fig. 368.—Right membrana tympani showing mucus secretion and air bubbles after tympanic inflation.

Fig. 369.—Right membrana tympani with mucus secretions and air bubbles after tympanic inflation, the patient having just arisen from the prone position.

the field of the mucus itself. They may be single or multiple. After tympanic inflation the line disappears, while the entire field of the drumhead is occupied by the air bubbles. After several hours they will, in part, have disappeared, and the line will have returned.

Aural auscultation, if used during the process of tympanic inflation, shows the presence of moist rales, due to the air passing through the viscid mucus. They are very different in character from the soft blowing murmurs heard during inflation of the normal ear.

The first inflation may not be successful, as the Eustachian tube is filled with viscid mucus, hence it should be repeated several times. The diagnostic tube should always be used in performing tympanic inflation.

The membrana tympani may or may not bulge into the auditory meatus, as this depends upon the amount of secretion within the middle ear. When it bulges into the meatus it is a positive indication that paracentesis, or incision of the eardrum, should be performed. To

neglect to do this subjects the patient to unnecessary pain and to spontaneous perforation of the membrane. Spontaneous perforation should not be allowed to occur, as the perforating process is due to necrosis. Not only is irreparable damage thus done to the drumhead, but other parts are subjected to pressure and to possible ulceration and necrosis.

Incision of the membrana tympani should, therefore, be done early, to prevent great destruction of tissue and to promote the reaction of inflammation. The incision does not result in scar tissue, which usually follows spontaneous rupture of the drumhead.

It should be made at the most bulging portion, and should be crucial or V-shaped in character. Simple paracentesis, while often recommended, is not sufficient for free drainage of the tympanic cavity. The incision should be from $\frac{1}{8}$ to $\frac{3}{8}$ inch in length. The crucial or curved incision forms a slight flap which permits a larger opening for the discharge of the tympanic contents. If the incision is made straight and the drumhead is tense, the aperture for the discharge of the secretion is very small; consequently, it is recommended that it be made V- or crucial-shaped.

Bone conduction is increased and the *Weber* and *Rinné experiments* give the results described under the *onset* of the disease. These tests should be made to determine, at the earliest possible moment, whether the labyrinth is involved.

Diagnosis.—The pain and objective symptoms are sufficiently characteristic to render the diagnosis easy in most cases. Should there be any doubt, the middle ear should be inflated and observation made through the diagnostic tube, as to the character of the rales present. The appearance of the bubbles and the disappearance of the dark line will, when visible, also aid in arriving at a correct diagnosis.

Prognosis.—This is favorable or unfavorable according to the period at which treatment is instituted for the relief of the disease. If the case is seen early and appropriate remedies are used, favorable results will follow in nearly all cases. If, however, the case is allowed to run on for some time before treatment is commenced, the prognosis is not so favorable. Changes of considerable importance may have taken place, such as adhesions of the contiguous parts, and ulceration in the superficial portions of the mucous membrane.

There are certain conditions which render the prognosis less favorable, such as general constitutional diseases, as syphilis, tuberculosis, anemia, etc. It is obvious that if the diseases of the nose, epipharynx, and fauces, which predispose the patient to the primary attack, are present, there will be greater difficulty in effecting a favorable termination of the case, and when it seems to have been cured there may be sudden recurrences.

The *duration* of the acute type varies from one to six weeks, although in some cases it may be aborted in one or two days. The pain, which is one of the firsts symptoms to appear, is also one of the first to subside. The redness of the drumhead and the swelling of the mucosa next subside, after which the hearing power begins to return. Later on the tinnitus

passes away. This symptom, however, often remains for several weeks, and in those cases which merge into the chronic form it becomes a permanent symptom.

Treatment.—There are several influences to be considered in the treatment of acute catarrhal middle-ear inflammation, as we have shown in the study of the etiology that the causes are various and sometimes quite complicated. We are often called upon to relieve the patient of the pain or even of the acute inflammatory process, but we are not so frequently asked to treat the conditions which, if removed, would prevent a recurrence of the disease. This cannot be done without giving attention to the epipharyngeal and faucial conditions which exert such a great influence in its production. The treatment should, therefore, be addressed to the relief of the acute inflammatory process in the middle ear and the upper respiratory tract in general, as well as to the complete removal of the morbid conditions of the nose, epipharynx, and fauces which made the disease possible. The first duty of the attending physician is, of course, to allay the pain as quickly as possible.

So many remedies and methods of treatment have been proposed for this purpose that it is bewildering to look over the literature upon the subject. I will not, therefore, enter into any detailed description of all the methods of treatment that have been suggested, but will limit my remarks to those which have been the most successful.

General or hygienic treatment should first of all be considered, as the proper care of the patient will largely influence the progress of the disease. He should be kept in the house during the acute stage, and if fever is present he should remain in bed. The room should be well ventilated and exposed to sunshine. His food should be simple and nourishing, such as is usually given to patients in hospitals. The bowels should be kept well regulated with saline cathartics, while alcoholic beverages and tobacco should be forbidden. A light pledget of cotton should be kept in the external meatus to protect the drumhead and the middle ear from air currents.

Pain, being the most prominent subjective symptom, should receive appropriate treatment at once. It is often so excruciating that the patient is very restless. A mixture of equal parts of carbolic acid, glycerin, and the hydrochlorate of cocaine may be dropped into the external meatus, where it will, in most cases, afford relief within a few minutes. A mixture of laudanum and oil in the external meatus is not to be recommended as of very great value. If there is virtue in the mixture at all, it is due to the warmth or protection it affords to the exposed and inflamed membrane. It is usually advised that it be used after warming it in the bowl of a teaspoon.

Another remedy of value for the relief of pain as well as of the congestion is a 12 per cent. solution of carbolic acid in glycerin (Andrews). While this solution does not have as great anesthetic power as the one first recommended, it nevertheless aids materially in allaying the pain. The remedy which I have often used to allay earache is the fumes of chloroform blown into the external meatus. This may be done in various

ways, perhaps most conveniently with a pipe, in the bowl of which there is a small piece of cotton upon which a few minims of chloroform are dropped. The stem of the pipe should be placed to the meatus, while the bowl is placed to the mouth of the operator.

The fumes may thus be gently blown into the external auditory meatus and usually afford relief in a very few seconds or minutes. Leeches applied to the tragus, or posterior to the auricle, also relieve the pain and promote the reaction of inflammation.

Cold packs and compresses may be applied over the ear for the same purpose, although their effect is neither so good nor so pronounced. Hovell recommends the use of blisters or plasters over the mastoid process, though they are liable to produce ugly sores. Their value is due to the fact that they promote the reaction of inflammation. There are, however, other remedies which are more efficacious and which do no harm. The same may be said in regard to the use of warm poultices, as they macerate the parts and render them less able to resist the infection present in the middle ear. Perforations of the drumhead have undoubtedly been induced by their application. The leukodescent light from a 500 candle-power lamp exerts a favorably influence upon the inflammatory process by promoting the reaction of inflammation.

Tympanic Inflation.—During the past few years the literature has shown a bias favorable to the use of glycerin and carbolic acid for the cure of acute middle-ear inflammations. The remedy is a valuable one, but it does not meet all the indications, especially those which arise from the great tumefaction and adhesive processes. It is important, therefore, that tympanic inflation be performed at frequent intervals, in order to increase the air pressure within the middle ear, thereby separating the inflamed surfaces.

In this way the *adhesions are prevented*, or, if formed, they are broken down and a long train of symptoms and impairment of the auditory function, so often seen in the dry or adhesive types of chronic ear disease, are averted. The inflation serves a very useful purpose in freeing the tympanic cavity from secretions and in maintaining the patency of the Eustachian tubes.

If the drumhead is very red and swollen, and there is great pain, the air douche should be used with great caution, as there is danger of perforating it. Inflation should therefore be chiefly limited to the second stage of the disease, when it should be performed at frequent intervals. The patient should be provided with the Politzer air bag and instructed in its use. The frequency with which it should be used depends upon the rapidity with which the secretions are formed. In ordinary cases it should be used at intervals of one to three hours. In this way the tympanic cavity and Eustachian tubes are kept free from secretions. The hyperemia is reduced by the increased air pressure, and the adhesions between the ossicles and tympanic walls are prevented

Inflation is most effective when performed through the Eustachian catheter, but this, of course, can only be done by the attending physician. If the case requires more frequent inflation than can be conveniently

given by the physician, dependence must be placed upon the use of the Politzer air bag.

Fig. 370

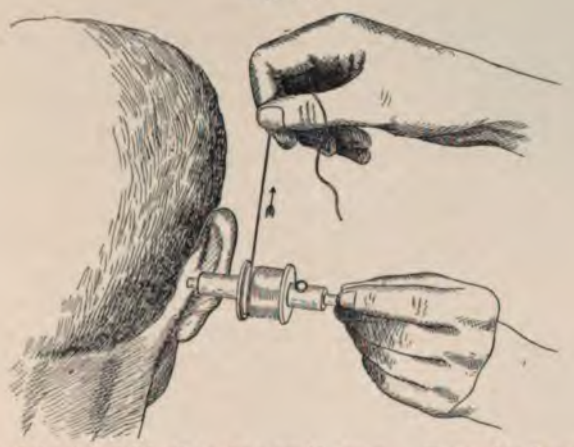

The application of the artificial leech to the mastoid process. The cord is drawn, thus rapidly rotating the circular knife applied to the skin of the mastoid process.

Leeching over the mastoid process and in front of the tragus is often attended by prompt and marked improvement. Leeches should be more frequently used than they are in acute inflammatory processes of the

Fig. 371

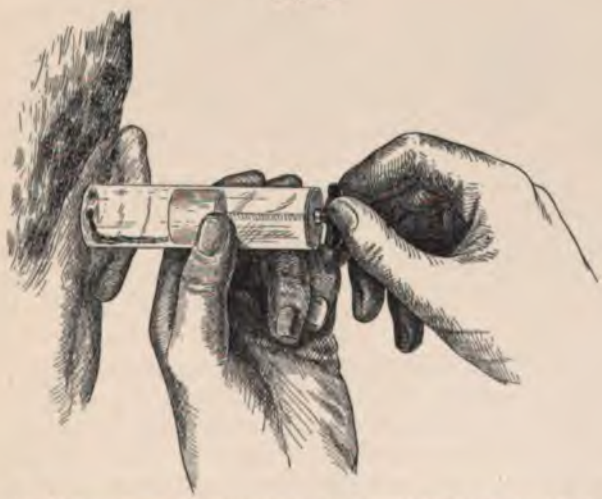

The exhaust pump withdrawing blood through the circular incision.

middle ear and mastoid process. There is no other remedial measure that acts as promptly. The artificial leech, as shown in Figs. 370 and 371, may be used instead of live leeches.

Pneumomassage is a valuable adjunct to the treatment of the later stages of acute inflammations of the middle ear. During the very acute or first stage its use is not tolerated on account of the pain and great swelling present. Later it is valuable, as it lessens the vascular and lymphatic engorgement of the tissues. It also prevents ankylosis of the ossicles. It should be applied only with such a length of piston stroke as gives rise to no pain. Should it be used in such a way as to cause pain, it may increase the inflammatory process or rupture the drumhead. The principle is the same as that relating to the use of massage in any other part of the body—namely, that it should be used with such force as not to produce contusion or injury to the tissues. The form of pneumomassage best adapted for use in these cases, at least in the secondary stage, is alternating compression and rarefaction of the air in the external meatus. With the Victor massage apparatus and the Pynchon modification of the pump (Fig. 15) any variety or character of compression and rarefaction that may be desired can be produced. It is, therefore, a good instrument for use in these cases. If such an instrument is not available, reliance should be placed upon the use of Siegle's otoscope (Fig. 372) or a simple rubber tube with a suitable meatal tip through which alternating compression and rarefaction may be produced with the mouth. Or the Delstanche masseur (Fig. 14) may be used. These instruments have the advantage of being under the perfect control of the operator, while they have the disadvantage of imposing upon him the necessity of administering the treatment from one to fifteen minutes, as the case may require. I cannot agree with some authors regarding the massage machines, which are propelled by an electric motor, as being impressive pieces of machinery, which have but little actual value as therapeutic agents. I know, from ten years of actual experience in their use, as well as in the use of the hand apparatus, that better results are obtained by the judicious use of the so-called "machines" than I have ever been able to get with the simpler devices. However, the hand instruments are especially well adapted for use in acute catarrhal cases, as pneumomassage is not usually used for so long a time at each treatment. Pneumomassage is of little value in well-advanced adhesive processes, nor is any other mode of treatment except surgical treatment in selected cases.

Fig. 372

Siegle's otoscope.

ACUTE INFLAMMATION OF THE EXTERNAL ATTIC OF THE TYMPANIC CAVITY (POLITZER).

The external attic is sometimes the seat of a circumscribed acute inflammation. The exudate is thrown out into Prussak's space (Fig. 334) and partly into the spaces formed by the folds of mucous membrane between the malleo-incudal body and the external tympanic wall.

The disease is *characterized by* slight pain and deafness, with a tumor or blister-like formation on the anterior portion of Shrapnell's membrane (membrana flaccida); or if the posterior spaces are involved, the projection forms upon the posterior portion of the flaccid membrane.

Etiology.—The exciting cause of this rather rare condition is the same as in acute otitis media, namely, the specific bacteria of exanthematous fevers, epipharyngitis, and influenza. The predisposing causes are those conditions which give rise to obstructed drainage through the Eustachian tube. Sea bathing or cold solutions in the external canal act as predisposing causes. It is probable that the infection usually reaches Prussak's space through the Eustachian tube, although it is possible for it to pass through the Rivinian foramen.

Symptoms.—In the *mild form* there is a feeling of fulness in the middle ear, slight pain, deafness, and tinnitus. The membrana flaccida is reddened and bulging, or it may be yellow at its prominent portion. The upper wall of the meatus near the drumhead is red and slightly swollen. The membrana tensa usually appears normal. The process may run its course in a few days.

In the *severe form* the reactive symptoms are more pronounced, the hearing being temporarily more disturbed, although there is usually no permanent loss of hearing. The membrana flaccida is much more bulging, often completely covering the short process and handle of the malleus. The course in the severe form is prolonged, but may finally result in complete recovery.

Treatment.—The treatment is the same as for acute otitis media and acute suppurative otitis media, except there is no need for tympanic inflation, as there is no deafness from swelling of the mucosa of the middle ear and Eustachian tube, and the tension of the membrana tensa and ossicles is not disturbed.

CHRONIC MOIST CATARRHAL OTITIS MEDIA.

This disease is characterized by intermittent or remittent deafness and *tinnitus aurium*. It may follow acute catarrhal otitis media, or it may come on without any previous history of acute disease. In some cases the deafness is progressive, while in others it extends by leaps and bounds. The patient often makes the statement that he hears very well until after exposure, after which he is much more deaf. The acuity of his hearing is usually less during the damp, cool weather of late autumn and early spring.

Etiology.—The study of the etiology, as given under Acute Catarrhal Otitis Media, in a large measure applies to this disease. Therefore a detailed statement is not given in this connection. It is sufficient to state that in most instances the chronic disease is an immediate result of the acute inflammation. This is especially true in those cases which are not treated early or in an appropriate manner. It is also especially liable to follow the acute type in those cases in which there has been previous chronic rhinitis, epipharyngitis, and obstruction of the Eustachian tubes. The obstruction of the tubes by adenoids, epipharyngeal catarrh, nasal and accessory sinus disease, etc., undoubtedly forms one of the chief factors in the production of the disease.

Attacks of one or more of the exanthematous fevers act as an exciting cause of both the acute and the chronic catarrhal inflammation. This also causes an increase of the hyperemia of the lymphoid tissue of the epipharynx and the Eustachian tubes. The patency is thereby lessened, while the presence of adenoids gives rise to a epipharyngitis, which tends to extend through the tube to the middle ear by continuity of tissue. There is a close relationship between adenoids and catarrhal processes in the middle ear, hence it is important that every case should be examined as to their presence. If present, appropriate measures should be instituted for their removal.

Enlarged or *diseased faucial tonsils* also exert a positive influence on disorders of the middle-ear cavity. The presence of foul and microbe-laden material in the crypts of the tonsils is very detrimental to the middle ear, as it gives rise to constant irritation and inflammation of the mucosa of the epipharynx and Eustachian tubes.

The *presence* of the *toxins* from the microbes is probably one reason for the irritation. All diseased conditions of the tonsils are likewise inimical to the integrity of the auditory apparatus. When the pharyngopalatine arch (posterior pillar) of the fauces is adherent to the tonsil, the palatopharyngeus muscle is subjected to irritation and inflammation; its fibers undergo degenerative changes, and its power to regulate the patency of the Eustachian tube is impaired.

Nasal diseases of an inflammatory type may extend to the epipharynx, from thence into the Eustachian tubes and the middle ears; hence, acute and chronic forms of rhinitis are active agents in the production of catarrhal otitis media.

Obstructive diseases of the nose which lead to rarefaction of the air posterior to the obstruction (during the act of inspiration) induce congestion of the nasal and epipharyngeal mucosa, and have a direct effect upon the congestion of the mucosa of the Eustachian tubes and the middle ears. This, after a time, results in retrograde changes of an inflammatory type, as chronic catarrhal otitis media. It is, therefore, apparent that nasal or epipharyngeal conditions which markedly depart from the normal may lead to catarrhal processes of the tympanic cavity.

The influences of climate, age, and sex have more or less to do with the causation of the disease. The climatic conditions found in most places in the temperate zones, and especially near great bodies of water, are

particularly aggravating to this class of cases. The disease is not one of young childhood, but appears more prominently in young or middle adult life. It is found in about equal proportions in males and females, although it is probably found more often among the males, as they are more exposed to the inclemencies of the weather.

The disease is usually bilateral, although in a few instances it is unilateral. When unilateral it is more often found in the left ear.

The use of alcohol and tobacco lowers the resistance of the mucous membrane and undoubtedly favors the production of the disease.

Symptoms.—Subjective Symptoms.—The chief subjective symptoms are deafness and tinnitus aurium. In addition to this, there is a feeling of fulness in the ears.

Giddiness is present in a certain number of cases, but is by no means a constant symptom.

Deafness.—This is the chief symptom of the disease, and is usually the one which leads the patient to seek relief. In quite a number of cases, however, the tinnitus is so much more annoying than the deafness that relief is sought on this account. The deafness may at first be so slight and so insidious in its progress that the patient is unconscious that his hearing is defective. He says his inability to understand what is said to him is explained by the slipshod way in which he is spoken to. It is not uncommon for such patients to feel offended when it is intimated that they do not hear well. They are very apt to reply that they can hear when they are spoken to in the proper manner. After a time they notice slight subjective noises, after which it is only a question of a few months until they become conscious that their hearing is defective. In some subjects, however, the progress is not so insidious as that just described. On the contrary, it may be very rapid, then after a time seemingly remain stationary for months or years. The deafness may again suddenly become worse, and so continue throughout life. The rapid progress made is not indicative of the severity of the inflammatory process, but rather points to the fact that certain vital parts have become involved, thereby limiting the sound-conducting function of the auditory apparatus. If the changes which take place in the middle ear are limited to the mucosa of the tympanic cavity, the deafness is slighter and less rapid in its progress; whereas if the ossicular chain, the round or the oval windows are involved in a marked degree, the deafness comes on suddenly and is more pronounced in character. It is important to bear this in mind, as otherwise it is not possible to understand why in one case of simple chronic catarrhal otitis media there is such slight deafness, whilst in another there is marked and sudden increase in the deafness.

Tinnitus aurium is a symptom which is almost constantly present in greater or less degree. When it is present the patients are often very much annoyed by it. Their sleep and rest at night are interfered with. They sometimes become nervous and hysterical, and if relief cannot be afforded they are apt to become morose. The noises in the ears and the head assume almost any variety of sounds or tones, ranging from simple pulsating murmurs to thundering noises, or reports like the shot of a

pistol or a cannon. In many they are of a whistling or singing character, whilst in others there is a buzzing, or dripping of water. They may be musical or simply noise. They may be mild or very intense. They may be constant, intermittent, or recurrent. It is doubtful if the noises in *simple* catarrhal otitis media ever assume the form of spoken language. Cases which seem to hear voices and to receive messages and revelations probably have a central lesion of the cortex. The brain may otherwise be practically normal, so that the psychological phenomena referred to the organ of hearing may be the only evidence that the patient has departed from the normal mental state. The case of Joan of Arc, which has excited so much historic and romantic interest, possibly belonged to this class.

In some cases the tinnitus is synchronous with the heart beat, whilst in others it is very irregular in rhythm. Various explanations have been given to account for those cases in which the noises are synchronous with the cardiac pulsations, none of which seem to explain them. The most probable explanation is that in some way or other the vibratory thrill of the arteries of the tympanum is imparted to the membrana tympani and the ossicular chain in such a way as to be transmitted to the labyrinth, from whence the sensation is conveyed through the auditory nerve to the brain centre, where it is appreciated as sound. The tinnitus may be very high or very low in pitch, and in either case it is indicative of an advanced stage of the disease. If, on the other hand, they are medium in pitch, they are indicative of a less advanced stage. The state of the general health very materially influences the degree and the character of the noises. When the patient is fatigued they are worse. If he is affected by some disease which lowers his vitality they are worse. I have seen patients who were the subjects of neurasthenia, in whom the pulsating noises were very pronounced. Some of these patients did not have ear disease, the pulsating tinnitus being only one of the symptoms peculiar to their nervous and anemic condition. In others, who were subject to catarrhal otitis media, the tinnitus was very much aggravated by the neurasthenia.

The excessive use of alcohol and tobacco increase the intensity of the noises, and may even cause pulsating tinnitus, synchronous with the cardiac pulsations, even in persons who are not subject to otitis media.

Autophony consists of a vibration and echo-like reproduction of the patient's own voice. This symptom is sometimes present in the moist, but more particularly in the dry type of catarrh. It is most commonly found in those cases in which there is an undue patency of the Eustachian tube or a stenosis of the same.

The *paracusis of Willis*, or "paracusis Willisii," is a symptom which is present in well-advanced cases. When present it is an unfavorable sign, and should lead to a very guarded prognosis. It consists of an ability to hear better in the presence of noises than in a quiet place. Thus patients will hear better in a street car or train than they do in the quiet of a country home. It is a probable indication that the mobility of the ossicles is interfered with by ankylosis or adhesive pro-

cesses, or the swelling of the mucous membrane of the tympanic walls, and that covering the ossicles may be so great as to interfere with their mobility, thus giving rise to the symptoms.

Objective Symptoms.—The *drumhead* should be examined with reference to its position, color, lustre, and reflection of light. In infants its position is normally at a very obtuse angle to the superior wall of the meatus, while in adults the obtuseness of the angle is much less pronounced. In other words, in adults the drumhead is more nearly at right angles to the axis of the external meatus than it is in very young children. In infants it is so nearly parallel with the superior wall of the meatus that it seems to be a continuation of it. As the tympanic ring develops it rapidly assumes a more erect position, until it finally has that which it maintains throughout adult life. Its position will, therefore, depend upon the age of the patient and upon the completeness with which development has taken place.

If the Eustachian tube is closed for any reason and the air is obstructed from the tympanic cavity the drumhead will be drawn inward or retracted. This gives rise to a change in the reflecting surface of the drumhead, and consequently modifies the reflection. The cone of light, which is normally present with the apex toward the lower end of the handle of the malleus while its base is directed downward and forward toward the periphery, will either diminish in size, break into one or two whitish spots, or entirely disappear. This symptom is, in most cases, indicative of retraction of the drumhead. If there are adhesions binding it to the promontory or other portions of the inner tympanic wall, the surface of the drumhead will present an uneven appearance, especially after inflation. At the points of adhesion it will appear whitish in color, whereas in the non-adherent portions there may be a slight reddish color, due to the reflection of light from the red mucous membrane of the inner tympanic wall.

The *color of the drumhead* has been variously described as of a pearl-gray, pinkish-gray, bluish-gray, or yellowish-gray membrane. Some of these observations have been made upon cadavers, in which the normal colors were not present. By the use of such lights as are now at the command of most practitioners, the healthy membrane uniformly presents a pearl-gray color, with here and there a slight admixture of orange and purple. The orange is due to the red reflex of the inner tympanic wall, though this is now regarded as a sign of spongifying.

Calcareous spots are sometimes found on the drumhead, even when there is no history of a previous suppurative process. They are undoubtedly the remnants of former inflammatory changes.

In the *normal drumhead* there is a *distinct luminous lustre* (Fig. 373), which is so modified in chronic catarrhal otitis media as to materially lessen its smoothness and brilliancy. The membrane appears whitish and velvety in texture in proportion to the amount of thickening it has undergone. The redness and the pinkish-gray color will have disappeared because the vascularity and transparency of the drumhead are diminished.

The appearance of the drumhead may be modified by the presence of *tympanic secretion*. The dark line spoken of under Symptoms of Acute Otitis Media, which marks the upper limit of the secretion, may be present in these cases. Unless the thickening of the drumhead is so pronounced as to interfere with its transparency, the bubbles of air spoken of in the same connection may also be seen. The presence of an appreciable amount of mucus in the middle ear is usually a sign of a subacute attack, but the drumhead may be so thickened that it is not easy to discern it. The opacity of the mucus increases with its viscidity, hence some estimate may be made by this observation as to the character of the secretion present. In those cases in which the drumhead is atrophied in circumscribed areas the secretion may be clearly seen at these points, while at the more opaque and thickened areas its presence cannot be detected. If there is a large quantity of mucus in the middle ear the drumhead may bulge outward in its entirety if non-adherent, or in part if there are adhesions.

Fig. 373

A normal membrana tympani of the right ear as viewed through a speculum.

Prognosis.—The curability of chronic otitis media is somewhat in proportion to its chronicity and the pathological changes in the essential structures of the tympanic cavity. If the disease is of recent occurrence and the morbid changes are slight, the prognosis is quite favorable. If the disease is of long standing and pronounced degenerative changes in the mucous membrane covering the ossicles or the membrana tympani have occurred, the prognosis as to the restoration of hearing is not good.

Treatment.—The treatment should take two general factors into account, namely, the etiology and the pathological changes present. If the chronic disease is the offspring of an acute catarrhal process, the causes of the acute disease should be determined and eradicated if possible. If the patient has been subject to either of the forms of rhinitis or sinuitis, he should be treated accordingly. Ethmoiditis and sphenoiditis are particularly responsible for otitis media. Too little attention has been given to these cavities in the treatment of ear disease. I have seen a number of cases in which the ethmoidal and sphenoidal disease was the chief cause of otitis media. Appropriate treatment, surgical or otherwise, addressed to the sinuses, speedily relieved the ear disease. The symptoms of mild chronic ethmoiditis and sphenoiditis are not so obvious as to attract the attention of the physician to them unless he has had unusual opportunities for making such observations. The patient, perhaps, only complains of a "dropping" into the throat. An examination of the epipharynx and posterior choanæ may show a mucopurulent secretion flowing over the posterior end of the middle turbinal on to the posterior wall of the epipharynx. Anterior rhinoscopy shows the

middle turbinal closely approximated to the septum. The divulsion of the middle turbinal away from the septum, or its partial or complete removal, will often exert a very favorable influence upon the course of the aural disease. In some cases it may be necessary to make a total exenteration of the ethmoidal cells and to remove the anterior wall of the sphenoidal sinus.

If the ear disease is due to tonsillar disease, the treatment should be directed to it, total ablation of the tonsil with its capsule intact being the best method of procedure.

Adenoids and inflammatory processes of the epipharyngeal mucous membrane, if present, should be treated. The presence of adenoids often perpetuates a chronic epipharyngitis, hence the removal of the adenoids exerts a favorable effect upon the epipharyngitis. As the pharyngeal inflammation extends by continuity of tissue to the Eustachian tube and middle ear, it is obvious that the removal of the adenoids or their remnants will exert a very favorable influence upon the course of the ear disease.

When the structures adjacent to the Eustachian tube have been freed from morbid processes, the ear may be treated for the removal of the local morbid lesions and to restore the mechanical equilibrium, which is so essential to normal hearing.

The tympanic cavity should be inflated for three purposes, namely: (*a*) To force the secretions from the tympanic cavity and Eustachian tube; (*b*) to restore the equilibrium of air pressure on the two surfaces of the membrana tympani; and (*c*) to improve the arterial and lymphatic circulation of the lining mucous membrane. (See Principles of Tympanic Inflation, and Methods of Tympanic Inflation.)

The air should be rarefied in the external meatus with Delstanche's rarefacteur after each inflation, as this increases the passive hyperemia of the inflamed membrane and promotes the absorption of the inflammatory exudates. It also reduces the annoying tinnitus usually present in this disease.

The mechanical removal of the secretions from the middle ear may be accomplished by paracentesis (Schwartze) or incision of the drumhead and by suction applied to the external meatus. This procedure is only indicated when the secretions are so heavy or tenacious as to resist being discharged through the Eustachian tube, or the tube is obstructed by disease. The incision should be long and curved (see Incision of the Membrana Tympani), as in acute suppurative otitis media before perforation.

Even then the secretions will not appear in the meatus for several minutes or hours, unless the middle is forcibly inflated or suction is applied to the meatus. The meatus should be lightly packed with a strip of gauze for a few hours, at the end of which time it will be saturated with the secretion. After thoroughly cleansing the meatus with a cotton-wound applicator it should be refilled with gauze. The incision usually closes in from one to three days, and should be repeated if marked bulging of the membrana tympani reappears.

When the secretions are more serous in character drainage is facili-

tated, as suggested by Politzer, by having the patient take a swallow of water in his mouth, then inclining his head well forward and somewhat toward the opposite side, thereby causing the axis of the Eustachian tube to stand perpendicular to the plane of the earth. The patient's head should be held in this position for two or three minutes, to allow the secretions in the middle ear to gravitate to the tympanic end of the Eustachian tube. At the end of this time the patient should swallow the water held in his mouth, thus opening the pharyngeal end of the tube and allowing the secretions to flow into the pharynx. As Politzer says, shortly after this procedure the membrana tympani presents a grayish color, whereas before it the membrane was yellowish in color.

The passive hyperemia of the mucous membrane of the Eustachian tube gradually subsides during the treatment by inflation, and the patency of the tube is gradually restored. The secretions also diminish in quantity and in consistency, and the tube becomes adequate to carry on its drainage and ventilating functions.

In rare instances the swelling of the tube persists, and it may become necessary to make local applications of weak zinc, silver, ammonium chloride, ol. eucalyptus, and the vapors of menthol to the tube. Generally speaking, these remedies are of slight value, a better procedure being the administration of hepatic and saline aperients. I have found mechanical vibrations behind the angle of the inferior maxilla very useful in opening the Eustachian tube when it resists the usual methods.

A. H. Buck has recommended the introduction of medicated bougies. Politzer uses a small violin string cut into suitable lengths for this purpose. They are soaked in a saturated solution of the nitrate of silver, dried, and introduced through a catheter as far as the isthmus tubæ, and left there for from three to five minutes; from three to four applications often open the tubes.

ADHESIVE PROCESSES IN THE MIDDLE EAR.

Synonyms.—Sclerosis of the middle ear; otitis media catarrhalis chronica; dry catarrh of the middle ear; otitis media catarrhalis sicca; otitis media sclerotica; proliferous inflammation of the middle ear.

Etiology.—The causes of adhesive processes in the middle ear are not fully understood. It is probable that several conditions are included under this title. Exudative catarrhs of the middle ear often seem to be attended by the formation of adhesive processes, and are often followed by their appearance. They sometimes appear without being preceded by a secretive or exudative catarrhal inflammation. The trophic centres or tracts seem to be at fault. The onset and progress of the disease are insidious and go on to pronounced deafness. The labyrinth is quite often involved, probably from the same trophic influences. The mucous membrane around the oval window is especially affected, and the cicatricial contraction of the fibrous bands often fixes the stapes firmly in the window. Atrophy, fatty and colloidal degeneration of the labyrinth often

occur simultaneously or precede the sclerotic processes in the middle ear. The adhesive processes resulting from exudative catarrh of the middle ear are not attended by such pronounced deafness, and are marked by decided symptoms even in the early stages. In the trophic or insidious form symptoms do not usually manifest themselves until the disease is well advanced.

The etiology may be summarized as follows:

(*a*) Exudative or moist catarrh of the middle ear. There is some doubt in my mind as to the causative influence of moist catarrhs, as in children in whom it most frequently occurs the adhesive processes are rarely found.

(*b*) *Trophic* disturbances affecting either the middle ear or labyrinth. It appears in some cases to affect the labyrinth first and extend to the middle ear. It is probable that both the middle ear and labyrinth are affected at the same time, although the symptoms may become manifest in one earlier than in the other. It is quite probable that hyperostosis or spongifying of the bony capsule of the labyrinth is mistakenly diagnosticated as an adhesive process.

Pathology.—The adhesive processes may be classified as either diffused or circumscribed. The diffused type usually arises from an exudative chronic catarrh; the circumscribed type from trophic disturbances.

According to Politzer, "the structural changes in the mucous membrane consist in partial or total transformation of the newformed round cells into fibrous connective tissue, interstitial hypertrophy of the mucous membrane with retrograde metamorphosis of the newformed tissue, shrinking, sclerosis, atrophy, and calcification."

In those cases in which the secretions are still abundant the mucous membrane is hyperemic, spongy, or gelatinous, and yellow or bluish red in color. The surface is uneven and ragged in appearance.

After the moist stage has subsided the membrane becomes smooth, very thick, and firmly attached.

In the diffused or *insidious type* the changes seem to proceed from the periosteum to the epithelial surface of the membrane. The favorite location for the adhesive process in these cases is about the oval window (spongifying?). The gross appearance on inspection through an opening in the drumhead shows very little evidence of the true condition. The contraction and calcification take place in the deeper portions of the mucosa and fix the foot plate of the stapes in the oval window.

In another class of cases numerous fibrous bands form in the middle ear. They may extend from the ossicles to the walls of the tympanum or from ossicle to ossicle; or they may extend from the wall to the drumhead. The ossicles are thus bound together, and the drumhead is drawn by contracting fibrous bands to the fixed walls of the middle ear. The normal tension of the ossicular chain and drumhead is thereby unbalanced, and serious interference with hearing occurs.

In *fetal life* bands or folds of mucous membrane exist in the same places often occupied by fibrous formations in the adhesive process. They are, therefore, only perversions of an earlier embryonal formation. According

to Toynbee and von Tröltsch the bands are sometimes transformed by calcareous deposits into bone-like processes.

In addition to the foregoing changes, the articulations of the ossicles may be ankylosed by fibrous formations or by the deposit of lime salts. In either event the vibratory function of the chain of ossicles is impaired.

The mucous membrane of the entire attic in rare cases undergoes calcification, and a partial or complete obliteration of the attic results.

The changes in the Eustachian tubes are largely dependent upon whether the middle-ear disease is of the diffused (moist catarrh) or of the circumscribed variety. In the diffused type the tube is similarly affected, while in the trophic type it is usually normal. The lumen is obstructed in the diffused variety, while it is unaffected in the circumscribed type.

Both ears are affected except in rare cases. This, together with the fact that it rarely occurs in children, in whom moist or exudative catarrhs are most common, rather discredits exudative catarrh as the cause. When it occurs in children it is usually easy to trace it to disturbances of nutrition, scrofula, etc.

Symptoms.—It is convenient to study the symptoms under the (*a*) drumhead, (*b*) the Eustachian tubes, and (*c*) the subjective symptoms.

(*a*) The *drumhead* is thickened, lustreless, and opaque. Areas of opacities more or less sharply defined may sometimes be seen. In some cases they are sharply defined, and appear as chalky white deposits, while in others they merge into the surrounding tissue with ill-defined borders. They are tendinous and gray in color. The spaces between the whitish deposits appear dark or bluish in color.

The *handle of the malleus* appears less distinct and wider than normal on account of the thickened condition of the drumhead. The cone of light is shortened, irregular, or entirely broken. The handle of the malleus is drawn inward and backward, and is, therefore, foreshortened.

The *adhesive bands* may be attached to the drumhead and cause circumscribed retractions. The retracted areas may also be due to atrophy or to direct adhesions of the drumhead to the inner tympanic wall. They appear as rounded or oval depressions (Fig. 374).

Schwartze called attention to a distinct reddish glimmer around the umbo as indicating a circumscribed inflammation (insidious type) around the oval window. In these cases the drumhead is usually normal, although it is occasionally opaque or atrophic. These cases are now generally recognized as hyperostosis of the bony capsule of the labyrinth.

The external meatus is usually devoid of cerumen, although it may be covered by a dense brown secretion.

(*b*) In the diffused variety the Eustachian tubes may be more or less obstructed by fibrous formations in their lumen. In the circumscribed variety they are usually normal.

(*c*) The subjective symptoms vary according to the degree of involvement of the middle ear and labyrinth. They also vary with the location and character of the lesion.

Perhaps the most common and most pronounced subjective symptom is *tinnitus*. If the disease is well advanced it is continuous, although its intensity varies with the atmospheric conditions and constitutional vigor of the patient. If tired, worried, or weakened from excessive alcoholic beverages or illness, they become more pronounced. The noises vary in character and intensity in different and in the same individual.

Disturbances of hearing may appear simultaneously with the tinnitus, although the subjective noises usually appear first. The noises increase with the deafness, although in many cases they diminish until with complete deafness there are none.

Pain is rarely present, although hyperesthesia acoustica is often a prominent symptom in the early stages of the disease. It is especially marked in the presence of shrill tones and loud speech.

More or less *giddiness* and *fulness in the head* are experienced in the cases in which there is continuous tinnitus. In some cases the Ménière group of symptoms are present, especially when there is a sudden increase in the deafness. It is probably due to a sudden deposit of an exudate in the labyrinth. The giddiness is sometimes persistent, while in others it gradually disappears without apparent damage. Aprosexia or difficulty in fixing the attention is sometimes complained of.

The *hearing is disturbed* in proportion to the interference of sound conduction to the oval window through the drumhead and ossicles and the degree of pathological changes within the labyrinth. The patient hears at greater distances at one time than at another, although the variation is not as great as is observed in ordinary catarrhal otitis media with secretion. The condition of the patient influences the hearing to a marked degree. He hears better in the morning when vigorous than he does toward evening when weary. Mastication of the food temporarily increases the deafness.

Hearing for speech may be very poor, while the finest variations in music may be distinguished, or the falling of a small instrument may be distinctly heard (Politzer).

Paracusis Willisii, or ability to hear better in a noisy place, as in a street car, than in a quiet room, is quite characteristic of this affection. It is my custom to ascertain in every case whether or not this symptom is present, as it gives a fair indication as to the prognosis of the disease. It should not be assumed, however, that the patient cannot be benefited by treatment because this symptom is present. The ordinary treatment by inflations and massage will, however, usually fail to afford relief. More radical measures, to be described, will in some instances prove effectual.

The Course of the Disease.—The course of the disease is *progressive*, although it is not steady in its advancement. It rarely progresses by gradual increase in deafness, but goes by leaps and bounds. It often remains stationary for years and then suddenly becomes worse. It is always progressive, as it is due to degenerative pathological changes in tissues, as contraction, calcification, and ossification. These conditions are slow in development, on account of the nature of the pathological

process. They progress by leaps because the changes may involve portions of the tissue but little concerned in the function of hearing, until finally it encroaches upon tissue intimately concerned in audition, and hearing suddenly becomes impaired. This does not necessarily mean that the pathological process has suddenly increased, but that it has invaded functionating tissue. The disease rarely goes on to complete deafness.

In the *insidious* or *trophic* type of the disease persistent tinnitus, often of a most aggravated character, may exist for years without deafness. The trophic intersitial changes are chiefly about the fenestra of the vestibule (oval window). Finally, the foot plate of the stapes is ankylosed, and deafness becomes a pronounced symptom. These cases are often mistaken for *nervous tinnitus* until the deafness sets in (spongifying).

Politzer says: "In the greater number of cases in which ankylosis of the stapes was observed postmortem, I found from the history of the patient that the decrease of hearing occurred after the existence of subjective noises for ten or fifteen years, and the progressive increase of deafness was very gradual. In these cases there was generally a marked negative Rinné, with sometimes lengthened and sometimes diminished duration of perception through the cranial bones; the latter, especially when the disease had existed for a long time, and in old age."

When unilateral adhesive inflammation has existed for a long time and the other ear subsequently becomes involved, the progress in this ear is quite rapid, in contradistinction to the progress in bilateral involvement.

In rare cases a change for the better takes place spontaneously. This may be permanent, or it may be followed by a sudden increase of the deafness and tinnitus.

Diagnosis.—(*a*) Thickening, contractions, and chalky deposits in the drumhead.

(*b*) The drumhead often presents a ground-glass appearance.

(*c*) Marked negative Rinné with loss of hearing for low tones shows middle-ear involvement.

(*d*) Adhesive bands may be present, and the Rinné test does not show a marked negative result. Labyrinthine involvement probably present.

(*e*) High tones are heard better than low ones. In some cases, however, there is loss of hearing for high tones, thereby indicating labyrinthine involvement.

(*f*) By the use of Siegle's otoscope (Fig. 372) the drumhead may be made to move back and forth under alternate suction and pressure. If adhesions are present, the drumhead will remain fixed at these points.

(*g*) Inflation of the middle ear will cause thin portions of the drumhead, when present, to bulge outward like bubbles. Improvement of hearing usually lasts while the bubbles remain inflated. The adherent parts remain unmoved under inflation.

(*h*) Marked movement of the handle of the malleus precludes ankylosis of the malleus and incus. Ankylosis of the incus diminishes the movement of the malleus..

Prognosis.—The prognosis will be studied under two headings, namely: (1) The more favorable signs, and (2) the unfavorable signs.

The More Favorable Signs.—(*a*) Fibrous bands following the secretive form of catarrh are more favorable than those from the insidious type which are more often associated with labyrinthine disease. (*b*) If the case has not progressed to a high degree of deafness the prognosis is more favorable. (*c*) If subjective noises have been but little manifested, the prognosis is more favorable. (*d*) Good bone conduction is also a favorable sign. (*e*) Improvement in hearing and tinnitus after inflation is a good sign.

The Unfavorable Signs.—(*a*) Early deafness. (*b*) Slight or no increase in the hearing distance after inflation of the middle ear. (*c*) Diminished bone conduction. (*d*) Advanced age. (*e*) Constitutional ailments. (*f*) Heredity.

It should be said that complete restoration of hearing is not possible in any of the cases, as the changes have been of long duration and are retrograde in character.

Treatment.—This is most conveniently divided into (*a*) non-surgical and (*b*) surgical treatment. The purpose of treatment should be threefold, namely, to improve the hearing, mitigate the tormenting subjective noises, and check the progress of the disease.

Non-surgical Treatment.—The form of treatment most in vogue among physicians in America is *inflation of the middle ear*, by either the Politzer method or through the Eustachian catheter. Politzer claims better results by his method than by the use of the catheter. This is probably due to the fact that the Eustachian tubes are usually quite patent and easily inflated by the bag. Those cases which show improvement after the use of the air bag are more favorable for treatment than those which show no improvement. The longer the improved hearing continues after each inflation the more hopeful is the prognosis. The object of middle-ear inflation is to restore the normal air pressure to the cavity of the middle ear and to stretch or break down recent adhesions. It is quite probable that but little effect of this kind is produced by this procedure, except in the early stages while the adhesive bands are slight and fragile. The chief use, therefore, of intratympanic inflation is to equalize the air pressure, and thus overcome in some measure the pressure upon the labyrinthine fluid and auditory nerve endings.

Local medical treatment has but little if any curative effect. The medicated vapors and nebulæ, so much extolled in the medical literature a few years ago, have no appreciable effect whatever, except such as may be explained by the inflation which usually accompanies their use. We may say the same in regard to many of the medicines injected through the Eustachian tubes, as their use is usually preceded by inflation.

Numerous *injections* have been recommended for adhesive processes in the middle ear, some of which seem to be followed by good results. Only those which have proved of special value will be referred to here.

The following formula has been used extensively by Politzer with favorable results:

℞—Sodii bicarb. . . . . gr. x
Glycerini . . . . . ♏ viiij
Aquæ des. . . . . q. s. ℥j—M.
Ft. sol.

Sig.—Inject 5 to 8 drops into the middle ear 2 to 3 times per week.

It acts mildly and does not cause irritation.

Pilocarpine is another popular remedy, and should be used in a 2 per cent. solution, 5 to 6 drops being injected into the middle ear. Perspiration and salivation usually occurs while the patient is still in the office, especially in those cases in which the membrane of the middle ear is still boggy and well supplied with bloodvessels. In the dry or trophic type these symptoms may not occur. It should not be used in patients with weak hearts.

Delstanche recommended that *liquid vaseline* be injected into the middle ear through a catheter. M. A. Goldstein has also reported favorable results from its use. It is claimed that it lubricates and softens the fibrous tissue, and that the force used in its introduction stretches the fibrous bands and liberates the ossicles. To me it appears that the only benefit to be derived from its use is obtained by the simultaneous inflation of the middle ear.

Caution.—Whatever method of medication is used, extreme care should be exercised lest too great an irritation be produced by the remedy. Temporary improvement only follows excessive irritation. The case then rapidly passes into a worse condition than before treatment.

Massage.—The alternate rarefaction and condensation of the air in the external acoustic (auditory) meatus moves the drum membrane back and forth. As the handle of the malleus is located between the layers of the drum membrane, it is also propelled inward and outward with the movements of the drumhead. If there are firm adhesions binding it down to the promontory, it will not perform these excursions unless there is power enough in the membrane to tear it loose. This seldom occurs, as the adhesions are strong and capable of resisting considerable force. Then, too, the drumhead is expansile, and will stretch to the point of bursting before the cicatricial adhesions are overcome. Notwithstanding, marked improvement occasionally follows the use of pneumatic massage.

Bing has recommended prolonged rarefaction of the air in the external auditory meatus by the use of an olive-tipped instrument inserted into the meatus. The tip is perforated and has a valve at its inner extremity. The air is withdrawn from the meatus through the rubber tubing, whereupon the air pressure closes the valve. In this way rarefaction can be maintained for one-half to one hour. He thinks that in some cases this is an advantage over simple alternating rarefaction and condensation of the air in the meatus.

Lucae has devised a spring probe with a cup-shaped extremity to fit over the short process of the malleus. Pressure is exerted upon the short process, and the malleus made to move. This motion is transmitted to the other ossicles, ankylosis and cicatricial adhesions being stretched or broken down. The treatments are very painful, and are,

therefore, not used to any great extent. If this difficulty could be overcome, the use of the probe would prove of great value in the treatment of these cases. I would suggest the advisability of administering nitrous oxide gas and using the probe during the brief anesthesia. There is little danger or inconvenience connected with this anesthetic, and the exigencies of the case often warrant its use. The injection of a 2 per cent. solution of cocaine into the middle ear through the catheter may also be used to mitigate the pain. I would advise the use of the probe in suitable cases at intervals of seven to ten days, inflation being practised on alternate days. If the element of pain can be eliminated, it is the remedy *par excellence* in cases in which the adhesive processes are not too far advanced. The hearing is sometimes improved to a remarkable degree, and the subjective noises correspondingly diminished. The improvement is not permanent in a majority of cases, nor is it by any other method of treatment. Inflation should also be practised.

The *length of time* during which any of the aforesaid treatments should be continued varies. It should only be continued while the hearing distance continues to increase. This usually ranges between two and six weeks. The greatest amount of improvement occurs during the first six or eight days. *To continue the treatments longer than improvement of the hearing distance increases often leads to speedy ill effects.*

As the improvement in hearing is temporary, it becomes necessary to give occasional treatments to maintain their beneficial effects. Politzer thinks his method of inflation the best adapted for the after-treatments.

Stenosis of the Eustachian tubes may be overcome by inflation if due to accumulation of mucus, or by the use of bougies if due to the formation of fibrous bands or rings within its lumen. If bougies are used, they should be introduced through the Eustachian catheter. In the adult the tube is about one and one-half inches long, and the bougie should be passed through its entire length. Bougies may be made of whalebone, catgut, or celluloid. If for any reason it is desirable to locate the stricture, an olive-tipped bougie should be used, whereas to secure its therapeutic effect it should be filiform in shape. Medicated bougies (silkworm gut) may be used and left in place for twenty or thirty minutes. A weak solution of the nitrate of silver is the astringent chiefly used for this purpose.

The introduction of the catheter should be done with extreme caution and gentleness, as force may cause it to penetrate the mucosa of the tube. This would be unfortunate, as subsequent inflation might cause emphysema of the submucous tissues. This accident occasionally happens in catheterization of the tubes through abrasions made during the manipulation of the catheter.

Internal medication is of value in those cases suffering from constitutional diseases. I have seen cases resist all treatment until iron and arsenic were administered. Others will improve in hearing when the iodide of potash or tonics are given. But even these cases do not entirely recover; they only become somewhat improved in hearing and tinnitus.

I am indebted to Dr. Geo. F. Suker for the following statement of the conditions of the ear in which thiosinamine is indicated. In 1897–98 he used it in a number of such cases, and bases his conclusions upon this experience together with the literature concerning its use in other conditions:

"The class of cases in which thiosinamine has been found of value come under the following heads:

1. "So-called cases of catarrhal deafness in which there is a diapedesis of leukocytes into the meshes of the membrana tympani which ultimately cause cicatricial-like thickening.

2. "Cases of subacute suppurative otitis media with a small perforation of the drum. The latter is thickened by infiltrations, but there is no true fibrous ankylosis of the ossicles.

3. "Cases of inflammation of the middle ear, suppurative or otherwise, leading to a fibrous ankylosis of the ossicles and with very slight structural changes of any kind in the membrana tympani.

4. "Cases of deafness, rather a loss in the acuity of hearing, due, as we have reasons to suppose, to some fibrous changes in the auditory nerve or its endings.

5. "Cases in which two or more of the above-mentioned conditions are present in the ear.

6. "Cases of suppurative otitis media with extensive loss of drum substance and the formation of fibrous bands which impede the free action of the ossicles.

7. "Cases in which there is a transudation of the lymph into the substance of the drum, which, instead of being absorbed, remains and becomes partly organized, thus causing drum thickening, and, therefore, interferes with the transmission of sound waves.

"All such cases, if the thiosinamine is persistently given in alternating periods of time, will be markedly benefited. It can be administered by the mouth or hypodermically. If by the mouth, the dose can be rapidly increased until 6 to 10 grains per day are taken. If employed hypodermically, use a 10 per cent. solution in equal parts of glycerin and water. Of this, give 12 to 18 mm. three times a week.

"Thiosinamine acts as a glandular stimulant; at first, for several hours, it causes a breaking down of the exudate. Its powers of removing or absorbing an exudate is not unlike that of potassium iodide and mercury, peptone, pepsin, sodium urate, and allied bodies.

"In employing the thiosinamine treatment, the hygienic and other needed *regime* must not be overlooked. Give it for periods of six to eight weeks and then cease for a week or ten days, after which begin again."

Whether or not larger experience will support the claims thus clearly set forth remains to be demonstrated. Enough evidence is available, however, to justify extended trials of it. Its favorable action on keloids and lupus is well known.

Rest is another therapeutic measure of special value in neurasthenic cases. I have seen cases make material improvement both in hearing

and in the severity of the subjective noises under this mode of treatment. J. A. Stucky reports good results following rest in bed, with massage of the body.

Dundas Grant recommended vibratory massage of the spinal column in these cases. He did not offer any satisfactory explanation of the therapeutic action of vibratory massage, but only reports as to its favorable action. More extended observations by Dr. Grant, the author, and others has shown the results to be slight and uncertain.

Surgical Treatment.—*Operations on the drumhead* for the relief of deafness have been done for more than a century. Himly and Astley Cooper,

Fig. 374

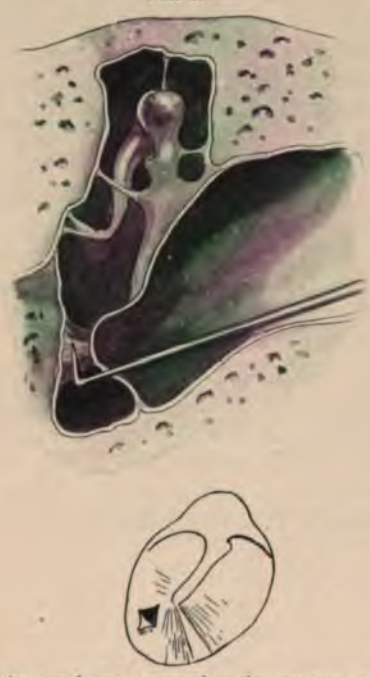

Severing an adhesion of the membrana tympani to the promontory. A small triangular flap is made in the drumhead and the right-angle knife introduced through the opening thus made and the adhesive band severed.

in 1795, removed portions of the drumhead and strongly recommended the procedure as a means of admitting sound waves to the labyrinth and of relieving the increased tension of the ossicular chain. Others soon followed in their wake, all to meet with ultimate disappointment, as the relief was only temporary. It was found impossible to keep the wound open for any length of time. Later vulcanite and metal eyelets were used with unsatisfactory results. All efforts to maintain the opening in the membrana tympani (drumhead) have failed. The difficulty has been to secure the epidermization of the edges of the wounded membrane. The author would suggest the use of the skin graft on the margin of the perforation, after the Thiersch method.

Malherbe recommends lifting the auricle forward, as in the mastoid operation and the removal of the posterior wall of the meatus external to the annulus tympanicus. He then establishes communication between the middle ear and the meatus *via* antrum and the aditus ad antrum. He maintains the opening by inserting a celluloid or gold tube through the opening in the wall of the meatus. He only recommends this procedure in cases of moderate severity.

Section of the posterior fold of the drumhead (Fig. 361) was first suggested by Politzer in 1871, who says: "It is advisable in all cases where the objective signs of an abnormal inward curvature of the membrana tympani are present, where the inferior extremity of the handle of the malleus is, therefore, abnormally inward, and the short process of the malleus and the posterior fold of the membrane extending from it project strongly toward the external meatus. If these changes are combined with a disturbance of hearing of a high degree and loud subjective noises, which cannot be materially improved by the local methods of treatment, an experimental section of the posterior fold is justifiable in such cases."

The operation is simple and consists of a section of the fold just posterior to the short process of the malleus or midway between it and the peripheral extremity of the fold. The knife should not penetrate deep enough to sever the chorda tympani nerve in its passage between the malleus and incus.

The handle of the malleus should immediately drop downward and forward as the tension is relieved. The tinnitus is usually most relieved, although in some cases there is also an improvement in hearing. The benefits last only a few weeks or months in most cases.

Adhesion of the drumhead to the promontory may be overcome by making a small triangular opening in the drumhead and introducing a right-angle knife through it. The adhesion is then severed, as shown in Fig. 374.

CHAPTER XLII.

HYPEROSTOSIS OF THE BONY CAPSULE OF THE LABYRINTH.

Synonyms.—Spongifying of the bony capsule of the labyrinth; otosclerosis; otitis media insidiosa; hyperplasia of the bony capsule of the labyrinth; capsulitis labyrinthii.

According to Henry J. Hartz, this disease is "fundamentally an hyperplasia of the bony capsule of the labyrinth; the hyperplasia is a transformation of cartilage into bone, *i. e.*, metaplasia, accompanied by the formation of an outgrowth of bone, *i. e.*, hyperostosis."

Etiology.—The dense bone of the osseous capsule of the labyrinth contains cartilaginous cells, hence it is the area of election for the transformation of the cartilage into bone. The ossicles also have cartilage cells in them, and may be the seat of this disease. The distribution of the cartilage cells is most constant in the posterior half of the margin of the oval window (fenestra of the vestibule), hence this is the most frequent site of the morbid process. They are also found in the capsule of the semicircular canals and the upper and lower walls of the cochlea. Any or all of these points may be affected and give rise to symptoms peculiar to the physiological bearings of the various structures. That is, the hyperostosis may be limited to the ossicles, the oval window, the cochlea, or to the semicircular canals, or it may involve two or more of them at once.

In addition to the predisposition of the cartilaginous area to undergo metaplastic changes, there are certain extraneous or constitutional diatheses which act as exciting causes. Syphilis, scrofula, acute rheumatism, gout, tonsillitis, inflamed processes of the ears, and exposure to the inclemencies of the weather have been ascribed as initiative influences in the disease. Personally, I do not understand how the inflammatory diseases of the tonsils, adenoids, and middle ear can have any relationship to the metaplastic changes in the capsule of the labyrinth. The etiology is still obscure.

Age exerts a positive influence upon the development of the disease. It usually begins between the eighteenth and the fortieth years of life. Heredity has been noted as a rather common factor in the etiology, many cases giving a history of other members of the family having had the disease. In a noted American literary family several members were affected by it. The majority of the cases occur in young women. Sexual intercourse and parturition aggravate the symptoms, probably on account of the increased hyperemia produced by these acts. The marriage of women affected by this disease should, therefore, be carefully considered before being consummated.

Pathology.—According to Denker, the osseous changes may be divided into two stages, the first of which consists in an active proliferation of all the cellular elements within the bone. New vascular and cellular tissue is formed in the narrow spaces and in the Haversian canals. Among the newformed bone cells may be found giant cells, under the influence of which the basement of the bone substance is principally absorbed. Hollow spaces are formed, and areas of erosion gradually undermine the originally compact bone, which becomes traversed by irregular and abnormal channels. With the absorptive process there is the formation and apposition of new bone, which is unlike the original, it being more voluminous and porous. The second stage is ushered in when the progressive changes cease and when the new bone assumes a lamellar structure. Then the abnormally large and thick bone corpuscles are found concentrically arranged, and the nucleus of these later undergoes atrophy. The vascular system is likewise gradually altered by the formation of connective tissue, in which at times may be found fat cells. The Haversian canals and spaces have been changed in structure by this resorptive and appositional process, and all the cartilaginous elements have been metamorphosed into osseous tissue, as it cannot be found in the new-growth. Thus the process constitutes not only an hyperplasia and hyperostosis, but also a metaplasia.

The new structure differs from the normal by its affinity and greater absorptive power for carmine stains, which fact is utilized in the differential diagnosis. The microscopic evidence of this new formation are the osteophytes, situated usually near the stapes articulation. Frequently the stapes is partially absorbed by penetrating bloodvessels and replaced by osseous formations. Sometimes a dislocation of the stapes is produced by an encroachment of the osteophytes. The functions of the oval and round windows may also be seriously interfered with by the hyperostosis producing partial or complete occlusion. When the process invades the base of the cochlea, the patency of the Eustachian tube is threatened. Its lumen is narrowed by thickening of the periosteum, as has been demonstrated by the microscope. Owing to the great vascularity attending it, especially the first stage of the process, it is probable that the distressing tinnitus of progressive deafness may have its origin in the increased capillary circulation.

The structural alteration consequent upon an invasion of this bone formation into the cochlea and the semicircular canals may cause a change in the pressure and the density of the labyrinthine fluid. The mechanical and physical qualities of the endolymph and perilymph may be so altered as to interfere with the nutrition of the parts and induce disease. The detonating sounds heard by some patients and the symptom complex of Ménierè may be ascribed to a perforation of the septum dividing the endolymph and perilymph systems.

While the histological alterations were found to be identical by different authorities, yet their designation of the bone hyperplasia differs and new synonymous terms are consequently introduced. Politzer defines it as capsulitis labyrinthii or otosclerosis. Siebenmann, noting

the resemblance to sponge because of the rarefied spaces and porous structures, designated the new formation as spongification. Katz compares the process to Volkmann's osteitis vascularis chronica. From personal observations of different specimens the osseous change appears to be identical with the rarefying osteitis of our text-books.

Symptoms and Diagnosis.—The symptoms, while more or less constant, vary with the anatomical structures involved. If only the ossicles are affected, the ankylosis of the stapes may be partial or complete; if the posterior bony margin of the oval window is the seat of the changes, the ankylosis may be complete and the stirrup pulled posteriorly by the stapedius muscle; if the cochlea is involved, the signs of nervous deafness are present, *i. e.*, diminished bone conduction and the loss of hearing for the upper tone limit; if the process is in the semicircular canals, giddiness and nausea may be present. In mixed cases there may be a combination of these symptoms.

In the cases as commonly recognized in practice the disease is characterized by the signs of middle-ear disease without the objective appearances of it. That is, there is (*a*) loss of the lower tone limit, (*b*) a negative Rinné, and (*c*) an increased duration of hearing by bone conduction, the findings in middle-ear disease. Upon inspection of the membrana tympani its appearance is normal, or is so slightly changed that it cannot account for the marked degree of deafness present.

When the hyperostosis is located exclusively in the ossicles, the ankylosis may be partial or complete, and the symptoms are those of ordinary middle-ear disease, except the membrana tympani is normal in appearance and the Eustachian tubes are open.

When the hyperostosis is limited to the cochlea, the usual signs of nervous deafness, loss of hearing for the upper tone limit, positive Rinné, and shortened and diminished bone conduction are present.

When both the oval window and the cochlea are involved, it is practically impossible to make a diagnosis. This is also true when the oval window is affected by hyperostosis (spongification) and the middle ear is simultaneously diseased. Tinnitus is present in nearly all cases, and is sometimes very pronounced.

Summary of Symptoms.—As the spongifying or hyperostosis affects various parts of the ear structures, the symptoms vary accordingly.

The following classification includes the chief clinical characteristics of each subdivision:

Hyperostosis about the Oval Window (Fenestra of Vestibule).—1. Loss of hearing for one-half to one and a half octaves of the lower tone limit in one or both ears.

2. Negative Rinné in varying degree.

3. Prolongation of hearing by bone conduction for fork A of the Edlemann-Bezold set of forks.

4. Hyperemia appearing as a yellowish-red glow of the promontory, showing through an otherwise normal appearing membrana tympani. The handle of the malleus may be foreshortened, but is not rotated.

5. Patency of the Eustachian tubes.

Hyperostosis of the Stapes.—The same as the preceding except in a less degree.

Hyperostosis of the Cochlea.—1. Loss of hearing for the upper tone limit, and slightly for the lower tone limit.

2. Positive Rinné.

3. Shortened duration of hearing by bone conduction for fork A.

4. Hyperemia of promontory showing through an otherwise normal membrana tympani.

5. Patency of Eustachian tubes.

Hyperostosis of the Semicircular Canals.—1. Giddiness or dizziness at times.

2. Nausea may or may not be present.

3. Perhaps slight deafness.

4. Membrana tympani and Eustachian tubes normal.

Hyperostosis around Oval Window Combined with Catarrhal Otitis Media or Other Middle-ear Disease.—1. Loss of hearing for one-half to two octaves of the lower tone limit.

2. Negative Rinné in varying degree.

3. Prolonged hearing by bone conduction for fork A.

4. Retraction of the membrana tympani.

5. Foreshortening and rotation of the malleus.

6. Eustachian tube obstructed.

A positive diagnosis of spongifying in a case with the above symptom complex is impossible.

Prognosis.—The cure of the disease appears to be impossible. In a few cases slight or temporary improvement follows treatment. In the early stage of the disease certain medicinal, mechanical, and surgical procedures afford relief. In the later stages all remedial measures fail.

Treatment.—Medicinal.—Small doses of phosphorus, gr. $\frac{1}{200}$, three times daily, for six months of the year, has given the best results. It acts best in the early stages during the active proliferation of the cellular elements within the bone, when new vascular tissue is being formed in the narrow spaces and Haversian canals, and absorptive processes and apposition of new bone is in progress.

Thyroid extract has likewise occasionally given good results under the same conditions.

Iodine, in the form of the iodide of potash, and mercury have been given by Politzer with good results when the diagnosis was made early on account of other members of the family having had the disease. That is, the appearance of the disease was carefully watched for, because its coming was expected on account of the hereditary influence known to be present. When a father or mother is known to have the disease, they should be warned that their children are liable to the same trouble, and that they should be periodically examined after puberty for its earliest expression. In this way there is some hope of modifying its progress by the administration of phosphorus, iodide of potash, or thyroid extract, and by the correction of inflammatory disease of the tonsils and adenoids, and of rheumatic, gouty, and scrofulous diseases.

Thyroidectin in five-grain capsules may be given three times a day. Depletion of the vessels of the head may be produced by the administration of cathartics and by hot foot and sitz baths.

An early diagnosis is positively necessary, and heredity should give warning of the impending disorder.

Mechanical.—Pneumomassage with the Delstanche rarefacteur (Fig. 14) may be used to mobilize the ossicles when they are not excessively ankylosed (Hartz).

Clarence Blake has called attention to the fact that in practising pneumomassage gentleness should be observed in its application, as, otherwise, the whole ossicular chain may be dislocated and irreparable damage done. He also calls attention to the fact that the posterior segment of the membrana tympani may become relaxed by excessive massage. Indeed, great damage may be done by any treatment addressed to the Eustachian tubes and middle ear. Aurophones are also damaging to this disease. The massage should therefore be gently administered, preferably with a hand pump, for one to two minutes, two or three times a week, for two months. After a rest of two months the massage may be tried again. Further massage may be given at the discretion of the aurist. As soon as the nature of the disease is known the patient should be advised to begin a systematic course in lip-reading.

Surgical.—Stapedectomy has been tried with almost universal failure. Jack has performed the operation a number of times with but one or two permanent improvements. In some cases stapedectomy is followed by the formation of scar tissue over the oval window, thus rendering the hearing worse than before the operation.

CHAPTER XLIII.

ACUTE AND CHRONIC SUPPURATIVE OTITIS MEDIA. CHOLESTEATOMA.

ACUTE SUPPURATIVE OTITIS MEDIA.

THIS type of inflammation of the middle ear is characterized by marked hyperemia of the mucous membrane of the middle ear, including the inner wall of the drumhead. This may be followed by pain and perforation of the drumhead, through which the pus discharges into the external auditory meatus.

Etiology.—The exciting cause of this disease is the presence of pathogenic microörganisms in the middle ear, as already described under Acute Catarrhal Otitis Media; indeed, the catarrhal inflammation often assumes the suppurative type after a few days. In many cases the inflammation remains catarrhal in type until the drumhead is perforated, the microörganisms thus receiving the required environment to promote their rapid propagation, though spontaneous rupture sometimes promotes a rapid reparative process, due to good drainage and the increased reactions of inflammation. (See Chapter VI.) The perforation may occur either spontaneously or by surgical intervention. Incision of the membrana tympani is not contraindicated, as, if it is done under aseptic conditions, the danger of increased infection is reduced to the minimum; indeed, the reactions of inflammation are promoted, and the infection is thus overcome instead of being increased. Some cases are undoubtedly suppurative in type from the beginning, the inflammation, temperature, and pain being more pronounced than in the simple catarrhal inflammation.

Arthur B. Duel arrives at the following conclusions in reference to the relation of the infectious fevers to acute suppurative otitis media, his conclusions being based upon a study of 6000 cases of scarlet fever, measles, and diphtheria in the Willard Parker Hospital:

Acute purulent otitis developed in about 20 per cent. of the scarlet fever cases, in about 10 per cent. of the diphtheria cases, and in about 5 per cent. of the cases of measles. There were 26 mastoid cases, 2 in measles, 2 in scarlet fever, and about 20 in combined scarlet fever and diphtheria. Two were complicated with thrombosis of the lateral sinus.

Time of appearance: In scarlet fever the ear complications occurred the second or third week; in diphtheria, during the acute symptoms; in measles, during the acute stage, fever still being present.

In scarlet fever there was usually much greater destruction of tissue

than in diphtheria or measles. A combination of two or more of the infectious diseases increased the danger, nearly one-half of such cases developing acute suppurative otitis media, and mastoiditis was a frequent sequela.

The Rivinian segment as an etiological factor: In children under five years of age Duel found postauricular swelling present most constantly, which, he thinks, was due to the escape of pus through the unclosed Rivinian segment. Between the ages of five and ten the postauricular swelling was due to perforation of the thin mastoid cortex. In older children mastoid swelling was rare, except in those cases in which the external meatus was greatly inflamed. In all cases there was sagging of the postsuperior wall of the meatus near the drumhead.

The *predisposing causes* are colds, exposure, chronic rhinitis, chronic and acute epipharyngitis, adenoids, enlarged or inflamed tonsils, syphilis, tuberculosis, and other constitutional diseases. The acute exanthematous fevers, as scarlet fever, measles, diphtheria, whooping-cough, and influenza, are also responsible for many cases. The use of the nasal douche sometimes causes the disease. I formerly used the nasal douche quite frequently in my office practice, but abandoned it after seeing two or three cases of acute suppurative inflammation resulting directly from it. Cold injections into the meatus, bathing, diving, and snuffing cold fluids into the nose also act as predisposing causes.

Age has a direct influence, a large majority of the cases being in children. The damp, unsettled weather of the autumn and spring also favors its occurrence.

Those cases occurring independently of any other disease are usually unilateral, while those occurring in connection with scarlet fever, diphtheria, measles, epipharyngitis, and adenoids are usually bilateral.

Finally, it may be stated that all conditions which lower the resistance of the tissues of the middle ear predispose to infectious inflammation. The exciting causes are the pathogenic microörganisms. The various constitutional diseases and the local diseases of the fauces, nose, and epipharynx produce lowered cell resistance, and predispose to the infection.

The *indications*, in view of the foregoing facts, are to remove the predisposing causes and increase the reaction of inflammation, in order to increase the resistance of the tissues and to destroy the bacteria and their toxins. (See Inflammation, and the Methods of Promoting the Reaction of Inflammation, Chapter VI and VII.)

Symptoms.—The symptoms may be grouped under pain, temperature, the appearance of the membrana tympani, the character of the secretions, the subjective noises, and the disturbances of hearing.

Pain.—The pain is sometimes preceded by a feeling of heaviness in the ear, or by a severe headache. The pain may be piercing, tearing, boring, or throbbing in character, and is more severe in children than in adults. It is continuous, but it becomes less severe toward morning, when the patient falls into a sound sleep. Photophobia, edema of the eyelids, and conjunctivitis occasionally complicate severe inflammations

prior to the time of perforation of the drumhead. Facial paralysis and trigeminal neuralgia occasionally complicate the disease.

Temperature.—The temperature at the onset is elevated from 1° to 3°, and is sometimes preceded by a slight chill, or creepy sensations, and, occasionally, in very young children, by convulsions. After the suppurative process is well established, and drainage is taking place through the perforation in the drumhead, the temperature subsides to about 1° above normal.

The Membrana Tympani.—In the early stages the membrana tympani presents the appearances found in acute catarrhal otitis media. It is scarlet red, ecchymotic, swollen, and more or less bulging. The handle of the malleus is obscured by the swollen drumhead. In the postsuperior quadrant of the membrana tympani a blister is sometimes present, giving a pearly lustre to this area. If the case is seen quite early, the round spots due to the bubbles of air in the viscid mucus may be seen through the still transparent drumhead. In the influenzal cases a hemorrhagic bleb often completely covers the drumhead. After a day or two the posterior half of the drumhead becomes covered by dead, cracked epithelium, beneath which there is a serous infiltration. Politzer was the first to show that the light reflexes on the bulging portions of the posterior segment of the drumhead sometimes pulsate. The yellow purulent secretion behind the membrana tympani does not show as often as one might expect, on account of the swollen and reddened condition of the membrane. Occasionally, however, a greenish-yellow bulging spot may be seen, and when it appears, perforation is imminent.

In diabetic patients, and occasionally in others, small interlamellar abscesses form in the posterior segment of the membrana tympani, or near the umbo. They are of the size of a millet-seed, and rupture early in the course of the disease.

The External Auditory Meatus.—The osseous portion of the meatus is almost always hyperemic, and is sometimes infiltrated, and more or less covered with blisters. The cartilaginous portion of the meatus is injected and painful in severe inflammations, the infection taking place through the numerous anastomoses of the capillary bloodvessels between the mucous membrane of the tympanic cavity and the skin of the meatus. The swelling and redness, or the so-called "sagging" of the postsuperior portion of the osseous meatus, near the membrana tympani (Fig. 375), occurs in those cases in which there is a marked suppurative process in the Kirschner mastoid cells. When it occurs it is usually a positive indication for the mastoid operation.

Perforation.—Perforation takes place at the seat of one of the interlamellar abscesses, or at the most bulging portion of the drumhead, generally in the anterior half, although it may occur in the posterior segment. The size and shape of the perforation varies, usually being an ill-defined area with triangular edges, while in others it appears as a small dark round spot, with a pulsating drop of mucus covering it. In still other cases the opening cannot be located. Inflation sometimes enables the observer to distinguish its edges. The same is true when

the air is rarefied in the external canal with Siegle's otoscope (Fig. 369). The perforation is usually single, although in tuberculous patients it is multiple and near the margin of the drumhead (Fig. 377). In influenzal otitis the perforation often occurs on the apex of a nipple-shaped elevation. A nipple-shaped perforation is, therefore, significant of serious mastoid disease. Even under favorable conditions, the nipple-shaped perforation persists for quite a time. In those cases occurring independent of one of the infectious diseases the perforation rarely exceeds the size of a millet-seed, whereas in cases secondary to the infectious fevers the perforation may be so large as to destroy the entire membrana tympani. The membrana flaccida (Shrapnell's membrane) is rarely perforated in acute suppurative otitis media.

Secretions.—The secretions may be serous, seromucous, serosanguineous, seropurulent, mucopurulent, or mucohemorrhagic. If it is purulent, it often runs a more favorable course than the mucopurulent type. The quantity of pus, serum, and mucus varies greatly at different times, and one form of secretion may alternate with another. In nephritic, cachectic, leukemic, hemophiliac, and traumatic cases the hemorrhagic secretion is usually present.

Fig. 375

Bulging or sagging of the posterior superior wall of the meatus; an imperative indication for the mastoid operation.

Subjective Noises. — Pulsating noises sometimes occur in acute suppurative otitis media, although they are not always present. They are due to the increased pressure within the cavum tympani from the hyperemia and excess of secretion. The labyrinth is also hyperemic and somewhat infiltrated, the noises being thereby augmented. Autophony is sometimes present.

The Hearing.—The hearing is impaired somewhat in proportion to the amount of congestion and secretion present. As the disease progresses, and the membrane becomes more congested, and the cavity filled with the secretion, the deafness, which at first was slight, becomes quite pronounced. In scarlatinal and diphtheritic infections involving the labyrinth the deafness may be profound and hearing for high tones lost.

Hearing by bone conduction for the watch, tuning-fork, and acoumeter remains intact, except in those cases wherein the labyrinth is involved. In the Weber test the sound is lateralized to the diseased ear, except in the aforesaid labyrinth cases, in which it is lateralized to the sound ear.

Course.—Taking the perforation of the drumhead as one of the early milestones in the progress of the disease, we may subdivide it into three classes, namely: (*a*) Those cases running a very rapid and destructive course, wherein the drumhead is perforated within the first

one or two days; (*b*) those cases wherein perforation occurs on the third or fourth day (primary suppurative otitis media); (*c*) and the more chronic type, in which perforation occurs within the second or third week of the disease.

Perforation usually ameliorates the symptoms, especially the pain due to pressure. Improvement does not always follow, however, as the mastoid antrum and cells may also contain pent-up secretions, and thus give rise to the pain, in spite of the lowered tension within the tympanic cavity. The fever, headache, and subjective noises are also abated when perforation and drainage into the meatus take place.

After a variable time the discharge ceases and the perforation closes. In the cases occurring independently of the infectious fevers, the perforation often closes in from one to three weeks, or it may not close in as many months. In those cases due to the infectious fevers and to influenza (nipple-shaped perforation), the perforation only closes after a protracted period.

I have seen a fatal type of mastoiditis develop seven years after an attack of mild scarlet fever. In one case, seven years after the scarlatinal infection, cavernous sinus thrombosis complicating mastoiditis, occurred, and was speedily followed by death. In another case, one year after a very mild attack of measles, suppurative labyrinthitis developed very suddenly, deafness being almost complete. Pachymeningitis, followed by death four days later, terminated the case. I am skeptical in reference to the safety of those patients whose ears become infected during the course of the exanthematous fevers. A latent or concealed inflammation so often persists, and after a lapse of a few years becomes active and destructive to a marked degree. I therefore emphasize the wisdom of giving a guarded prognosis in otitis media secondary to the eruptive feyers. In the primary type the prognosis in this respect is much more favorable.

I recognize another type of otitis as having dangerous tendencies, namely, those cases running an irregular or intermittent course. The discharge ceases, and then, after a variable interval, reappears. Pain also occurs at irregular intervals. In other words, the acute type becomes chronic and somewhat latent in character. Necrosis of the bony tissue takes place, and mastoiditis, complicated with sinus thrombosis, brain abscess, or meningitis, occurs.

Terminations and Sequelæ.—This phase of the subject is of great importance, on account of the apparent harmlessness of the disease in many cases, whereas it is in reality a most grave and destructive one. It is not so much the disease that is to be feared as the sequelæ. The terminations and sequelæ should engage the thoughtful consideration of the attending physician quite as much as the primary otitis. For convenience of discussion, Politzer's classification of the terminations will be followed:

(*a*) **Cure.**—That many cases terminate in a positive cure, no vestige of the disease remaining, cannot be questioned. That many are pronounced "cured" when in reality a serious sequela is left as a heritage.

is also unquestioned. A careful analysis of the case, its etiology, course, etc., should be considered in arriving at a correct conclusion as to whether or not it is "cured." What, then, are the points that should be considered in arriving at a conclusion as to whether the case is "cured"? In the first place, if the case is primary, or independent of a preceding infectious fever, and has run a mild and rapid course, and if there are no demonstrable ear lesions, it is safe to pronounce the case probably cured. Such an opinion should, however, be based upon accurate and intelligent observations. I have seen many cases pronounced cured in which subsequent results demonstrated the opinion to have been erroneous.

(*b*) **Catarrhal.**—A catarrhal termination is not attended by immediate serious consequences, but it may in time produce pronounced impairment of hearing. The perforation may be completely closed by cicatricial tissue and a seromucous secretion, with slowly increasing deafness and tinnitus as the chief symptoms.

(*c*) **Adhesive Processes.**—This form of termination is not rare, but, on the contrary, is comparatively common. The thick mucoid secretion or exudate becomes organized, the adhesive bands binding the ossicles to each other or to the walls of the tympanic cavity. The drumhead may also be involved by adhesions to the inner tympanic wall, drawing in ridges and folds toward the wall from which the adhesive bands spring. The deafness and tinnitus are usually progressive, although they may increase by bounds. In the earlier stages, bone conduction is increased. Rinné (see Functional Tests of Hearing) being negative, while in the more advanced stages Rinné is positive. The positive Rinné in the later stage is accounted for by the extension of the sclerotic process to the labyrinth.

(*d*) **Permanent Deafness.**—Permanent deafness is usually a result of the secondary infection from scarlet fever, measles, diphtheria, etc., the membrana tympani and ossicles being partially or entirely destroyed. I have seen cases in which the drumhead and ossicles were entirely destroyed, the inner wall (promontory) of the tympanic cavity being plainly visible, in which the hearing was remarkably acute. The chief loss of function seemed to be an inability to locate the direction of sound or speech. After once grasping the fact that they were being addressed, these cases seemingly hear with almost normal acuteness. Another cause of permanent, and often very pronounced, deafness is the panotitis of Politzer, wherein the whole auditory apparatus is involved in the infective process. In these cases there is caries of the bone separating the tympanic cavity from the labyrinth (promontory), or there is a perforation of the windows leading to the labyrinth. This condition is usually secondary to the infectious fevers.

(*e*) **Mastoiditis.**—While mastoiditis nearly always complicates middle-ear infection, it is not always severe enough to cause serious symptoms. In some cases, however, notably those due to the infectious fevers, influenza, and typhoid fever, the mastoid involvement often becomes the chief problem in the management of the case. In mastoiditis having its origin in influenza the abscess is usually circumscribed, and is

located in the mastoid process, the tympanic cavity containing no pus. In children the mastoid process is often perforated through the external plate, thus giving rise to a subperiosteal abscess.

(*f*) **Loss of Mucous Membrane, Ossicles, and Infection of the Labyrinth.**—Labyrinthitis, while similar in some respects to the condition described under (*d*) Permanent Deafness, is different in regard to the virulency of the infection. It is found following mild infectious fevers, typhoid fever, and tuberculosis. The tympanic cavity is denuded of mucous membrane, and the ossicles are necrosed. A probe introduced into the cavity through the external meatus shows bare, comparatively smooth bony walls. The labyrinth may be exposed by necrosis of the promontory or inner wall of the middle ear. The hearing in these cases may not be as profoundly affected as in (*d*), though when the labyrinth is involved the deafness is usually profound.

(*g*) **Chronic Suppuration.**—This sequela is not so much to be dreaded as the more latent form, in which there seems to be a cure, when necrosis is probably steadily progressing. In the open frank chronic suppuration the physician and patient are not so readily deceived, but recognize the possible danger still attending the further progress of the disease.

(*h*) **Death.**—A fatal issue may result early in the disease from meningitis, sinus thrombosis, septicemia, or brain abscess. The infection may reach the meninges through the labyrinth, the tegmen antri or tympani, or through one of the open sutures of the temporal bone in infants and children.

Diagnosis.—The diagnosis of acute suppurative otitis media is neither easy nor simple. The difference between it and acute catarrhal otitis media is often so slight in the early stage of the suppurative type that only a careful and intelligent examination will enable the surgeon to make a correct diagnosis.

(*a*) **Pain.**—In suppurative otitis media the pain previous to perforation is very intense and boring in character, especially in children, whereas in adults it is not so severe.

(*b*) **Temperature.**—The temperature ranges from 1° to 3°, or even more, above normal in children. It does not run so high in adults. In catarrhal otitis media the temperature does not usually exceed 1° or 2° above normal.

(*c*) **Appearance of the Drumhead.**—In suppurative otitis media before perforation it is quite similar in appearance to that of catarrhal otitis media. After perforation a dark spot is seen in a few cases, while in others the perforation is not visible. A pulsating droplet of mucus or pus is, however, significant of perforation. If the drumhead is destroyed the red promontory may be seen when the pus is cleared away.

(*d*) **The Probe.**—The probe may be used to differentiate between a reddened promontory wall and a reddened drumhead. The promontory is firm and unyielding, while the drumhead is resilient. With the probe a flake of mucus or pus may be brushed away, and thus show whether a perforation or intact membrane is present. Necrosis of the inner wall of the tympanic cavity may be demonstrated with the probe.

(*e*) **Inflation.**—Inflation of the middle ear and the simultaneous use of the diagnostic tube will produce a whistling tympanic murmur when perforation is present, or a soft blowing tympanic murmur when the drumhead is intact. Inflation should be practised with caution in acute cases, as the infectious material may thus be forced into the deeper recesses of the tympanic and mastoid cavities. If, during inflation, the distal end of the diagnostic tube is dropped into a basin of water, bubbles of air may be seen to rise if perforation is present. A manometric tube partly filled with water and inserted into the external meatus during inflation will cause the column of water to rise in the distal arm of the U-shaped tube during inflation if a perforation is present.

(*f*) **Compression of Air in the Meatus.**—Compression of the air in the external canal will force air through the perforation into the middle ear. The sound may be heard by inserting one end of the diagnostic tube into the nose of the patient (one nostril being closed), the other end being placed in the external auditory meatus of the observer.

Prognosis.—The prognosis has already been quite fully considered under Terminations and Sequelæ.

Treatment.—The treatment will be considered in connection with the subject of middle-ear suppurations in general. A brief *resume* will, however, be given in this connection.

(*a*) Complete asepsis or cleanliness and drainage should be striven for, to prevent the otorrhea becoming chronic. To fail in this regard subjects the patient's life to great hazard. If thorough asepsis is maintained, a secondary staphylococcus infection will be prevented. Staphylococcus infection means chronicity. Do not allow it to occur.

(*b*) In the early stage, before perforation occurs, a 12 per cent. solution of carbolic acid in glycerin (A. H. Andrews) should be dropped into the meatus. It is also a valuable remedy after perforation has occurred, as it is hygroscopic, reduces the edema of the mucous membrane, and thus establishes a more rapid flow of blood through the tissues. The resistance of the tissues is thus raised and the infection checked.

(*c*) Early incision of the drumhead should be practised at its most bulging portion. The incision should be free and curved to allow of good drainage. Simple puncture, the so-called paracentesis, is never indicated. It is an obsolete procedure. Drainage is the object sought for, hence use the lance with a free hand. Incision also promotes the reaction of inflammation, and thus favors a speedy resolution (Fig. 376).

(*d*) If the secretions are thick and tenacious, the syringe may be used to remove them. A sterile alkaline solution should always be used for this purpose, as it thins the secretion and facilitates its removal.

(*e*) An aqueous solution of the peroxide of hydrogen or hydrozone may also be used to break down the secretions, after which they are more readily wiped away with a cotton-wound probe.

(*f*) The cotton-wound probe should be used gently, but repeatedly, at each sitting, to wipe away all the secretion present. In my experience

this is the most effectual method of removing the secretion in those cases in which the perforation is of large size.

(*g*) Inflation of the middle ear may be practised with caution after the pain and other acute symptoms have subsided.

(*h*) A safer procedure is to use suction with Siegle's otoscope in the external auditory canal.

(*i*) Constitutional treatment: Calomel may be given in $\frac{1}{10}$ grain doses three to ten times a day. For the relief of the pain, 1 grain of codeine, or 3 to 6 grains of phenacetin may be given. The epipharynx should be frequently gargled after the von Tröltsch-Swain method.

Fig. 376

A long, curved incision extending across the drumhead and into the meatus at the upper portion.

(*j*) Six weeks of daily inspection and appropriate treatment will, in most cases, result in a complete cure. Less faithful and intelligent attention will result in many cases becoming latent or chronic, with the usual sequelæ so unfortunate in their effects.

(*k*) In those cases in which there is sagging of the postsuperior meatal wall the simple mastoid operation should be performed at once. Delay is dangerous. If the infection is staphylococcal, the urgency for the operative interference is not so great as in streptococcus infection. In the latter type of infection local treatment is usually unavailing, surgical procedures being required to effect a cure.

(*l*) The ice-bag may be used over the mastoid process for from two to four hours when great pain is present. If no improvement follows, it should be discontinued and operative measures considered. Discontinue the ice when pus flows freely and the pain subsides. If the infection is streptococcal, its use will be unavailing. If it is staphylococcal, it may abate the infective process.

(*m*) Leeches, natural or artificial, applied over the mastoid process and in front of the tragus are, perhaps, the most effectual method of promoting the reaction of inflammation and aborting the disease. (See Chapter VII.)

ACUTE SUPPURATIVE OTITIS MEDIA IN INFANTS AND CHILDREN.

In view of the fact that in 50 per cent. of the cases of measles there is an inflammatory affection of the middle ear in infants and young children, and that in all infectious diseases there is more or less inflammation of the ear, it is proper to give a brief consideration of inflammations of the middle ear as found in infants and young children.

The pathological changes found vary all the way from a simple catar-

rhal inflammation, with swelling and cloudiness of the mucosa, to infiltration and purulent secretion. The secretion is usually serous or seromucous, with some pus cells.

The embryological conditions influencing the occurrence of the process in infants are (*a*) the presence of an opening in the upper segment of the drumhead, which does not always close before birth. In bathing, water may thus gain entrance into the tympanic cavity and set up an inflammation. (*b*) According to Weiss, the mucous membrane of infants is embryonic in type, and is, therefore, more liable to be affected by microörganisms.

The cachexia of infancy, bronchitis, the infectious fevers, and chronic intestinal catarrh are also special causes of this affection in children.

Coughing, vomiting, sneezing, and other violent respiratory efforts force infected matter through the Eustachian tube into the middle ear and excite catarrhal and suppurative inflammations.

Otitis media is sometimes present in the newborn, and is probably due to the forcible entrance of amniotic fluids into the middle ear during delivery.

Postnasal adenoids, enlarged or diseased tonsils, epipharyngitis, and coryza are conditions peculiarly prevalent among children, and contribute toward the causation of otitis media.

Symptoms.—In infants with cachexia there are often no subjective symptoms. Objectively, the drumhead may be a little reddened, especially about the short process and along the handle of the malleus. A small amount of slimy secretion may be found in the canal. It may be questioned whether the cachexia is the cause of the ear disease, or whether the ear disease is the cause of the cachexia. It is quite certain, however, that even a mild suppurative process in infants is quite sufficient to cause pronounced disturbances of nutrition. Every case of malnutrition, peevishness, twisting of the head, or dropping it to one side should lead to the careful inspection of the ears of these young patients. Boring the head, or occiput, into the pillow, hanging the head to one side (affected ear), placing the hand to the affected ear, going to sleep when lying on the ear toward which the head is inclined, refusing to take the breast except on the side which allows the patient to lie with the affected ear against the bosom, all point to acute inflammation of the middle ear. The infant or young child cannot tell of his sufferings, but if the physician carefully observes his actions, he will often find them speaking louder than words.

In older children the symptoms are more pronounced, and just prior to perforation of the drumhead the pain is often excruciating. There may be vomiting, unconsciousness, and convulsions. In other words, signs of meningeal irritation are often present. This is accounted for by the free anastomoses of the bloodvessels of the temporal bone and the cranial cavity.

When perforation takes place there is an immediate relief of all the symptoms.

The tendency to frequent relapses is a prominent characteristic of

otitic inflammations in infancy and childhood. After the tenth to the fifteenth year of age this tendency is not so marked.

Treatment.—The treatment is almost the same as in adults, with the exception that tympanic inflation is usually followed by great relief. When the inflammation is suppurative in character, the external meatus should be thoroughly cleansed with cotton-wound probes. The same treatment described under acute suppurative otitis media and acute mastoiditis is applicable to these cases. Adenoids, when present, should be removed.

CHRONIC SUPPURATIVE OTITIS MEDIA.

Owing to the faulty instruction, or, more properly speaking, to the lack of systematic instruction in otology in most American medical colleges, false ideas are prevalent concerning the true importance of chronic suppurative otitis media. The acute exacerbation is the only phase that ordinarily attracts serious consideration. When we recall the fact that none of the prominent life insurance companies will accept an applicant who is affected with chronic otorrhea, we are brought face to face with the business man's view of the disease. He has found, after a careful study of the mortality tables, that applicants thus affected do not live to the full term of their life expectancy. Both clinical observation and pathological findings bear out this conclusion. Clinically, we find chronic otorrhea attended by a sallow muddy complexion and acute exacerbations, during which there is pain and mastoid tenderness, and an increased flow of pus, which subsides only to return again after many weeks, months, or years. In still other cases we find sinus thrombosis, septicemia, meningitis, brain abscess, etc., which often lead to a fatal termination. Bearing these facts in mind, and their relation to what seems to be a simple and harmless chronic otorrhea, it becomes apparent that chronic suppurative otitis media is not to be thought of as a trivial or an unimportant disease

Pathology.—It is very interesting, as well as instructive, to trace the pathological changes which occur in the mucous membrane, periosteum, and bony wall of the tympanum in the course of chronic suppurative otitis media. They may be somewhat didactically stated as follows:

(*a*) The first important change, after the hyperemia and slight infiltration of the early stages, is the loss of the ciliated columnar epithelium in circumscribed areas, while in other portions the mucous membrane is much thickened, the ciliated epithelium often being several layers deep. In cholesteatoma the epithelium becomes flattened or epidermic in character.

(*b*) Infiltration, thickening, dilatation of the bloodvessels, and the new formation of bloodvessels gradually take place. The lymph vessels in the deeper layers also become dilated (Politzer).

(*c*) The tubules of the acinous glands sometimes become closed by adhesive inflammation, and cystic cavities are thus formed.

(*d*) The round-cell infiltration gradually changes to spindle cells, the inflammatory exudate being thus transformed into adhesive or cicatricial bands.

(*e*) The periosteum remains intact for a period varying from a few weeks to a few years, although it is probable that in a majority of cases it loses its integrity within two years' time.

(*f*) As the outer plate of the bone is nourished by the periosteum, it thus loses its nutrient fluids, and becomes carious and necrosed. Ulceration of the mucous membrane, periosteum, and bone rapidly succeed one another until there is extensive destruction of the tissues, often exposing the sigmoid sinus, dura mater, or jugular bulb.

(*g*) Avenues of infection of the cranial contents are thus opened and the patient's life is placed in imminent danger.

(*h*) All these changes may occur in the course of a chronic otorrhea, without any alarming symptoms whatsoever, such a state of affairs existing for an indefinite time, perhaps for years, without giving rise to severe or alarming symptoms. On the other hand, dangerous complications may occur at any time, speedily leading to a fatal issue.

In addition to the foregoing pathological changes should be included the loss of the malleus and incus through atrophic and ulcerative degeneration of the tendinous bands holding them in place. Being thus loosened, they may become necrosed and slough away through the large perforation in the drumhead. The perforation in the drumhead is usually large, often involving the entire membrana tensa, the size and location of the perforation varying with the location and nature of the pathological process in the middle ear and associated cavities.

Symptoms.—The symptoms vary with the nature and location of the pathological process, as well as with the acuteness or chronicity of the same. In some cases the signs of the ear disease are so latent that but little thought and less attention are given to them. In others, there is a constant or intermittent flow of pus or mucopus into the external canal, with occasional twinges of pain. In still others, there are acute exacerbations, characterized by profuse pus discharge, often admixed with blood, and attended by pain, mastoid tenderness, and swelling. The chief difference between the types is in the degree of obstruction to free drainage and in the virulency of the microörganisms in the tympanic cavity and mastoid cells. So long as there is free drainage, and there are no virulent microörganisms jeopardizing the middle ear and cranial contents, the symptoms are not alarming in character. On the other hand, when free drainage is interfered with, and virulent infection supervenes upon the preëxisting less virulent infection, the symptoms assume a most aggravated and alarming character. In other words, the so-called chronic suppurative otitis media assumes the proportions of an acute mastoiditis, with threatened intracranial complications.

The Latent Form.—The symptoms in this type of middle-ear suppuration are scarcely appreciable to the patient, as there is little discharge and no pain or tenderness over the mastoid process. The patient often says there is no discharge, nor has there been for many months or

years. Ocular inspection, however, will often show a small amount of pus in the middle ear and external auditory meatus. The amount is so small that it does not reach the concha, but is evaporated in the meatus, the dried remains being thrown off with the cerumen and epidermis. In these cases the drumhead is perforated, usually away from its margin, the size varying from a millet-seed to almost the entire membrane (pars tensa), though I have frequently observed cases of latent otorrhea when the perforation was marginal.

The Chronic Discharging Form.—There is a profuse but intermittent purulent discharge, sometimes admixed with mucus and blood. Acute coryza, epipharyngitis, and exposure to inclement weather increases the amount of discharge and its purulency. Pain may be present, especially when aggravated by either of the foregoing conditions. There is, at these times, a slight tenderness over the mastoid process, especially over the antrum. Inspection of the fundus meati shows pus filling it completely, or oozing through the perforation in the drumhead. If the drumhead is largely destroyed, and the pus has its origin in the attic, it may be seen to trickle down the long process of the incus into the atrium of the middle ear. After removing all the pus from the middle ear, the mucosa over the promontory may be seen as a yellowish-red reflex. Granulations or polypi may be present, filling the middle-ear cavity, or even protruding into the external meatus. I have seen cases in which the polyp protruded into the concha of the auricle. When polypi are present blood is often admixed with the secretions.

There is more or less elevation of temperature during the subacute exacerbations. The skin is yellow and muddy, the whites of the eyes are slightly discolored, and a feeling of lassitude and mental inertia possesses the patient.

Chronic Otorrhea with Acute Exacerbations.—This form of chronic suppurative otitis media attracts attention on account of the exacerbations of pronounced pain, mastoid tenderness, and elevation of temperature. The patient and attending physician become conscious of the danger, which, indeed, may have existed for some weeks, months, or even years previously. What was previously regarded as a simple harmless discharge is now recognized as a threatened mastoiditis. There is a profuse flow of pus, perhaps admixed with blood, the mastoid is tender to the touch, either at its tip or over the antrum, and the temperature ranges from 1° to 4° above normal. There may be no distinct chill.

The patient complains of lassitude, and is disinclined to pursue his vocation. He may be possessed with a feeling of apprehension or of impending danger.

Having thus characterized the more obvious symptoms of the three most common types of chronic suppurative otitis media, the further study of the signs of this disease, and their significance in estimating the nature and location of the pathological changes, will be based upon the location of the perforation in the drumhead.

Perforations, their Location and Significance.—To Leutert, Zaufal, and others we owe our knowledge of the pathological significance of the

location of the perforations in the drumhead. It may be said, in general, that if the perforation is marginal, there is bone necrosis in the region of the perforation; and if the perforation does not involve the margin of the drumhead, but is near its centre, bone necrosis is absent, the case being one of simple suppurative otitis media. The information thus afforded, while not absolute, is nevertheless very valuable in arriving at a full knowledge of the case.

The Clinical Significance of Chronic Perforations of the Membrana Tympani.—A central perforation (one not marginal) (Fig. 377) (*a* and *b*) usually signifies inadequate drainage and ventilation through the Eustachian tube, the perforation occurring at the point of least

Fig. 377

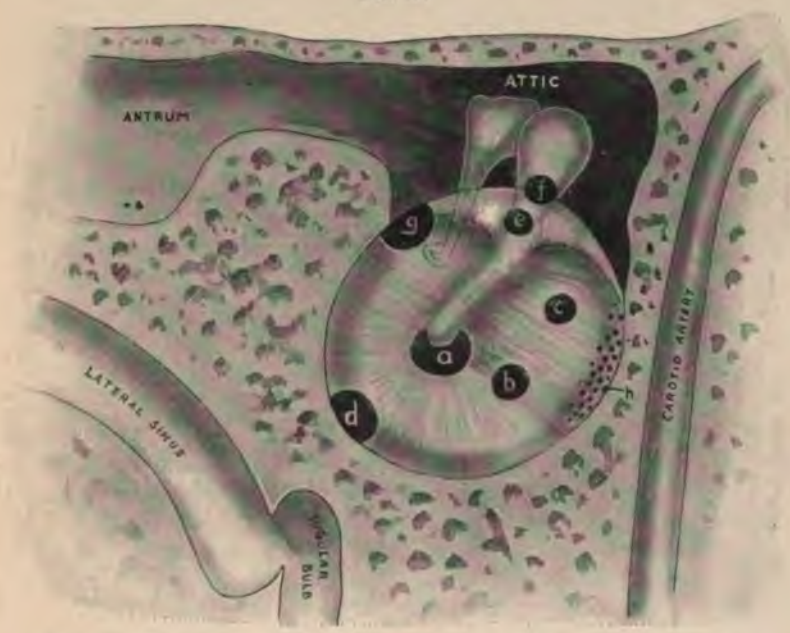

The significance of central and marginal perforations of the membrana tympani.

resistance. A central perforation is rarely attended by necrosis of the bony walls of the cavum tympani or of the ossicles, and may be successfully treated without major surgical interference. According to Leutert, all central perforations indicate tubal infection.

(*c*) While this is a central perforation, it is located over the tympanic orifice of the Eustachian tube, and is the result of continual middle-ear infection from the tube. The Eustachian tube is probably infected from the epipharyngitis which is present. The epipharyngitis may be due to the presence of adenoids or their remnants, or to diseased tonsils, or to ethmoiditis and sphenoiditis. A perforation of the membrana tympani over the tympanic orifice of the Eustachian tube should, therefore,

direct the attention of the aural surgeon to the epipharynx and the contiguous structures, rather than to the tympanic cavity. A radical mastoid operation upon a case with a perforation at this point would, in all probability, fail to check the otorrhea. An attempt to close the tympanic orifice of the Eustachian tube at the time of the radical operation would, in all probability, meet with failure, as the continued infection from the epipharynx would prevent closure. The rational treatment of such a case would be to cure the sinuitis, remove the adenoids and tonsils, or to adopt such other remedial measures as will cure the epipharyngitis.

(*d*) A perforation of the inferior margin of the membrana tympani signifies necrosis of the inferior wall or floor of the tympanic cavity. The only vital structure in this region is the jugular bulb (Fig. 377). As the bony wall separating the tympanic cavity and the jugular bulb is usually quite thick, the perforation may signify nothing more than necrosis of the floor of the tympanic cavity, a region which is accessible to curettement through the external meatus. In rare instances, however, the jugular bulb is separated from the tympanic cavity by only a thin bony wall, or the wall may be entirely absent. A marginal perforation at this point should, therefore, be regarded as suspicious of necrosis from jugular bulb disease, especially if septic symptoms are present. The exploration and curettement of the floor of the tympanum should in such cases be prosecuted with caution.

(*e*) A perforation of the membrana flaccida immediately above the short process of the malleus usually signifies necrosis of the head of the malleus, a structure in close apposition to the perforation.

(*f*) A marginal perforation immediately above the short process of the malleus and extending to the superior wall of the meatus usually signifies necrosis of the tegment tympani (roof of the attic).

(*g*) A perforation of the membrana tympani at the margin of the posterior superior quadrant of the membrana tympani usually signifies necrosis of the incus and of the bony wall of the antrum.

(*h*) Numerous small perforations near the margin of the membrana tympani are usually significant of a tuberculous otitis media.

From the foregoing data it may be inferred that a central perforation signifies a simple infectious process in the cavum tympani, whereas a marginal perforation usually signifies bone necrosis. Marginal perforations are, therefore, indicative of a more serious process in the middle ear (cavum tympani) than is indicated by a central perforation. The entire absence of the membrana tympani is equivalent to a marginal perforation, and is strongly suggestive of bone necrosis.

While the significance of chronic perforations is generally to be interpreted as given in the foregoing paragraphs, it should not be inferred that the location of the perforation is an infallible guide to the condition present in the middle ear and mastoid cavities. All the other clinical phenomena should be taken into consideration, and a conclusion be drawn from the entire symptom complex.

Prognosis as to Hearing.—In simple or central perforations the hearing may be but slightly affected after the suppurative process is relieved. In the complex or marginal perforations, with bone necrosis, the hearing is usually diminished after the radical operation, whereas it is greatly improved after the Heath operation. The patient should be made to understand that, while every effort will be made to maintain or improve the hearing, the chief concern is to check, or to cure, the suppurative process, which, if allowed to run its course, may jeopardize both the health and life of the patient.

According to Clarence Heath, of London, many of the cases heretofore operated by the radical method may be cured by his method of operating. (See Meatomastoid Operation.) In addition to a less radical procedure, he claims for his operation that the hearing is not only conserved, but that it is usually restored to near the normal. My own experience with the meatomastoid operation is limited to twelve cases, and thus far the results obtained have been all that he claims. The cases selected by me for this operation have been those in which the ossicles were not markedly necrosed, though the perforation in some was marginal. The prognosis as to the permanent cure of the disease by this operation is still open until further experience demonstrates its exact place in otological surgery. That the hearing is preserved, and usually greatly improved by this method of operating, is, I believe, fairly well demonstrated.

Treatment.—The treatment of chronic suppurative otitis media does not offer a brilliant therapeutic field. In spite of all that can be done with local treatment, the discharge often persists, or, if checked, recurs within a few weeks or months. Many so-called "cured cases" are in reality only latent, and with the first "cold in the head," or other local irritation, become active again. This tendency is so strong that many otologists have regarded the persistence, or the tendency to recurrence, as an indication for the radical mastoid operation. While this is probably an extreme view, it is, nevertheless, a more rational one than the view held by some, that most cases of chronic otorrhea may be cured by simple local treatment, or by simple operative measures through the external auditory meatus. As a matter of fact, each case should be diligently studied as to the local morbid conditions, and as to the main etiological factors. Furthermore, the pathological laws underlying infectious processes in cavities lined with mucous membranes should be well considered. (See Chapter VI.)

The treatment of chronic suppurative otitis media will be studied, with the foregoing facts in mind, under the following headings:

The Treatment of Chronic Otorrhea with a Central Perforation of the Membrana Tympani.—Chronic suppurative otitis media with a central perforation of the membrana tympani (Fig. 377 *a*, *b*, *c*) usually signifies a simple infection of the mucous membrane of the middle ear without involvement of the bony tissue of the tympanic walls, or of the ossicles, and is, therefore, often amenable to simple local treatment. An exception to this should be made when the perforation is located over the tympanic

orifice of the Eustachian tube (Fig. 377 *c*). A perforation in this region indicates a suppurative process in the Eustachian tube, hence the middle ear cannot be cured while the tubal infection continues. In such cases the first attention should be given to the Eustachian tube and the conditions giving rise to its involvement (adenoids, epipharyngitis, sinuitis).

The treatment of otorrhea with a central perforation of the membrana tympani is, therefore, divided into two classes, namely, (1) otorrhea with a central perforation, other than over the tympanic orifice of the Eustachian tube, and (2) chronic otorrhea with a central perforation of the membrana tympani over the tympanic orifice of the Eustachian tube.

1. The treatment of chronic otorrhea with central perforation of the membrana tympani which is not over the tympanic orifice (Figs. *a* and *b*) of the Eustachian tube is based upon (cardinal principles) free drainage, the removal of the morbid material, and the maintenance of aseptic conditions while repair is taking place and is as follows:

Dry Gauze Dressings.—In 1880–82, Dr. Spencer, of St. Louis, advocated the use of strips of dry gauze in the treatment of acute and chronic suppurative otitis media. Since then the same method of treatment has been urged by Gradinego, Pierce, Gradle, and others. The gauze promotes drainage of the secretions, and at the same time prevents further infection through the auditory meatus.

Fig. 378

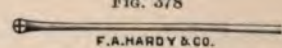

Bane-Allport gauze packer.

The fundus of the meatus should be mopped dry with a cotton-wound applicator before the strip of gauze is applied.

The end of the gauze is then carried to the membrana tympani with a probe packer (Fig. 378). The meatus is then loosely packed with the gauze and a small piece of cotton placed over it. The gauze should be removed every twenty-four to forty-eight hours and the secretions thoroughly removed with a cotton-wound applicator. A new strip of gauze is then applied as before.

In many cases the drainage and protection afforded by the gauze leads to the rapid disappearance of the infection and to repair. The perforation sometimes voluntarily closes by granulation from its edges. In other cases it persists, and may be closed by the application of a 33 per cent. solution of trichloracetic acid to its edges at intervals of a few days. No attempt should be made to close the perforation until the secretions are normal.

In addition to the foregoing method of treatment, alcohol in varying strength may be instilled into the middle ear through the meatus.

The middle ear may also be cleared by inflation through the Eustachian tube if the otorrhea persists after several treatments.

2. The treatment of otorrhea with a central perforation over the tympanic orifice of the Eustachian tube (Fig. 377 *c*) is more complicated than when the central perforation is otherwise located. The otorrhea is

perpetuated by the discharge of infected secretion from the Eustachian tube into the tympanic cavity, and cannot be cured without first overcoming the infection and discharge from the Eustachian tube. The mucous membrane of the Eustachian tube, when normal, is covered by ciliated columnar epithelium, which propels the secretions toward the pharyngeal orifice of the tube. In chronic infectious processes the cilia are lost, or their wave-like motion is inhibited, and the secretions flow in the direction of least resistance. The isthmus of the tube forms a barrier to the downward flow of the secretions from the tympanic end of the tube, hence they are poured into the tympanic cavity. The constant irritation of the membrana tympani over the tympanic orifice of the tube leads to perforation of the membrana tympani at this point. The first indication in these cases is to remove the cause of the tubal infection and inflammation.

If the tubal infection is due to a constriction at the isthmus of the tube, the tube should be dilated with bougies, and astringent and antiseptic solutions forced through it with a Weber-Liel catheter.

If the tubal infection is due to the presence of epipharyngeal adenoids, or their remnants, they should be removed.

If the infection is due to an epipharyngitis, it should receive appropriate treatment.

And, finally, if the tube is infected by the discharge from diseased nasal sinuses, especially the posterior ethmoidal and the sphenoidal sinuses, this condition should receive appropriate surgical treatment.

Having removed the cause of the tubal infection, the infection tends to disappear with little or no other treatment. In some cases, however, the infectious process in the Eustachian tube is attended by such pronounced tissue changes that additional local treatment is necessary.

The local treatment of the infected Eustachian tube and tympanic cavity consists in the use of the dry gauze treatment and in the use of mild astringent and antiseptic solutions through the Eustachian tube, a Weber-Liel catheter being used for this purpose. The Weber-Liel catheter consists of a small, long, flexible hard rubber catheter, placed inside of a larger catheter of the usual length. The larger catheter is passed to the pharyngeal orifice of the tube, and the smaller one is introduced through it to the isthmus of the Eustachian tube. A small syringe, filled with an alkaline antiseptic solution, is then attached to the smaller catheter and forced through the Eustachian tube into the middle ear. This course of treatment, following the removal of the conditions causing the tubal and middle-ear infection, is often attended by a complete cure of the chronic otorrhea.

The Treatment of Chronic Otorrhea with Marginal Perforations of the Membrana Tympani.—As marginal perforations of the membrana tympani usually signify necrosis of the ossicles, the bony tympanic walls, the tegmen tympani or tegmen antri, and the other contiguous bony structures, the treatment of chronic otorrhea thus characterized is not so simple as in central perforations. The same fundamental principles of treatment should, however, be observed. The drainage and the

removal of the morbid material are absolutely essential to the success of the treatment. The methods of establishing drainage and of removing the morbid material are radically different, for anatomical and pathological reasons, from those pursued in otorrhea with central perforations. It is obviously impossible to materially facilitate drainage with dressings in the external auditory meatus when the obstruction is in the antrum or aditus ad antrum. It is equally obvious that the morbid material cannot, under such conditions, be removed through the auditory meatus. Such measures must be adopted as will expose these regions to the surgeon's instruments.

1. When the perforation is just above the short process of the malleus (Fig. 377 *e*), the head of the malleus is probably necrosed, and the malleus should be removed. (See Ossiculectomy.) A 2 per cent. solution of the nitrate of silver may, however, be injected through the perforation to promote healthy granulation, with the hope of healing the diseased ossicle and thus avoiding the necessity of removing it.

2. When there is a perforation at the upper margin of the membrane (Fig. 377 *f*), and it involves not only the membrana flaccida but the superior wall of the auditory meatus, the tegmen tympani is probably necrosed. Even in these cases osseculectomy is sometimes attended by a cure of the chronic infection and otorrhea. If the floor of the attic is blocked, the removal of the malleus and incus may establish free drainage, and thus effect a cure. In other instances, ossiculectomy will not effect a cure, probably because the case is complicated by epipharyngitis, salpingitis, or necrosis of the antrum walls. Ossiculectomy is, therefore, only applicable to those cases in which the tegmen tympani is alone necrotic, the complicated cases being amenable to the meatomastoid or the radical operation, preferably the radical operation.

3. When the chronic otorrhea is attended by a marginal perforation at the postsuperior quadrant of the membrana tympani, as shown in Fig. 377 *g*, necrosis of the antrum is probably present. The incus also may be necrosed. To establish drainage, and to remove the morbid material, either the radical or the meatomastoid operation should be performed. It is barely possible, however, that by irrigating the attic through the perforation, drainage may be established through the aditus ad antrum and a cure be effected. In these cases the meatomastoid operation appears to be well adapted.

4. With a perforation at the inferior margin of the membrana tympani (Fig. 377 *d*), the necrosed bone may be removed with a curette introduced through the auditory meatus. If septic symptoms are present, the floor of the tympanic cavity should be cautiously explored, as the necrosis may be due to an extension from the jugular bulb. If septic symptoms are present in such a case, the rational procedure would be to perform either the radical or the meatomastoid operation, and then expose the sigmoid portion of the lateral sinus and the jugular bulb. If septic symptoms are absent, the floor of the tympanum should be explored with a blunt probe for necrotic bone, and if found it should be carefully removed with a bent curette through the perforation. The

perforation should be previously enlarged by two divergent incisions. After curettement, the meatus should be loosely packed with sterile gauze, as recommended in simple central perforations. The gauze should be removed daily, the meatus freed of secretions, and repacked with gauze, until the necrotic area is healed and the perforation closed. If the secretions disappear and the perforation persists, it may be closed by the application of a 33 per cent. solution of trichloracetic acid.

5. Otorrhea attended by a perforation of the membrana tympani at its anterior margin usually signifies necrosis in this region. As the carotid artery passes upward through the temporal bone near the anterior boundary of the cavum tympani, curettement should be cautiously performed in this region (Fig. 377).

6. Numerous pinpoint perforations of the membrana tympani usually signify a tuberculous otitis media.

Other Methods of Treatment.—Curettage of the attic *via* the external auditory meatus should be undertaken with great reluctance and caution. If granulations are present, it is quite probable that the tegmen tympani is necrosed and that the granulations are thrown around and over it to wall off the invading pathogenic bacteria from the meninges. The removal of the granulation tissue without at the same time establishing free drainage of the secretions from the tympanic cavity might lead to infection of the meninges. Such a condition may be much more successfully and safely (and I may add more conservatively) treated by the radical or the meatomastoid operation.

The *alcohol treatment* has been held in high esteem in chronic suppurative otitis media. Its field of usefulness is chiefly limited to central perforations, except when it is over the tympanic mouth of the Eustachian tube (Fig. 377 *c*). In otorrhea with a marginal perforation, alcohol only relieves the symptoms, but does not cure the disease.

The alcohol may be used in various dilutions, ranging from 25 to 95 per cent., beginning with the milder solution to avoid pain, and then using the stronger solutions. The alcohol should be left in the cleansed ear for twenty minutes at each treatment.

Alcohol holding boric acid or iodoform in solution or suspension may be used in otorrhea with a central perforation, though it is probable that its therapeutic value is not increased by the addition of the boric acid or iodoform.

In fetid otorrhea the instillation of the *compound tincture of benzoin* may be used to remove the fetor. It is also an antiseptic and astringent, and acts favorably upon the diseased tissues. The fundus of the meatus should be mopped dry before applying the compound tincture of benzoin.

When the mucous membrane of the middle ear has undergone fungoid granulation degeneration, a 95 per cent. solution of carbolic acid may be dropped into the ear, care being exercised to prevent the acid coming into contact with the meatal skin. At the expiration of one minute alcohol should be instilled into the ear to check the action of the acid, after which the ear should be mopped with a cotton-wound applicator until dry. The meatus should then be loosely packed with dry, sterile gauze.

CHOLESTEATOMA.

Cholesteatoma of the middle ear is characterized by the formation of masses of epidermoid cells arranged in concentric layers between which are found cholesterin crystals.

Etiology.—About the year 1840, J. Müller described new formations in the temporal bone, resembling pearly growths. They were composed of concentric layers of epidermoid cells with cholesterin crystals between them. They are commonly found in the antrum and attic, and are covered by a delicate membrane which is closely adherent to the periosteum of the bone to which they are attached. This variety is known as primary cholesteatoma, as it seems to have its origin in the cavity where it is found. The secondary and most common type is due to an extension of the epidermis of the external meatus and membrana tympani into the middle ear through a perforation in the drumhead.

Primary Cholesteatoma.—Primary cholesteatoma is variously believed to be heteroplastic, possibly arising from the epithelium of the ductus vestibule; that is, it is a remnant of the second visceral cleft left behind after its closure. Mild inflammatory action in the middle ear favors their growth, whereas severe inflammation hinders it. Primary cholesteatoma is probably quite rare. Its existence might well be doubted if it were not for the fact that eminent observers have made full and detailed reports of such cases. Other equally eminent observers claim there is no such condition, all cases being secondary to suppurative processes in the tympanic cavities. Von Tröltsch, Habermann, Politzer, and others hold this opinion.

Secondary Cholesteatoma.—This is the type found in practice, the primary form being chiefly limited to the literature. The masses in all probability have their origin from extensions of epidermis from the external meatus and drumhead. The conditions favoring this extension are:

(*a*) A marginal perforation of the drumhead.

(*b*) A mild chronic suppurative inflammation of the mucosa of the middle ear.

(*c*) A fistulous opening in the posterior or superior wall of the meatus.

(*d*) Adhesions at the margin of the perforation.

(*e*) Adhesions of the end of the handle of the malleus to the promontory.

(*f*) Aural polypi.

Perforations in the posterior portion of the membrana flaccida are especially liable to be followed by cholesteatoma on account of the tongue-like or thickened extension of epithelium from the superior wall of the meatus to the drumhead at this point. Politzer reports a case in which the growth seemed to have its origin in a fistulous opening in the mastoid process.

The cholesteatomatous masses are of a pearly gray color, and slightly lustrous. Upon section they are found to be composed of concentric

layers of epidermic cells intermixed with detritus and cholesterin crystals. If the conditions are favorable the masses grow larger and larger, causing eccentric pressure atrophy of the bony walls of the cavity involved. In some cases there is bone necrosis, which may thus expose the brain, lateral sinus, and labyrinth to the infection contained in the masses. They are broken down in their centres, richly odorous, and loaded with pathogenic microörganisms. The central breaking down is due to putrefaction.

Aural polypi, with mild suppurative inflammation, are often attended by cholesteatomatous formations. If there is an active or profuse pus discharge, the formations are checked or altogether dissipated. The free drainage incident to a profuse discharge seems to prevent the further inward extension of the epidermic process, the masses gradually disappearing, and the cavity healing with a layer of flat epithelial covering or matrix. The size of the cholesteatomatous masses varies from a hemp-seed to a large walnut. Their shape either conforms to that of the cavity in which they form, or they are round, oval, or very irregular in outline.

Extensions of the cholesteatoma into the Haversian canals have been demonstrated, which may, in part, account for the marked tendency to recurrences in spite of thorough operative interference. E. B. Dench has called attention to the presence of small masses of cholesterin crystals without epithelial cells, the etiology and pathology of which are not known. He reported two such cases operated by the radical method with good results.

Symptoms.—The masses may be present for years without giving rise to distinct symptoms. Sudden swelling of the mass from the entrance of moisture into the external meatus, as from sweating, bathing, syringing, etc., may cause pressure symptoms, as pain and necrosis. In this event there may be a feeling of fulness or pain in the affected ear, with headache, nausea, vomiting, staggering gait, fever, and aprosexia. The moisture causes the horny cells to swell, and the sudden pressure thus exerted causes the above signs of pressure and of intracranial irritation.

Inspection of the meatus shows it to be more or less filled with a pearly gray mass, admixed with granulations or aural polypi. If a portion is removed and placed in water, it appears as shreds of delicate tissue with the golden grains of cholesterin, which are characteristic of this growth. If the mass is favorably located, it may be removed with the syringe or ear spoon. In other cases it is necessary to do the radical mastoid operation to eradicate it. Even then it may be necessary to repeat the operation one or more times before a satisfactory result is obtained.

The termination of cholesteatoma may be by (*a*) epidermization after the spontaneous or instrumental removal of the mass; (*b*) it may be forced through the Eustachian tube into the epipharynx, or into the maxillary articulation through the anterior wall of the meatus; (*c*) it often breaks through the walls of the semicircular canals (Jansen);

(*d*) in some cases it pushes its way through the external plate of the mastoid process and presents the appearance of a mastoid abscess; (*e*) in still other cases it may cause necrosis of the tegmen antri and tympani and cause death from involvement of the cranial contents; (*f*) death may also result from sepsis arising from the absorption of the retained secretions; (*g*) and from meningitis, brain abscess, sinus thrombosis, or thrombosis of the jugular vein; (*h*) and through the digastric fissure.

Diagnosis.—The diagnosis may be made by the removal of the growth and subjecting it to microscopic examination. This may be done with a curette, probe, or syringe when the growth is in the middle ear. If in the antrum, it can only be removed by mastoid operation. Sydacker has called attention to the sedimentation of the washings of the ear, which, when microscopically examined, show the epithelial cells with neuclei staining very faintly. Particles of bonedust are also shown as highly refractile crystals. Brühl-Politzer have called attention to the use of a chloroform solution of the cholesteatomatous masses in which the cholesterin produces a greenish discoloration.

Prognosis.—The prognosis is bad. In those cases in which there is a spontaneous or instrumental expulsion of the cholesteatoma the cavity usually becomes refilled with it. Even after the most thorough radical operation the disease may persist. This is not at all difficult to understand when we recall the fact that the cholesteatoma forces its way into the Haversian canals of the bone, thus effectually forming focal centres from which it may extend again. Sac-like prolongations into the bone have also been observed, thereby making it difficult to entirely eradicate the process. The uncertainty of cure leaves the possible complications, as meningitis, brain abscess, pyemia, sinus and jugular thrombosis, a menace to the health and life of the patient. Cures are, however, frequently effected, and we are warranted in attempting thorough surgical measures for its relief.

Treatment.—The treatment in uncomplicated cases may be begun with the removal of the cholesteatoma through the perforation in the drumhead with small curettes, ear hooks, etc., or with a syringe. In some instances it is found to be advantageous to force sterile fluid through the Eustachian tube into the middle ear, thus getting the force of the stream of water behind the mass, and forcing it into the external meatus.

Should polypi be present, they should be removed. If there is necrosis of the ossicles, they should be removed. Adhesions of the edges of the perforation to the inner wall of the tympanum, or adhesions of the end of the handle of the malleus to the promontory should be broken down. After having removed the tumor the parts should be dusted with an antiseptic powder.

Should these simple measures prove ineffective, recourse must be had to the radical mastoid operation, elsewhere described in this work. The meatomastoid operation is not indicated. As the chief object of the meatomastoid operation is to preserve or improve the hearing, and as this object is defeated by the unavoidable dislocation of the ossicles in removing the cholesteatoma, the meatomastoid operation is contra-indicated.

CHAPTER XLIV.

THE SEQUELÆ OF SUPPURATIVE OTITIS MEDIA, MASTOIDITIS, AND CHOLESTEATOMA. SUPPURATION OF THE LABYRINTH.

DISEASES OF THE MASTOID PROCESS.

PRIMARY disease of the mastoid process is very rare. Diseases of the mastoid are usually secondary to a suppurative process in the middle ear. Pneumococcus and more especially influenza infection sometimes appear in the mastoid process without first affecting the middle ear. As a matter of fact, all, or nearly all, suppurative middle-ear inflammations probably also involve the mastoid cells.

It is difficult to separate the suppurative processes of the middle ear from those of the mastoid cells. Clinically the disease is subdivided upon an arbitrary basis according to the focal manifestations present. The anatomical distribution of the pneumatic spaces of the temporal bone is so complex that it is advantageous to subdivide suppurative inflammations within them according to the focal centre of involvement, while, on the other hand, it is more rational to regard the process as one disease regardless of the focal symptoms. The antrum is perhaps the axial centre of the pneumatic spaces of the ear, the mastoid cells communicating with it posteriorly, while the attic and atrium (middle ear) communicate with it anteriorly. If the case requires external surgical treatment, it is most centrally attacked by way of the antrum, the operative field being extended posteriorly into the mastoid cells and anteriorly into the middle-ear, according to the conditions present. If the disease is mild and focalized in the middle ear, it may be regarded as middle-ear disease. In those acute cases terminating without focal mastoid symptoms it has been customary to speak of them as acute otitis media regardless of the fact that the mastoid cells were also involved.

With this understanding the various diseases of the mastoid process will be described.

ACUTE SIMPLE MASTOIDITIS WITHOUT INTRACRANIAL LESION.

Symptoms.—It is probable that in nearly every case of acute infection of the middle ear the mastoid cells and antrum are also involved. It is chiefly in those cases in which free drainage is interfered with that the mastoid symptoms become manifest. The mastoid symptoms are chiefly those of pressure from retention of the secretions within the cells. They are pain, redness, swelling, and tenderness upon pressure or

percussion over the mastoid process. When such symptoms supervene, the original disease sinks into a place of secondary importance, while the secondary conditions come forward as the object of greatest interest. The disease is no longer called otitis media, but is called mastoiditis.

There is a sudden rise of temperature accompanied by rigors of varying intensity. Many cases, however, have but slight elevation of temperature at any time during the disease. In others the rise is as high as 104°.

The pain originates behind the auricle and radiates toward the teeth and shoulders (Politzer), the occiput, neck, and face. Mastication may be painful on account of an involvement of the bony portion of the external meatus, which is in close proximity to the glenoid fossa.

The sternocleidomastoid and the other muscles of the neck attached to the mastoid account for the pain upon movements of the head. Torticollis may be present in mastoiditis. It is due to a fixation of the muscle to avoid pain upon movement. It has been shown by others (Broca and Lubet-Barbon) that it is sometimes due to enlargement of the cervical glands and to infection from measles, in which otitis media was not present. In the case of measles the torticollis was probably due to glandular enlargement from infection.

Schwartze calls attention to the intolerance of pressure over the whole mastoid, but more particularly immediately below the zygomatic ridge (antrum).

The appearance of the skin over the mastoid process becomes red and swollen, and can no longer be picked up between the fingers. In some cases the auricle stands forward, even approaching a right angle to the side of the head in some instances. In these cases a subperiosteal abscess is present.

The aural discharge may be scanty or profuse. Redness and swelling of the postsuperior wall of the external meatus near the drumhead are commonly present. This condition is variously spoken of as the "dip," "chute," or "bulging" of the postsuperior wall. Under the pathology of the mastoid I have already referred to the presence of pneumatic mastoid cells (the border cells), which are found between the antrum and meatus. These break down, and the retained secretions cause the wall to thus "dip" or "bulge." This sign is pathognomonic of mastoiditis of a destructive type, and is therefore a strong indication for an immediate operation (Fig. 375).

The diagnostic value of this sign has been emphasized by Schwartze, Macewen, Holmes, Sheppard, Duplay, and many others. Politzer thinks it is not necessarily an indication for the mastoid operation, while Schwartze, Broca, and Luber-Barbon hold the contrary view.

Delay in operating subjects the patient to almost certain danger, even though it does not become apparent for years. I can recall but one case (following an attack of influenza) in which the "dip" and all other signs of middle-ear and mastoid disease seemed to disappear. I use the word "seemed" advisedly, for there is little doubt as to a subsequent recurrence in such cases. I fully recognize that there are

exceptions to all rules, and that this instance may be one of them. Nevertheless, the rule and not the exceptions should guide us.

Perforation of the drumhead nearly always exists. It is usually small and filled with pus and debris, which pulsates synchronously with the heart beat.

Granulations sometimes protrude through the opening and block the discharge of the secretion. The removal of the granulations is often sufficient to establish free drainage and relieve the acute mastoid symptoms. It may be doubted whether it really cures the mastoiditis, as this may remain in a latent form for years before culminating in an alarming exacerbation.

In still other cases the perforation is large and discharges but little pus. In these cases the aditus ad antrum is obstructed. This is of interest as a diagnostic and prognostic point. It enables the attending physician to locate the obstruction prior to the operation, and to determine whether relief may be expected from a simple middle-ear operation (removal of the granulations) or whether it will be necessary to do a postauricular mastoid operation to open the aditus ad antrum.

Spontaneous cures should be looked upon with suspicion, as in nearly every case it amounts to nothing more than a remission. Politzer, Schwartze, Duplay, Holmes, Ballenger, Stucky, Macewen, Dench, St. John Roosa, Hollinger, Pierce, Whiting, and others report recurrences in cases which had seemed to be cured.

One should be extremely modest in claiming to have "cured" mastoiditis without surgical intervention. That such a termination may occur cannot be denied, but such a termination is rare.

Treatment.—If the case is seen before spontaneous perforation of the eardrum has occurred it should be freely incised at the points of greatest bulging. This is done to promote the reaction of inflammation and to relieve the pressure and the tissue necrosis. The tissues in the presence of an acute infectious process are very susceptible to necrosis while pressure is maintained, hence the necessity of an early incision. The incision should be a long and curved one, so as to make as free an opening as possible. Some writers advise carrying the incision into the meatus (Fig. 376), thus cutting through the annular plexus of vessels surrounding the attachment of the membrana tympani. The free bleeding thus produced acts favorably upon the progress of the inflammatory process; that is, it promotes the reaction of inflammation and favors free drainage. Some writers condemn the extension of the incision through the annular plexus of vessels, on account of the liability of extending the infection through these vessels. If there is a virulent streptococcus infection the incision should not be thus extended, while it may be so extended in the milder infections. Personally, I do not often carry the incision into the external meatus. If the destructive process is not great, there is no necessity for so doing, whereas if the destructive process is great, there are dangers attending such a procedure.

Cold applications by means of an ice-bag or a Leiter coil may be made over the mastoid process if the case is seen within thirty-six hours of the

onset, and if there is great pain and scanty discharge of pus. If applied after this time, it has little or no therapeutic value. Cold reduces the inflammatory reaction, diminishes the swelling of the mucous membrane, and thus overcomes the obstruction to the flow of the secretions. If the applications fail to remove the tenderness and pain and to establish a more free discharge of secretions, it should be discontinued and leeches applied. Indeed, leeching is much more efficacious than ice. In some cases the cold applications mask the symptoms and lead the surgeon to believe the disease is conquered. The real problem in acute mastoiditis is not to bring about an abatement of the acute symptoms, but to relieve the patient of the suppurative process by promoting the reaction of inflammation. Even though the acute symptoms disappear and the patient appears to be well, but still has an ear discharge, a cure is not effected. The patient should have no ear discharge or perforation of the eardrum. Too much attention has been given to the relief of the acute symptoms, and too little to the cure of the suppurative process. The acute symptoms will usually subside if nothing is done for the patient. It is true that in most cases less damage follows if appropriate attention is given to the acute symptoms during their manifestation. Eradication of the suppurative process should be the ultimate aim of the treatment. The attending surgeon should not be satisfied, therefore, to relieve the pain, redness, tenderness, and temperature, but should also institute such remedial measures as will modify the acute symptoms and at the same time eradicate the infection.

To accomplish the foregoing results it may become necessary to perform a mastoid operation, which, if done at a sufficiently early period, need not be an extensive or formidable affair. On the other hand, the delay of a few days or weeks may make it necessary to perform a radical operation. The cold applications, the incision of the eardrum, leeching, etc., should therefore be tried early, so as to determine as quickly as possible whether the disease can be aborted. If the mastoid is still tender upon pressure and the discharge continues, there is a strong probability that the acute process will merge into a chronic one if surgical interference is not instituted. The point I wish to emphasize is that the simple operation may be performed within the first three or four weeks of the onset of the disease, whereas if delayed to a later period the meatomastoid operation may be necessary. There are hundreds of cases of chronic otorrhea which would never have existed had they been operated on sufficiently early, or if the operation has been delayed too long to be cured by the simple mastoid operation, had the meatomastoid or the radical operation been performed. Just when to operate, and the kind of an operation to perform, is the great problem in acute suppurative otitis media complicated by mastoiditis. It should also be stated in this connection that all cases do not need to be operated upon. Many get well without such interference. If the pain over the mastoid persists after the incision of the membrana tympani and the use of the leeches, an operation is indicated; that is, the disease will probably persist as a chronic otorrhea unless an operation is performed. The object of the operation is to prevent further mischief, rather than to

avert immediate danger. It is not good practice to wait for dangerous symptoms, as the mortality under these conditions is much higher. Chronic otorrhea is a signal of impending disaster, and every effort should be exerted to cure it, even though a radical operation is necessary to accomplish it.

The Leiter coil (Fig. 354) should be connected by rubber tubing with a tank or bucket of iced water, and the water passed through it by siphonage and allowed to escape into a vessel through another tube attached to the opposite end of the coil. The iced water should be renewed each time the tank becomes empty for about one hour, or until the pain ceases and the purulent discharge becomes more profuse.

An ice-bag filled with cracked ice may be used for about one hour instead of the Leiter coil. The ice should be renewed as often as it becomes melted. The bag may be fastened over the mastoid process by bands of linen.

Hot irrigations with bichloride of mercury, 1 to 5000, may be used every hour to promote the reaction of inflammation.

Bier's treatment by constriction of the neck, if judiciously applied, often exerts a favorable influence upon the course of the disease. The patient should be placed in bed, the foot of which is raised several inches from the floor, and an Esmarch elastic band applied around the neck. It should produce no pain or discomfort, and only slight cyanosis of the face. It should be kept in position about sixteen hours of the twenty-four. It should be applied four times daily, with two-hour intervals between applications. If the bandage is applied tight enough to produce pain, it may do great damage.

The object of Bier's treatment is to promote the reaction of inflammation; that is, to increase the passive hyperemia and the migration of leukocytes, so as to remove the bacteria and their toxins. Ice, in view of these principles, is contraindicated as it diminishes the reaction of inflammation. Inasmuch as the mastoid may be regarded as an encapsulated organ, ice is not always contra-indicated. Encapsulated organs sometimes become so distended by inflammatory swelling that the flow of blood through them is very much blocked. Ice relieves the distention and establishes the flow of blood, and is indicated under the circumstances. When the distention or pressure symptoms (excessive pain and scanty discharge of pus) are relieved ice should be discontinued and measures adopted that promote the reaction of inflammation.

Other methods of promoting the reaction of inflammation are leeches, light, heat, hot poultices, etc. (See Chapter VII.) Of these, leeching, the leukodescent light, and Bier's treatment are of special value in the treatment of acute mastoiditis.

Leeching should be more generally used than it is at present, as it is one of the best means of promoting the reaction of inflammation. I have seen cases following the measles running a temperature of 102° to 104°, rapidly subside after the use of leeches.

Subacute Mastoiditis.—This form of mastoiditis has been referred to under Acute Mastoiditis as the stage following the subsidence of the

acute symptoms. It should be regarded as a chronic disease, as it only responds to treatment suited to chronic cases. While the conditions present may be of recent origin, they do not respond to the treatment suited for acute cases. The infectious agent is usually the staphylococcus, the usual germ in chronic suppuration.

Subacute mastoiditis is, therefore, the persistent remains of an acute mastoiditis, in which the more active microörganisms have disappeared, the staphylococcus perpetuating the inflammatory process. It is amenable to such treatment as is recommended for Chronic Mastoiditis.

ACUTE PERIOSTITIS OF THE MASTOID PROCESS; SUBPERIOSTEAL MASTOID ABSCESS.

Subperiosteal mastoid abscess is characterized by a pronounced bulging outward of the affected ear. The auricle at its superior portion stands far from the side of the head, while its entire free border stands well out, almost at right angles to the plane of the side of the head. In other words, the outline of the ear, as seen from either the front or the rear, falls from the upright toward the horizontal plane of the head.

Upon manipulation the swelling above the auricle fluctuates more or less in proportion to the amount of pus beneath the soft tissues. Duplay says that before the pus forms externally one feels the elevation and depression, under pressure, of the external table of the mastoid.

The alarm occasioned by an abscess of this type is out of proportion to the danger attending it, as it rarely proves fatal.

Etiology.—It usually has its origin in an infectious otitis media which extends to the antrum and mastoid cells. In young children the middle ear and antrum alone are involved, as the mastoid cells as not yet formed.

The periosteum over the squamous portion of the temporal bone is more easily separated (Macewen) than over the mastoid process. In consequence the pus passes upward and causes the outward bulging of the upper portion of the auricle.

Chronic otitis media suppurativa predisposes to the formation of the abscess. A low stage of vitality is also usually present. It usually occurs in children, hence the movements of the bony plates.

Treatment.—In acute cases it is often only necessary to make a free incision through the skin and periosteum covering the mastoid process and evacuate the purulent accumulation. As the abscess is of otitic origin, it may in some cases be necessary to perform a mastoid operation either at the time of the incision or subsequently. In chronic subperiosteal abscess the simple incision (Wilde's) may not effect a cure, as the ear disease is well established and may require an operation.

CHRONIC MASTOIDITIS.

Symptoms and Diagnosis.—Chronic mastoiditis is not necessarily characterized by any special symptom other than those present in chronic suppurative otitis media. Mastoid pain and tenderness are often absent. Indeed, all focal symptoms are usually absent. The mastoid bone often undergoes an eburnizing sclerosis in the course of the disease, the cortex becoming quite dense and the cells replaced by the dense bone. It is not unusual to find the mastoid process with but a few small cells, while the remainder of the process is as hard as ivory. In this case the antrum may be smaller than normal. With such dense bony substance on the external aspect of the mastoid process acute or pressure symptoms are not present. The cranial aspect of the mastoid process does not always undergo the sclerosing process, and in these cases mastoid tenderness and swelling may be present. Intracranial complications, as sinus thrombosis, meningitis, brain abscess, etc., may be the first focal symptoms to develop. A neuralgic pain often accompanies the osteosclerosis of the mastoid process. Schwartze recommends the removal of a wedge of bone from the mastoid process for the relief of the pain of osteosclerosis.

The inspection of the drumhead and the middle-ear cavity often affords useful information as to the diagnosis. The drumhead is usually almost or entirely destroyed. Usually the short process and the head of the malleus are present, while the handle is gone. The incus is often entirely destroyed, though it may be present in the more recent cases. A fetid purulent secretion fills the meatus and the middle-ear cavity. When this is removed and suction is applied with the Siegle otoscope, the secretion may be seen trickling from the attic into the antrum. An evidence of mastoid involvement is to be found in the presence of a fetid odor after the middle-ear cavity is thoroughly cleansed; that is, the foul pus continues to enter the antrum from the inaccessible attic and antrum, thus perpetuating the odor.

Another evidence of chronic mastoiditis is the necrosis and absence of the incus. In discussing perforations of the eardrum I pointed out the significance of a marginal perforation in the postsuperior quadrant of the eardrum and the associated necrosis of the incus, signs of disease in the antrum. The increased quantity of purulent secretion is also a sign of mastoid involvement, although such an involvement may be present with scanty discharge. Indeed, Macewen calls attention to the fact that in many cases of mastoid disease the discharge is so slight as to escape attention. In some of the cases granulations or polypi are the only evidence of mastoid disease. The polyp, when examined with a delicate curved probe, may be traced to the attic for its attachment. Polypi generally signify bone necrosis. If, after cleansing the antrum of all secretions, suction is applied through the Siegle otoscope, and pus is seen to trickle down one of the fragments of the ossicles, attic and antral involvement may be safely inferred. Indeed, the presence of persistent

purulent discharge unchecked by local treatment is fairly good evidence of chronic mastoiditis. Macewen also called attention to the fact that chronic suppuration of the middle ear extending over a period of two or more years was usually attended by necrosis. Neuralgic pains in the mastoid region occur in those cases attended by eburnizing osteosclerosis of the mastoid process. In those cases in which acute exacerbations occur there may be headache, especially at night. The mastoid skin may be slightly red, swollen, and hot. The temperature rises one or two degrees above normal. The meatus is slightly swollen and hyperemic and the postsuperior portion near the eardrum is tense and swollen, or distinctly bulging. A cessation or diminution of the discharge is attended by pain, and signifies an obstruction to the discharge.

The course of the disease varies greatly in different cases. In some it runs a long and uneventful course without distinct symptoms other than the intermittent discharge. In others acute exacerbations occur every few weeks or months with the acute symptoms described in the preceding paragraphs, whilst in others the discharge is so slight as to escape attention unless the attic of the tympanum is explored with a probe. Either of these types may develop one or more of the intracranial complications and become a very serious disease.

Caries and necrosis of the mastoid process is a frequent result of the retention of the purulent secretion. Most cases of two or more years' duration are thus affected. Such destruction may take place without marked symptoms. The insidious progress of the disease makes it a formidable process. As Macewen has so well said, one with a chronic otorrhea is likened unto one with a charge of dynamite in the head: he does not know when it will explode. Safety lies in removing the "charge" or diseased process. Tuberculous patients are especially subject to caries and necrosis, and do not heal so readily after operation. I recall one case on whom I performed a radical operation, and it was six weeks before I could remove her from the hospital. I subsequently did a secondary operation, and it was six weeks before I could remove her to her home. At the second operation I applied Thiersch grafts with success, the entire cavity now being covered by epidermis.

In caries and necrosis careful examination will generally develop tenderness upon pressure, as the periosteum is apt to be swollen and inflamed. If in such cases the temperature is recorded every four hours, it will be found to be raised. In severe cases paralysis of the facial nerve may be present. A bony sequestrum sometimes becomes separated and may be removed through the meatus.

Prognosis.—The prognosis varies with the focal centre of the disease, the extent of the necrosis, and the presence or absence of intracranial involvement. When there is free drainage and only superficial involvement of the mucous membrane, the disease is not essentially a serious one. When extensive necrosis is present, serious intracranial complications are present, and the danger to life is imminent. Chronic sepsis, as evidenced by the yellow pasty skin and an increased leukocytosis, while not serious, undermines the general health and paves the way for the development of

other serious diseases. According to T. Mark Hovell, attacks of partial or complete unconsciousness, restlessness, and feverishness are always of grave import when occurring in a person suffering from disease of the mastoid process.

Treatment.—The local medical treatment of chronic mastoiditis is the same as that given for chronic suppurative otitis media (pp. 723 to 727). When this has been tried for a few weeks without effecting a cure of the disease, the mastoid antrum and cells and the middle ear may be opened, as the object of this mode of treatment is to (*a*) establish free drainage, and (*b*) remove the morbid material.

General Indications for the Mastoid Operations.—There are practically but three general types of mastoid operation now practised: one, the simple mastoid operation for acute mastoiditis, wherein only the mastoid antrum and cells are opened; another, the radical mastoid operation for subacute and chronic mastoiditis, wherein the mastoid antrum and cells and the middle ear are thrown into one large irregular, but freely communicating cavity; the other the meatomastoid operation, which may sometimes be used instead of the radical operation. The indications for the mastoid operations are in general those phenomena present in a persistent otorrhea which do not yield to local treatment (including the associated nasal and throat diseases) or to operation through the external auditory meatus. The more specific indications are as follows:

1. Persistent tenderness over the mastoid process, with or without copious ear discharge.
2. Persistent ear discharge and polypi.
3. Fistulous opening into the roof or postsuperior wall of the external auditory meatus.
4. Caries of the attic, as shown by probing or by bone dust in the ear washings.
5. Facial paralysis.
6. Labyrinthine involvement, as shown by dizziness, nausea, and profound deafness.
7. Chronic ear discharge with neuralgic pain over the mastoid process.
8. Chronic ear discharge and septicemia.
9. Intracranial complications and a history of chronic otorrhea.

These and other signs may indicate the same type of mastoid operation. Indeed, in view of the fact that life insurance companies refuse to insure persons affected by chronic otorrhea the otorrhea alone may be a positive indication for the radical operation.

CHAPTER XLV.

PRINCIPLES OF TREATMENT AND GENERAL CONSIDERATIONS IN SUPPURATIVE OTITIS MEDIA.

THERE are four cardinal principles to be considered in the treatment of suppurative inflammations of the middle ear and mastoid cells, namely: (1) The promotion of the reaction of inflammation to aid Nature in combating the host of invading pathogenic microörganisms; (2) the establishment of free drainage and the reduction of pressure; (3) the removal of the morbid material; and (4) the maintenance of asepsis while repair is taking place.

1. **The Promotion of the Reaction of Inflammation.**—As shown in Chapter VI, on Inflammation, the reaction of inflammation is a beneficent process, the object of which is to combat the infectious microorganisms. The reaction of inflammation is a threefold process, namely: (*a*) Increased hyperemia, (*b*) increased nutrition, and (*c*) increased leukocytosis of the affected tissues.

The increased hyperemia floods the cells of the tissues with nutrition and thus raises their resistance. The increased migration of leukocytes into the tissues provides a fighting force which destroys the pathogenic bacteria and disposes of the dead cells of the tissues. As the reaction of inflammation is usually inadequate to successfully and quickly destroy the pathogenic bacteria, the therapeutic indications are to adopt measures which will increase, or promote, the reaction of inflammation. Various modalities may be used for this purpose, some of which are, for anatomical and physiological reasons, especially well adapted to the treatment of the ear. (See Chapter VII.)

As stated in the chapter on Inflammation, heat, irrigation with alkaline solutions, incisions, leeching, massage, and radiant energy may be used to promote the reaction of inflammation.

Heat has long been used in the treatment of inflammation. Every one has observed the increased redness of the skin under its influence. The hyperemia thus produced increases the nutrition, and it is now believed increases the migration of leukocytes into the tissues.

There are differences in heat, as there are differences in silk and calico. Heat is produced by a wide range of vibrations. Some wave-lengths of wide amplitude and slow vibration produce heat of slight penetrating power. Other wave-lengths of short amplitude and rapid vibration produce heat of high penetrating power. The shorter the wave-length and the more rapid the vibrations, the higher the penetrating power. Heat from a hot-water bag or low candle-power incandescent lamp is of long wave-length and slow vibration, and is of slight pene-

trating power. Heat from a 500 candle-power incandescent lamp is of short wave-length and rapid vibration, and is of high penetrating power. The therapeutic value of heat is proportionate to its penetrating power. In selecting the modality for the application of heat these principles should be borne in mind. If the inflammation is superficial, a hot-water bottle or a low candle-power (16 to 100) lamp may be used, though a higher candle-power lamp will produce better results. If the inflammation is deep seated, a high candle-power incandescent lamp (300 to 500 candle-power) or an arc light should be used (Fig. 19).

Radiant light as given by the leukodescent lamp (Fig. 19) is a remedy of some value in suppurative otitis media. It not only gives off heat of high penetrating power, but it gives off rays possessing high degrees of chemical activity. The spectrum of the leukodescent lamp is rich in the blue violet rays which effect chemical changes in the tissues exposed to them. The leukodescent lamp is, therefore, a mechanical device furnishing two powerful therapeutic agents, namely, heat with high penetrating power, and blue violet rays of chemical activity. I do not believe, however, that the leukodescent light is as good a remedy in acute suppurative otitis media as incision of the membrana tympani and leeching. The progress of the disease is so rapid, and the structures of such vital physiological importance, that it is imperative that immediate improvement be obtained. Incision of the membrana tympani and leeching should, therefore, be used in the early stage of acute otitis media.

As the middle ear and mastoid cells are deeply located, heat of high penetrating power should be used to promote the reaction of inflammation. If the external auditory meatus is utilized, heat of low penetrating power, as irrigation with hot sterile or alkaline water, may be used, the heat being brought in direct contact with the inflamed tissues through the membrana tympani. Clinical experience has shown hot irrigations through the auditory meatus to be of considerable value in acute catarrhal otitis media (G. P. Head) and in the early stage of suppurative otitis media. After the formation of pus and after perforation of the membrana tympani it is of comparatively little value. Heat should therefore be reserved for the early presuppurative and preperforative stage of acute suppurative otitis media.

Irrigation with alkaline solutions but slightly increases the hyperemia and leukocytes, and is, therefore, of but little value in the treatment of suppurative otitis media.

Incision of the inflamed tissue has long been a therapeutic measure of acknowledged efficacy. In the treatment of acute catarrhal and preperforative stage of suppurative otitis media, incision of the membrana tympani is one of the most efficient modes of treatment. The good effects following incision of the membrana tympani are not altogether due to the increased hyperemia and leukocytes, though this influence is greater than is generally believed. In addition to the increased reaction of inflammation, the incision of the membrana tympani establishes free drainage and permits of the removal of the morbid material.

Incision of the membrana tympani is an almost ideal therapeutic measure in the early or preperforative stage of acute suppurative otitis media, though it is of little value in the later stages of the disease; nor has it any considerable value in the chronic type of the disease. Indeed, but little can be done by promoting the reaction of inflammation in chronic suppurative otitis media. In such cases the establishment of free drainage and the total removal of the morbid material should be accomplished. The incision of the membrana tympani should be long and curved, or V-shaped, to permit the secretions to flow through it.

Leeching is another old and all but discarded remedy in the treatment of acute inflammation. In my hands it has proved one of the most satisfactory methods of combating acute catarrhal and suppurative otitis media. It is my practice to apply from three to five leeches over the mastoid process and one to the tragus in front of the ear. If applied in the preperforative stage, or when the mastoid is swollen and tender, or when pain is present, the improvement is usually prompt and marked. Indeed, the case often proceeds to rapid resolution.

Leeching increases the hyperemia and the migration of leukocytes into the inflamed tissues, and thus favors the destruction of the pathogenic bacteria and the repair of the tissues.

Artificial leeching is, perhaps, of equal value, and is easier of application. The skin over the mastoid process should be incised, as shown in Fig. 370, the circular knife being adjusted with a set screw so as to cut the desired depth. When the incision is made the exhaust pump should be applied, as shown in Fig. 371, and the air exhausted by turning the hand screw. An ounce of blood may thus be drawn from the inflamed tissues. The effect of this procedure is to overcome the venous stasis and edema, and thus establish a more rapid arterial flow of blood through the tissues. The nutrition of the tissues is raised and the migration of leukocytes is increased.

Massage is of little value in promoting the reaction of inflammation in otitis media. External mechanical vibratory massage under the angle of the jaw over the course of the Eustachian tube will often quickly relieve the edematous obstruction to the Eustachian tube in tubal catarrh.

In the acute and chronic stages of suppurative otitis media the leukodescent light may be applied with some advantage, though other methods of treatment should also be used.

2. **Establishing Free Drainage.**—The second principle of treatment, the establishment of free drainage, is a very important part of the treatment of suppurative otitis media. If free drainage is maintained, infection rarely persists, whereas if the drainage is blocked, infection is apt to occur, or, if present, to persist.

In the early stage of acute otitis media free drainage may be established by incising the membrana tympani. The Eustachian tube is, for the time, inadequate to carry away the excess of secretions. A free incision of the membrana tympani, as shown in Fig. 359, affords an accessory outlet for the secretions, and, in addition, it promotes the reaction of imflammation and relieves the pressure and attending necrosis.

If the obstruction is in the aditus ad antrum, incision of the membrana tympani may not establish free drainage; indeed, it may be necessary to perform a mastoid operation in order to do it. In some cases of chronic otorrhea the obstruction is at the floor of the attic, which is formed by the heads of the malleus and incus, together with the ligamentous bands and adventitious cicatricial tissue resulting from the inflammatory process. In such cases the removal of the malleus and incus would establish free drainage. Heath claims that the Eustachian tube is usually adequate to drain the tympanic cavity, even when diseased, but that it is inadequate to also drain the diseased mastoid antrum and cells. He therefore recommends that the secretions from the antrum and mastoid cells be diverted from the aditus ad antrum to the external auditory meatus, as described in the meatomastoid operation.

3. **Removal of Morbid Material.**—Whatever method of treatment is adopted, earnest effort should be made to remove all obstruction to the flow of secretions from the tympanic cavity. In infants and children the removal of the adenoids may accomplish the purpose by unblocking the Eustachian tubes. The removal of aural polypi or granulations may temporarily establish drainage. Incision of the membrana tympani, leeching, hot irrigations, dry heat, etc., may act favorably in establishing drainage. In many cases it will be necessary to resort to a mastoid operation.

4. **Maintaining Asepsis.**—Having promoted the reaction of inflammation, established free drainage and the removal of the pressure, and having removed the morbid material from the diseased ear or mastoid cells, there remains but little to do to maintain the parts surgically clean. Gauze dressings applied to the auditory meatus or to the mastoid wound is all that is necessary for this purpose. Extraneous infection is thus prevented while the reparative process is in progress.

THE TREATMENT OF CHRONIC SUPPURATIVE OTITIS MEDIA AND MASTOIDITIS.

The consideration of this subject will not be divided into medicinal and surgical treatment, as is usually done, but will be considered according to the *predominance of the type and location of the morbid process.*

Suppuration of the atrium (lower chamber of the middle ear), perhaps, does not exist alone, but is usually associated with the same type of inflammation in the attic, antrum, and mastoid cells. The focal centre of the process may, however, be located in the middle ear, and the case can be successfully treated *via* the auditory meatus.

The dry gauze treatment should be carried out as described under Acute Suppuration of the Atrium. In chronic cases the perforation in the drumhead is usually quite large, sometimes involving the entire membrane. It is not, therefore, usually necessary to enlarge the perforation or incise the drumhead. The gauze wick should be introduced into the cavity of the middle ear, and the meatus loosely packed with

it. It is usually sufficient to apply the gauze every alternate day, although it may be necessary to do it oftener.

The Alcohol Treatment.—This does not differ materially from that already given under Acute Suppuration of the Atrium (p. 715). It should be preceded, however, by thoroughly cleansing the secretions from the meatus by cotton-wound applicators and by inflation of the middle ear with the Eustachian catheter.

The *alcohol* should be left in the middle ear for from five to twenty minutes, the patient inclining the head to one side. The alcohol should vary in strength (25 to 95 per cent.) according to the pain produced by its introduction. Some cases tolerate the 95 per cent. solution from the start, while others will complain of pain if a greater strength than 25 per cent. is used. In such cases begin with the weaker solution, and then instil a stronger and still stronger until the full strength solution is tolerated.

In the interims between treatments the ear may be left without special protection other than a loose piece of absorbent cotton or sterilized gauze in the external meatus.

The treatments may be repeated on alternate days, or as often as indicated.

Some writers advocate the addition of boric acid to the alcohol, while others use an etheric-alcohol solution of iodoform.

Alcohol acts as a hygroscopic agent, thereby depleting the edematous membrane and granulation tissue. It is an antiseptic and astringent, and it excites the reaction of inflammation.

The Compound Tincture of Benzoin.—During the last ten years I have used the compound tincture of benzoin in nearly every case of otorrhea coming under my care. It has steadily grown in my estimation with each passing year. Its efficacy is in part due to the alcohol in its composition, but not altogether to it. It is more soothing than plain alcohol, and it is more antiseptic and more healing. I have found it to be of special value in those cases in which the fetid odor is present. This speedily disappears and the other features of the case also improve.

The compound tincture of benzoin should be dropped into the meatus, the head being inclined toward the opposite side. If the discharge is not too profuse the gauze may be allowed to remain in the ear and meatus for two or three days without developing fetor.

The middle ear should be previously cleansed as described above, although this may not be necessary after a few applications of the remedy, as the discharge often rapidly decreases until there is scarcely a drop on the gauze when removed.

I do not wish to be understood as claiming that the otorrhea will not return after the discontinuance of the benzoin, for I believe it will in most cases, no matter what form of local treatment is pursued.

Irrigation.—*The use of the syringe* is not indicated, as it is in acute cases. It may be used to advantage, however, when there is a considerable accumulation of desiccated or tenacious mucous and pus in the *atrium* of the middle ear. The force of the stream loosens and propels

the secretions from the middle ear, and thus prepares the tissues for treatment by other methods. Sterile water or normal salt solution should be used as hot as can be comfortably borne by the patient, one-half gallon being the correct amount for each treatment.

The Boric Acid Treatment.—This method of treatment is of less value in chronic than in the acute inflammations of the middle ear. If the discharge is profuse it may be used, although other measures afford more relief.

Camphoroxol has recently been highly recommended by Hotz and others in obstinate otorrhea in which other methods of treatment had failed. Hotz reports several cases in which the remedy seemed to give speedy and satisfactory relief. Further observations along this line are needed, however, before the real value of this remedy can be estimated.

THE TREATMENT OF SUPPURATION INVOLVING THE ATRIUM AND ATTIC.

Under this caption are included those cases in which the centre chiefly involved, or which forms the chief source of annoyance and danger, is the attic. The consideration of the best methods of treatment will, therefore, hinge upon the structure and arrangement of the parts composing the attic.

The point of chief interest is the lower boundary or floor of the attic, namely, the heads of the malleus and incus, and the ligaments and adventitious fibrous bands uniting them to the walls of the tympanum. Another point of clinical interest is Shrapnell's membrane, or the membrana flaccida. Perforation of this membrane affords one of the most obvious signs of attic suppuration. Irrigation of the attic may be accomplished with a curved cannula inserted through the perforation in Shrapnell's membrane (Fig. 382), and local medication and explorations may be carried on through it.

The floor of the attic is of importance because, whereas in health it affords ample drainage for the secretions, it is oftentimes inadequate in chronic otorrhea. The inadequacy may be due to the excessive and heavy secretions, or to a more or less complete obstruction by the adventitious fibrous tissue of the spaces in the floor of the attic. At any rate the secretions are pent up in the attic and may give rise to serious pathological changes.

While the principles of treatment remain the same, the motive for treatment increases tenfold.

Free drainage is imperative and should be established by surgical interference. The perforation may be enlarged by an incision extending anteriorly and posteriorly. The treatment should be addressed not alone to the attic, but to the atrium also. In other words, the treatment described in the preceding section should be used, and in addition thereto the following measures should be instituted:

THE TREATMENT OF SUPPURATION OF THE MIDDLE EAR AND MASTOID PROCESS.

Treatment of Suppuration of the Atrium.—Although it cannot be correctly said that infection is ever limited to the *atrium* (lower chamber of the middle ear), it is nevertheless expedient to treat some cases as though they were thus restricted. They are probably only mildly infected, and in reality involve the whole tympanum (atrium and attic and mastoid spaces). But as the area of infection is limited, simple measures often suffice to effect a cure. While the whole tympanum and mastoid spaces may be somewhat involved, the focal centre of infection is in the *atrium*, or lower chamber of the middle ear. As this chamber is easily accessible through the external auditory meatus and through the Eustachian tube, the four principles of treatment (p. 740) may be effectively carried out.

In acute cases the perforation is usually small, and should be enlarged by free incision of the drumhead (Fig. 373). An unwarranted dread or fear exists among a large percentage of those practising medicine as to paracentesis or incision of the drumhead. Such fear is ill-founded, as experience has shown that such injuries are quickly repaired without the intervention of the one causing it. Indeed, the wound usually closes too quickly. However this may be, the first cardinal principle is to establish *free drainage* as quickly as possible. This can be done most easily by enlarging the already existing perforation. The incision should be curvilinear, so as to create a flap of the membrane on one side of the perforation (Fig. 373). The pus escapes through an opening as large as the perforation plus the space occupied by the flap. Through this opening the atrium can be freed from morbid material and kept aseptic by gauze drainage. Having thus established (*a*) free drainage, (*b*) asepsis, (*c*) freedom from morbid material, and the reactions of inflammation, resolution may be expected. The difficulty in most cases treated is that the attending physician does not make it possible to accomplish the four cardinal principles of treatment. He trusts to hydrozone, boric acid solutions or powder, alcohol, and other remedies to do what they cannot, except free drainage is first established.

Method of Incising the Drumhead.—(*a*) First, remember that the drumhead is within 3 to 4 mm. of the inner tympanic or labyrinthine wall. It is important, therefore, that the knife used should not penetrate the drumhead deeper than 1 to 2 mm., as the inner wall may be injured thereby. There could be no special harm in incising the mucous membrane of the inner wall, but the oval and round windows are located there, and to disturb their contents would expose the labyrinth to the dangers of infection. This is mentioned because the knowledge of it will prevent careless or reckless incisions of the drumhead. I will say, however, that such accidents rarely occur, even at the hands of an inexperienced surgeon.

(*b*) The best instrument for the purpose is Hartman's curved bistoury

(Fig. 355). It is pointed and the cutting edge is concave, thus favoring the retention of the blade within the membrane as the incision is made. If it were convex on its cutting surface, it would have a tendency to slide out of the membrane as the incision is made.

Paracentesis (simple puncture) should not be practised, as the opening thus made is entirely inadequate for the purposes heretofore described under Principles of Treatment.

(*c*) The incisions should begin at the centre (regarding the existing perforation as the centre), and should radiate in the direction affording the largest field of drum membrane. The flap thus formed between these radiating incisions will be somewhat triangular in shape, with the apex toward the perforation and the base (usually) toward the periphery of the drumhead.

(*d*) Where it is not easy or feasible to make the incisions as described above, it should be done as follows: Select the largest available field of the drumhead and begin the incision near the periphery, and extend it in a curve or crescentic line toward the opposite side of the chosen field. The curved or crescentic incision allows the flap to open out as a valve and permits free drainage and cleansing of the atrium.

The Removal of the Morbid Material.—Having made an opening in the drumhead sufficiently large to allow free drainage, the next step is to remove the morbid material. This is accomplished in a variety of ways, among them being the use of the syringe.

The use of the syringe in otitis media has been so much abused, or, rather, the patient has been so much abused by its use, that I hesitate to recommend it. I shall do so only with specific directions as to how it should be used. When so used, it is, under proper circumstances, a very valuable mode of treatment.

How to Use the Ear Syringe.—(*a*) *Select a syringe* that is aseptic and that will throw a fair-sized steady stream. Dr. Todd has devised one that meets these requirements. It is operated by means of a bulb, and is so constructed that it can easily be rendered aseptic. Nearly all the ear syringes on the market are hotbeds of microbic propagation, and their use in the middle ear is attended by considerable risk.

(*b*) *Use large quantities* of sterile (boiled) water or other fluid. It is the quantity I wish to emphasize, rather than the kind of solution used. A little water or aqueous solution of some antiseptic material may be very harmful in such cases. If one begins to "wash" a septic mucous membrane, it should be very thoroughly done. Experience has taught us that only by using large quantities of solution can good results be obtained in otorrhea. Small, meagre flushings often aggravate the condition.

(*c*) After quantity I will name *temperature* as the element of next importance in syringing the middle ear. The solution should be slightly above blood heat, 105° being best suited for the purpose. The temperature should be subject to variation, however, according to the syringe used. If a fountain syringe is used, the solution will cool several degrees in passing through the long tube. The solution should be

so tempered that when it reaches the ear it is about the temperature of the blood, or a little above rather than below it.

(*d*) *The solution used* may be what is known as the "normal salt solution." A formula which is correct enough for the purpose is: One teaspoonful of table salt to each quart of water. Warm boric acid (saturated) solution is a favorite remedy with some, while others prefer bichloride of mercury (1 to 5000 or 1 to 2000).

Still other solutions may be used (as carbolic acid), although it is doubtful if any of the antiseptic solutions excel the normal salt solution. The chief value of the procedure, as I view it, is to "wash" the infected membrane. Plain water is known to irritate mucous membranes, hence the addition of the salt brings it to about the specific gravity and alkalinity of the blood, thereby overcoming the irritating quality of the water.

The antiseptics as used really exert no microbe-killing or inhibiting power other than that due to the removal of the "soil" in which the microbes are embedded.

(*e*) The *frequency* with which these flushings may be used will depend upon the quantity of the discharge and the virulency of the infection. If after cleansing the ear in this way (with the other treatments, as described) the ear remains comparatively free from morbid material for twenty-four to forty-eight hours, there is no occasion for using it sooner. The frequency will, therefore, depend upon the length of time the ear remains "clean." If the discharge forms rapidly, it may be necessary to use the douche oftener.

(*f*) After having thoroughly syringed the ear, the moisture should be removed by the use of a cotton-wound probe. In some cases, alcohol (50 to 95 per cent. strength) may be used with advantage for its hygroscopic property. Its affinity for water is so great that it will abstract it from the swollen and edematous tissue. I have found it to be irritating in some cases, especially those very acutely inflamed. It should, therefore, be used in weak solution, or not at all, in acute cases.

(*g*) The middle-ear cavity and external meatus should now be loosely packed with sterile gauze, which acts as a wick, removing the secretions as fast as they are formed. Amberg has had gauze strips one-half an inch wide and six inches long put up in oiled paper and sealed packages for this purpose. The idea is an excellent one, as the strip is handled only at the time of its use.

(*h*) If the discharge is very profuse, a pad of gauze should be placed in the concha and held in place by a collodion dressing (Fig. 420).

(*i*) The hands, instruments, etc., should be cleaned as for an operation, as otherwise infection may he added to that already existing.

The Dry Gauze Treatment.—Spencer first advocated the use of dry gauze in the treatment of middle-ear suppuration in 1880–82. Since then Gradinego and Pierce have advocated its use. The special points in its use may be tabulated as follows:

(*a*) First, remove all the secretions from the middle ear and meatus with cotton-wound probes. (It is here presumed that if the perforation

in the drumhead is not large enough to allow free drainage, it has been incised, as heretofore described.) The parts may be also treated by instillations of alcohol in 50 to 95 per cent. aqueous solution. This, in turn, should be wiped out. Alcohol not only acts as a hygroscopic agent, but is astringent and antiseptic as well.

(*b*) The meatus should be loosely packed with a strip of gauze about one-half inch wide and three inches long. For this purpose a small silver probe, with two notches filed at right angles across its end (Fig. 318), as suggested by Bane, should be used. The notches form four shallow teeth, which catch in the meshes of the gauze and carry it to the desired location. The end of the strip should be placed against the opening in the membrana tympani, so that the secretions will be taken up at once and carried outward through the gauze in the meatus.

The gauze may be covered with a small piece of absorbent cotton and sealed with an ether solution of collodion (Fig. 420).

(*c*) The dressing should be left in position for from twelve to seventy-two hours, according to the amount of discharge. It should then be removed and the same procedure repeated until improvement or complete relief is afforded. Not every case will yield to this mode of treatment, nevertheless many will do so.

The Alcohol Treatment.—This mode of treatment also has its advocates, and for good reasons. I recall an incident which gave me great confidence in its efficacy. At that time I had 10 cases of *chronic otorrhea* under my care, all of which were being treated by the dry gauze method. Improvement was slow, and I determined to change to the *alcohol treatment*. In about one week the otorrhea ceased in eight cases. Subsequent experience has not upheld the good opinion formed at this time. Nevertheless, this mode of treatment is a good adjunct to the dry gauze treatment.

Many acute cases do not tolerate alcohol well, violent pain and inflammatory edema often being excited by its use.

Boric Acid Powder Treatment.—This mode of treatment is quite old, and therefore merits attention. The fact that it has remained in use so long argues that there is probably some merit in it. It is true that remedies are now used in its stead which give better results. The question arises, however, as to whether the improved results are due so much to the newer remedies as to the *manner* in which they are used. The boric acid powder treatment fell into disuse about the time modern surgery was adopted by the profession. Hence, the newer remedies have been used with antiseptic and aseptic precautions. For example, so much care was not formerly exercised to thoroughly drain and clear the middle-ear cavity of morbid material, nor was it attempted to render it aseptic. The superficial pus and debris were removed and the boric acid powder (usually a very impure preparation) was poured into the external meatus and packed tightly. Hence, I believe boric acid fell into disrepute as a remedy in otorrhea, not because it is an inefficient remedy, but because it was used in an improper manner or under improper conditions.

Boric acid should be used as follows:

(*a*) Secure a chemically pure boric acid *powder* (Merck's) or *flour*. The impure preparations contain the biborate of soda, which cakes in the ear and causes obstruction to the drainage. It is also acid, and irritates the mucosa. Pure boric acid is neutral, and will not "cake" or irritate the tissues.

(*b*) The best way to use it is with a powder blower (Fig. 21). The powder should be blown into the external meatus and middle ear with low air pressure. If a high pressure is used the whirlwind created in the meatus will blow the powder out again. In this way a thin layer of powder is introduced into the diseased ear, where it acts as an absorbent and antiseptic. It dissolves slowly, and its action is prolonged for some time. It will not "clog" or obstruct the drainage.

(*c*) The meatus should be loosely packed with a strip of gauze.

(*d*) The treatments should be repeated as often as the powder becomes wet with the secretion.

(*e*) Previous to introducing the powdered boric acid, the middle ear and meatus should be cleansed with cotton mops.

(*f*) This treatment is especially useful in those cases in which there is a *profuse acrid discharge* and the *perforation is large*.

Eczema and *dermatitis* of the external auditory canal and auricle are often present in otorrhea. They are due to the irritation of the aural discharge. The application of the following ointment has proved very satisfactory:

℞—Zinc oxide . . . . . ʒi
Morphine acetate . . . . . gr. j
Lanolin,
Vaseline . . . . . āā q. s. ad ℥j.—M.
Ft. unguent.

Sig.—Apply once or twice daily to the inflamed auricle and meatus with a cotton-wound probe or applicator.

The alcohol treatment is not well tolerated by these cases, the boric acid and gauze treatments being better.

Pain in the ear should cause the attending physician to carefully investigate its cause. It may be due to insufficient drainage through the perforated drumhead, in which event it should be incised as heretofore described; or it may be due to an obstruction (Sheppard) in the *aditus ad antrum*. The mucosa may be swollen in the canal, or granulations may have formed and occluded its lumen. This would interfere with the discharge of the pus from the antrum and mastoid cells into the attic of the ear. The pain is the expression of retention pressure, and steps should be instituted to unblock the occluded passages. As I have already pointed out, the obstruction is probably in the aditus ad antrum, the floor of the attic, or in the drumhead. If the floor of the attic is the seat of the obstruction, it may become necessary to remove the malleus and incus. Sheppard reports his results in 31 cases, and finds that the removal of the malleus alone is not usually followed by good results. (See Ossiculectomy.) If the obstruction is at the drumhead, it will bulge outward, the perforation being either small or blocked with granulations. The drumhead should be incised and the granulation tissue removed.

To remove the granulations it may be necessary to enlarge the perforation in the drumhead by incisions radiating from the perforation. Through this opening the granulations can be still further examined and removed, either with a snare (Fig. 379) or with a small spoon curette. *Local anesthesia* may be induced with cocaine (10 to 20 per cent.), or with the following mixture:

℞—Cocaine crystals,
Carbolic acid crystals,
Menthol crystals . . . . . āā ʒj—M.
Mix by rubbing in a mortar, and a syrupy fluid is formed.

The above solution, when dropped into the meatus, will produce local anesthesia when cocaine fails to do so.

Fig. 379

Showing the removal of an aural polyp which projects into the meatus through a perforation in the membrana tympani.

If the *obstruction is in the aditus* the problem becomes at once more difficult and serious. It is practically impossible to reach the canal through the external auditory meatus without resorting to a mastoid operation. If the malleus and incus are removed, the obstruction may gradually disappear without the mastoid operation. The advantage to be gained by doing the mastoid operation is that the disintegration which occurs with such rapidity under retention pressure is checked before serious and extended destruction of the tissue takes place, and the danger of meningeal and cranial involvement is thereby reduced to the minimum.

If the *pain* is associated with *bulging and redness* of the postsuperior wall of the meatus near the drumhead, the indications for immediate operation are imperative. If the bulging and redness are not present, other treatment may be tried. In the meantime close observation of the case should be maintained. A rapid rise in temperature, with chills or chilliness and profuse sweating, strongly indicates septic poisoning, possibly from sinus thrombosis.

CHAPTER XLVI.

THE GENERAL PATHOLOGY OF OTITIS MEDIA AND MASTOIDITIS.

MICROÖRGANISMS are the exciting causes of middle ear and intracranial pyogenic processes. Various organisms are active, either alone or in combination, no special one being characteristic of these processes.

The *free communication* between the epipharynx and middle ear and the perforated drumhead makes infection easy if the local conditions are favorable. The vitality is lowered during the course of one of the exanthematous fevers, hence the conditions for infection of the middle ear are favorable. Pathological destruction and changes occur in the mucosa and drumhead, and microörganisms continue to flourish, the suppurative process being established. The *cilia* which normally partially cover the tympanic mucosa are destroyed, or their vitality is so impaired that their propelling function is no longer adequate to drive the secretions toward the Eustachian outlet. Accumulation, decomposition, and irritation follow. The mucosa breaks down, the periosteum covering the bone beneath loses its vitality and disintegrates, and the bone depending upon it for nutrition becomes necrotic. The arteries in the mucosa become thrombosed, and the arterial supply is thus cut off from the membrane and periosteum as well as from the bone. Thus the process of disintegration proceeds with greater or less activity, oftentimes without serious symptoms being present. The brain may be exposed by the caries of the tegmen tympani or through the various channels of communication. Finally, the conditions become such that acute reaction sets in, and life is placed in imminent danger.

It has been said that about two years of chronic suppuration usually precedes bone necrosis in the middle ear and its accessory cavities. This should be taken only as an approximate estimate, as the time varies with the type of the infection which predominates, and with the obstruction offered to the discharge of the morbid secretions. If the flow from the mastoid cells and antrum is free and unobstructed, the process may continue for years without bony necrosis. If, on the other hand, marked obstruction occurs quite early in the suppurative process, bone necrosis may take place before the two years have elapsed.

It is of great importance in estimating the gravity of a suppurative process in the tympanum to determine definitely the predominant character of the microbic infection that is present. To this end cultures and microscopic examinations should be made. While but few physicians are prepared to make either the cultures or microscopic examinations, nearly all know where they can secure culture tubes and have such

examinations made. The attending surgeon should smear the secretion from the ear on the contents of the culture tube and send it to a pathologist.

I will here suggest a few places where the above examinations may be made:

(*a*) The Health Board of your own or some neighboring city.

(*b*) A brother practitioner.

(*c*) The nearest medical college, or the one from which you graduated.

(*d*) A pathological laboratory established for the purpose of accommodating those in need of such work.

The expense of such an examination is small, and the information obtained may be of inestimable value to the patient.

John Funke has reported the results of his observations as to the "Bacteriology of Otitis Media," and his work seems so conclusive and suggestive that an epitome of it is herewith given:

"The following conclusions are based on a study of the literature of otitis media and my observations:

"1. There is no specific organism of otitis media.

"2. Acute otitis media is not invariably monomicrobic, as is commonly held. The pathogenic organism present may be of a single variety, but with it are frequently found a varying number of associated bacteria, which may or may not be influential in determining the outcome of the case.

"3. The organisms commonly found, in the order of frequency, are: The pneumococcus, streptococcus, pyogenic staphylococci (albus and aureus), and the bacillus of Friedlander. I am strongly inclined toward the belief in a definite grippal otitis, primarily due to the influenza bacillus, which, however, becomes quickly associated with, or replaced by, other organisms.

"4. The Bacillus diphtheriæ is more commonly present in otorrhea than is usually believed; it may be (*a*) the initial infecting agent, (*b*) or it may enter with the streptococcus or pneumococcus, or (*c*) it may be a secondary infection carried to the already infected ear by the fingers of the patient, or otherwise, as held by Baginsky.

"5. It is reasonable to believe, as my observations show, that it persists for a varying period of time in the discharges, and may constitute a centre of danger, just as has been thoroughly established concerning its prolonged residence in the nasal cavities, pharynx, etc. Its frequent association with the Bacillus pseudodiphtheriæ has here the same significance as elsewhere, a factor not as yet fully determined.

"6. The streptococcal infections are more grave and persist longer than pure pneumococcal infections, but both are usually supplanted by the staphylococcal sooner or later.

"7. There is a true pneumobacillary otitis, usually acute and quickly converted into a mixed infection. The gravity of the process depends almost exclusively upon the character of the mixed or secondary infection.

"8. Chronic suppurative otitis media is practically always a sequence of the acute.

"9. Like the acute, it possesses no specific organism.

"10. Unlike the acute, it is practically always polymicrobic.

"11. Its polymicrobic character may be evinced in any of three ways: (*a*) A mixed infection of pathogenic organisms; (*b*) one or more recognized pathogenic organism (usually pyogenic staphylococci), with one or more bacteria usually regarded as saprophytes; (*c*) the usual pyogenic and pathogenic bacteria are absent, and the discharges are maintained through the activity of organisms that commonly lead a saprophytic existence.

"12. While anaërobic organisms may play an important part in the pathogenesis of chronic suppurative otitis media, my observations have not established their almost constant presence, as maintained by Rist.

"13. The fetor met in the cases here reported can be explained by the presence of Bacillus pyogenes fetidus without anaërobic organisms.

"14. All clinical and collated bacteriological data indicate that otitic inflammations present different bacteriological findings in different localities. According to Moos, during the influenza epidemic of 1890 in Vienna the otitic complications were due to the pneumococcus (Weichselbaum), and to the streptococcus in Strasburg, Greifswald, and Bonn (Ribbert).

"15. Reports gathered from literature establish the existence of a primary tuberculous otitis, but all observers are of one mind as to the almost utter impossibility of the routine demonstration of the bacillus in discharge.

"16. For the demonstration of the tubercle bacillus in suspected cases I would recommend an examination of tissue obtained by the curette."

Gradle and others, some years ago, called attention to the odor attending chronic otorrhea, claiming its presence or absence was the "most sensitive criterion of the efficacy of the treatment." He says:

"So long as the pus of the otorrhea smells fetid the treatment employed has exerted no curative influence on the disease; and, conversely,

"The first sign from any treatment of curative influence upon the course of an otorrhea is its effect upon the odor of the discharges."

Macewen says: "The virulence of a discharge cannot be measured by its odor. Nearly odorless otorrhea may contain pathogenic micrococci, and some of the most serious intracranial inflammatory lesions ensue in the presence of odorless otitis media. It is well, therefore, in estimating the gravity of an otorrhea that pus from the middle ear should be stained and examined microscopically and by cultivations."

He goes on to state that intracranial complications do often arise in the course of fetid otorrhea, but that the pathogenic germ is not the one causing the odor, it usually being a non-pathogenic microörganism.

These views, while they seem to be diametrically opposed to each other, are really not so opposite as they appear. The first is fallacious, in that it leads to the inference that with the disappearance of the odor the patient's condition becomes safe; whereas, the second view tells us

the absence of fetor is no criterion as to the non-virulence of the infection. Gradle's views lead, by inference, to the conclusion that absence of fetor is a guide to the mildness of the infection; whereas, Macewen says the absence of fetor gives no information whatever as to the virulence of the infection. He goes still farther and says some of the most virulent intracranial infections have occurred in connection with odorless otorrhea.

The author is inclined to agree with Macewen on this point, although he readily admits Gradle's major proposition, that the disappearance of the odor under the syringe, etc., usually heralds an improved drainage and ventilation. The improvement, however, is not due to the removal of the odor or the germs producing it, but to the removal of the saprophytic bacteria and the establishment of free drainage by the removal of the desiccated secretions. The disappearance of the odor is incidental, and signifies that other and more virulent organisms may have been removed also.

When the true nature of chronic otorrhea is explained to patients, many of them reply that they have had the discharge off and on for many years with no untoward result, and that they do not fear serious complications in the future. They express a belief that is often too prevalent among physicians, namely, that chronicity of otorrhea is a guarantee of its innocent nature. The process of disintegration has been going on, and may continue to do so, so long as the otorrhea lasts. Fresh invasions of germs, or the encroachment upon a new area, or a lowered vitality of the patient, may give rise to sudden and alarming symptoms.

It may be said that *the more chronic the otorrhea the greater the danger of intracranial or other extension of the infective process.*

Acute primary otitis media suppurativa rarely extends to the brain or meninges, as the process does not continue long enough to break down the mucous membrane, bone, and other tissues enveloping it.

In infants this protection is not so complete, as the various parts of the temporal bone are not yet united by ossification. The vascular and cartilaginous lines of union afford less resistance to the transmission of microörganisms to the cranial cavity; hence, intracranial involvement is more common in infants in the course of, or subsequent to, an acute primary suppurative otitis media.

In addition to the infection and consequent ulceration, thrombosis, and necrosis, there are other pathological conditions which are incidental to the suppurative process. *Adhesive bands* often form in the course of this disease, and the ossicles become bound to each other and to the tympanic walls. The handle of the malleus, being retracted, may become adherent to the promontory.

The writer has a case under observation, aged forty years, with adhesion of the handle of the malleus to the promontory. When a young child she had suppuration of the middle ear, following scarlet fever. There have been occasional discharges since then. When she came under my observation there was a *perforation of Shrapnell's membrane.* This healed under applications of the nitrate of silver. Examination with Siegle's otoscope shows the malleus to be adherent to the promon-

tory. The anterior half of the drumhead is also adherent in places, while the posterior half is perfectly free. In other cases the adhesions have been severed (Fig. 373), with great improvement of the hearing.

Calcareous salts may be deposited in the drumhead and in the tympanic mucosa. The articulations of the ossicles may become ankylosed. The foot plate of the stapes is sometimes ankylosed from the deposit of lime salts in the fibrous ring which unites it to the margin of the oval window (fenestra of vestibule). This condition may be mistaken for hyperostosis of the bony capsule of the labyrinth (spongifying), though in the latter condition the drumhead and Eustachian tube are normal, whereas in the former they are abnormal.

Granulations (aural polypi) are common, especially in old cases, in which the mucosa and periosteum are ulcerated and bony necrosis is present. They are the expression of Nature's effort to repair the tissues.

Middle-ear Suppuration.—Microscopic Examination of One Hundred Cases, with Special Reference to the Presence of Tubercle Bacilli and Acid-fast Bacilli.—Wyatt Wingrave[1] gives the following analysis: Special care was taken in obtaining the discharge. Carbol-fuchsin was used in staining, with methylene blue as a counterstain:

	Cases.
Squamous and pus cells present together in	41
Pus alone	38
Squamous alone	21

BACTERIA.

Staphylococci	41
Diplococci	20
Streptococci	7
Bacillus proteus vulgaris	14
Micrococcus tetragenus	4
Bacillus coli	3
Gonococci	33
Bacillus subtilis	2
Aspergillus niger	1
Leptothrix	1
Diphtheria (Klebs-Loeffler)	1
Yeast	1

[1] Jour. Laryngol., Rhinol., and Otol., March, 1903

CHAPTER XLVII.

INTRACRANIAL AND JUGULAR PYOGENIC DISEASES OF OTITIC ORIGIN.

General Considerations.—Infection and inflammation of the middle ear, mastoid cells, and labyrinth are not *per se* usually a serious menace to life. The real danger is in the extension of the infection to the contents of the cranium or to the jugular vein, and thence to the important viscera, or a general dissemination throughout the body (general septicemia). In more rare instances the infection may be conveyed to the distant viscera, as the lungs, spleen, liver, heart, and kidneys. Pneumonia, splenitis, hepatitis, endocarditis, and nephritis of otitic origin have been observed. The infection more often extends to the intracranial sinuses (veins) and to the jugular vein. Septicemia is also an occasional sequel of otitic and mastoid infection.

Of the intracranial pyogenic infections, thrombosis of the sigmoid portion of the lateral sinus, and the various types of meningitis, are most often observed. As the symptoms are not always characteristic of the type and field of invasion, the differential diagnosis is often difficult to make. There are, however, certain general characteristic phenomena, especially after the process is well advanced, which usually enable the aural surgeon to diagnosticate the condition present. When, for example, there is a chill, followed by a rapid and excessive rise of temperature, the evidence is conclusive that the system has been invaded by a numerous pyogenic host from some source. The most probable source of such an invasion is a disintegrating thrombus. The thrombus, being infected, finally undergoes disintegration, and the pathogenic bacteria are thrown in great numbers into the general circulation. As the sigmoid portion of the lateral sinus is in intimate anatomical relation to the mastoid process, the natural inference to be drawn from the chill and rapid rise of temperature is that lateral sinus thrombosis is present. If after the lapse of twenty-four hours a similar symptom complex recurs the diagnosis may be more surely made. The thrombus may, however, be in either the superior or the inferior petrosal sinuses, longitudinal, or the cavernous sinus. These sinuses are, however, usually involved secondarily to the lateral sinus. The symptoms of cavernous thrombosis are so characteristic, that, when involved, the diagnosis is easily made.

Diffused purulent meningitis also presents certain characteristic symptoms which render the diagnosis comparatively easy. The temperature remains more or less constantly elevated, whereas in thrombosis there are distinct chills followed by a sudden and marked rise in the

temperature, and a recession to nearly normal within six to ten hours. Extradural abscess and brain abscess may be attended by only a moderate, or no elevation of temperature, though there are frequent exceptions to this rule.

Lumbar Puncture.—Lumbar puncture for the diagnosis of meningitis should be made between the third and fourth lumbar vertebræ. A tapeline or cord passing around the body on a level with the crest of the iliæ passes over the spine of the fourth lumbar vertebra; the spine just above is the third lumbar vertebra, and at a point midway between the two spines is the location for making the puncture. The needle should be introduced at a point a little to one side of the median line.

In infants and young children a simple acute otitis media may give rise to symptoms simulating cerebral complications, as headache, nausea, vomiting, and excessive elevation of temperature (Gradle). If meningitis is suspected, the diagnosis may be cleared by making a lumbar puncture and subjecting the removed spinal fluid to microscopic examination. If purulent meningitis is present, the fluid is turbid and loaded with pus cells and pathogenic bacteria, especially streptococci. If the fluid escapes under high pressure, and is clear and contains only a few leukocytes and no demonstrable bacteria, serous meningitis is present, and a mastoid operation should effect a cure without resorting to an exposure of the cranial contents other than at the atrium of infection, the tegmen tympani or antri. Lumbar puncture is negative in reference to the other intracranial infections.

These and other clinical phenomena usually enable the aural surgeon to differentiate the various extensions of the infection from the ear and mastoid cells to the cranial cavity. In the following presentation of the intracranial and jugular infections only the more typical clinical phenomena will be given. (See Macewen's work on *The Pyogenic Diseases of the Brain and Spinal Cord.*)

MENINGITIS SEROSA.

This disease is of otitic orgin and is characterized by a serous infiltration of the pia mater and an increase in the cerebrospinal fluid in the subarachnoid space and in the ventricles of the brain.

Etiology.—(*a*) It is more often a complication of chronic otitis media and mastoiditis. (*b*) The channels of invasion may be through the tegmen tympani and antri, or through the labyrinth.

Symptoms.—Headache, dizziness, nausea, vomiting, restlessness, ataxia, torticollis, disturbances of vision, etc., are usually present, though not all of them at one time. The symptoms are not different from those in the suppurative form of meningitis, and it is, therefore, difficult to make a diagnosis before operation. If there is a spontaneous cessation of the meningeal symptoms, or if they cease after a mastoid operation, the disease is probably serous in character, the purulent forms rarely being thus favorably affected. Lumbar puncture is negative.

Quincke's puncture is of little value in the diagnosis, as there is likewise a pressure of the serous fluid in the purulent forms.

Treatment.—A radical mastoid operation and exposure of the dura mater at the tegmen tympani and antri should be performed to evacuate the extradural accumulation if present. The dura should be opened even if pus is not found. If serous fluid is discharged under high pressure and in a large quantity, and the meningeal symptoms rapidly disappear, the diagnosis of meningitis serosa may be confidently made.

EXTRADURAL ABSCESS; PACHYMENINGITIS EXTERNA CIRCUMSCRIPTA.

Definition.—An extradural abscess is a localized or circumscribed pachymeningitis. The thin plate of bone between the attic and the dura, or between the antrum and the dura, undergoes carious and necrotic degeneration, and the dura over this area becomes inflamed, throws out a plastic exudate, and is firmly attached to the bone it covers. After a time the bone is destroyed and the purulent secretion burrows between the dura and the bone, but is prevented from extending over a large area by the plastic exudate. It is generally located in the middle fossa.

Etiology.—The abscess usually occurs in chronic otorrhea with acute exacerbations of mastoiditis. It also occurs in cholesteatoma with suppuration. The cholesteatomatous mass in the attic or antrum causes pressure necrosis of the tegmen tympani and tegmen antri, and thus exposes the dura of the middle fossa to suppurative infection. Acute suppurative otitis media, especially of influenzal origin, may also cause it, as the bacillus of influenza is very destructive to bone tissue. An infected embolus or a thrombus from one of the veins or its tributaries may cause an extradural abscess without bone necrosis.

Symptoms.—The signs of this condition are not well marked, a severe headache with a slight rise in temperature being the most reliable ones. The headache is continuous and is referred to the affected side. When, however, there is a sudden profuse discharge of pus from the ear, the headache and the temperature are relieved or disappear altogether. If the membrana tympani (drumhead) is observed by reflected light, and the pus pulsates, it may be inferred that it has its origin in the middle fossa of the skull. That is, the pus comes from a cavity surrounded or partly surrounded by a resistant tissue. The dura is such a tissue, hence the inference. If the pus comes from a bony cavity, no such pulsation is present, unless an artery is exposed by the necrotic process. The internal carotid artery passes close to the anterior portion of the cochlea, and if there is a labyrinthine suppuration, and the artery is exposed, there may be a pulsation of the escaping pus.

If during a mastoid operation there is a profuse discharge of pus which pulsates synchronously with the heart beat, there is in all probability an extradural abscess, which may be evacuated and cured by removing the tegmen tympani and tegmen antri.

Localizing or motor symptoms are absent, as the motor tract of the brain is not involved.

The abscess is not always located in the middle fossa. Necrosis of the cells posterior to the labyrinth may occur, and thus communicate with the cerebellar fossa back of the pyramid of the temporal bone. Hence, vomiting and vertigo may be the prominent symptoms. The headache in these cases is referred to the region of the occiput on the affected side. The temperature is about the same as in extradural abscess of the middle fossa. As the disease progresses, mental dulness and coma develop from the increased intracranial pressure, due to the effusion into the ventricles.

In a case recently operated on by me the patient rapidly developed coma during the course of an otitis media and an acute exacerbation of mastoiditis on the right side. The surgeon who was in attendance had placed the patient in a hospital for observation, and had recommended an operation for mastoiditis. This was refused. During the absence of the surgeon from the city the coma developed. When I saw the patient he was semicomatose. The nurse stated that he had been complaining of pain in the back of the head, but did not know to which side he referred it. I performed a radical mastoid operation upon the right side, and, as I suspected a cerebellar abscess, the operation was extended in the usual way to this region, but without locating the abscess. At the post-mortem an extradural abscess containing about 2 drams of thin yellow pus was found on the opposite side on the posterior inferior aspect of the cerebellum. The left ear was not affected.

Prognosis.—If the abscess becomes latent, and acute exacerbations of the otitic and mastoid inflammation do not occur, the patient's life may not be placed in jeopardy for a long time. If, on the contrary, the abscess occurs during an acute exacerbation, or following an acute attack of influenza, the abscess may break its bounds and penetrate the substance of the brain and lead to a hasty fatal issue.

If the abscess is recognized, located, and successfully operated on, the patient usually recovers. Spontaneous evacuation into the ear or through the outer table of the skull may result in recovery. Knapp reports two such cases which evacuated near the occipital protuberance, both of which recovered. Dench reports 25 cases of extradural abscess, 23 of which recovered and 2 died. Of 10 cases occurring in my practice, 8 recovered and 2 died.

Treatment.—The treatment is surgical; alcoholic stimulants may be given if sepsis is present.

The surgical treatment of an extradural abscess consists in removing the plate of bone underneath which the abscess rests and evacuating its contents. If the abscess is in the middle fossa, it can be generally reached through the tegmen tympani and antri, which have already been exposed by the radical mastoid operation. A carious opening usually exists, and this should be enlarged until the plastic adhesion to the bone is reached. This should not be disturbed, as to do so opens the avenues of infection to the healthy dura beyond it. A curved probe introduced

through the fistulous opening in the roof of the attic or antrum will enable the operator to define the outlines of the abscess cavity, and he can thereby judge the area of bone to be removed. It will be rarely necessary to make an opening through the squamous portion of the temporal bone except in those cases due to a thrombus or an embolus, in which case it may be necessary to trephine the skull on the affected side. If there is a point of tenderness, this may be utilized as a tentative means of locating the abscess. If, after making the opening, healthy dura is found, introduce a probe between the dura and the bone and pass it in various directions in an endeavor to locate the abscess. If the abscess is chronic and walled off, do not rupture the plastic barrier if it is possible to reach it by making an opening directly over it, as to do so may set up a diffused meningitis. If, however, the abscess is not directly accessible through an external opening, the plastic wall may be broken down and the pus evacuated through the opening already made by lifting the dura with a heavy probe and allowing it to escape. The dura should then be lifted and the parts irrigated with warm bichloride solution, 1 to 5000.

If the abscess is between the posterior wall of the pyramid and the dura, it may be reached through the mastoid wound by extending the bony wound from the posterior wall of the antrum backward and to the inner aspect of the sigmoid groove of the lateral sinus. If the sinus is large and well forward, this route is not available.

INTRADURAL ABSCESS; PACHYMENINGITIS INTERIOR CIRCUMSCRIPTA.

This condition is quite similar to extradural abscess, except that the dura is perforated and the plastic exudate exists between the dura and the pia mater, thus walling off the purulent accumulation from the brain. The symptoms are the same as in extradural abscess. The prognosis is more grave, as the brain is in greater danger of infection. The treatment is the same, though the probing must be more carefully prosecuted, as the pia mater is more delicate than the dura.

LEPTOMENINGITIS DIFFUSA PURULENTA OF OTITIC ORIGIN.

Leptomeningitis may arise in the course of an otitis media or mastoiditis from a perforation through the tegmen tympani and antri, the carotid canal, the labyrinth, and through the sheaths of the anastomotic bloodvessel in influenza. Ethmoiditis and sphenoiditis may also give rise to it.

Symptoms.—Headache, at first remittent and later constant, is characteristic of this disease. The temperature is elevated and the face flushed. The pulse and respiration are rapid, the latter assuming the Cheyne-Stokes type as a fatal issue is approached. Persistent vomiting

of mucus and bile is present. Mental excitement, as irritability, delirium, and extreme restlessness are marked symptoms; as the disease progresses, somnolence and loss of memory develop. Rigors are present, but not so marked as in sinus thrombosis.

The muscles of the face and extremities become drawn or contracted, but this phenomenon finally centres in the muscles of the neck, and the head is retracted. The pupils are contracted. The muscles of the abdomen are drawn in and the abdomen is flat. The motor oculi, trochlear, and abducens nerves become paralyzed.

Spinal involvement is shown by Westphal's symptoms, viz., increased tendon reflexes, and paresthesia and hyperesthesia of the extremities.

By Quincke's lumbar puncture the increased pressure of the spinal fluid may be measured, the coagulability of the fluid and the presence of streptococci determined. The virulence of the streptococci may be tested by inoculating a guinea-pig with it. Coma occurs a few hours before death.

Prognosis.—Death occurs in nearly every case. Operative interference is not warranted.

BRAIN ABSCESS OF OTITIC ORIGIN.

Bacon emphasizes the significance of a firm, dense mastoid process in cases operated upon in which such symptoms as high fever, rapid pulse, etc., do not abate after the operation. He thinks it points to cerebral complications, and should lead the operator to explore the cranial cavity without further delay. This is sound advice. Many cases may pass into a most serious condition while the surgeon is waiting, Micawber-like, for something to "turn up." If the pus and debris are removed and drainage is established, the symptoms should at once become better, and they should remain so. If, on the other hand, only the outer pus pocket (mastoid antrum) is evacuated, while the inner pus pocket (brain abscess) remains closed, the septic symptoms will continue. I cannot too strongly impress the needlessness of delay in operating, or doing secondary operations upon the cranial cavity, when the septic symptoms continue without abatement. The dangers attending the secondary operation are small compared with those of delay.

It is the aural surgeon's business to know when to await developments and when he should operate at once. He should either be a surgeon or have a close friend who is one.

When, after a mastoid operation, the fever and pain continue and the examination of the fundi of the eyes is negative, the surgeon should not be misled by the negative symptoms, as many cases are reported in which the subsequent history showed brain involvement to have been present.

J. F. McKernon writes that when the *occipital pain* is not relieved by the primary mastoid operation, the aural surgeon should go deeper and explore the cerebellar area, in order, if possible, to determine the cause of

the pain. He recommends a grooved director for exploring the brain substance in place of an aspirating needle, as it allows the thick pus to escape, whereas an aspirating needle does not.

McKernon formulates the following indications for exploring the cranial cavity when an otitic abscess is suspected:

1. That a chronic otorrhea is or has been present.
2. Persistent headaches, general or localized.
3. Restlessness and irritability of temper.
4. Tenderness of the affected side on percussion.
5. Nausea, vomiting, and vertigo.
6. An almost persistently low temperature.
7. A slow pulse, later, stupor. Optic neuritis may or may not be present; when present it may aid materially in arriving at a diagnosis, as may also aphasia and motor disturbances.

He believes head pain (2) to be the most significant symptom.

"In the great majority of cases, other than traumatic or pyemic, the patient has had a chronic purulent discharge from the middle ear, often dating from an attack of one of the exanthematous fevers of childhood, or he has had a chronic ulceration about the nose or mouth" (Macewen).

The following statement refers to cases of aural origin: I have been told so often by patients in my clinic at the College of Physicians and Surgeons that they have no discharge from the ear, in which, upon casual examination the pus is easily seen. The patients seem to intend to convey the idea that the discharge, though present, is not profuse enough to run out over the ear and face. Among private patients a more exact statement is usually given, as they are more fastidious, and are annoyed by even slight moisture in the external meatus.

As Macewen says, "The otorrhea may have given little trouble, and its long continuance without apparent harmful result may have lulled the initial fear, until the ear disease is regarded as of no importance."

A person thus affected may suddenly become seriously ill after unusual exposure or injury to the head, or even without any known cause. Persistent headache develops without any increase in the pus discharge. Other symptoms follow, and the patient applies to his physician for relief.

There may be a perforation of the tegmen tympani, which has existed for years without infection of the meninges. The granulations fill the opening and effectually guard the intracranial contents from septic infection. Such a favorable result is not always to be expected. In removing the granulations from the attic through the external meatus great care should be exercised, lest a perforation in the tegmen be thereby opened and septic infection transmitted to the meninges.

Symptoms.—According to Macewen the symptoms of the acute brain abscess may be divided into three stages:

First Stage.—Twelve to seventy-two or more hours.

(*a*) Violent (usually) pain in the ear which soon extends into the temporal region, with shooting pains in the frontal and occipital regions.

(*b*) Vomiting without (usually) nausea.

(*c*) Rigors occur early and are nearly constant. They may vary in intensity from a mere feeling of chilliness to violent shivering and chattering teeth. *Cutis anserina* is well marked.

(*d*) The temperature is slightly above normal.

(*e*) The pulse is accelerated.

(*f*) The tongue is coated and furred.

(*g*) Prostration is marked early.

(*h*) Otorrhea ceases, or becomes less in quantity.

Second Stage.—(*a*) Pain diminished.

(*b*) Percussion over mastoid and squamous portions of temporal bone on the affected side causes the patient to wince. (Compare the two sides.)

(*c*) Cerebration is slow. The eyes have a vacant, dreamy appearance.

(*d*) Want of sustained attention, and finally mental obscuration.

Fig. 380

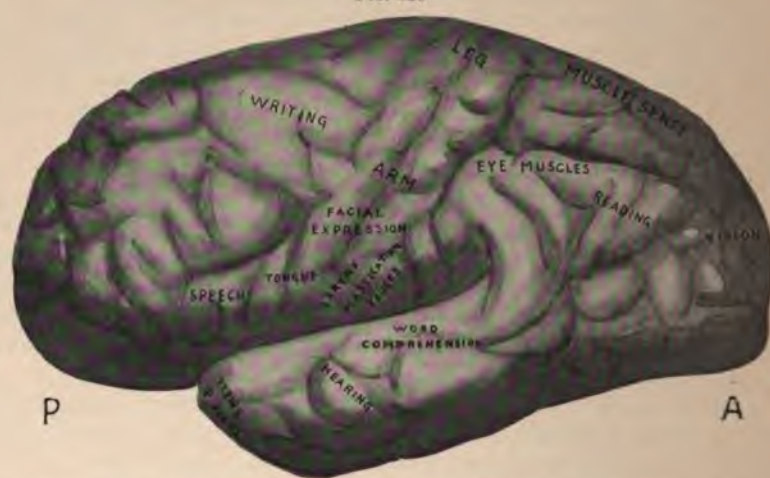

The cortical centres of the cerebrum, to be used in localizing lesions within the skull.

(*e*) Inability to apply strength. The strength exists, but the will power to use it is gone.

(*f*) Temperature about normal or subnormal.

(*g*) Pulse slow and full. Sometimes weak and soft (50 to 60 per minute).

(*h*) Respirations slow and regular.

(*i*) Constipation the rule.

(*j*) The urine occasionally retained.

(*k*) Loss of appetite (anorexia) the rule

(*l*) Vomiting on moving about. No nausea.

(*m*) Convulsions occur occasionally.

(*n*) Paralysis may occur from brain necrosis and pressure from the abscess (Fig. 380)

(*o*) The face is that of one who is seriously ill. The gray color described by some is not always present.

(*p*) The breath is putrid.

(*q*) Rigors do not often occur, except upon extension to a new area.

(*r*) Emaciation toward the latter part of the second stage.

(*s*) The reflexes do not give reliable data.

(*t*) Optic neuritis frequent in latter part of the second stage.

(*u*) Examination of the ear shows otorrhea and granulations and perforation of the drumhead. The curved probe may reveal erosion of the tegmen tympani.

(*v*) Swelling and redness over the mastoid usually absent in adults.

Third or Terminal Stage.—The natural termination is in death. Surgical interference may avert this if done in the first or early part of the second stage. Stupor and coma gradually increase. The abscess may break and leak on the surface of the brain or into the ventricles. Such an event is attended by vomiting, flushing, restlessness, rigidity of limbs, clonic spasms, quick pulse and respiration, and high temperature.

Prognosis.—Koerner reported 92 cases of brain abscess operated upon, with 51 recoveries. The prognosis varies, however, according to the stage in which the operation is performed. If operated in the first stage, the death rate should be small, perhaps less than 10 per cent.; if in the second stage, before stupor develops, it should not exceed 50 per cent. If the operation is postponed until encephalitis has become extensive, or until the pus has escaped from its sac and invaded the meninges and ventricles of the brain, the mortality probably exceeds 90 per cent. Taking the cases as they have been operated upon and reported in the literature, the average death rate is about 50 per cent.

Treatment.—(See the Surgery of the Temporal Bone.)

THROMBOSIS.

A thrombus is a mass formed in the heart or peripheral vessels the component parts of which are derived from the blood (Frazier). They are arterial, venous, capillary, or cardiac in origin, and, according to their composition, are white, red, and mixed thrombi.

The following four factors enter into the pathogenesis of a thrombus:

1. Infective microörganisms.
2. Structural changes in the intima of the vessel or organ.
3. Disturbances of the blood current.
4. Chemical changes in the blood.

1. In the non-infective thrombus the microörganisms are absent. It is the infective type, however, with which the otologist has to deal. "The primary causative factor is a pyogenic organism, the primitive lesion a phlebitis, and the terminal process a thrombosis or a thrombophlebitis. Thrombophlebitis, associated with such general septic processes as pyemia and septicemia, was the first to be recognized as of infective origin; subsequently, however, the infective nature of thrombophlebitis has been admitted and recognized in other diseases of infectious origin, as in the various so-called infectious diseases" (Frazier). Streptococci

are the most frequent cause of this disease. A negative bacteriological finding does not necessarily preclude an infectious origin, the toxin remaining being the exciting inflammatory agent.

2. The structural changes in the intima are due to the irritation by the toxins of the bacteria. The intima becomes rough and adhesive. The injured cells of the intima liberate a fibrin ferment which favors thrombus formation. The roughened projections of the intima into the lumen of the vessel interfere with the velocity of the blood current and thereby favor thrombus formation.

3. The slowing of the blood current cannot alone cause thrombosis. If associated with changes in the intima and the presence of microörganisms, it predisposes to thrombus formation. The slowing of the blood current is attended by a rearrangement of the constituents of the blood. The white blood corpuscles incline to the periphery of the current and are admixed with a few platelets. As the current becomes slower, the white corpuscles diminish and the platelets increase in number. In some instances a projection from the intima causes a whirling motion of the current, which still further favors thrombus formation.

4. The chemical changes in the blood, while not yet demonstrated, seem to be factors in thrombosis. A fibrin ferment is probably liberated in the infected thrombus, and it may influence the production of the platelets.

Pathology.—The thrombus is composed of the constituents of the blood in varying proportions, and are white, red, or mixed, according to whether they are formed in circulating or stagnant blood. If in circulating blood, they are white or mixed; whereas, if in stagnant blood, they are red, and have no clinical significance. Blood platelets form the nucleus of the white and mixed variety, though in the later stages they may have disappeared.

According to Frazier, the thrombus, at first composed of the normal constituents of the blood, undergoes various changes, which become an element of considerable danger. The leukocytes undergo fatty degeneration and necrosis; the red corpuscles are decolorized, irregular in shape, and pigmented. The platelets disappear and are replaced by fibrinous deposits. Softening or liquefaction occurs, and the creamy substance contains granular debris, pus cells, and microörganisms. It is in the septic variety of softening that fragments become separated from the thrombus, and, as infected emboli, are carried off by the circulation and deposited in the internal organs, usually the liver, kidneys, and lungs, where they give rise to secondary or embolic abscesses.

The terminal stage of a thrombus is organization, or rather a disappearance of the thrombic material and the deposit of fibrous material. At the beginning of organization the thrombus becomes infiltrated with leukocytes, and following this there is a proliferation of fixed connective tissue cells derived from the endothelium and the other fixed cells of the intima. Bloodvessels penetrate the clot and form anastomoses with each other and with the vessel walls above and below the thrombus. The thrombus is absorbed, and is replaced by embryonic connective

tissue rich in bloodvessels. The fibrous mass becomes firm, contracts, and may completely or partially occlude the vessel. In rare instances the fibrous tissue disappears and leaves the lumen of the vessel unimpaired.

Venous thrombi extend toward the heart or with the blood current. In thrombosis of the sigmoid or petrosal sinuses the thrombus may extend to the jugular vein and completely occupy its lumen.

LATERAL SINUS THROMBOSIS.

Etiology.—The causes of infective thrombosis of the sigmoid portion of the lateral sinus are chiefly to be found in the loss of integrity of the intima of the membranous sinus from the extension of the destructive process in suppurative mastoid or labyrinthine inflammation. So long as the intima is healthy it inhibits the coagulation of the blood in contact with it, but where its vitality is impaired by a necrosing mastoiditis its inhibitory power is lost and the blood fibrin coagulates on the affected area, and a thrombus is thus established. The thrombus may or may not occlude the lumen of the vessel. At the beginning it is limited to the external or bony aspect of the sinus, as this is the part first involved by the necrosis of the bone. The necrosis may extend from the mastoid cells of the process or from the labyrinth (in labyrinthine suppuration) to the cells lying between the labyrinth and the antrum, and thence to the antrum and mastoid cells, from whence it involves the sinus.

At the beginning the thrombus is not infected. It is only after the wall of the membranous sinus has undergone marked deterioration that the infective microörganisms penetrate it and lodge in the thrombus. There is food for thought in this fact. That is, if the condition is diagnosticated before infection of the thrombus occurs, the infection and its evil consequences could be thwarted by an exposure of the sinus and the removal of the diseased bone surrounding it without opening the sinus itself. Unfortunately, the diagnosis of thrombosis at this early stage is extremely difficult to make, and is rarely made except during a mastoid operation.

Symptoms.—The symptoms of lateral sinus thrombosis may be divided into three stages, based upon the pathological changes so minutely described by Macewen in his masterly work on *The Pyogenic Diseases of the Brain and Spinal Cord.*

First Stage.—The thrombus, partial or complete; disintegration not established.

(*a*) Slight fever.

(*b*) Rigors, usually present. Slight rigors exceptional.

(*c*) Headache, slight or severe, limited to the affected side.

(*d*) Slight tenderness over the region of the mastoid emissary vein.

(*e*) Slight edema and tenderness below the tip of the mastoid in the posterior triangle of the neck.

(*f*) Leukocytosis with increased polymorphonuclear count.

Second Stage.—The thrombosis, partial or complete; disintegration and systemic absorption established.

(*a*) Temperature always above normal and distinctly fluctuating.

(*b*) Frequent rigors.

(*c*) Headache and tenderness over the mastoid emissary vein.

(*d*) Edema and tenderness below the tip of the mastoid in the posterior triangle of the neck.

(*e*) Increased leukocytosis and polymorphonuclear count.

Third Stage.—The thrombosis, partial or complete; disintegration and excessive systemic absorption.

(*a*) A chill or rigor followed by great and marked fluctuations of temperature; sometimes subnormal, and then rapidly rising to 104° or 106°.

(*b*) Headache, severe, often excruciating.

(*c*) Marked tenderness over the mastoid emissary vein and the posterior triangle of the neck. The internal jugular vein may be tender on pressure.

(*d*) Metastatic pneumonia, enteritis, or meningitis may be present, with their characteristic symptoms.

(*e*) Still greater leukocytosis and polymorphonuclear count.

NOTE.—The leukocytosis and polymorphonuclear count is greater in sinus thrombosis than in simple mastoiditis.

(*f*) Coma as the fatal issue approaches.

Early Diagnosis.—If diagnosticated in the first stage, and operated at once, nearly all cases recover. If diagnosticated and promptly operated in the second stage, before metastatic extension to the brain, lungs, bowels, spleen, etc., fully 50 per cent. will recover; whereas, if diagnosticated and operated in the third stage, the mortality rate is very high.

In view of the foregoing facts, it is evident that all cases of suppurative otitis media, especially if there is a secondary acute manifestation, should be critically studied to detect the earliest sign of sinus involvement. Such observations cannot be made unless the patient is placed in bed, with a trained nurse in attendance, and the temperature, pulse, and respiration recorded every three hours. Inquiry as to the presence of a unilateral headache, not necessarily severe, should be made two or three times daily. The surgeon should examine for tenderness over the mastoid emisssary vein and the posterior triangle of the neck. The occurrence of a rigor, even if slight, should excite suspicion, and lead to most careful inquiry as to all the other symptoms.

If a diagnosis is not positively made before a mastoid operation is performed, the sigmoid portion of the sinus should be exposed and its membranous walls examined. Infective perisinuous abscess may be present, without involvement of the intima of the sinus. Sometimes the external surface of the membranous sinus is velvety and granular in appearance, the smooth surface and pearly gray color normal to the sinus being absent. I have seen cases like this recover after exposing the membranous sinus. The drainage of the perisinuous abscess checked the

inward extension of the infective process, and thus thwarted the formation of the thrombus in the sinus.

I saw one case in which perisinuous abscess was present and the lumen of the sinus open, which afterward developed thrombosis of the lateral and the cavernous sinuses. The question as to the advisability of opening such a sinus is of considerable importance. I believe it should be done, and done thoroughly, the sinus being walled off after exploration and drained with iodoform gauze.

A partial thrombosis of the sigmoid sinus may sometimes be demonstrated by compressing the sinus with the finger and noting the uneven or nodular surface when collapsed. The use of a hypodermic needle is useless for diagnostic purposes, as it may penetrate the thrombus, and withdraw blood from beyond it.

In complete thrombosis of the sinus palpation with the finger gives the sense of a doughy resistance. After full exposure of the sinus, it should be palpated to determine, as far as possible, the probable extent of the thrombus. If it is doughy over the full area of the exposure, the clot probably extends to or above the knee, and below to the jugular bulb.

The knowledge thus gained may determine the advisability of a still further exposure of the jugular bulb. (See Thrombosis of the Jugular Bulb.) In complete thrombosis there is no flow of blood upon incising the sinus, nor will the hypodermic needle draw fresh blood.

Prognosis.—The prognosis depends chiefly upon the stage in which diagnosis and operative procedures are made. If made in the first stage, nearly all will recover. If in the second, about one-half will recover. If in the third, the mortality rate is high. If not operated, nearly all cases terminate fatally.

Here is a field in which an early diagnosis and an early operation are the means of saving life; whereas a late diagnosis, even with operative interference, will in a majority of subjects fail to save life.

Thrombosis of the Jugular Bulb.—Whiting has formulated the following test: Compress the membranous sinus as near the bulb as possible, and draw the finger upward to empty it; the compression is then removed, and if the vessel fills from below, it is assumed that the bulb is not thrombosed. Allport believes this procedure is dangerous, as it may liberate infective clots and disseminate the infection to other parts of the body. Such occurrences have not been reported.

Grunert exposes the jugular bulb by opening the mastoid, exposing the sinus, and ligating the jugular. The retro-auricular and cervical (jugular) incisions are then united and the tip of the mastoid process is resected. The soft parts are then pulled forward and loosened as far as the jugular foramen. The bone should be removed until the jugular bulb is exposed. (See Surgery of the Temporal Bone.)

Cavernous Sinus Thrombosis.—Thrombosis of the cavernous sinus is rare. Two cases of otitic origin have occurred in my practice, though this is probably an exceptional experience, as many aurists of equally large experience have reported no cases.

When of otitic origin, it usually extends from the superior or inferior petrosal sinus to the cavernous sinus. When it complicates inflammation of the nasal accessory sinuses, it extends from the secondarily infected eye through the ophthalmic vein to the cavernous sinus.

The general symptoms are similar to those present in thrombosis of the lateral sinus (thrombosis lateral sinus). The characteristic symptom is the marked edema of the peri-ocular tissues and the protrusion of the eyeball, as shown in Fig. 381, drawn from one of my cases.

Fig. 381

The author's case of cavernous sinus thrombosis of otitic origin. The drawing shows the case in the early stage before the thrombus had extended to the left side through the circular sinus.

My first case occurred in a girl, twelve years old, seven years after an attack of scarlet fever, at which time she had an acute otitis media purulenta. During the interim (except the last week of her life) she was said to have had no ear discharge. The mastoid symptoms and otorrhea developed rapidly. When I saw her on the third day she was greatly prostrated and septic, and one eye slightly protruding. The first chill and rigor occurred on the fourth day. The lateral sinus was exposed, but was apparently not thrombosed. Death occurred three days later.

In my second case the cavernous sinus was thrombosed secondarily to the lateral sinus. The lateral sinus was exposed, and the thrombus

removed as high and as low as possible without establishing a flow of blood. The patient gradually became stupid, finally comatose, and died one week after the lateral sinus was exenterated.

Symptoms.—The symptoms depend on whether one or both sinuses is affected. It usually begins in one and spreads to the other through the circular sinus. The symptoms shift from one eye to the other, a differential point between thrombosis of the cavernous sinus and inflammations confined to the orbital cavity.

(*a*) Pain may be occipital, supra- and infra-orbital, and in the vertex.

(*b*) Exophthalmos and edema of the eyelids and side of the nose are characteristic symptoms due to venous obstruction.

(*c*) Drooping of the eyelids (ptosis), strabismus, and pupillary reactions due to pressure on the third nerve are also present.

(*d*) Edema of the pharynx and tonsil on the same side is occasionally present.

The nerves involved are the second, third, fourth, and sixth, and the first division of the fifth. The third is the most constantly involved, as is evidenced by the ptosis. The duration of the disease varies from a few days to several months, generally only a few days. The death rate is extremely high.

Treatment.—The treatment is chiefly palliative. When tension of the conjunctiva is extreme, it may be slit or punctured. The eyeball may be removed, together with the thrombosed vessels, with a view of affording some relief from the pain and distress. Such interference should be undertaken only in extreme cases, as there is no hope of effecting a cure by this procedure. Attempts to operate upon the sinus have generally failed, though favorable reports have been made. (See Surgery of the Temporal Bone.)

CHAPTER XLVIII.

THE SURGERY OF THE TEMPORAL BONE.

THE surgical treatment of the diseases and complications included in this chapter are: (1) Acute mastoiditis; (2) chronic mastoiditis; (3) Bezold's mastoiditis; (4) necrosis of the semicircular canals; (5) necrosis and suppuration of the semicircular canals and vestibules; (6) necrosis and infection of the cochlea and semicircular canals; (7) thrombosis of the lateral sinus; (8) thrombosis of the jugular vein; (9) thrombosis of the jugular bulb; (10) extradural abscess in the middle fossa of the skull; (11) serous meningitis; (12) abscess of the cerebrum; (13) abscess of the cerebellum; (14) facial paralysis; and (15) postauricular fistula.

Ossiculectomy.—The removal of the malleus and the incus for the relief and cure of chronic suppurative otitis media has fallen into disuse since Macewen's work on *The Pyogenic Diseases of the Brain and Spinal Cord* appeared in 1893. His presentation of the efficacy of the radical mastoid operation for this purpose was so convincing that it has been almost universally adopted by otologists throughout the world. There is now a reactionary tendency to differentiate the cases, and to adopt various surgical procedures, according to the character of each individual case. In some instances the radical mastoid operation is elected as the best method of procedure; in others the mastoid meatus operation is elected; and in still others the otologist is content to remove the granulation tissue and secretions through the external meatus by means of small curettes, the syringe (Figs. 382 and 383), and inflation and irrigation through the Eustachian tube by means of a Weber-Leil catheter.

Technique.—*The Anesthetic.*—Ossiculectomy may be performed under local anesthesia, though it is usually quite painful. In my experience the most reliable anesthetic mixture is composed of equal parts of cocaine carbolic acid, and menthol. Instil a few drops of this mixture into the meatus, and at the end of twenty minutes its full anesthetic effect is obtained.

It is usually preferable, however, to administer a general anesthetic, as this ensures a painless operation.

Preparation of the Ear.—The auricle and external meatus should be scrubbed with soap and water, and followed by an alcohol bath. A cotton-wound toothpick or applicator may be used in scrubbing the meatus. If a general anesthetic is to be given, the patient should be placed in the hospital the day before the operation, and the bowels and diet regulated as for the mastoid operation.

Incision of the Membrana Tympani.—The incision may begin at the margin, at the junction of the antero-inferior and the anterosuperior

PLATE XI

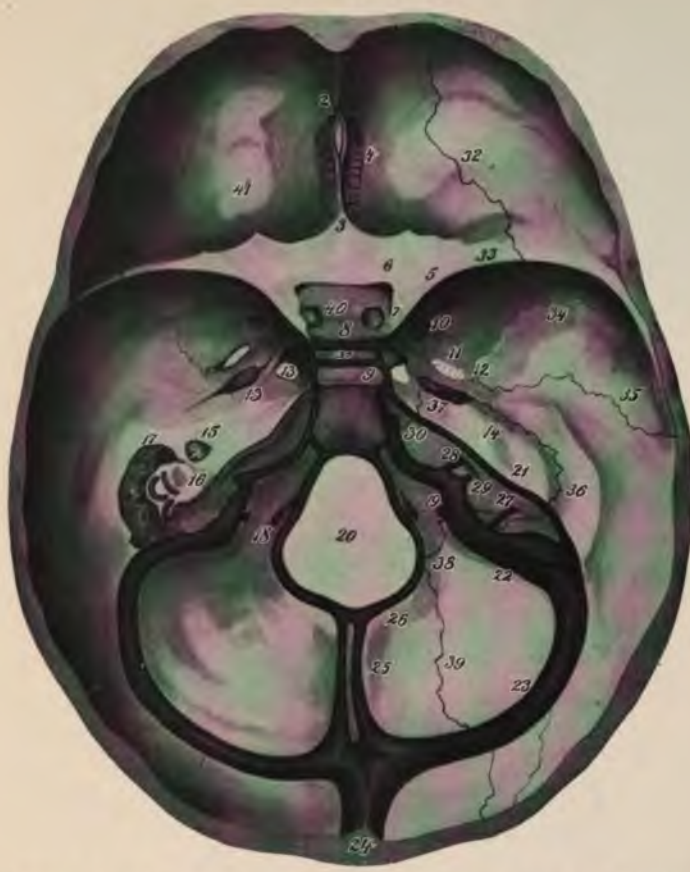

Base of the Skull: Left Labyrinth Exposed on the Right Side, the Grooves in the Base of the Skull are Shown also the Sinuses of the Dura Mater.

Two-thirds Life-size.

1, Crista frontalis (on the left, beginning of the superior longitudinal sinus); 2, foramen cecum (emissarium Santorini); 3, crista galli; 4, lamina cribrosa (olfactory nerve); 5, lesser wing of sphenoid; 6, optic foramen (optic nerve, ophthalmic artery); 7, anterior clinoid process; 8, sella turcica, flanked by the median clinoid process; 9, dorsum ephippii, with posterior clinoid process; 10, foramen rotundum (second division of fifth nerve); 11, foramen ovale (third division of fifth nerve); 12, foramen spinosum (middle meningeal artery and recurrent branch of fifth nerve); 13, carotid canal and foramen lacerum anterius (great and lesser superficial petrosal nerves, Eustachian tube, and tensor tympani muscles); 14, anterosuperior surface of pyramid; 15, cochlea; 16, semicircular canals; 17, tegmen tympani and roof of antrum laid open; 18, anterior condyloid foramen (twelfth nerve); 19, posterior condyloid foramen (emissarium Santorini); 20, foramen magnum; 21, superior petrosal sinus; 22, transverse sinus (descending portion); 23, transverse sinus (horizontal portion); 24, superior longitudinal sinus and torcular Herophili (confluence of the sinuses); 25, occipital sinus; 26, occipital sinus; 27, vein of aqueductus vestibuli (emerging at the external aperture of aqueductus vestibuli); 28, internal auditory vein (emerging in the internal auditory meatus); 29, vein of aqueductus cochleæ (emerging at the external aperture of aqueductus cochleæ; 30, inferior petrosal sinus emptying into the cavernous sinus; 31, circular sinus (Ridley); 32, groove traversing anterior fossa of skull; 33, sinus of lesser wing of sphenoid; 34, groove of meningeal artery; 35, transverse groove through middle fossa of the skull; 36, longitudinal groove through petrous portion of temporal bone (tegmen tympani); 37, groove through apex of pyramid; 38, transverse fissure (between posterior condyloid foramen and foramen magnum); 39, longitudinal groove through posterior fossa of skull; 40, impressio carotica (corresponding to the bend in the internal carotid artery); 41, juga cerebralia and impressiones digitatæ. (After Bruhl-Politzer.)

[redacted]

quadrants of the membrane (Fig. 384), and be extended upward to the malleus, thence downward along the anterior border of the handle to its

FIG. 382

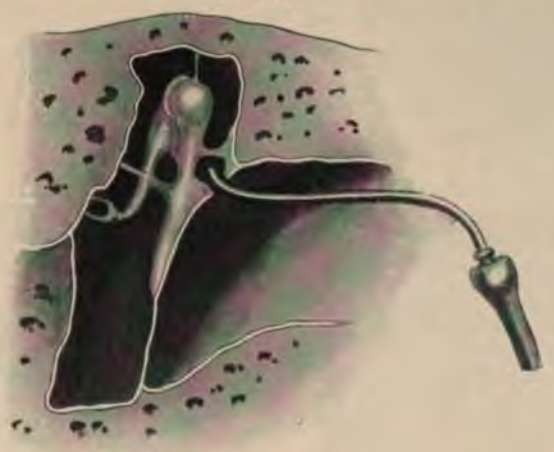

Irrigation of the attic through a perforation of the membrana flaccida.

umbo, or lower extremity, thence upward along its posterior border to the upper limit of the membrane, and thence downward along the posterior margin of the membrane to the junction of the postsuperior and postinferior quadrants of the membrane, as shown in Fig. 385. This incision makes two flaps of the membrana tympani, which drop downward and expose the tympanic cavity and its contents to view. This incision preserves a large portion of the membrana tympani and favors a speedy regeneration of it in the process of repair. The great objection to this incision is that the lower half of the membrane interferes with the drainage of the tympanic cavity.

FIG. 383

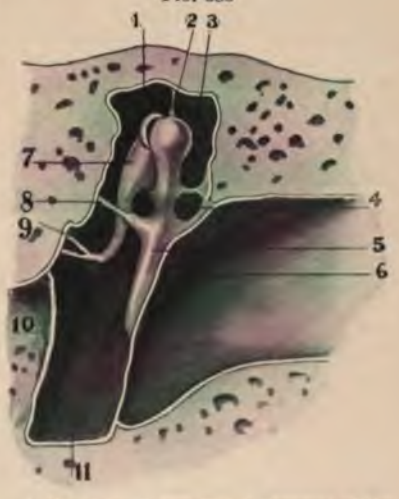

1, the attic; 2, suspensory ligament of the malleus; 3, external space of the attic; 4, Prussack's space; 5, malleus; 6, external meatus; 7, incus; 8, ligament attaching malleus to inner wall of the tympanic cavity; 9, stapes; 10, promontory; 11, cavern tympani.

Instead of the above incision, the entire membrane, or the fragments of it, if it is largely destroyed, may be removed by making an incision around its entire margin and along both borders of the handle of the malleus. This provides for perfect drainage during the after-treatment.

Removal of the Malleus and Incus.—The malleus should first be removed and then the incus. The attachments of the tensor tympani

muscle and the tendinous attachments of the malleus to the tympanic wall should be severed. Various instruments have been devised for this purpose, the best of which are Sexton's small angular blades (Fig. 386), which should be passed behind the handle of the malleus and carried upward to the tendinous attachment of the tensor tympani muscle. It should then be introduced through the space occupied by the membrana (pars) flaccida, to sever the ligamentous attachment to the outer wall of the tympanic cavity.

Fig. 384

Fig. 385

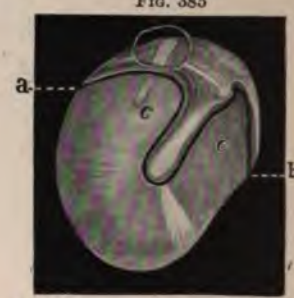

Fig. 384.—Right membrana tympani, showing the division into *A*, postsuperior quadrant; *B*, anterosuperior quadrant; *C*, antero-inferior quadrant; *D*, postinferior quadrant.

Fig. 385.—The right membrana tympani with a perforation at the margin of the postsuperior quadrant over the lenticular process of the incus, indicating necrosis of the incus and of the mastoid antrum. The line *a b* is the line of incision preliminary to the removal of the malleus and incus. The flaps of membrane thus made drop down and expose the upper half of the tympanic cavity to view.

Delstanche's ring knife may be used to remove the malleus. Its ring blade should be insinuated around the handle of the malleus and passed upward as far as possible, cutting the attachment of the tensor tympani muscle.

Having thus severed some of the attachments of the malleus, it should be removed either with the ring knife (Fig. 387) or with forceps (Fig. 388).

Fig. 386



Sexton's ossiculectomy knives.

Fig. 387

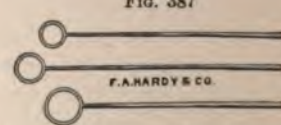

Ring curettes for removing the malleus.

The ring knife, or dull ring (Fig. 388), should encircle the handle of the malleus as high as possible, and then, with a rocking motion, or side-to-side motion combined with a downward pull, the malleus is dislodged and removed through the external meatus (Fig. 388).

If the forceps are used, the handle of the malleus should be seized as high as possible and rocked from side to side, combined with a downward pull, and dislodged from its position and removed (Fig. 388).

The incus is not so easily dislodged from its position, as its long process

is often beyond the grasp of the forceps, and even when it can be seized it is so fragile that it is apt to break. The incus hook (Fig. 389) is the

FIG. 388

Showing the severance of the ligamentous attachments of the malleus. After this is done the malleus is grasped with the forceps or a ring curette, and drawn downward until its head is disengaged from the attic. It is then removed through the external auditory meatus.

FIG. 389

Removal of the incus with the incus hook, after the removal of the malleus. The hook should be introduced posterior to the incus, the incus pushed forward and downward. If it is pushed backward it is apt to become lodged in the aditus ad antrum.

best instrument for its removal. Another difficulty encountered is the liability to dislocate it backward into the aditus ad antrum, or even into the antrum. To obviate this mishap, the incus hook should be introduced behind the body of the incus and passed upward and forward over its body. The hook should then be pressed downward and slightly forward, thus dislodging the incus and bringing it into the lower portion of the tympanic cavity, where it may be removed with the forceps (Fig. 389).

The stapes is never removed in the operation, as to do so would subject the labyrinth to infection.

Hemorrhage.—Bleeding may be controlled by mopping the tympanic cavity with adrenalin or with a hot 1 to 2000 bichloride of mercury solution.

Dressings and After-treatment.—The best dressing is a loosely applied strip of sterile gauze extending from the tympanic cavity to the auricle. The cavity of the auricle should be loosely filled with gauze and cotton and the whole covered with an ethereal solution of collodion, which holds in place as effectually as a large and cumbersome bandage (Fig. 420).

The after-treatment consists in applying similar dressings and the cleansing of the tympanic cavity with cotton-wound applicators, inflation through the Eustachian tube, and the reduction of granulations with carbolic acid or dehydrated crystals of chromic acid, for a period of about one month, or until the ear is dry.

In the event that this operation is unsuccessful, either the radical operation or the meatomastoid operation may be performed.

ACUTE MASTOIDITIS.

The Indications for Surgical Intervention.—It is taken for granted that the usual abortive therapeutic measures, as (*a*) the application of leeches (or the artificial leech) over the mastoid process and in front of the tragus, (*b*) the instillation of a 12 per cent. solution of carbolic acid in glycerin (A. H. Andrews) into the auditory meatus, (*c*) free incision of the membrana tympani, (*d*) ice over the mastoid process, (*e*) heat, cathartics, etc., have been used without success.

1. These and perhaps other therapeutic measures having failed to abort the infectious and destructive process in the cavum tympani and mastoid antrum and cells, the disease tends to become chronic, a fact which may constitute a sufficient reason for performing a simple exenteration of the mastoid antrum and cells. To wait for other and more definite indications might develop the necessity for a much more radical operation, or even lead to serious intracranial complications, and endanger the life of the patient. Intervention, when threatened chronicity is imminent, requires a comparatively simple surgical procedure, which almost always results in a permanent cure, often with but little or no impairment of the function of the ear.

2. Bulging or sagging of the posterior superior wall of the external

auditory meatus near the membrana tympani (Fig. 375) is due to the involvement of the mastoid cells below and anterior to the antrum (cells of Kirchner), and is a positive indication for the mastoid operation.

3. Pain over the mastoid antrum and tip which is not relieved by the application of ice (one to four hours), alternated with heat, over a period of from twenty-four to forty-eight hours, is an indication for the simple mastoid operation. The pain signifies congestion, edema, or granulations which block the drainage of the secretions. Pressure, necrosis, and toxemia rapidly develop under such conditions, and if the pain persists the mastoid antrum and cells should be opened.

4. Edema and redness of the mastoid region signify blocking of the secretions, and, if the condition is not relieved by leeching, ice, heat, etc., constitute another indication for surgical intervention.

5. The presence of a subperiosteal abscess over the mastoid process, especially in adults, having its origin through a fistulous opening in the mastoid cortex, is an indication for the operation. In infants and children such a condition often has its origin beneath the periosteum of the meatus, the mastoid cortex being intact, hence a subperiosteal abscess and the infection of the ear and mastoid antrum may be cured by an incision (Wilde) through the skin over the mastoid process.

6. Meningeal irritation (complicating acute mastoiditis), as evidenced by convulsions (in infants and children), delirium, intense headache, etc., may call for the mastoid operation.

7. Other and more serious intracranial complications, as circumscribed meningitis (epidural abscess), serous meningitis, thrombosis of the lateral sinus, etc., constitute positive indications for the mastoid operation.

The Simple Mastoid Operation in Acute Mastoiditis.—The Technique.—The preparation of the patient and anesthesia will not be discussed farther than to say that the head should be shaved, scrubbed, etc., over an area extending at least three inches from the attachment of the auricle, both above and behind it. Otherwise the patient should be prepared and anesthetized as for any other major surgical operation.

The incision back of the auricle should be so extended as to fully expose the entire field of the operation. In adults, the primary incision (Fig. 390 *a a'*) should begin at the mastoid tip, one-half inch posterior to the attachment of the lobule of the auricle, and extend upward behind the auricle, gradually approaching its attachment, until, when near the superior attachment, it should be about one-fourth of an inch posterior to it. It should then be extended anteriorly to a point immediately above the superior attachment of the auricle (Fig. 390 *a*). If, upon retracting the posterior flap, the operative field (posteriorly) is not fully exposed, a secondary incision (Fig. 390 *b b'*) should be made at right angles to the primary one. It should begin on a level with the external auditory meatus and be extended backward for a distance of one inch (Whiting). In those cases in which the mastoid cells extend well back toward the occiput it will be necessary to extend the secondary incision accordingly.

The primary incision (Fig. 390 *a a'*) should be first superficially outlined with the scalpel (Fig. 391), to ensure clean-cut edges, proper curve, and extension. It should then be carried through the entire substance of the skin, subcutaneous tissue, and the periosteum.

The Elevation of the Cutaneous-periosteal Flaps.—The skin and periosteum should be elevated together. Great care should be taken to preserve the periosteum, as the subsequent repair of the wound will depend somewhat upon the integrity of this structure. With this object in view, the author devised the periosteal elevator shown in Fig. 392. The periosteal blades are at right angles to the axis of the handle of the instru-

Fig. 390

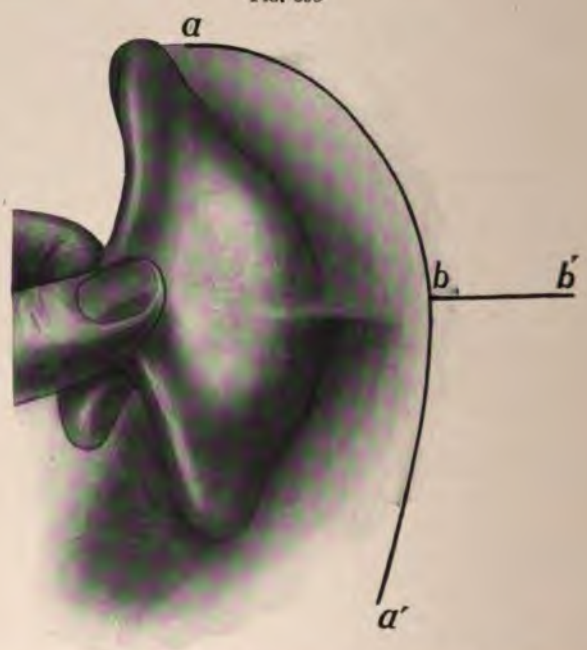

The postauricular mastoid incision. *a a'*, the primary incision; *b b'*, the secondary incision.

ment. Experience has shown that this angle is best adapted to the clean elevation of the mastoid periosteum. The instrument is provided with two right-angle elevators, one elevating on the pull, and the other on the push. But little difficulty will be experienced in elevating the upper two-thirds of the anterior and posterior flaps; whereas, the lower third will be elevated with difficulty, as the tendinous fibers of the sternomastoid muscle pierce it. The tendinous bands of this muscle should be cut with short, blunt scissors from the external cortex of the mastoid tip before elevation of the periosteum is attempted. If this is not done, long muscle fibers may be pulled from the sternomastoid muscle, thus opening avenues of infection in its substance (Whiting).

The Anatomical Landmarks.—Having elevated the cutaneoperiosteal flaps, the external characteristics of the mastoid process and auditory meatus should be noted. To experienced surgeons this requires but a few seconds of time. The first concern should be to determine the location of the mastoid antrum, as it forms the deeper landmark of the mastoid process. It is usually located at a depth of about one-half inch beneath the mastoid cortex and a little above and behind the cavum tympani. There are four more or less constant external landmarks which will guide the surgeon to the mastoid antrum. The one most constantly

Fig. 391



Mastoid scalpels.

present is the area of sieve-like perforations in the mastoid cortex just behind the external opening of the meatus (Fig. 393). These small openings contain minute vessels which bleed after the periosteum is elevated. The surface of the bone should be mopped dry, and in a moment the bleeding points will appear. Another landmark usually present is the suprameatal spine, or the spine of Henle (Fig. 393). It is a small triangle or diamond-shaped bony lip projecting outward and forward from the posterior margin of the external auditory meatus. The point for entering the antrum is immediately behind the spine.

Fig. 392

The author's mastoid periosteal elevator.

The third landmark for locating the mastoid antrum is the suprameatal triangle (Fig. 393). The upper boundary of the triangle is formed by the lower border of the posterior ridge or root of the zygomatic process; the posterior inferior boundary is formed by an imaginary line extending from the posterior end of the root of the zygoma to the inferior portion of the spine of Henle, or, if this is not present, to the posterior inferior margin of the auditory meatus. An opening made in the anterior portion of this triangle near the auditory meatus will enter the mastoid antrum. The fourth landmark to the antrum is the direction of the posterior superior wall of the bony portion of the auditory meatus. This

is ascertained by introducing a straight probe into the meatus along its posterior superior aspect and noting the angle of inclination in relation

Fig. 393

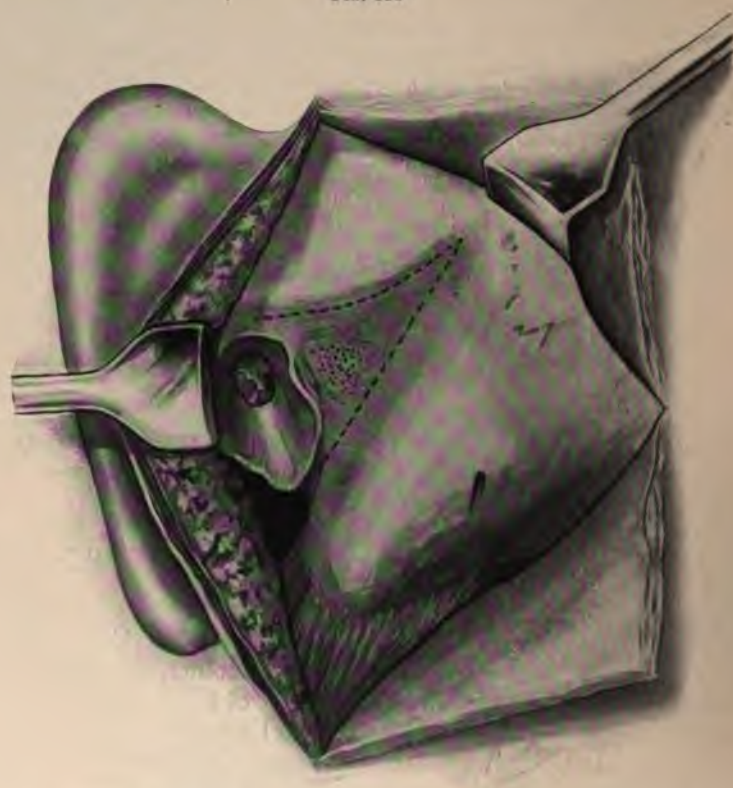

The anatomical landmarks for opening the mastoid antrum. The suprameatal triangle, the spine of Henle, and sieve-like depression.

to the general surface of the mastoid cortex. Having noted the foregoing anatomical landmarks, the exenteration to expose the antrum should be begun at the point indicated by the first three landmarks described,

Fig. 394

The Russian perforator.

and extended inward in a direction parallel with the probe, as suggested in the description of the fourth landmark. The usual direction

of the posterior superior wall of the bony meatus is markedly inward, and slightly downward and forward. After excavating for a depth of one-half inch (sometimes more, rarely less), the outer extension of the mastoid antrum may be looked for. The sinus is sometimes near the surface, and may lie immediately beneath the skin. Should the mastoid cortex be carious, the fistulous tract may be followed to its origin in the antrum or cells without regard to the external landmarks.

Opening the Mastoid Antrum.—The Russian perforator (Fig. 394) or a gouge may be used to expose the mastoid antrum. Personally, the author prefers the Russian perforator, as its use avoids the shock incident to the blows of the mallet (Fig. 395) in using the gouge. If the Russian perforator is used, its tip should be placed in the supra-meatal triangle (Fig. 393), with the long axis of the instrument paralle, with the probe placed against the posterior superior wall of the meatusl as described under External Landmarks. The mastoid cortex is then perforated with a boring movement of the perforator, the bone

Fig. 395

Allport's mastoid mallet.

shavings passing into the hollow chamber of the instrument. The instrument should be removed from time to time to examine the bottom of the bony wound, to see when a pneumatic space is uncovered. When this occurs, a dark spot will be found in the bottom of the wound. When the mastoid cortex is carious the tissue may be excavated with a curette, the anatomical landmarks being disregarded. A curved silver probe should be introduced into the pneumatic space, the curved tip being directed anteriorly. If the pneumatic space is the mastoid antrum, the tip of the probe will pass forward through the aditus ad antrum into the cavum tympani, as shown in Fig. 396. If the pneumatic space is a mastoid cell, the probe will not pass forward through the aditus ad antrum. If the sigmoid portion of the lateral sinus is located anteriorly against the posterior wall of the auditory meatus the perforator will uncover it, but will not injure its membranous covering. Herein is another reason for preferring the Russian perforator to the gouge.

As Whiting has so well shown, the external conformation of the mas-

toid process will show the position of the sigmoid portion of the lateral sinus. The sinus, being a large vessel, requires space; hence the area of greatest external bulging or convexity of the mastoid cortex may be taken as a guide to the location of the sinus. When the convexity is at the middle portion of the mastoid cortex it is well out of the way in opening the antrum. When, however, the anterior portion of the mastoid cortex is elevated, and the posterior wall of the meatus drops at right

Fig. 396

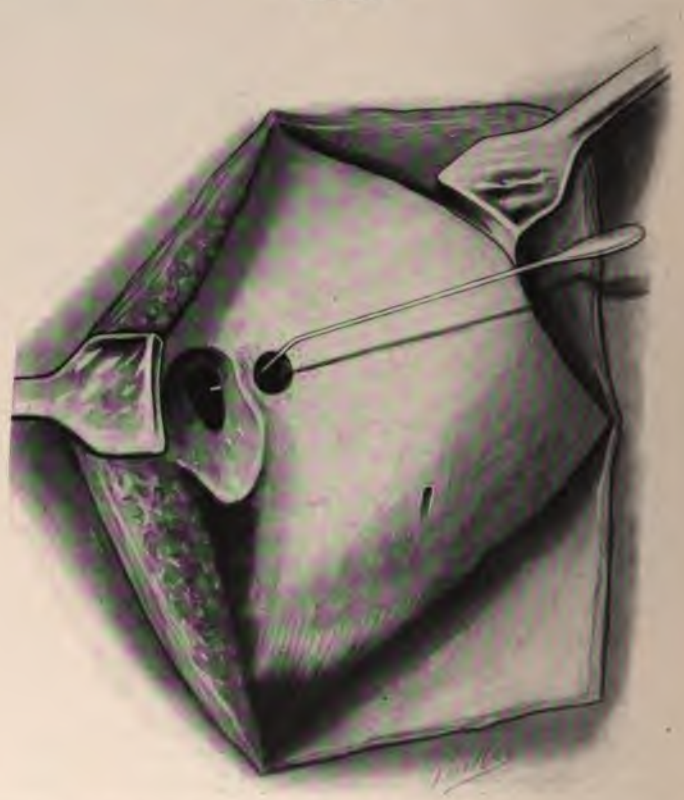

The opening into the mastoid antrum made with the Russian perforator. The fact that the silver probe passes forward through the aditus ad antrum into the cavum tympani, is proof that the pneumatic space at the bottom of the wound is the antrum and not a mastoid cell.

angles from it, the sinus is located anteriorly, and will be exposed in opening the antrum. In such subjects it may be necessary to open the antrum by removing the posterior wall of the meatus after the method of Stacke.

Having exposed the mastoid antrum, its dimensions and extensions should be determined with a bent probe introduced through the bony wound. The whole outer wall of the antrum should then be removed with a gouge and mallet or the rongeur forceps.

The Removal of the Mastoid Cortex.—The mastoid cortex should be removed in parallel shavings (Fig. 397), as recommended by Whiting. From three to four grooves are thus made, exposing the superficial cells. The gouge may be applied at either the mastoid tip, as shown in the drawing, or at the level of the mastoid antrum. Care should be exercised to avoid injuring the mastoid emissary vein shown at the posterior portion of the mastoid process (Fig. 397). This vein opens into the

Fig. 397



The removal of the cortex of the mastoid process.

sigmoid portion of the lateral sinus, and, when injured, bleeds profusely and persistently. It may be readily closed by placing the tip of some blunt instrument against the opening of its bony canal and tapping it smartly with the mallet.

The Exenteration of the Mastoid Cells.—After the cortex is removed the cells should be broken down and removed with the curette and the rongeur forceps. If the intercellular walls are soft or necrosed, they

may be removed with a curette. If they are firm, the rongeur forceps is better for the purpose. The overhanging edges of the mastoid cortex should be removed with the rongeur forceps (Fig. 398) until all cells are completely exposed and accessible to curettement. Large mastoid cells are often found in the tip of the process, and they may be the focal centre of the infection, pus only being found when these cells are reached. The cells should, therefore, be exposed to the tip in all cases, as other-

Fig 398

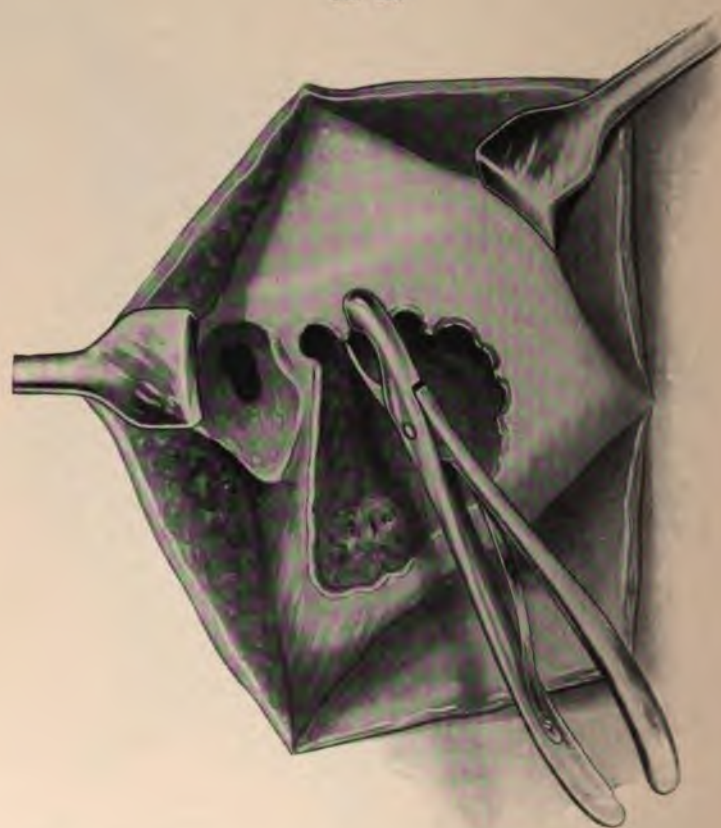

The completion of the removal of the mastoid cortex with the rongeur forceps. The cells may also be removed with the same instrument.

wise the focal centre of infection may not be exposed and the operation fail of its purpose. All cells should be opened, but not completely obliterated, as in the meatomastoid and radical operations.

The Irrigation of the Wound.—As the infective microörganisms in acute mastoiditis are usually quite active and virulent, and it is almost impossible to prevent them coming in contact with the soft tissues, it is a wise precaution to irrigate the wound with a 1 to 4000 bichloride solution

at about 100°. The external auditory meatus should also be scrubbed and irrigated with the same solution, care being exercised to avoid injuring the membrana tympani and dislocating the ossicles.

The Closure of the Cutaneous Wound.—As drainage must be maintained for several days subsequent to the operation, and the cavum tympani is not exposed by the operation, it is necessary to provide for drainage through the posterior wound.[1]

The cutaneous wound is not, therefore, completely closed at the time of the operation. The upper two-thirds is sutured as shown in Fig. 399, while the remaining lower third is left open for the introduction of the drainage tube and gauze.

Fig. 399

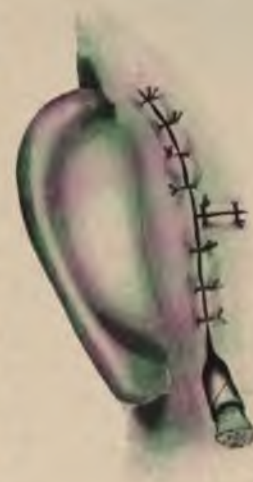

Method of closing the mastoid incision after the simple mastoid operation in acute mastoiditis. The spiral rubber tube and gauze drain in the lower angle of the incision prevent disfigurement.

The Dressing.—The object of the dressing is twofold, namely, to promote drainage and protect the wound from further infection while the process of repair is in progress. In order to accomplish the first object, the dressing should be so applied as to ensure free drainage. According to the author's experience, only so much gauze should be introduced into the depth of the bony wound as to carry off the secretions to the outer absorbent dressing. To pack the wound with gauze is poor practice, as the gauze becomes saturated with the secretions, retains them in the wound, where they bathe its walls, and retard the reparative process. On the other hand, if only a small wick of gauze is carried to the bottom of the bony wound the secretions are carried out as fast as formed, and the healing process progresses uninterruptedly and rapidly to recovery. The author's practice has been, therefore, to introduce a spirally cut, soft-rubber tube, with a small wick of gauze placed loosely in its lumen (Fig. 400), into the mastoid wound. After two years of such practice he is convinced that healing takes place more certainly and rapidly than it did in the cases previously dressed with gauze more or less packed into the wound. A small wick of gauze is also placed in the external auditory meatus. The outer absorbent and protective and absorbent dressing consists of gauze pads, 5 x 6 inches, placed over the auricle and mastoid wound, and held in position with a bandage applied in fan-shape or a half figure-of-eight.

The bandage should not be applied under the chin or around the neck, as it is uncomfortable and unnecessary.

In performing the simple mastoid operation for acute mastoiditis it is unnecessary to expose the external and auditory meatus, as is shown in the drawings. The drawings are thus made to show the anatomical landmarks for teaching purposes, and for reference in describing the radical and the meatomastoid operations for chronic mastoiditis.

The After-treatment.—The first dressing should be removed at the expiration of three days, the wound cavity gently mopped dry with a cotton-wound applicator, and another spiral tube dressing introduced. The meatus should also be mopped until freed of secretions, a fresh gauze wick applied, and the whole covered with gauze pads, as at the first dressing. The suture should be inspected before redressing the wound, and if stitch abscesses are present the sutures should be removed. If the wound is healthy, they may be left in position until the fourth or fifth day. The wound should be dressed daily as described, until the secretion diminishes to a small amount, after which the tube should be

Fig. 400



Rubber drainage tube cut spirally with a wick of gauze. This is the only dressing used by the author in his mastoid wounds. The usual gauze and cotton dressing are placed externally over the tube dressing. The spiral cut provides for drainage the whole length of the tube.

omitted and only a small wick of gauze introduced. The cavity will then rapidly fill in from the bottom with healthy granulation tissue, and at the end of from three to six weeks be entirely healed with a slight depression at the lower angle of the wound.

In exceptional cases infection of the labyrinth, sinus thrombosis, etc., may develop subsequent to the operation and modify the course of the reparative process, or even necessitate the adoption of other surgical procedures hereinafter described.

CHRONIC MASTOIDITIS.

Chronic mastoiditis, which has resisted simple methods of treatment, has, during the past fifteen years, been chiefly treated by the radical mastoid operation. Two years ago Charles Heath, of London, called attention to the brilliant results he obtained by a less radical procedure, whereby the hearing was greatly improved and the disease apparently cured. Since then the author has performed twelve meatomastoid operations with good results. Köerner, Stacke, and others previously described an operation similar to that described by Heath. My method differs from theirs, in that I make a complete exenteration of all the pneumatic cells of the temporal bone, as in the radical operation, and I call the method the meatomastoid operation. The (*a*) radical and the (*b*) meatomastoid operations will, therefore, be described as remedial measures for the cure of chronic mastoiditis.

The Radical Mastoid Operation. — **Technique.** — The patient is prepared as for the simple mastoid operation in acute mastoiditis. The mastoid antrum and cells are exenterated as in the simple operation in acute mastoiditis. (See Simple Mastoid Operation, Figs. 390 to 398.)

The Removal of the Posterior Wall of the Bony Meatus.—Having completed the exenteration of the mastoid antrum and cells, the posterior wall of the bony meatus is removed with a chisel, as shown in Fig. 401. In the removal of this wall there are certain anatomical structures which may be injured if due care is not exercised to avoid them. These structures are the facial nerve, the external or horizontal semicircular canal (Fig. 401), and the dura of the middle fossa of the skull. The facial nerve emerges from the petrous portion of the temporal bone and passes backward along the superior margin of the inner wall of the cavum

Fig. 401

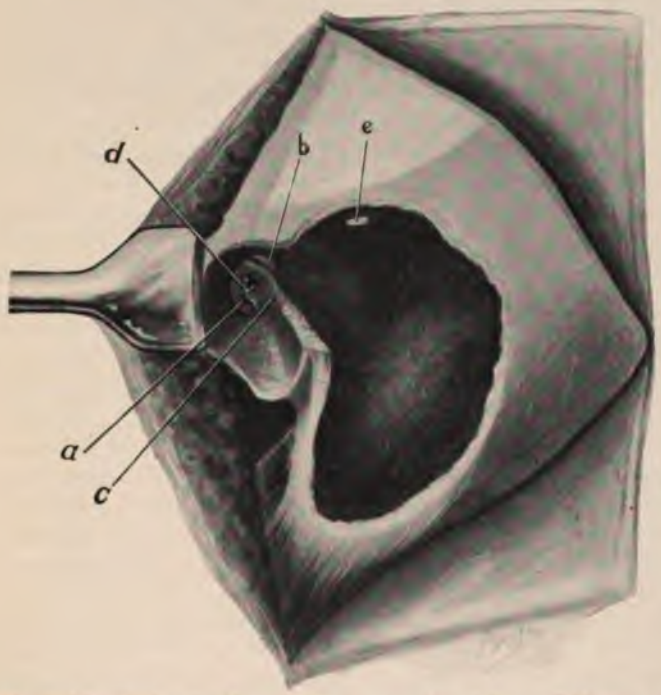

The anatomical landmarks after the complete exenteration of the mastoid process and cavum tympani. *a*, the round window; *b*, ridge of horizontal, semicircular canal; *c*, the facial ridge; *d*, the stapes in the oval window; *e*, the dura of the middle fossa exposed through a perforation in the tegment antri.

tympani just above the oval window. It then courses downward across the inner and inferior wall of the aditus ad antrum, immediately below the upper and deeper portion of the bony wall of the meatus (Fig. 401 *c*). From thence it passes downward, deeply buried in the plate of bone forming the posterior wall of the auditory meatus, and emerges just anterior to the styloid process. The nerve is most liable to injury in removing the posterior meatal wall directly over the aditus ad antrum, as it is only protected in this area by a thin but dense bony covering. Should the chisel by any mischance cross the space of the aditus ad antrum

(channel of communication between the cavum tympani and the mastoid antrum) to its inner and inferior wall, across which the facial nerve passes, facial paralysis may follow. In the removal of the posterior wall of the meatus the more superficial parts may be removed without fear of damaging the facial nerve, while the deeper portion should be removed with due regard to the facial nerve which passes through it.

After the facial nerve crosses the floor of the aditus ad antrum it turns sharply downward and emerges near the styloid process. As it makes the bend (Fig. 401 *c*) it rises almost to the level of the anterior portion of the annulus tympanicus, to which the membrana tympani is attached. It is obvious, therefore, that the lower portion of the posterior wall of the meatus cannot be removed deeper than the annulus tympanicus without injuring the facial nerve.

To recapitulate: The upper portion (erect position) of the posterior wall of the meatus may be removed in its entirety, or down to the aditus ad antrum, whereas the lower portion should only be removed down to the level of the annulus tympanicus or drumhead. The complete removal of the wall, in so far as it is compatible with the integrity of the facial nerve, is shown in Fig. 401. In the meatomastoid operation the removal does not include the annulus tympanicus. When completely removed, the upper bony wound extends inward at almost right angles to the lateral plane of the head, whereas the inferior bony wound extends inward and upward at an acute angle to the lateral plane of the head.

Another important anatomical structure in the immediate vicinity of the facial nerve as it crosses the floor of the aditus ad antrum is the external or horizontal semicircular canal (Fig. 401 *c*). It is located a little above and behind, and more superficially, than the facial nerve at this point. The precautions taken to avoid injury to the facial nerve will at the same time protect the semicircular canal. Indiscriminate curettage of the inner wall of the cavum tympani (middle ear) may injure either the facial nerve, the semicircular canal, or the stapes and oval window (Fig. 401 *d*).

All these structures should be constantly held in mind during the removal of the posterior bony wall of the meatus. The dura of the middle fossa (Fig. 401 *e*) is in but slight danger of exposure, and even when exposed the danger of infection is slight, as the pathogenic microörganisms of chronic infection are but moderately virulent. One of the greatest objections to the radical mastoid operation is that the hearing is usually impaired by it, especially after a period of one year. The impairment of the hearing is due to two factors, namely: (*a*) to the displacement of the foot plate of the stapes in the oval window (Fig. 401 *d*) at the time of the operation, and (*b*) to the gradual displacement and fixation of the foot plate of the stapes by cicatrices and contraction subsequent to the operation. On the other hand, it is claimed that the radical operation is justified, because in many cases it is the only known procedure that will cure the chronic otorrhea and protect the patient from the dangers incident to such a pathogenic process in the temporal bone. Life insurance companies have justly refused policies to persons affected with

chronic otorrhea, and have granted them when an aural surgeon of repute made a written statement that they were cured by the radical operation.

With these facts in mind, the radical mastoid operation has been and is still a justifiable procedure in properly selected cases. It is important, however, that the surgeon should take every precaution in the performance of the operation to preserve the hearing as much as possible, consistent with the safety to the life and health of the patient. In order to do this, the stapes and the oval window should be respected in the performance of the operation. Furthermore, the extraction of the stapes from the oval window opens an avenue of infection to the labyrinth, which, if it occurs, means the almost certain loss of hearing in the ear under operation. Fortunately, infection has rarely occurred when this accident has happened in the course of the radical operation, as the infective bacteria are usually of low virulency.

The removal of the posterior bony wall of the meatus converts the cavum tympani, mastoid antrum, and the mastoid cells into one large irregular cavity (Fig. 401), which is easily drained, and if the plastic surgery of the meatal skin-flaps is properly executed, results in a cure of the disease in more than 85 per cent. of the cases.

The Removal of the Malleus and Incus.—The removal of the malleus and incus, or their necrotic fragments, is an essential part of the radical operation, as it has been held that if they are left in position the attic of the middle-ear cavity will not be sufficiently drained. This is true to a degree, as the bodies of these bones partially form the floor of the attic, and their presence interferes somewhat with the exit of the secretions from the attic or upper portion of the cavum tympani. Furthermore, the complete removal of the bony partition involves the fracture and removal of a portion of the annulus tympanicus, to which the membrana tympani is attached. This, in addition to the fact that the incus, the long process of which projects backward into a sulcus of the bone forming the wall of the aditus ad antrum, would, in many instances, be dislocated and thus rendered useless as a functionating mechanism of the ear.

For these reasons the malleus and incus should be removed in performing the radical operation, and the stapes left *in situ*.

The *technique* of the removal of the malleus and incus is comparatively simple if the skin incision or incisions have been sufficiently extended to allow the complete exposure of the auditory meatus and cavum tympani. The primary skin incision (Fig. 387 *a a'*) should, at its upper limit, extend one-half inch more anteriorly than in the simple mastoid operation. This will allow the auricle to be retracted far enough forward to expose the meatus and cavum tympani.

When the posterior bony wall of the meatus is removed, the middle-ear cavity should be packed with cotton saturated with a 1 to 2000 solution of adrenalin chloride to check the hemorrhage. After the lapse of five minutes it should be removed and the contents of the cavum tympani inspected. The manubrium or handle of the malleus should

be seized with small alligator forceps (Fig. 402), dislocated downward, and removed. The incus should be likewise removed. Both ossicles

Fig. 402

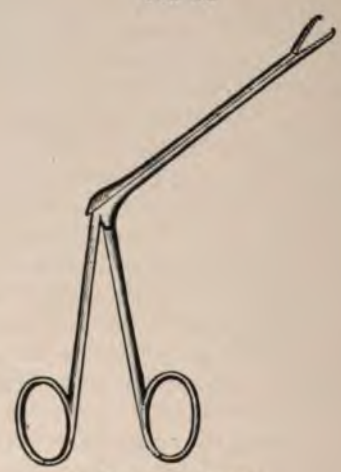

Noyes' ear forceps.

Fig. 403

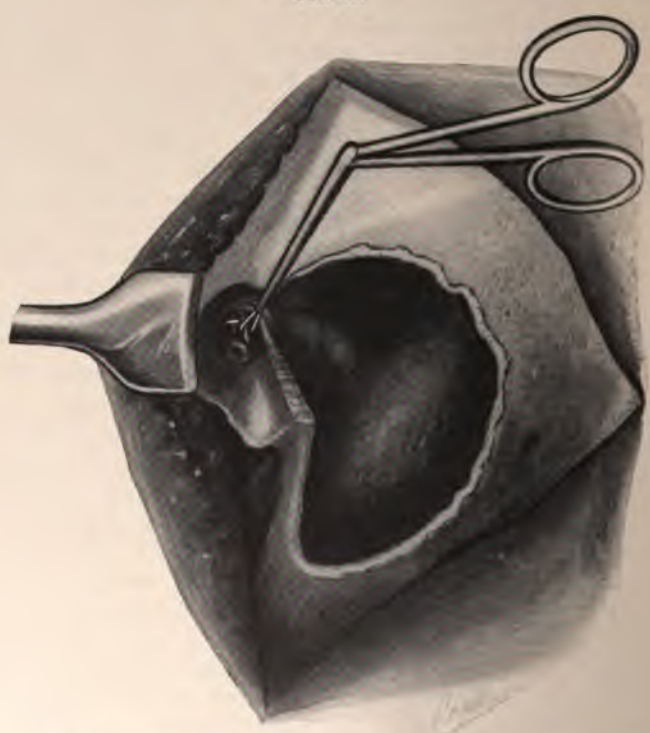

The removal of the malleus and incus in the radical mastoid operation.

may be removed with a small curette, though the danger of dislocating and extracting the stapes is thereby increased (Fig. 403).

The Removal of Necrosed Bone from the Cavum Tympani.—Necrosis of the tegmen tympani (roof of the attic) is present in a majority of the subjects of chronic mastoiditis, a fact which gives color to the claim that the radical operation should always, or at least usually, be performed in these cases. This phase of the subject will be more fully discussed under the meatomastoid operation in chronic mastoiditis.

Fig. 404

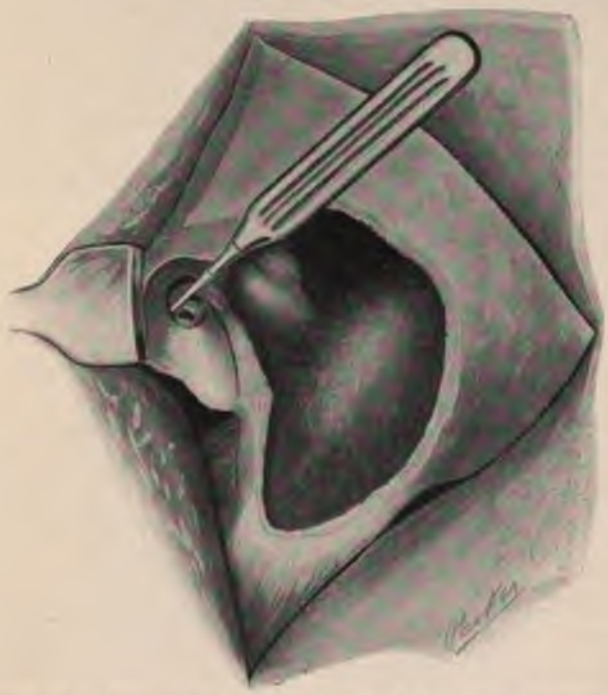

The curettage of the tympanic end of the Eustachian tube to cause it to close. A small burr or curette should be used to reach the isthmus of the tube.

All necrosed tissue in the tegmen tympani, or elsewhere in the walls of the cavum tympani, should be carefully but thoroughly removed with a small, sharp curette. The region of the oval window and the promontory, as well as the external semicircular canal, should be inspected, under adrenalin, with a strong reflected light for necrosed bone and granulation tissue, and, if found, the proper surgical procedures should be instituted to remove the conditions of the labyrinth which the necrosis and granulations indicate are present. (See Surgery of the Labyrinth.)

The Curettage of the Eustachian Tube.—Many failures attending the radical mastoid operation are attributed to the infected and purulent discharge from the tympanic end of the Eustachian tube into the cavum

tympani, subsequent to the operation. With this fact in view, it has been recommended that the tympanic end of the tube should be curetted, or burred out, to promote its closure by granulation tissue and cicatricial contraction (Fig. 404). The author has repeatedly performed this procedure, with an almost unbroken record of failures. He attributes the failures to the fact that in nearly every instance the suppuration within the tube had its origin either in a chronic epipharyngitis or a chronic ethmoidal and sphenoidal infection, to which the pharyngitis is often due. It may also have been due to the fact that too large a burr was used. To be successful, the burr should be small enough to reach to the isthmus of the Eustachian tube. If the sinus disease and epipharyngitis were first corrected, the curettage of the Eustachian tube would almost invariably result in its permanent closure.

The Plastic Surgery of the Cutaneous Meatus.—The success of the radical mastoid operation often largely depends upon the proper use of the skin of the auditory meatus in lining the bony cavity of the mastoid wound. The bone of the mastoid process is frequently sclerosed, and

Fig. 405

Curved flat scissors.

affords scant soil for the formation of granulation tissue with an epidermal covering. The granulation tissue in such subjects is poorly nourished, as the blood supply from the underlying bone is scant, and infection, therefore, often occurs. The reparative process is thus hindered, and the after-treatment may be extended over a period of several months. This deplorable state of affairs may be largely overcome by the proper disposition of the meatal skin-flaps against the bony walls of the mastoid wound. The plastic flaps thus reflected become adherent to the walls of the mastoid wound, and thus immediately cover a large portion of the bone which would otherwise have to depend upon the reparative granulation tissue, springing from the bone In addition to this, the full blood supply of the meatal flaps ensures the rapid extension of granulation tissue from their edges. The scant blood supply from the sclerotic bone of the mastoid process is thus complimented by that of the meatal skin-flaps, and a speedy regeneration and epidermization of the entire mastoid wound may be confidently expected. In exceptional cases it will be necessary to resort to plastic skin-flaps from the margins of the mastoid

wound, or upon Thiersch grafts, as recommended by Charles Ballance. (See Thiersch Grafts.)

The *technique* of the formation and application of the plastic flaps of the meatus to be described is in the main after the method recommended by Ballance. The form of the flaps is after Ballance, while the method of suturing to hold them in position is, so far as the author knows, original with him.

Before making the incision in the meatus all the tissue on the posterior surface of the cutaneous meatus should be removed with short, stout,

Fig. 406

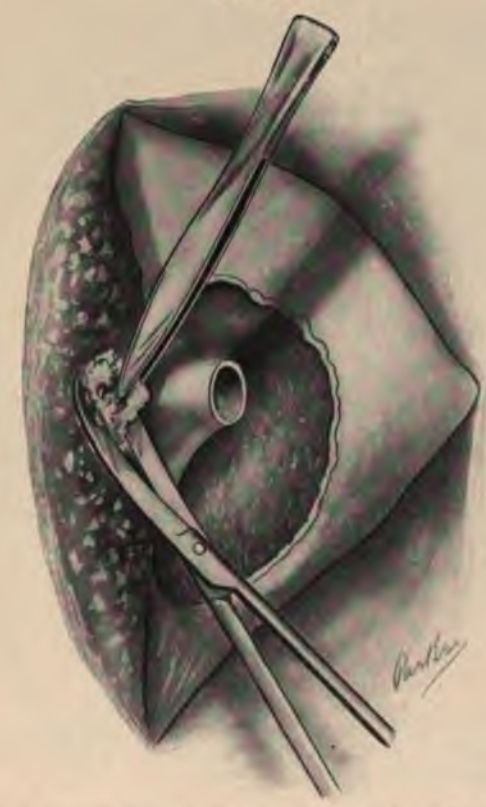

Removing the fibrous and muscular tissue from the posterior surface of the cutaneous meatus and concha, preparatory to making the plastic meatal flaps.

curved scissors (Fig. 405). This should be carried to the extent shown in Fig. 407, which shows the whole of the meatus and a portion of the concha divested of all tissue except the cartilage of the concha. The skin of the concha is included in the plastic flaps. This extensive removal of all the tissues covering the posterior half of the meatus and a portion of the concha is essential, because by so denuding them the meatal flaps can be more perfectly and extensively applied to the bony

walls of the mastoid wound. It is obvious that the meatal flaps, with the thick, tendinous, fibrous, muscular, and cartilaginous tissues attached to them, could not be properly reflected and adapted to the walls of the mastoid wound.

Having prepared the meatus and concha as described in the preceding paragraphs, and as shown in Fig. 407, the Ballance incision, sometimes referred to as the "shepherd's-crook" incision, should be made. While it is by no means as easy to do as might be inferred from the schematic

Fig. 407

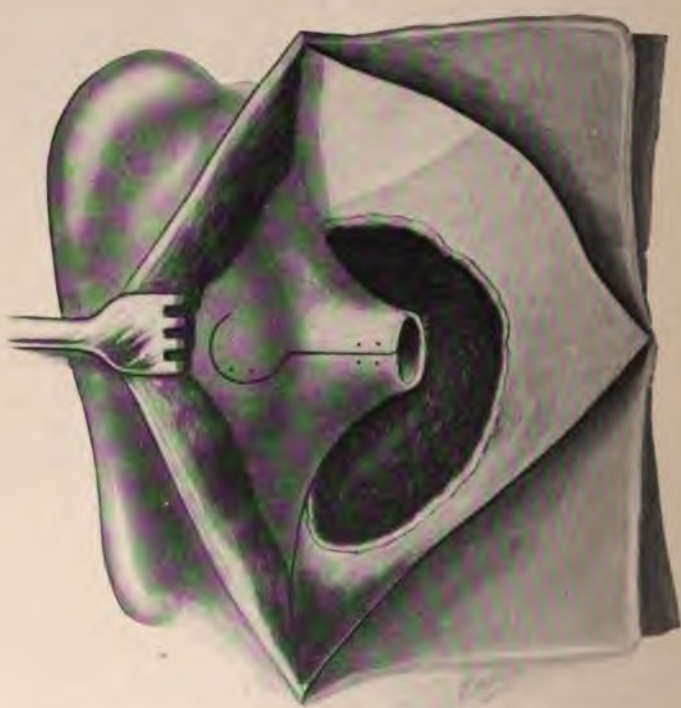

The Ballance incision. The straight portion is made in the posterior inferior portion of the meatus, and the curved portion in the concha. The curved portion should be made from the anterior aspect of the concha (Fig. 410).

drawing, it is nevertheless comparatively easy if the superfluous tissue is removed as recommended. The blades of a slender divulsion forceps (Figs. 408 and 409) should be introduced into the meatus with its tips at the inner end of the meatal tube. The blades should be spread, to put the meatal tube upon a slight tension. The blades of the divulsion forceps should be so placed as to have the open space between them at the posterior inferior segment of the tube, as the straight incision should be made through this portion of the meatus, while the curved portion is made from the anterior surface of the auricle, as shown in Fig. 410. If the

cartilage of the conchal portion of the upper flap has not already been removed, it should be done at this time.

Ballance stitches the flaps to the posterior fleshy surface of the anterior or auricular flap. According to the author's method the plastic meatal flaps are anchored to the posterior mastoid flaps, as shown in

Fig. 408

Allport's meatus divulsor.

Figs. 411, 412 and 413. Two sutures are used in the superior meatal flap, one in the conchal portion, and one in the meatal portion. Only one suture is used in the abbreviated inferior meatal flap (Fig. 412). One thread of each suture is introduced beneath the skin and subcutaneous tissue of the posterior mastoid flap for a distance of three-quarters

Fig. 409

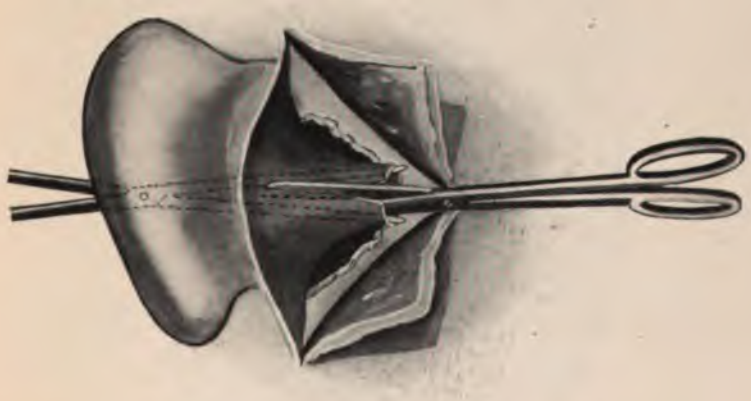

Showing the method of splitting the posterior wall of the skin meatus to convert it into flaps for reflecting into the upper and lower portions of the mastoid bone cavity to promote rapid and complete epidermization of its surface after the radical mastoid operation.

of an inch, and then through these tissues to the surface of the skin. The other thread of each suture is placed in the primary mastoid incision (Figs. 411, 412 and 413). Before piercing the mastoid skin with the sutures the auricle and mastoid flaps should be placed in their proper relations to the head, and traction should be made upon each suture until

Fig. 410

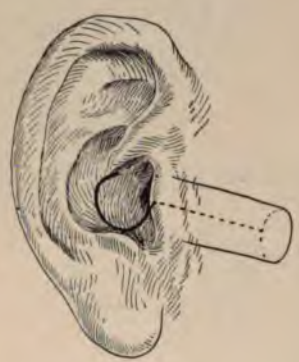

Fig. 411

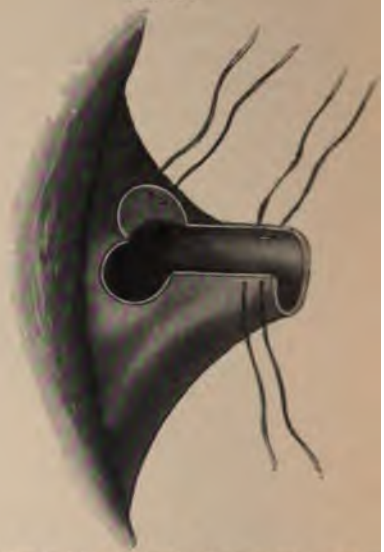

Fig. 410.—The Ballance plastic meatal incision. The incision begins in the posterior wall of the meatus (straight dotted line) and extends into the concha in the form of a shepherd's crook.

Fig. 411.—The plastic flaps slightly retracted with the anchor sutures in position.

Fig. 412

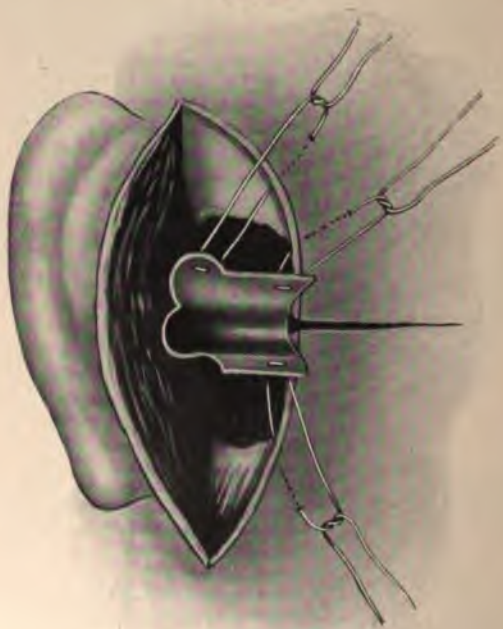

The plastic meatal flaps with the anchor sutures in position. When the auricle is placed in its proper position and the anchor stitches are drawn over the rolls of gauze (Figs. 413 and 414) the plastic meatal flaps will partially line the mastoid wound.

the flaps assume the proper position in the mastoid wound. The conchal suture should be thus tested and its location determined. The meatal suture of the superior meatal flap should next be tested, and, finally, the inferior meatal suture similarly tested, the flaps properly located, and stitches in the posterior mastoid flap placed accordingly. The ends of the sutures should then be secured with artery forceps until the mastoid incision is completely closed by sutures. The anchor sutures should then be tied over small rolls of gauze (Figs. 413 and 414), beginning with the upper, and thence to the lower ones, until the flaps

Fig. 413

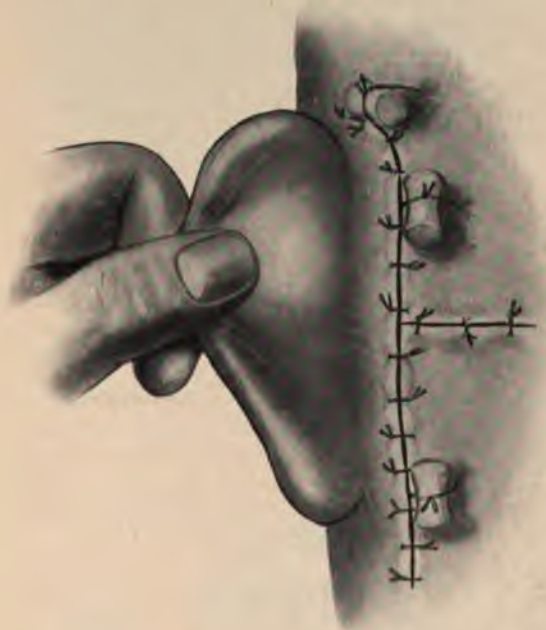

The postauricular incisions closed, and the anchor sutures tied over small rolls of gauze. The anchor sutures retract the plastic meatal flaps into the mastoid wound when they become adherent and partially cover the bony surface with true skin. The whole surface is finally covered by extension from the borders of the plastic flaps.

assume the desired positions in the mastoid wound. The upper flap is drawn against the roof of the mastoid wound while the lower flap is drawn over the facial bridge. The bony walls being removed, and the cutaneous flaps reflected into the mastoid cavity, and permanent free drainage and ventilation of the middle-ear and mastoid cavities thereby assured, the dressings may be applied *via* the external auditory meatus, as shown in Fig. 414. Other methods of making the plastic meatal flaps are shown in Figs. 415 to 420.

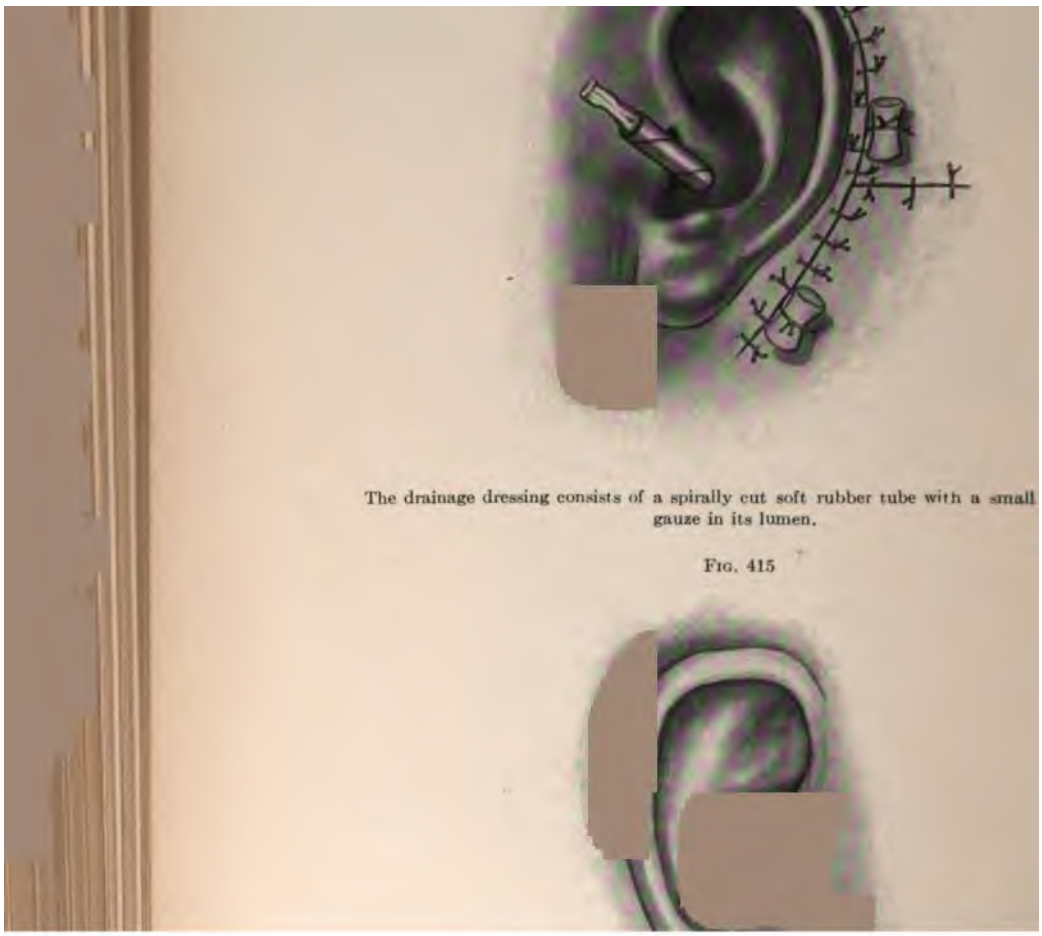

The drainage dressing consists of a spirally cut soft rubber tube with a small gauze in its lumen.

FIG. 415

gauze are inserted through the enlarged meatal opening in the concha (Fig. 414) instead of through the postauricular wound. The distal end of the tube is placed into the deepest portion of the mastoid wound.

Fig. 416

Showing the Troutmann tongue flap, which should be reflected into the mastoid wound and held in apposition to its posterior surface by small pledgets of gauze packed over cargile membrane. Remove the gauze in forty-eight hours.

This should be removed on the fifth day, or earlier if the temperature persistently remains above 101°, or if severe pain develops and persists. The wound should be mopped dry with a cotton-wound applicator, inspected for exuberant granulations, and a fresh sterilized tube and gauze inserted. If exuberant granulations are present, they should be reduced by painting them with carbolic acid, and, after the lapse of

Fig. 417

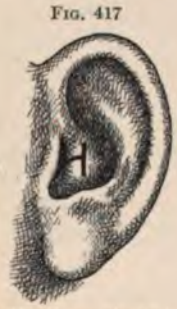

Fig. 418

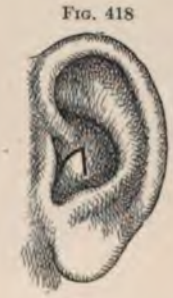

Fig. 417.—The Pause plastic incision of the meatal skin.

Fig. 418.—The Jansen-Stacke plastic incision. This flap should be used when the sigmoid sinus and jugular bulb are exposed. The flap is turned downward and backward and thus covers these areas.

one minute, with alcohol, to check the action of the acid. This method of treatment should be continued daily for ten days after the operation. After this the tube may be abandoned and a small wick of gauze inserted

into the wound at its most dependent portion and extended to the concha. Small gauze pads should be placed in the concha of the auricle

Fig. 419

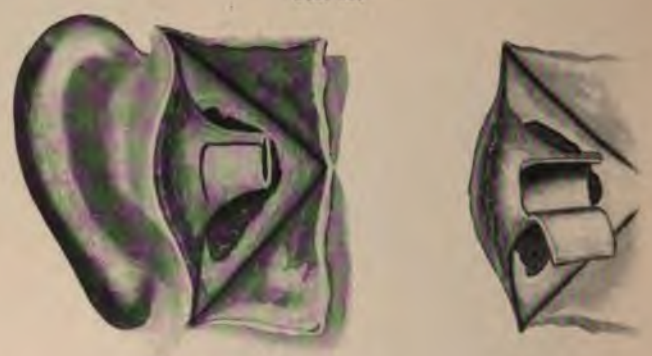

Showing the method of making the Jansen modification of the Stacke plastic flap of the skin meatus. The inferior large flap should be reflected into the lower portion of the mastoid wound and held in place by anchor stitches. The upper short flap should be reflected into the upper portion of the mastoid wound and held in place by an anchor stitch.

Fig. 420

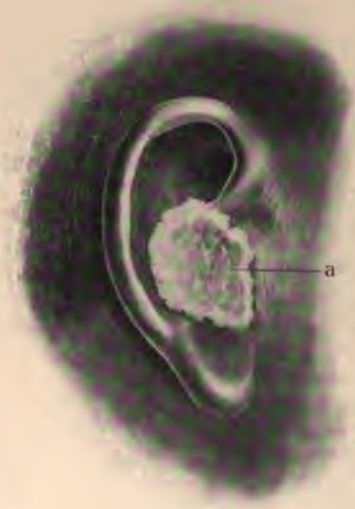

Fig. 421

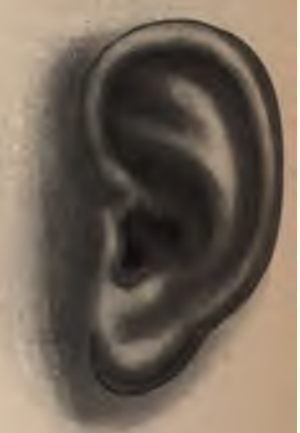

Fig. 420.—A collodion dressing used in the after-treatment of operative mastoiditis. A loose wick of gauze is inserted into the mastoid wound through the external meatus and covered with a film of cotton, which is then saturated with an ether solution of collodion to seal it.

Fig. 421.—The appearance of the concha and external auditory meatus, after healing is complete.

to catch the secretions drawn out by the gauze wick. Large pads are placed over the auricle and mastoid region and secured with the fan-shaped bandage. After the tenth day the large gauze pad and bandage

may be omitted and the dressing applied in the cavity of the auricle instead. This should be secured in place by putting a thin film of cotton over it (Fig. 420) and painting it with an ethereal solution of collodion (Pierce). The mastoid wound usually becomes covered with squamous epithelium in from three weeks to two months, though the process may cover a longer period of time. Various factors may cause a prolongation of the period of repair, chief of which are suppurative inflammation of the epipharynx, ethmoiditis, sphenoiditis, and a secondary

Fig. 422

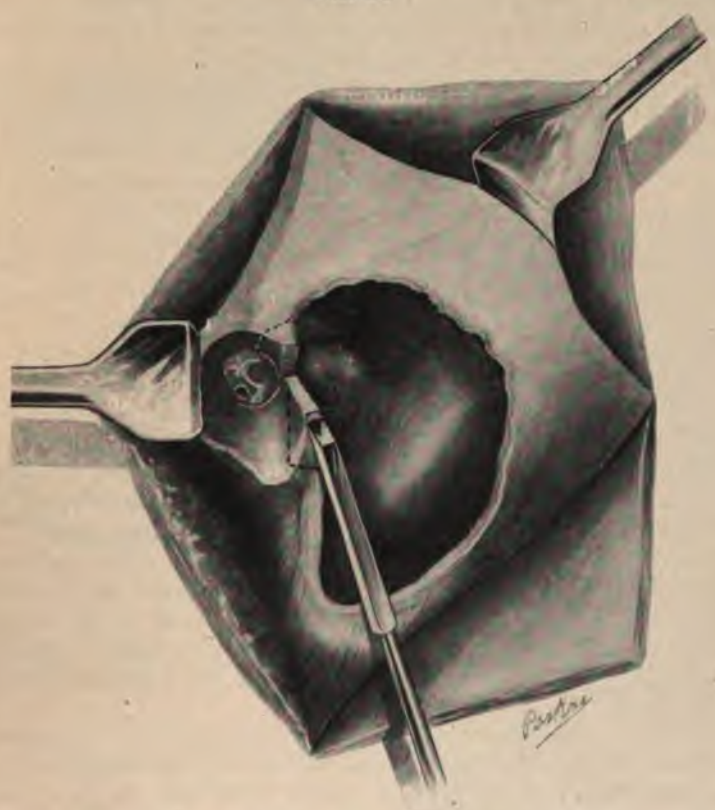

The removal of the posterior wall of the external auditory meatus down to the annulus tympanicus in the meatomastoid operation. Dotted lines indicate the amount to be removed.

infection of the Eustachian tube. Certain constitutional dyscrasias, as syphilis, tuberculosis, and struma, may also lower the vitality of the tissues and prolong the reparative process.

The disfigurement following the Ballance plastic meatal flaps is slight (Fig. 421). It should be said, however, that chondritis of the auricle with marked shrinkage and deformity may follow any of the plastic operations which include the cartilage of the concha. Every effort should be made to prevent the infection of the wound either during or after the operation.

The edges of the conchal wound should be touched with carbolic acid to seal up the lymph spaces.

The Meatomastoid Operation.—This operation may be called a modified radical mastoid operation, though it does not include the exposure of the middle ear. It does, however, include the plastic meatal flaps and the removal of the posterior bony wall of the meatus down to the annulus tympanicus. The postauricular wound is closed as in the radical operation, and the dressings are applied through the concho-meatal wound.

The advantages claimed for this operation over the radical operation in chronic mastoiditis are: (*a*) The preservation of the function of the middle-ear contents, and of the membrana tympani; (*b*) an improvement in the hearing, whereas in the radical operation the hearing is either unchanged or impaired; (*c*) the perforation in the membrana tympani cavity often closes, after the necrosis and granulations have disappeared; (*d*) the secretions from the antrum and mastoid cells drain into the auditory meatus through the opening in the posterior wall of the meatus, thus relieving the Eustachian tube of the excess of secretions.

The principle upon which the operation is based is, that, *if ample drainage is provided the infectious process tends to subside.* The removal of the posterior wall of the bony auditory meatus and the retraction of the plastic meatal skin flaps into the mastoid wound provide for the drainage of the mastoid antrum and cells, and thus remove the stress from the Eustachian tube. The Eustachian tube being relieved is usually ample to drain the cavum tympani, even when chronically infected. As a result, the resistance of the diseased membrane, periosteum, and bone is increased, and the infection gradually subsides. The mucous membrane, periosteum, and bone become healthy and "heal out."

Heath claims that the removal of the fragments of the malleus and incus often disturbs the relation of the stapes to the fenestra vestibuli (oval window), and thus impairs the hearing. That is, the stapedius muscle pulls the stapes backward and displaces the foot plate of the stapes in the window. This could also be obviated in the radical operation by severing the tendon of the stapedius muscle.

The reported cases have been so few in number that it is impossible to estimate the place the operation should have in the surgery of chronic mastoiditis. The results thus far reported have been so good, and the principle upon which the operation is based appears so rational, that the technique of the operation is herewith given.

Technique.—(*a*) Prepare the patient as for the simple and radical mastoid operations.

(*b*) Expose the mastoid antrum and cells as in the radical operation.

(*c*) Remove the posterior bony wall of the auditory meatus down to the annulus tympanicus, as shown in Fig. 422. At no time during the operation should the membrana tympani and the ossicles of the cavum tympani be injured by probing or other instrumental procedure. The introduction of a probe into the meatus to determine its depth and direction, as recommended in the radical operation, should be studiously

avoided. If this precaution is not observed, the ossicles may be dislocated and the hearing impaired. The posterior wall of the meatus should be removed as widely as possible so as to provide free drainage and access

Fig. 423

Author's meatal flap retractor.

to the exenterated antrum and cells through the auditory meatus during the after-treatment. It is sometimes necessary to remove some bone from the superior wall of the meatus. Enough bony tissue should be removed

Fig. 424

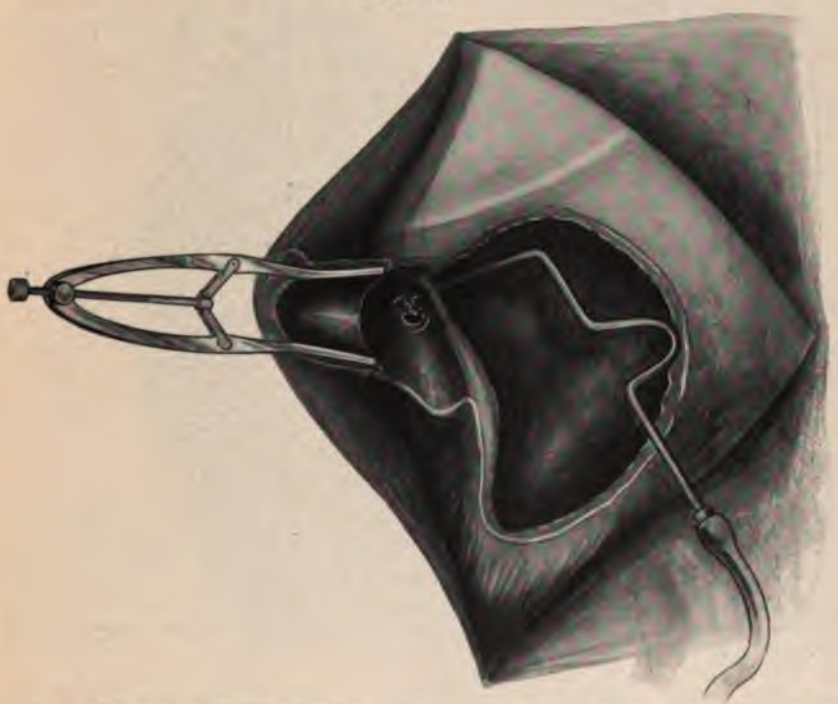

The meatomastoid operation complete. The curved cannula is inserted into the aditus ad antrum, preparatory to blowing a blast of air through the cavum tympani, to remove the secretions and debris. The author's meatus retractor makes the view of the membrana tympani possible during this procedure.

to fully expose the membrana tympani to inspection after the auricle is replaced and sutured in position. The proper prosecution of the after-treatment will largely depend upon the completeness with which this step of the operation is carried out.

(*d*) The plastic meatal flaps should now be formed as in the radical operation. The operator's individual preference may be used, though it is essential that the skin of the concha be included in the flaps, so as to enlarge the meatal opening and facilitate the application of the dressings to the mastoid wound and the inspection of the membrana tympani. Personally, I have found the Ballance incision the most satisfactory for this purpose. The reader is referred to Figs. 406 to 419 for the details of the various plastic meatal flaps, with the suggestion that in applying them to this operation they should be so utilized as not to obstruct the opening made by the removal of the posterior bony wall of the auditory meatus.

Fig. 425

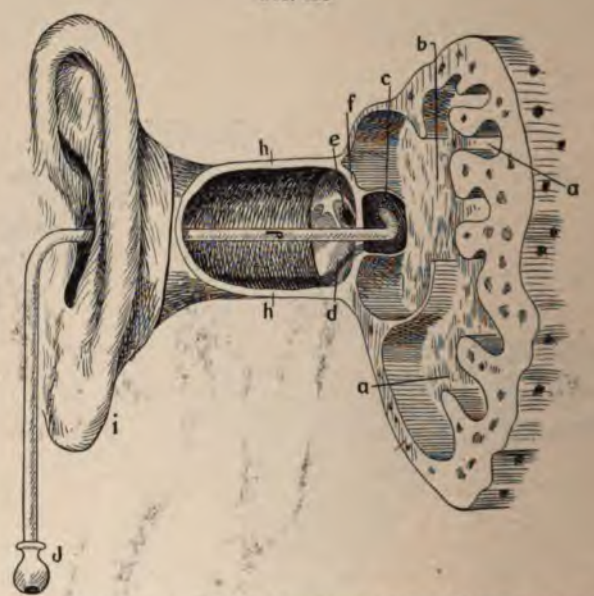

Schema of the ear showing the method of cleansing the tympanic cavity after the meatomastoid operation. *a a*, mastoid cells; *b*, antrum; *c*, aditus ad antrum; *d*, membrana tympani; *e*, perforation in the membrana tympani; *f*, annulus tympanicus; *h*, external meatus, the posterior wall of which is removed; *i*, the auricle; *j*, silver cannula introduced through the opening in the posterior opening in the meatus, and thence forward into the aditus ad antrum *c*; air pressure applied with a rubber bulb forces the secretions, granulations, etc., from the tympanic cavity through the perforation (*e*) in the membrana tympani into the meatus.

(*e*) Retract the meatal plastic skin-flaps with the author's retractor (Fig. 423) to bring the membrana tympani into view, as shown in Figs. 421 and 424. This will greatly facilitate the next step in the operation, as it is necessary to see the membrana tympani during its performance. If the meatal retractor is not used the meatal flaps will constantly obstruct the view and hinder the operator in his work.

(*f*) Insert a cannula, as recommended by Heath, into the aditus ad antrum *via* the antrum (Figs. 424 and 425), and, with an attached rubber

bulb, send blasts of air into the cavum tympani. The secretions and pedunculated granulations within the middle-ear cavity are thereby blown out through the perforation in the membrana tympani into the auditory meatus. The middle ear may also be irrigated with the same apparatus.

Fig. 426

Hajek's hand burr.

(*g*) If granulations or polypi are thus blown through the perforation, they should be grasped by small dressing forceps and removed. If they appear at the perforation, but do not protrude through it, they may be grasped by gently pressing the forceps blades (one on either side of the

Fig. 427

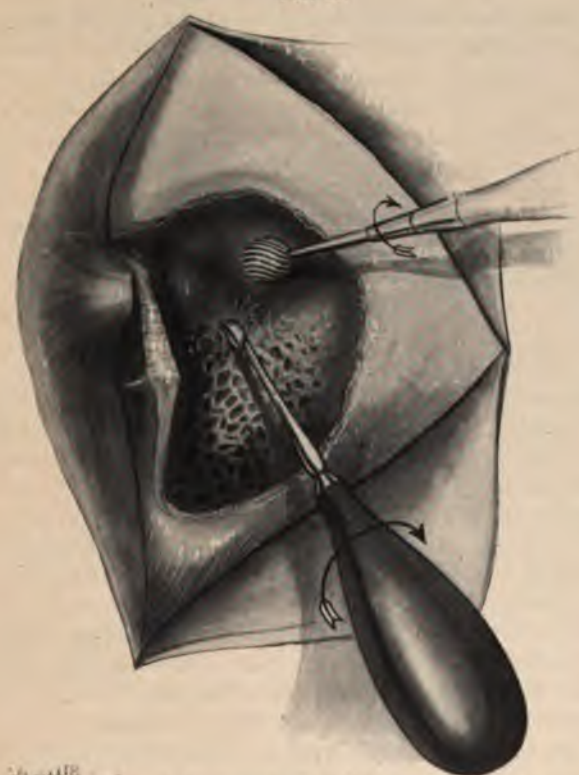

After the exenteration of the mastoid cells in chronic mastoiditis, the surface should be made smooth with a curette and burr, to promote rapid healing.

perforation) against the margins of the perforation, thus bringing them within the grasp of the forceps. The blasts of air should be repeated until all the secretions, polypi, and debris are expelled from the

tympanic cavity. Tubes of various sizes should be at hand, one being selected that fits the aditus ad antrum. If the tube is too small, it may pass so far into the aditus as to dislocate the incus and thus impair the hearing. It may be necessary to modify the shape of the antral aspect of the aditus with a small curette or hand burr (Fig. 426), to adapt it to the cannula.

(*h*) Having removed the secretions, polypi, and debris from the tympanic cavity with the air blasts and forceps, place a small wet pad of cotton over the perforation in the membrana tympani, and a small plug of the same material in the antral end of the aditus ad antrum, to keep the blood and bone chips from entering the middle ear.

(*i*) Anchor the plastic meatal flaps, as in the radical mastoid operation, with suitable stitches (Figs. 411 to 414).

(*j*) Close the postauricular incision as in the radical operation.

(*k*) Introduce the tube dressing (Fig. 414) through the auditory meatus into the mastoid wound. Do not place it against the membrana tympani, but pass it backward through the opening in the posterior wall of the meatus into the mastoid cavity. If other forms of dressing are preferred, they should be introduced in the same manner. Whatever dressing is employed, it should be loosely placed, not packed, as its primary purpose is to facilitate drainage. Some operators recommend that gauze be firmly packed into the mastoid wound to "keep down" the granulations. If the operation is thoroughly done, exuberant granulations will not form; furthermore, good drainage lessens the tendency to the growth of exuberant granulations. Exuberant granulations are the product of infection, whereas healthy granulation tissue is formed in the process of repair. Firmly packed dressings are contra-indicated because they obstruct drainage and prevent the regeneration of the tissue.

The ear should be covered by several large gauze pads, which should be removed in from three to five days, the wound gently dried with a cotton-wound applicator introduced through the auditory meatus, and a new loose dressing applied, which should be changed daily. The sutures should be removed on the fifth day.

The membrana tympani should be inspected daily, especially when the blasts of air are forced through the aditus ad antrum. After the mastoid wound is cleansed with the cotton-wound applicator the curved cannula should be introduced into the aditus *via* the meatus and the opening in the posterior wall of the meatus (Figs. 424 and 425) and blasts of air forced through the tympanic cavity to clear it of secretions and granulations. All granulations or polypi appearing at the perforation in the membrana tympani should be removed with forceps or with caustics.

The secretions and granulations from the middle ear gradually subside as the perforation closes. The mastoid cavity usually becomes filled with connective tissue, thus closing the aditus, or it becomes lined with epidermis and remains a dry cavity. In either event the Eustachian tube is no longer burdened with the secretions from it, but only has those from the middle ear to dispose of.

Of the twelve cases I have thus operated, all have healed and are

covered with epidermis. The mastoid wounds are almost filled in the process of repair. The membrana tympani reformed in three, the hearing returned to almost the normal in all.

Thiersch Grafts in the Mastoid Wound.—To Reinhard, Jansen, and Ballance belong the credit of applying the Thiersch grafts to the mastoid wound. Ballance has, perhaps, used it more constantly and frequently than anyone else, and his technique is generally followed. Personally the author has had but rare occasion to use it, as his cases usually became covered with epidermis in as short a time as is claimed by Ballance after the use of the Thiersch grafts. In only two cases has it been necessary to apply the grafts, and in these they were successfully applied after secondary operations. By using the Ballance plastic meatal skin-flaps, and fixing them as in Figs. 416 and 423, the author's cases have, with rare exceptions, healed with epidermis over the walls of the mastoid wound in from three to ten weeks, rarely longer. That this good showing is due to other factors than the plastic flaps in quite certain. It is due to several factors, chief among which are: (*a*) The Ballance plastic meatal flaps applied after the author's method. (*b*) The use of the spiral rubber tubing

Fig. 428

Thiersch's graft razor.

with a small wick of gauze in its lumen as the sole drainage dressing. The author is quite sure that tightly packed gauze in the wound interferes with drainage and favors the formation of unhealthy granulations, though other writers (Allport) claim to use firm dressings to prevent and to combat unhealthy granulations. The author does not use packed gauze dressings, nor does he have unhealthy granulations to contend with in 1 per cent. of his cases, and he therefore concludes that the loose dressing is in part responsible for the good results obtained. (*c*) Another cause of the rapid epidermization of the mastoid wound is the complete exposure and exenteration of the mastoid antrum and cells. The cells of Kirschner, between the antrum and meatus, and those in the posterior root of the zygoma are likewise carefully sought for, and if present are removed. It has been claimed that no operator can say he has removed all the mastoid and associated cells. This is not true, as there are many aural surgeons who can and do remove all in every radical operation if he so desires. Herein is another reason Thiersch grafts are not often required. (*d*) Rendering the edges and the surfaces of the bony mastoid wound smooth with a curette and burr also favors a rapid reparative process (Fig. 427).

If the surgeon finds that a considerable number of his cases pursue a prolonged course of healing, he should carefully scrutinize his technique, and, if found to be faulty at any point, improve it accordingly, and if his cases still refuse to heal properly he may try the Thiersch grafts.

Technique.—(*a*) The grafts may be applied at the close of the primary operation, ten days after the primary operation, or after a secondary operation. Dench applies the grafts at the close of the primary operation. Ballance ten days after the primary operation. The author only after secondary operations; that is, only after it is conclusively shown that repair will not follow the primary operation. Since adopting the technique described in the radical mastoid operation the author has not had more than 1 per cent. of cases requiring a secondary operation, whereas, in his earlier practice about 10 per cent. required secondary operations.

Fig. 429

Thiersch's graft spatula.

(*b*) The patient's arm or thigh should be shaved and scrubbed twenty-four hours before grafting, a moist carbolized dressing applied, and held in position with a bandage.

(*c*) The patient should be anesthetized for the reason that (1) it prevents the "goose-flesh" contraction of the skin, which so materially interferes with cutting thin Thiersch grafts, and (2) it also prevents the pain incident to securing the grafts and opening the wound for their application. If the grafting is done at the time of the primary operation, the patient is already anesthetized and the arm or thigh prepared when the mastoid region was shaved.

Fig. 430

Teasing needle for Thiersch grafting.

(*d*) Rescrub the skin after the bandage and dressing are removed.

(*e*) With the skin moistened with normal salt solution and drawn tight between the forefinger and thumb, remove the thin cortex of the skin with a rapid sawing motion with the broad Thiersch razor (Fig. 429). The razor is flat upon one side, while the other (the upper) is concave. Normal salt solution should be dropped into the hollow surface of the razor to float the graft. The size of the grafts should be about 2 x 3 cm., or large enough to cover the entire bony wound.

(*f*) Float the graft from the razor blade to the large spatula (Fig. 429), using a teasing needle in transferring it.

(*g*) The mastoid wound, having been previously opened and freed of all blood and oozing, is made the repository of the graft. With a teasing needle (Fig. 430) the edge of the graft is transfixed to the border of the

Fig. 431

The Thiersch graft being applied to the mastoid wound.

mastoid wound and the spatula gradually withdrawn. The graft is thus deposited smoothly and evenly over the surface of the wound. If necessary, other grafts are also applied.

Fig. 432

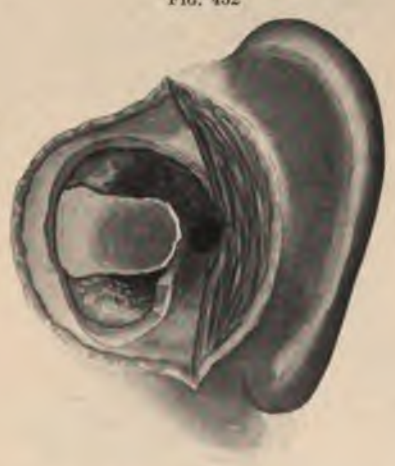

The Thiersch graft in position. Other grafts are introduced until the entire bony wound is covered.

(*h*) The grafts should be pressed against the walls of the wound with a small blunt instrument until they are closely adherent to their uneven surfaces (Fig. 432). A small glass pipette or medicine dropper may be

used to withdraw bubbles of air from beneath the grafts. Some operators prefer to first fill the mastoid cavity with normal salt solution and float

FIG. 433

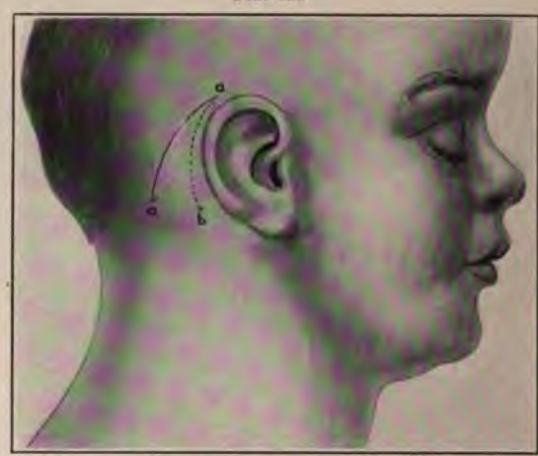

Mastoid incision in infants. *a a*, the proper location of the incision. The lower end of the incision should be about one-half inch posterior to its position, in adults in order to avoid injury to the facial nerve at its exit from the mastoid bone at *b*. *a b*, the usual location of the mastoid incision in children.

FIG. 434

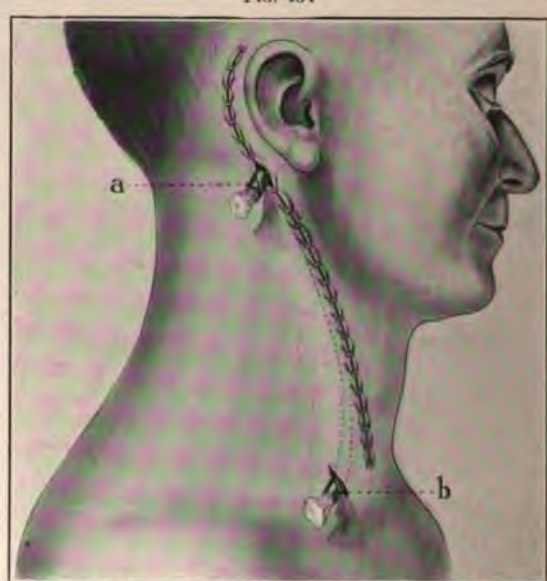

Bezold's mastoiditis. The wound is closed with Michel's metal clamps. *a*, spiral tube draining the mastoid wound; *b*, spiral tube draining the abscess of the anterior triangle of the neck. An accessory incision is used to drain the abscess, as this will heal quickly after the tube is removed. If the tube makes its exit at the lower portion of the primary incision, healing will be slow and a scar is left, as this is in the infected field. The portion of the incision below the mastoid also represents the incision for the excision of the external jugular vein and for the removal of the glands of the neck.

the graft upon its surface. The fluid is then gradually withdrawn with a pipette until the graft rests upon the surface of the bony wound. It is

Fig. 435

Allport's mastoid retractor.

Fig. 436

Jansen's mastoid retractor.

Fig. 437

Allport's bone-crushing forceps.

Fig. 438

McKernon's rongeur forceps.

not necessary to engraft the entire surface of the wound, as the interspaces soon become covered by extension from the edges of the grafts

(*i*) Ballance formerly covered the grafts with very thin gold-foil to prevent the small cotton pads adhering to the grafts and dislodging them when the dressing was removed. He now applies the cotton balls

Fig. 439

Jansen's rongeur forceps

Fig. 440

Curettes.

Fig. 441

Reverdin's needle.

Fig. 442

Malleable ear probe.

Fig. 443

Hotz's Aural applicator.

directly to the grafts, with good success. As a matter of fact, the grafts will remain in position, if properly adjusted (evenly and closely applied), without either gold-foil or the gauze pads. The postauricular wound

should be reclosed with sutures after the grafts are applied and the subsequent dressings applied through the enlarged auditory meatus.

(*j*) The small cotton balls are used to hold the grafts in apposition to the granulating bony wound, and they should be removed on the third day. Portions of the grafts will not "take" or grow, hence necrosis occurs, giving rise to a horrible stench. The engrafted area should be gently mopped dry with a cotton-wound applicator, the necrosed particles removed, and a fresh dressing applied. The dressing should be renewed daily, as after the mastoid operation.

Fig. 444

Scheibel's suture forceps.

Fig. 445

Michel's metal clamp suture.

Fig. 446

Michel's suture clip forceps.

Fig. 447



Sexton's ear knife.

It should be borne in mind, however, that Thiersch grafts will rarely be necessary if the cutaneous portion of the external auditory meatus is properly and intelligently utilized to line the mastoid wound, and if the cells are completely exenterated and the whole surface rendered smooth with a curette and burr.

The Mastoid Operation in Infants and Young Children.—As the mastoid tip and cells are but slightly developed before the age of puberty, the technique of the mastoid operation should be somewhat modified. The rudimentary tip of the mastoid process is located much higher and more posteriorly than in adults.

The postauricular incision should, therefore, begin higher and more posteriorly, as shown in Fig. 433. Furthermore, the facial nerve makes its exit from the styloid foramen quite near the surface, and, if the incision is made as in the adults, may be injured and result in facial paralysis. The mastoid antrum is almost or fully developed at birth, and is often the only portion of the mastoid bone involved.

The Surgical Treatment of Bezold's Mastoiditis.—The early surgical treatment is the only procedure that is applicable in this affection. The usual mastoid incision is made with an extension downward beyond the tip of the mastoid parallel with the anterior border of the sternomastoid muscle to the lowest portion of the brawny swelling of the neck. The

Fig. 448



Mastoid chisels and gouges.

aponeurosis of the sternomastoid muscle is divided and retracted. The mastoid is opened from below upward, toward the antrum. All the mastoid cells are thoroughly curetted until the perforation in its *inner plate* is located. The perforation is followed into the loose tissues of the neck, and the granulations removed with a dull curette. The rough projections of bone are smoothed with a burr or curette and the ragged edges of the muscles are trimmed off with scissors. If the abscess has burrowed into the neck anteriorly or posteriorly, it is necessary to lay it wide open and thoroughly remove all diseased tissue with a curette. The mastoid portion of the incision should then be closed, and a spiral tube with gauze in its lumen, the distal end of which is placed in the mastoid wound (Fig. 434). If the abscess extends into the neck, the incision should be closed over another spiral rubber tube, which is allowed to drain through a separate incision back of the lower end of the neck incision, as shown in Fig. 434.

The dangers attending this operation are the wounding of the facial

nerve at its exit from the bony canal in the mastoid process, and the spinal accessory nerve going to the traspezius muscle. If this nerve is wounded the shoulder will droop. The lateral sinus is also in close proximity to the perforation, hence great care should be taken in operating in this region.

If the disease is early recognized and prompt and thorough surgical measures are instituted the prognosis is fair, although the recovery may take several weeks, as the healing of the wound after such an extensive operation requires considerable time, and not infrequently a secondary abscess forms in the neck because of poor drainage.

NECROSIS AND SUPPURATION OF THE LABYRINTH.

The extent to which the labyrinth may be surgically exenterated is still to be determined by additional experience. That it may be successfully invaded within certain circumscribed areas has been already demonstrated. The dangers arising from the possible and probable extension of the infection from the labyrinth to the cranial contents are so grave that the surgeon is justified in opening the labyrinth, at least sufficiently to establish free drainage of the cochlea, vestibule, and the semicircular canals. The dangers attending the complete exposure of the two and one-half coils of the cochlea are so great that it is extremely doubtful if such an operation should ever be attempted. Richards, in a recent article, reported the complete exposure of the cochlea. He calls attention to the danger zones, or points of anatomical vulnerability, which should be carefully considered in performing the operation. In the description of the technique these zones will be more fully discussed.

General Technique.—As the suppuration and necrosis of the labyrinth is usually associated with and is secondary to mastoiditis, the preliminary stage of the surgical treatment of the labyrinth disease is the radical mastoid operation. Indeed, the disease of the labyrinth is often only discovered during the course of the mastoid operation, though if the functional tests of hearing were uniformly used in all cases of mastoiditis, previous to the operation, the disease of the labyrinth would nearly always be determined before beginning the mastoid operation. Richards reports cases in which the functional tests failed to indicate the labyrinthine disease. He does not, however, fully describe the nature of the tests employed, and the author is inclined to suspect that he is mistaken in his suggestions in relation to the unreliability of the tests, for it has been generally conceded that labyrinthine disease may with a fair degree of certainty be demonstrated by the functional tests of hearing when carefully and understandingly applied.

Richards very properly divides the labyrinthine cases into two classes, namely: (1) Those in which the horizontal (external) semicircular canal is alone necrosed, and (2) those in which the cochlea, vestibule, and semicircular canals are involved.

In the first class of cases the surgical treatment is quite simple, and does

not require special preparation of the surgical field. In the method he recommends a wider exposure of the petrous pyramid than is required in the radical mastoid operation. If the extensive exenteration of the cells which is recommended by him in extreme cases is to be performed, the exposure should be as shown in Plate XII, as a less extensive exposure would not allow the instruments necessary to successfully accomplish the work. If only the bony wall between the oval and round windows and the portion of the promontory covering the first or lower half of the first coil of the cochlea are to be removed, a less extensive exposure of the operative field will be required.

The Anatomical Landmarks.—The radical mastoid operation is first performed in the usual manner, the bony tissue of the sigmoid portion of the lateral sinus (Plate XII, [illegible]) being fully exposed [illegible] all cells and cancellous bone in front of and above its knee. The [illegible] above the knee and posterior to the antrum is completely exenterated, thus giving the necessary space for introducing the instruments in opening the canals [illegible]. A portion of the posterior zygomatic root and upper wall of the meatus are also removed to give better access to the semicircular canals and the petrous portion of the pyramid. The greater portion of the floor of the external auditory meatus is removed to expose the hypotympanic space. The anterior wall of the external auditory meatus is removed [illegible] to expose the cochlea in front and the anterior wall of the Eustachian tube [illegible] which should be removed. The [illegible] should also be [illegible]. As the carotid canal is immediately behind the posterior wall of the Eustachian tube, care should be exercised [illegible] [illegible]

THE SURGERY OF THE HORIZONTAL SEMICIRCULAR CANAL

[illegible]

PLATE XII

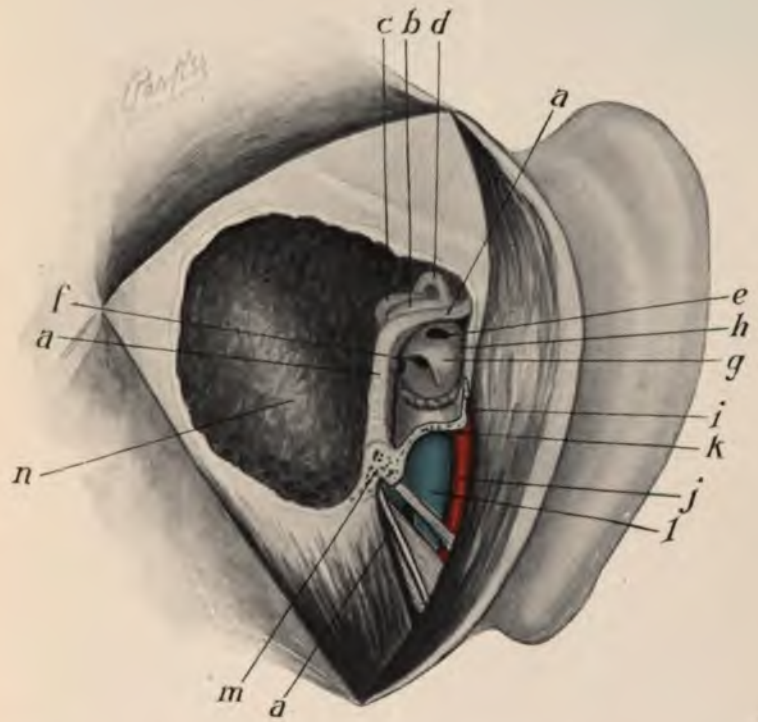

The Exposure Required for an Extensive Operation upon the Labyrinth.

a, a, a, the facial ridge and nerve; *b*, the horizontal semicircular canal; *c*, the oblique semicircular canal; *d*, the perpendicular semicircular canal; *e*, the oval window; *f*, the round window; *g*, the promontory; *h*, the tympanic end of the Eustachian tube; *i*, the fragment of the anterior bony wall of the meatus; *j*, the internal carotid artery; *k*, the remaining portion of the floor of the meatus, the deeper portion of the floor of the meatus has been removed to expose the hypotympanum; *l*, the internal jugular vein and bulb; *m*, a section of the bone covering the facial nerve; *n*, the sigmoid portion of the lateral sinus.

Technique.—The carious wall of the canal may be removed with a sharp curette, due precautions being taken to avoid the ridge of the facial canal (*a, a, a*), which is situated just below and anterior to the carious wall of the semicircular canal. The curette should be directed backward and upward away from the facial ridge. Richards prefers to remove the diseased area with a small sharp chisel, the cutting edge of which is placed well above the facial ridge and is directed upward and inward to prevent fracture of the facial canal. Bourguet's method of opening the horizontal canal is, perhaps, the safest and best. He has devised an instrument (Fig. 449) for the protection of the facial nerve during the procedure for the opening of the canal. The instrument is provided with a semilunar plate, 3 x 2 mm. in size. The convex border of the plate has a heel or toe projecting from it somewhat like the toe of a horseshoe. The heel or toe is inserted into the oval window, while the convex border of the plate is directed upward. The body of the plate is thus located over the facial canal. When the instrument is thus adjusted, the convexity in the plate is a guide to the junction of the horizontal and perpendicular semicircular canals. A small sharp gouge is placed in the convexity of the plate, and with a few rotary motions it penetrates the

Fig. 449

Bourguet's guide and protector.

bone and exposes the ampullar space beneath the angle. The external arm of the horizontal semicircular canal may then be exposed to its posterior limit, and, if necessary, the external arm of the perpendicular canal may also be exposed by removing its outer wall upward from the primary opening at the petrous angle of the two canals (Fig. 450).

The Bourguet protector and guide is in position, protecting the facial ridge and guiding the gouge to the petrous angle at the junction of the two canals.

Having thus removed the necrosed tissue, a small wick of gauze should be placed against the opening and the mastoid wound loosely packed with gauze. The disturbance due to the opening of the canal, as the loss of equilibrium, dizziness, nausea, vomiting, and nystagmus, will disappear within a few hours or days.

The Complete Exenteration of the Semicircular Canals.—When the entire system of semicircular canals is filled with granulations it may become necessary to open them through their entire extent. If they are only infected and contain purulent matter, the opening at the petrous angle of the horizontal and perpendicular canals and the removal of the outer wall of the horizontal canal may be sufficient to establish drainage of the

entire system. Should this be regarded as insufficient, because the canals are filled with granulations, the entire system should be opened. The hearing is necessarily greatly damaged when only the outer wall of the horizontal canal is opened, as described in the preceding section. There is, therefore, no objection to opening all the canals, as the hearing will not be rendered worse by it. The chief objection is the difficulty involved in the procedure and the possible fracture of the cranial plate on the superior and posterior surfaces of the petrous portion of the temporal bone, and the danger from the meningitis which may follow. The complete exposure of the bony walls of the canals before opening them will largely obviate these difficulties.

Fig. 450

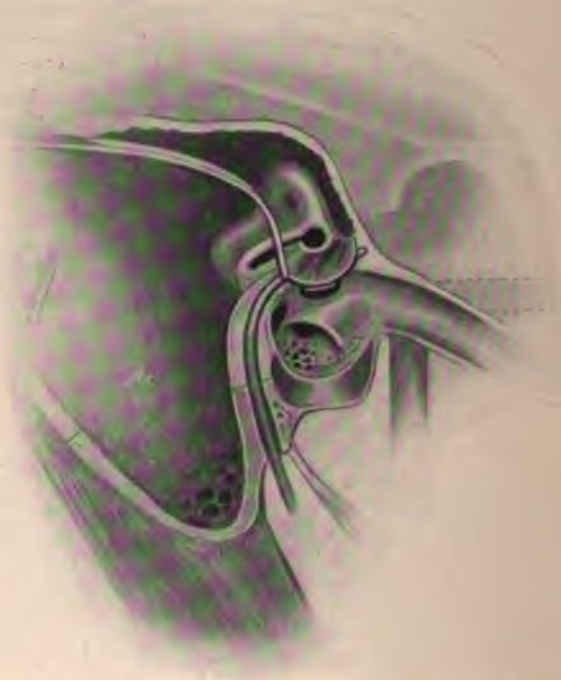

Schema showing Bourguet's operation upon the horizontal semicircular canal. The facial nerve is not actually exposed in the operation.

Technique.—(*a*) Complete the radical mastoid operation.

(*b*) Remove the portion of the zygomatic root and of the roof of the external auditory meatus, as shown in Plate XII, to facilitate the use of the curette in removing the bony tissue surrounding the canals.

(*c*) Having exposed the contour of the canals to view (Plate XII, *b*, *c*, *d*), introduce Bourguet's guide and protector (Fig. 449) with its heel or toe in the oval window and its semilunar plate over the facial ridge, as shown in Fig. 450.

(*e*) Proceed to open the petrous angle of the horizontal and perpen-

dicular canals as described in the Surgery of the Horizontal Semicircular Canal (Fig. 450).

(*f*) Extend the opening upward and backward, thus removing the outer walls of the horizontal and perpendicular semicircular canals (Fig. 451).

(*g*) With a small curved gouge introduced above and beyond the outer limit of the horizontal canal (Fig. 451) remove the superior wall of the oblique canal.

(*h*) Proceed to complete the opening of the horizontal and perpendicular canals with the small curved gouge and small thin chisel. The major portion of the work should be done with the gouge, a rotary or boring motion being used, as the blows of the mallet are liable to fracture the bone in unexpected directions and lead to the dangers of meningitis.

(*i*) Endeavor to open the upper portion of the vestibule, as this will ensure better results, as the semicircular canals open into it. This should be done with a small thin chisel curved on the flat. The petrous angle of the horizontal and perpendicular canals, directly above the oval window, should first be opened as shown in Fig. 451, and the chisel used to extend the opening downward to the vestibule. The force of the blows of the mallet should not be allowed to be expended upon the facial ridge. That is, the chisel should be well above the facial ridge (not resting upon it), as to use the facial ridge as a fulcrum in loosening the chips of bone might fracture it and cause facial paralysis (Richards).

(*j*) The dressings and after-treatment should be as described in the Surgery of the Horizontal Semicircular Canal.

Richards says that this route to the vestibule is safer than that *via* the inner wall of the cavum tympani, as there are no vulnerable points to be encountered except the facial ridge, whereas, in opening it by removing the bridge of bone between the oval and round windows and a portion of the promontory, the inner thin wall of the vestibule is more liable to injury, especially as the vestibule is shallow at this level and its inner wall very thin.

THE SURGERY OF THE VESTIBULE VIA THE INNER WALL OF THE CAVUM TYMPANI BELOW THE FACIAL NERVE.

When granulations and pus extrude from the oval window, the vestibule is profoundly affected and should be opened. Indeed, the cochlea, or at least the lower turn of it, is also often involved. It is imperative that the vestibule be opened, the granulations removed, and better drainage established. It may be necessary to exenterate the semicircular canals, as described in the preceding sections, as they may also be involved.

Technique.—Bourguet's method will be adhered to in this description.

(*a*) The radical mastoid operation.

(*b*) Check the hemorrhage by curetting the tympanal end of the Eustachian tube (Fig. 404). Also apply pledgets of cotton saturated with adrenalin solution to the cavum tympani.

(*c*) Remove the pledgets of cotton after a few minutes, and introduce the heel of Bourguet's protector and guide into the oval window, as shown in Fig. 450, to protect the facial nerve from injury.

Fig. 451

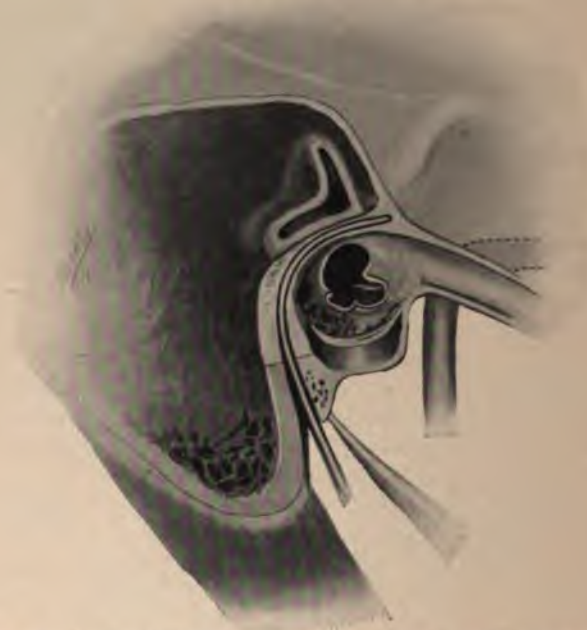

Schema showing Bourguet's operation upon the semicircular canals, vestibule, and cochlea. The semicircular canals are opened, as shown in Fig. 450, with the protector and guide in position. The facial nerve is not exposed in the actual operation.

Fig. 452

Schema showing a cross-section through the cochlea from apex to base. The central shaded portion (*a*) is the modiolus. If more than the upper apecial coil is removed, the internal auditory canal (*b*) at its base would be opened, thus exposing the patient to the dangers of meningitis.

(*d*) Remove the bridge of bone between the oval and round windows with a thin sharp chisel, thus exposing the lower space of the vestibule (Fig. 451).

(*e*) Enlarge the opening, if necessary, to expose a portion of the lower coil of the cochlea (Fig. 451). This figure also shows the horizontal and perpendicular semicircular canals opened.

(*f*) Gently remove granulations from the vestibule, and bear in mind that the inner wall of the lower portion is thin and easily fractured.

(*g*) The after-treatment is as heretofore described.

The Partial Exenteration of the Cochlea.—The extent to which the cochlea may be exenterated is still an open question. According to Richards, it may be opened in its entirety; that is, its two and one-half coils may be completely uncapped. To do this it is necessary to remove the upper coil and a portion of the modiolus. Herein lies the danger. The modiolus (Fig. 452) is a hollow cone at its base, but is solid at its apex, which supports the cupola of the cochlea. If the modiolus is removed so low or deep as to open the cone-shaped cavity at its base, the cerebrospinal fluid will escape into the cavum tympani, and pathogenic microörganisms may enter the cranial cavity and cause meningitis.

Fig 453

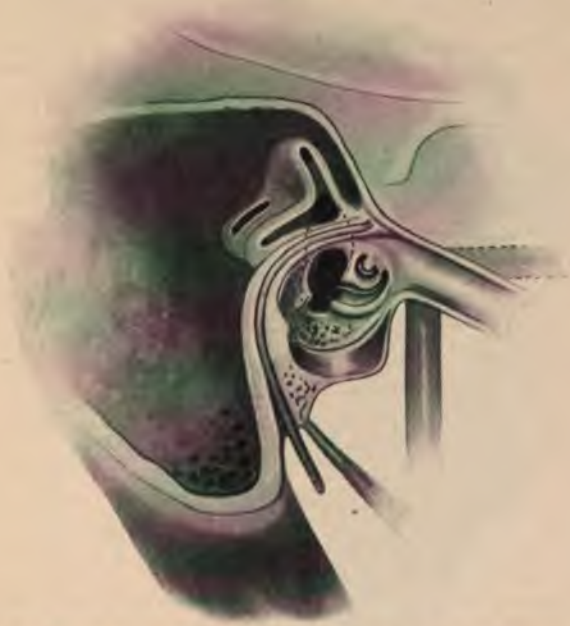

An extensive exposure of the canals and cochlea. The apecial whorl is removed. A more extensive exposure is attended by great danger, and should rarely be attempted.

In attempting to remove the apex of the modiolus the blow of the mallet may accidentally fracture it at its base (Richards), and thus cause leakage of the cerebrospinal fluid, meningitis, and death.

It is obvious, therefore, that under nearly all circumstances the uncovering of the cochlea should be limited to the removal of the outer walls of the coils, the modiolus and deeper walls being unmolested. In this description the limit of safety will be observed, and it is only when the cochlea is choked with granulations, and necrosis is present, that this much of an exposure is justifiable.

Technique.—(*a*) Preliminary radical mastoid operation, plus the more extended exposure shown in Plate XII.

(*b*) Check hemorrhage with adrenalin and the curettage of the Eustachian tube.

(*c*) Expose the vestibule and semicircular canals as previously described.

(*d*) Remove the lower promontory wall covering the first half of the first coil of the cochlea, as shown in Fig. 451. A small chisel, a little wider than the cochlear canal, should be used to uncap it. The chisel should be directed inward and backward, carefully following the canal as it curves upward and disappears in the deeper structures of the bone, when the dissection should be discontinued.

Fig. 454

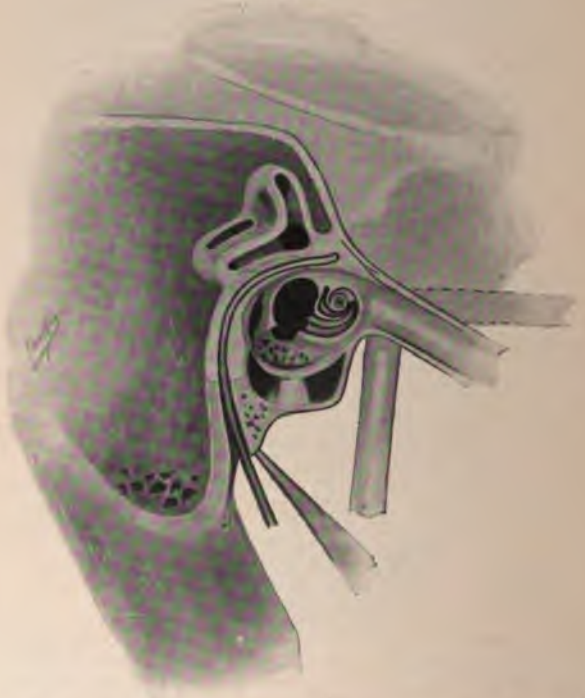

Richards' radical operation upon the cochlea and canals. The cupola or apecial whorl is removed, including the modiolus. This radical exposure of the cochlea should rarely be performed, and only then by a surgeon qualified to do it.

(*e*) Next uncap the cupola, first locating it by noting the contour of the inner wall of the cavum tympani at a point above the anterior extension of the lower coil already exposed. The slight elevation at this point gives the location of the cupola or apex of the cochlea. A small gouge is better for this part of the procedure, as it may be rotated, thus boring an opening into the upper coil of the cochlea. The outer wall of the bone may thus be removed from the upper coil, or coil and one-half (Fig. 453). Having exposed the outer aspect of the coils of the cochlea, cease the

operation without attempting to extend it farther, as to do so might, and probably would, end in meningitis and death.

The dressing and after-treatment are as previously described.

The Complete Exenteration of the Cochlea.—As already stated in the preliminary discussion under Partial Exenteration of the Cochlea, the complete exenteration is rarely, if ever, justifiable, certainly not in the hands of the average surgeon, unless he has done extensive dead-house work to prepare him for it. Even then the dangers are great and almost beyond control. Richards had two deaths from such operations, which he ascribed to operative interference. He states, however, that he believes he could in future avoid such accidents. In the meantime we should

Fig. 455

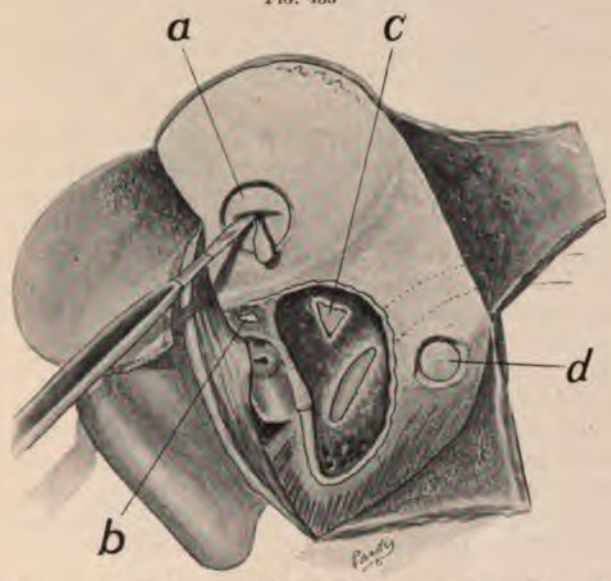

Avenues of approach to brain abscess. *a*, through the squamous plate to the temporosphenoidal lobe; *b*, through the tegmen tympani to the temporosphenoidal lobe; *c*, through the mastoid wound to the cerebellar fossa; *d*, through the cranial cortex (one and one-quarter inches posterior to the cavum tympani) to the cerebellar fossa.

remember that the operation, even in the hands of an expert who has devoted much thought and deadhouse work, as well as work upon the living, to it, is fraught with extreme hazard.

Technique.—The technique of the complete exenteration of the labyrinth will not be given, as it is not the author's purpose to recommend it as a justifiable procedure, at least in the present status of the subject.

In Fig. 454 is shown the complete exposure of the cochlea, its cupola or upper coil being removed with the apex of the modiolus. The black spot in the centre of the coils is an opening into the internal auditory canal (Fig. 452 *b*), through which cerebrospinal fluid would escape, and through which infection of the cranial contents might occur. Only the

basal coil and half of the second remain. The vestibule and all of the semicircular canals are also shown exposed by surgical interference.

Caution.—Before undertaking the surgery of the labyrinth the otological surgeon should consider the following facts:

(*a*) But few cases of otorrhea and mastoiditis have been found to be complicated by suppurative labyrinthitis, though doubtless many such complications have been present and not discovered.

(*b*) Most of the labyrinthine suppurations observed have not been treated surgically, and in nearly every instance recovery has occurred.

(*c*) Those operated have invariably been followed by marked deafness, whereas those not operated have been attended by less pronounced deafness.

(*d*) In view of these facts surgical intervention should be undertaken with reluctance, except in those cases in which the deafness is already profound, or in which meningeal irritation is already present, or appears to be imminent, as shown by the location and extent of the morbid lesions.

Facial Paralysis Resulting from the Surgery of the Labyrinth.—Facial paralysis resulting from the surgery of the labyrinth, as described in the above surgical procedures, should only occur in those cases in which the facial canal is involved in the necrotic process. It is never necessary to uncover the facial nerve to expose the semicircular canals, vestibule, or cochlea sufficiently to establish good drainage. Accidental injury of the nerve may usually be avoided by heeding the precautions given in the descriptions of the various surgical procedures. Bourguet's guide and protector is a valuable addition to the instrumentarium, and largely solves the problem of protecting the facial nerve as it crosses the upper and outer wall of the vestibule. The vestibule may be opened above the facial nerve or below it, as described, but under no circumstances, other than the presence of marked necrosis of its bony canal, should the bridge of bone containing the nerve be removed. While facial paralysis may, and has, followed the surgery of the labyrinth, it may, with added experience and an improved technique and instrumentarium, be avoided.

THE SURGERY OF BRAIN ABSCESS.

The Surgery of Cerebral Abscess.—Abscess of that portion of the cerebrum embraced within the temporosphenoidal lobe may be opened through two routes, namely, (*a*) the tegmen tympani and antri, and (*b*) the squamous portion of the temporal bone. In some cases both routes should be employed, especially if the abscess is located high above the tegmen tympani and contains large masses of debris and broken-down brain substance which cannot be removed through the perforation in the tegmen. In those cases in which the abscess is located near the tegmen tympani (roof of the cavum tympani) and in which the contents of the abscess are purulent or fluid, the route through the enlarged perforation in the tegmen may prove adequate for the drainage.

Drainage through the Tegmen Tympani.—(*a*) A preliminary radical mastoid operation is first performed, not only to cure the mastoiditis and otitis media, but to expose the tegmen, or roof of the cavum tympani, the atrium of the brain infection.

(*b*) The middle-ear cavity (cavum tympani) is mopped with a cotton-wound applicator to free it of pus and blood, and if necessary adrenalin chloride solution should be applied to check the hemorrhage.

FIG. 456

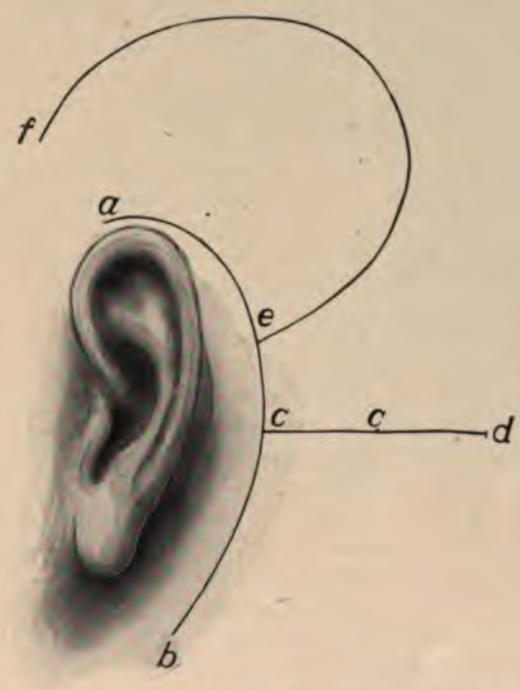

The incisions for brain abscess. *a b*, the primary mastoid incision; *c c*, the secondary mastoid incision; *c d*, an extension of the secondary incision for cerebellar abscess; *e f*, the incision for abscess of the temporosphenoidal lobe of the cerebrum.

(*c*) The tegmen tympani should then be inspected under strong reflected light for oozing pus, and for the dehiscence or perforation resulting from necrosis. A probe may also be used to explore for rough and necrosed bone.

(*d*) Having located the point from which pus oozes, or the granulations protrude from the necrosed area of the tegmen, it should be gently curetted to remove the granulations, and to expose the necrotic bone and the perforation through it. The opening should be enlarged by removing all the necrosed bone (Fig. 455 *b*), a dull curette being used for the purpose.

(*e*) If the abscess is located near the floor of the middle fossa immediately over the perforation in the tegmen tympani it may be readily

drained through this enlarged opening. The dura and brain substance may be incised to enlarge the channel of communication between the abscess cavity and the cavum tympani. In one case coming under the author's observation the abscess cavity extended into the brain substance for the distance of one and one-half inches, and communicated freely with the cavum tympani. Large cholesteatomatous masses were admixed with the pus, and they were readily removed through the tegmen opening.

(*f*) If the abscess is acute, simple drainage and irrigation are usually quickly followed by complete recovery. If the abscess is chronic, and the walls are lined with necrotic sloughs of brain substance, the healing process is much prolonged and requires careful after-treatment.

Drainage through the Squamous Plate.—The drainage of cerebral abscess through the squamous plate of the temporal bone is indicated when (*a*) the opening through the tegmen tympani is not large enough to ensure adequate drainage; (*b*) when the abscess is located high in the brain substance, and only communicates with the perforation in the tegmen through a small fistulous tract; and (*c*) when the necrotic or cholesteatomatous masses are too large to escape through the tegmen opening, or are inaccessible through the tegmen tympani.

Fig. 457

Circular trephine.

Technique.—(*a*) It is presumed, if the abscess is of otitic origin, that the radical mastoid operation has been performed. The skin incision should be extended from the postauricular mastoid incision in a curved direction backward, upward, and then forward, as shown in Fig. 456 *e f*. The flaps are then elevated and retracted with the periosteum.

(*b*) A circular plate of bone one-half inch in diameter is then removed from the squamous portion of the temporal bone (Fig. 455 *a*), with a circular trephine (Fig. 457). The centre pin of the trephine should be located at a point one inch above the posterior wall of the meatus within the square area shown in Fig. 458. As the bone is of unequal thickness, one section of the circle may be penetrated before the others. The centre pin should be set one-eighth of an inch flush with the plane of the teeth of the trephine, as this is the average thickness of the squamous plate in this region. The trephine should be removed from time to time, and a small probe introduced into all parts of the circular cut to remove the bonedust, and to determine if the bone has been cut through at any given point. If it has, the trephine should be slightly tilted, so as to cut only at the intact portions. When the entire button of bone is severed from its attachments a thin elevator or spatula should be inserted into the cut and the button gently lifted from the dura. The button of bone should be wrapped in a piece of sterile gauze and placed in a sterile or antiseptic solution ready for reinsertion should it be needed—that is, if pus is not found.

(*c*) Inspect the exposed dura for the following conditions: (1) The

presence of pus from an associated meningitis. (2) The presence of congested and infiltrated membranes. (3) The presence of brain pulsation. Brain pulsation is usually present when the abscess is large and deeply

Fig. 458

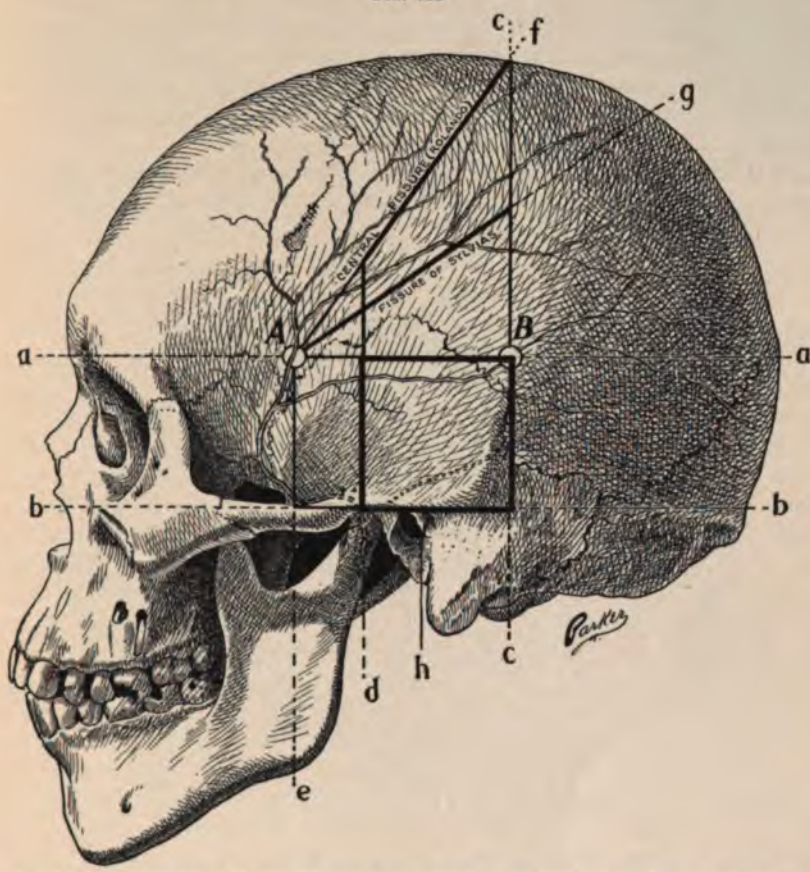

Kronlein's landmarks. *b b*, the German horizontal line, or Read's base line, extending from the lower margin of the orbit to the occipital protuberance; *a a*, the upper horizontal line extends from the supra-orbital margin parallel with the German line. *A e*, the anterior vertical line, extending upward from the middle of the zygoma at right angles to the German line *b b*; *d*, the middle vertical line passes through the condyle of the inferior maxilla at right angles to the German line *b b*; *c c*, the posterior vertical line extends from the posterior margin of the mastoid process at right angles to the German line *b b*. *A f* represents the location of the central fissure of Rolando; *A g* represents the fissure of Sylvius; *A B* represent the points for trephining to evacuate blood from a ruptured middle meningeal artery. Von Bergmann's area is enclosed within the square outlined by the heavy, black lines. Otitic abscess and abscess of the temporal lobe may be drained through this area. The upper line of the square represents the area for tapping the lateral ventricle. *c B*, the sigmoid portion of the lateral sinus; *h*, the point for entering the antrum.

located in the brain substance, or when the abscess is small and superficial. The absence of pulsation may, therefore, be taken to indicate a small deep-seated pus cavity or a large superficial one. Leptomeningitis with

pachymeningitis may result in the fusion of the meningeal membranes, and thus obscure the pulsations which would otherwise be present.

(*d*) The dura should be incised layer by layer near the centre of the opening until its entire thickness is penetrated. It should then be seized with forceps, lifted from the underlying structures, and incised the whole diameter of the opening. If necessary, a cross-incision may be made to overcome the tension. The bloodvessels crossing the field should be cut one at a time, pinched with artery forceps, and ligated if necessary, as the blood might otherwise penetrate between the membranes and produce pressure, or carry infection to other parts.

(*e*) The exposed membranes, brain substance, and bone edges should be dusted with iodoform powder to protect them from the infected pus when the abscess is opened.

Fig. 459

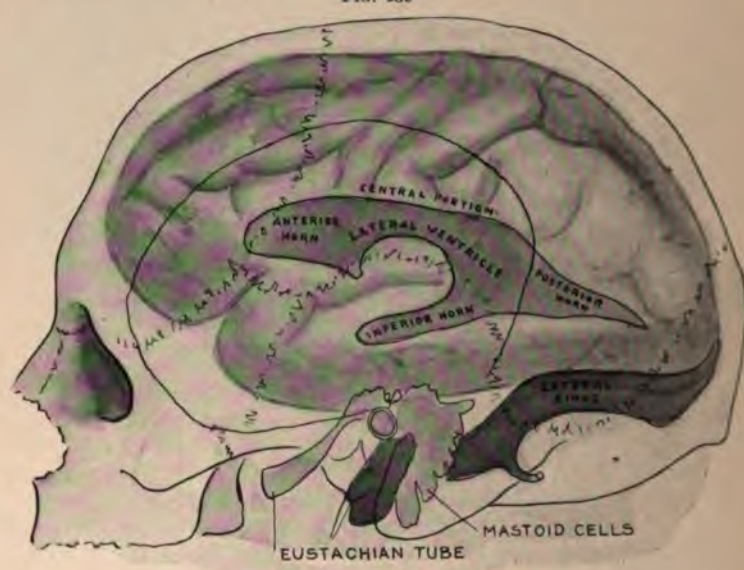

A transparent skull showing the relation of the sutures, ventricles, Eustachian tube, tympanic cavity, mastoid cells, and lateral sinus of the left side of the head.

(*f*) The choice of an instrument for opening the abscess, or for exploring for it, is a matter of some importance. A hollow needle or cannula has commonly been chosen for this purpose. The late Christian Fenger preferred a long, slender-bladed scalpel, as it inflicted less damage to the brain substance, and at the same time was superior in locating and evacuating the pus. The needle and cannula are objectionable on account of the brain substance entering their lumen when suction is applied, thus interfering with the detection and withdrawal of the pus.

The knife should be passed a distance of one inch into the brain substance, then slightly rotated and lifted to open the channel for the discharge of the pus. If pus does not appear, it should be introduced a half inch farther and similarly rotated and lifted. The knife should be

introduced to a greater depth than this with great caution, as the lateral ventricles (Fig. 459) may be opened and exposed to infection. If pus is not thus found, the knife should be withdrawn and reinserted in another plane, and if necessary in several planes, until the abscess is located and evacuated. If care is taken to keep the exposed area of the surface of the brain and the knife surgically clean, there is but slight danger from this method of procedure, even when several punctures are made. The parts of the brain thus incised are not functionally injured, as the incision is clean cut, and the instrument is sterile.

(*g*) If the pus is too thick to flow readily through the incision, or the necrotic sloughs of brain substance are too large to pass through the incised channel, the encephaloscope designed by Whiting should be used. It should be introduced over the blade of the knife while it is still in the brain, the blade acting as a guide to the abscess. Through the opening thus obtained the pus will readily flow, and the sloughs may be removed. When the abscess cavity is emptied its walls may be inspected by the aid of reflected light. If they are necrotic they should be curetted until healthy brain substance is exposed. Should such material be left in the cavity, the infection and inflammation will be much prolonged. Whiting's encephaloscope affords a means of treatment of great advantage that should be utilized whenever the conditions present warrant it.

(*h*) The abscess cavity should be irrigated with a warm antiseptic solution until the return flow is clear. With Whiting's encephaloscope or brain speculum the irrigation is a simple matter, as it allows the nozzle of the syringe to be introduced and at the same time allows the fluid to make its exit into the pus basin. If the encephaloscope is not used, a cannula should be introduced, the lumen of which is larger than the one attached to the syringe, to prevent the possibility of becoming plugged. This provision is necessary, as, if the outflow of the irrigating solution is blocked, the pressure of the retained fluid may cause it to extend beyond the walls of the abscess cavity to other parts of the brain.

(*i*) The first dressing should consist of a drainage wick of gauze, a protective covering of antiseptic powder, and an outer absorbent gauze pad. The drainage wick should extend to the outer wall of the cavity and should come in contact with the external absorbent gauze pad. The proximal end of the gauze wick should be folded over the bony wound and dusted with a mixture of iodoform and boric acid (1 to 5), to prevent adhesion between the gauze wick and the outer absorbent gauze pad, as it may be necessary to leave the gauze wick in position for several days; whereas the outer gauze pad may, and in many instances should, be removed daily. In acute cases the walls of the abscess cavity may collapse and heal in a day or two. Chronic cases will require several days or weeks to heal. Macewen recommends that in some acute cases only the outer gauze pad be used, and if there is no temperature or pain, that it be left undisturbed for three weeks, the obvious purpose being to avoid the possibility of infecting the wound by removing the dressing. When, however, the discharge is sufficient to soil the outer gauze pad, it should be removed daily until healing is completed.

THE SURGERY OF CEREBELLAR ABSCESS.

There are three routes available for evacuating abscess of the cerebellum, namely: (*a*) Through the mastoid wound *via* the recess at the angle of the sigmoid knee (Fig. 455 *c*), that is, through the recess between the inner wall of the antrum and the knee of the sigmoid sinus; (*b*) through the inner wall of the sigmoid sinus when the vessel s thrombosed and has been exenterated; (*c*) through the skull one and one-fourth inches posterior to the meatus, and below the level of the lateral sinus (Fig. 455 *d*).

(*a*) If the abscess is immediately behind the petrous pyramid of the temporal bone it may be easily reached through the mastoid wound *via* the recess between the knee of the lateral sinus and the antrum.

(*b*) If the lateral sinus is thrombosed (and it is often the source of the cerebellar abscess), its walls should be carefully searched for necrotic areas, not alone as an avenue of approach to the abscess, but as a means of tracing the location of the abscess through the fistulous tract leading from the sinus to the abscess cavity. This route may be utilized to evacuate the abscess, though the subsequent treatment through this route is difficult to carry out on account of the contracted and deep situation of the opening in the mastoid wound. This is also true of the first (*a*) route.

(*c*) The external route through the skull (Fig. 455 *d*) is generally preferable on account of its accessibility.

The technique of the operation is otherwise similar to that described for cerebral abscess.

THE SURGICAL TREATMENT OF SEROUS MENINGITIS.

Serous meningitis has no characteristic symptoms by which it may be positively diagnosticated from purulent meningitis. If, however, after completing the radical mastoid operation the tegmen tympani or antri is opened and serous fluid escapes, and the meningeal symptoms subside, the diagnosis of serous meningitis may be made (Fig. 455 *b c*).

The surgical treatment consists in removing the tegmen tympani or the tegmen antri and allowing the serous effusion to escape. The after-treatment consists in the usual mastoid dressings.

THE SURGICAL TREATMENT OF EXTRADURAL ABSCESS OR PACHYMENINGITIS CIRCUMSCRIPTA.

Circumscribed pachymeningitis, or extradural abscess, located over the tegmen tympani or antri in the middle fossa of the skull, may be successfully treated in nearly all cases by first performing the radical mastoid operation, and then removing the roof of the cavum tympani or the roof

of the antrum, and evacuating the purulent secretion. An extradural abscess is a localized meningitis, the circumference of which is walled off by a plastic exudate.

The early operation upon these cases prevents the spread of the infection in the form of a brain abscess and leptomeningitis, which are more serious affections. Leptomeningitis is usually fatal, though a few cases have recovered under surgical drainage.

THE SURGICAL TREATMENT OF THROMBOSIS OF THE LATERAL SINUS.

Infective thrombus is more often found in the sigmoid portion of the lateral sinus than in any other of the intracranial sinuses. Early recognition and surgical treatment is of the greatest advantage to the patient, as many cases thus early recognized and treated recover.

Technique.—(*a*) A preliminary mastoid operation is performed. If the mastoiditis and otitis are acute, it may be only necessary to do a simple mastoid operation, the cavum tympani being unmolested; if, however, the mastoiditis or otitis are chronic, and if the labyrinth is involved by the infective process, the radical mastoid operation should be performed. Richards reports 11 cases of labyrinthine disease upon which he operated, performing more or less extensive exenterations of the labyrinth, of which three were affected by thrombosis of the lateral sinus. This, as he says, points strongly to the labyrinth as a possible atrium of infection (Figs. 368 to 398, and the technique of the mastoid operations).

(*b*) Remove the cortex of dense or necrosed bone covering the mastoid aspect of the lateral sinus as extensively as possible, thus exposing the membranous sinus to observation and operation. Determine whether a perisinuous abscess (extradural abscess of the sinus) is present. Note the texture of the membranous sinus, whether velvety, covered with granulations at certain points, or necrosed. Palpate it with the finger to determine its resistance, whether doughy, hard, or fluid. Some surgeons recommend that the sinus be exposed in every mastoid operation, and that a portion of its contents be withdrawn with a hypodermic needle to ascertain if pus is present. This is reprehensible practice, as it is an unreliable method of determining the presence of pus, and exposes the sinus to the danger of infection. Whiting recommends that the tip of the finger be placed as near the jugular bulb as possible and then drawn upward toward the knee, and noting whether the stripped sinus refills below the finger. If it does, the jugular bulb is open. The sinus should then be stripped from above downward toward the jugular bulb, and the same observation made of the upper portion of the sinus. If it refills, the sinus is open above; if it does not, it is closed by a thrombus. Having determined to open the membranous sheath of the sinus, see that iodoform and boric acid powder (1 to 5) and a strip of iodoform gauze (1 x 24 in.) are in readiness in case free hemorrhage occurs.

(c) Incise the whole length of the exposed portion of the membranous sinus (Fig. 460), and if the hemorrhage is free it should be closed by turning in the cut edges of the membrane and packing the bony opening with the strip of iodoform gauze. A few moments of hemorrhage should be allowed, as it may wash out the infective material and lead to recovery.

If the incision is not followed by hemorrhage, the thrombic clot, whether it be solid or undergoing disintegration, should be removed with a dull curette. The portion of the clot near the jugular bulb should be curetted until blood appears at the lower end of the opening. The curette should then be passed upward through the knee of the

Fig. 460

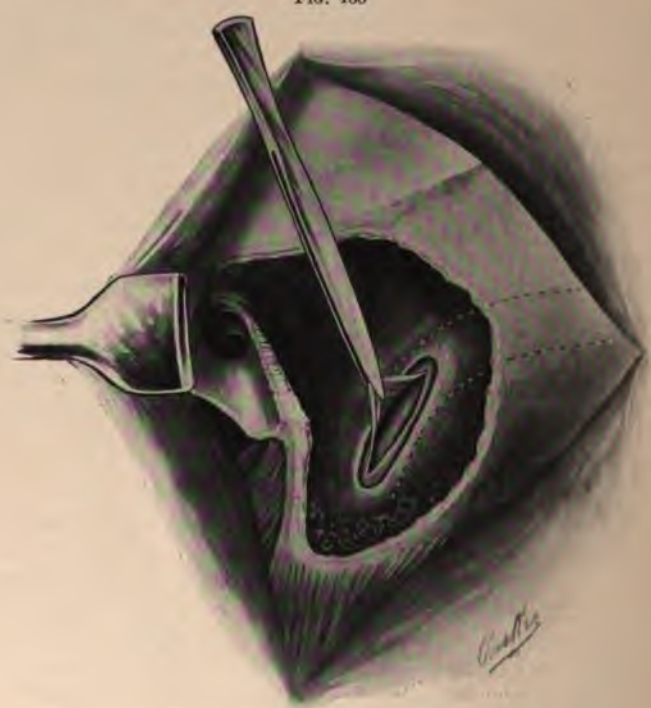

Thrombus of the lateral sinus exposed.

sinus, and the clot removed from this part of the sinus. The flow of blood from this end of the sinus is evidence that this portion has been cleared of the thrombus. Both ends of the sinus should give forth blood. The lower or jugular end of the sinus should be kept closed with the finger while the upper end is being curetted, as too much blood might otherwise be lost, or the surgeon be impelled to work in unseemly haste. Having cleared the sinus of the clot, it should be filled with the iodoform boric acid powder, the edges of the membrane turned in and the bony aperture filled with iodoform gauze, and the usual mastoid drainage and absorbent dressing applied.

(*d*) The dressing may be removed at the end of from twenty-four to forty-eight hours, and the gauze removed from the bony aperture of the lateral sinus without danger of hemorrhage.

(*e*) The after-treatment consists in the usual mastoid dressings heretofore described.

Should pain, chills, and a rise in temperature occur, the dressings should be removed at once and the parts examined to determine the conditions which gave rise to the symptoms. If pus is present, endeavor to trace it to its source. It will usually be necessary to reopen the sinus and extend the curettement, as the sepsis is probably from within the sinus, fragments of the thrombus having probably been left at the time of the primary sinus operation. The sepsis may, however, have its origin from a perisinuous abscess. It may become necessary to resect the jugular vein and the jugular bulb.

RESECTION OF THE INTERNAL JUGULAR VEIN.

The indications for the ligation and resection of the internal jugular vein are as yet not fully established. It is still a question as to when the resection increases the danger of spreading the infection, and when it prevents spreading the infection from a thrombosed lateral sinus. If the internal jugular vein is ligated and resected, the anastomotic channels, of which there are many, will receive the venous blood current, provided there is a flow of blood through the sinus. If only the lower portion of the lateral sinus is closed by an infected thrombus, the blood may be forced into the superior petrosal sinus and cause thrombosis in it and the cavernous sinus, with which it communicates. If the entire sigmoid portion of the sinus is blocked by a thrombus, the blood current may be forced backward into the superior longitudinal sinus. If the thrombus is limited to the jugular bulb the blood current may be forced into almost any or all of the intracranial sinuses. In ligating the internal jugular vein the effect upon the blood current is the same as that in jugular bulb thrombus. The question as to when the jugular vein should be ligated and removed from the neck resolves itself into the consideration of the foregoing facts, and may be stated as follows:

(*a*) It may be ligated and removed when the entire sigmoid sinus is thrombosed and obliterated by operative procedure. The jugular vein should be removed first, however, to obviate the danger of disseminating particles of the thrombus which may become detached during the exenteration of the sigmoid sinus.

(*b*) The internal jugular vein may be ligated and removed when the jugular bulb is thrombosed, the jugular bulb being removed after the resection of the vein, provided the sigmoid and lateral sinuses are entirely free from infection, or that the sigmoid sinus is obliterated at the same time, whether it is infected or not. If the sigmoid sinus is left open, the infective material from the jugular bulb may be forced backward through the sigmoid sinus, and from thence through the petrosal to the cavernous sinuses.

(*c*) The internal jugular vein may be ligated and resected when it is thrombosed by extension from a similar condition in the sigmoid sinus and jugular bulb.

(*d*) The jugular vein should not be ligated and resected when there is a flow of blood through the sigmoid sinus.

(*e*) In a general way it may be said that the jugular vein may be ligated and resected when the sigmoid sinus is completely blocked with an infected thrombus.

The object of the ligation and resection of the internal jugular vein is to prevent the dissemination of the infection to other parts of the body, as the lungs, spleen, liver, kidneys, intestines, etc. Statistics show more favorable results when this is done in complete blockage of the sigmoid sinus; and, on the contrary, the results are worse when the sigmoid sinus still has a current of blood passing through it.

Technique.—(*a*) Extend the mastoid incision downward along the anterior border of the sternomastoid muscle to the sternal notch (Plate XIII).

(*b*) Retract the sternomastoid muscle backward and separate the fascia and other structures by blunt dissection until the internal jugular vein is exposed.

(*c*) The pneumogastric nerve runs between the internal jugular vein and the carotid artery, and should be respected.

(*d*) Ligate the internal jugular vein just above the sternum and just below the floor of the external auditory meatus (Plate XIII).

(*e*) Ligate all the branches of the vein given off between the upper and lower ligations of the jugular vein (Plate XIII).

(*f*) Sever the jugular vein just above the lower and just below the upper ligatures. Then sever all the branches close to the jugular vein, and remove the vein from the neck. A gauze pad should be placed under the vein before resecting it to protect the tissues from infection.

(*g*) The sigmoid sinus is next opened and the thrombus removed as described in the preceding section. The danger of disseminating the disintegrating thrombus through the jugular vein is largely obviated by its removal, though the anastomotic communications are not altogether obliterated.

(*h*) The sigmoid sinus should be packed and obliterated (Plate XIII), and the mastoid wound dressed as previously described, with the exception that the lower half of the mastoid incision is left open so that the region of the exenterated sigmoid sinus may be subsequently inspected and dressed through it. The incision in the neck should be closed throughout its entire length, a secondary incision being made one inch posterior to the lower angle. This incision should be made to communicate with the primary neck wound by tunnelling beneath the skin. A spiral tube with a small wick of gauze in it should be introduced into the secondary incision, and be extended beneath the skin to the lower portion of the primary neck wound, as shown in Fig. 434. The object of the secondary incision is to prevent an unsightly scar. As the primary wound was occupied by an infected and thrombosed vein, the tissues may have become contaminated. Under these circumstances, if the tube dressing were intro-

PLATE XIII

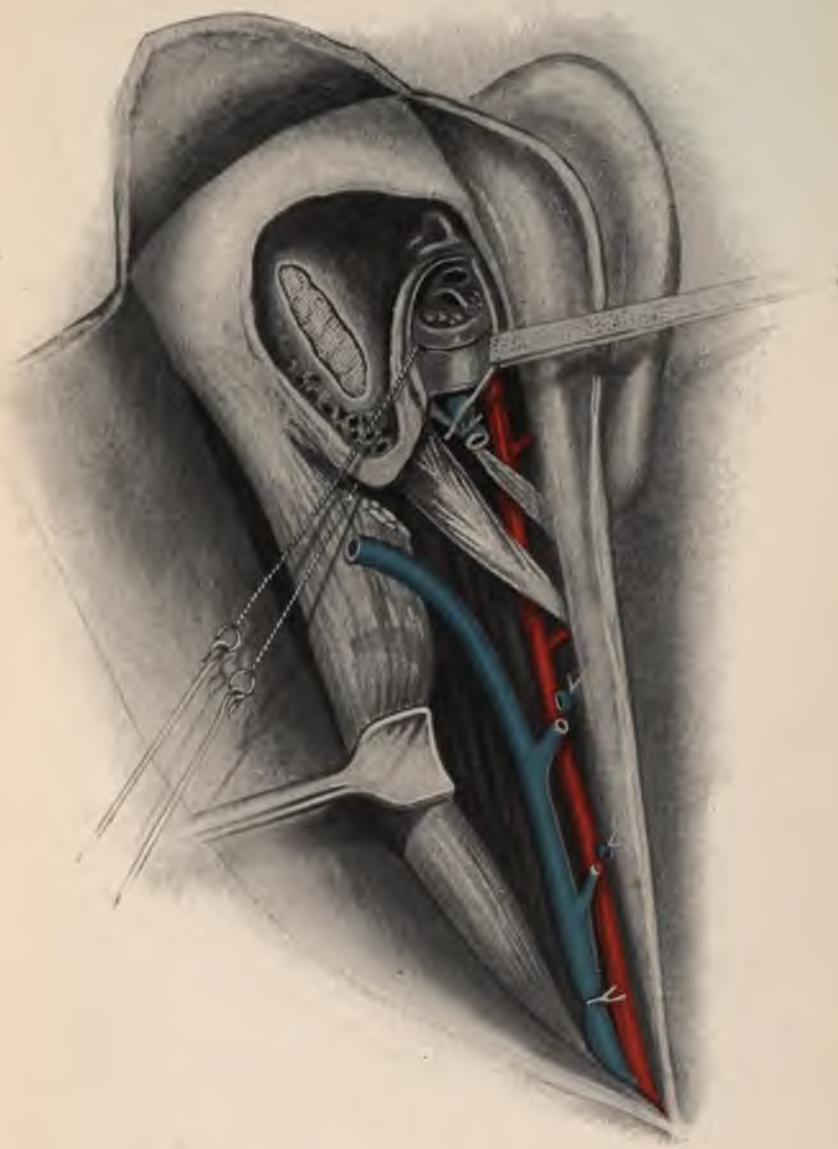

The Combined Operation for the Removal of a Thrombosed Sigmoid Sinus, Jugular Vein, and Jugular Bulb.

The sigmoid portion of the lateral sinus has been exenterated and packed with gauze. The jugular vein and its branches have been ligated and severed, and the floor of the meatus is being removed with a Gigli saw to expose the jugular bulb. The facial nerve has been exposed and retracted forward with a gauze tape to permit the bone which encloses it to be removed, as it is in the operator's pathway to the jugular bulb, though this was not necessary in this particular dissection.

PLATE XIV

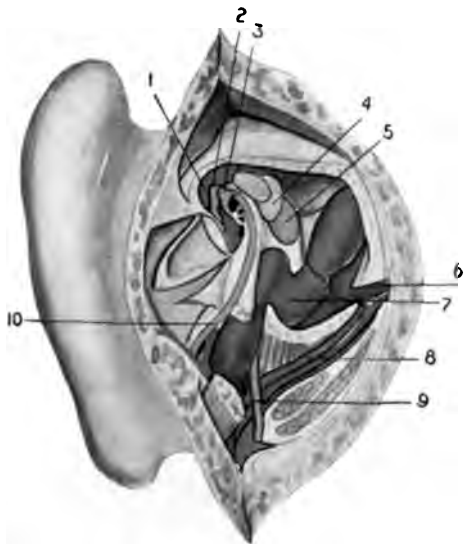

The Anatomy of the Grunert-Panse Exposure of the Jugular Bulb. Grunert removes the tip of the mastoid process and then proceeds toward the jugular foramen at the base of the skull. When the jugular foramen is reached he removes the outer and posterior portion of the bony ring encircling the vein. As shown in the drawing, the facial nerve lies in the way. Panse exposes it, removes it from its canal, displaces it forward, and proceeds to expose the jugular bulb.

1, Tympanic cavity; 2, malleus; 3, incus; 4, posterior semicircular canal; 5, saccus endolymphaticus; 6, mastoid emmisary vein; 7, lateral sinus; 8; occipital vein; 9, spinal accessory nerve; 10, facial nerve. (After Bardeleben.)

duced into the wound through the primary incision, the tissues around the tube dressing would heal slowly and cause a retracted and disfiguring scar. The secondary incision, being removed from the region of infection, will, after the tube is discontinued, heal quickly and with little scar and disfigurement.

(*h*) The after-treatment, in so far as the wound in the neck is concerned, consists in the removal of the drainage tube dressing at the end of the third day, or earlier if pain and temperature arise and persist. In those cases in which the neck wound was not infected the tube dressing may be dispensed with after the first dressing, a small gauze wick being inserted only a little distance into the wound to carry away the excess of secretions. The channel occupied by the tube will quickly fill by granulation, and at the third dressing the gauze wick may be omitted to allow the cutaneous edges of the incision to approximate and unite. The scar resulting will be slight and the cosmetic effect good.

The sigmoid and mastoid wounds should be dressed as previously described.

THE SURGERY OF THE JUGULAR BULB.

The indications for the removal of the jugular bulb are (*a*) extensive necrosis in the region of the bulb; (*b*) severe systemic infection from the disintegrating thrombic clots; and (*c*) the desire to remove every vestige of the foci of infection in order to give the patient the greatest chance of recovery.

Technique.—(*a*) The mastoid operation is first performed as previously described. The simple mastoid operation is performed if the case is acute and there are no special indications, as labyrinthine suppuration and necrosis, for opening the cavum tympani. Cerebral abscess with the atrium of infection through the tegmen tympani, and sigmoid sinus thrombosis with the atrium of infection through the labyrinth, etc., necessitate the performance of the radical mastoid operation.

(*b*) The internal jugular vein is next resected as described in the preceding section (Plate XIII).

(*c*) The sigmoid sinus is exposed, exenterated, and packed with gauze (Plate XIII).

(*d*) The floor of the external auditory meatus is removed, as it is in the pathway to the bulb (Plates XIII and XIV).

(*e*) The facial nerve is exposed as recommended by Panse, as it often lies in the pathway to the bulb. The nerve should be lifted from its exposed canal, a strip of gauze passed around it, with which it is retracted anteriorly, as shown in Plates XIII and XIV.

(*f*) The styloid process, together with the lower portion of the bone which previously supported the facial nerve, and that portion of the mastoid tip which obstructs the path to the bulb, should be removed with a chisel, bone forceps, or a Gigli saw, as shown in Plate XIII. The saw should be placed in front of the fragment of the floor of the meatus, the anterior wall having been previously removed. One end should be passed

backward beneath the tip of the mastoid process (the sternomastoid muscle being partially severed, (Plate XIII), and the other backward and

Fig. 461

Fig. 462

Fig. 463

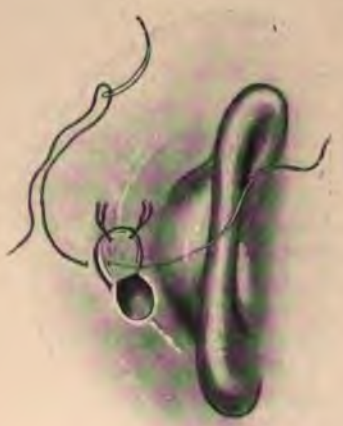

Fig. 464

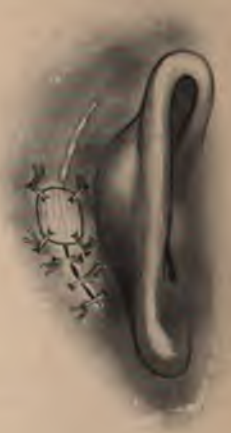

Fig. 461.—The first step of the Mosetig-Moorhof plastic operation for the closure of a persistent retro-auricular opening.

Fig. 462.—The second step of the Mosetig-Moorhof plastic operation.

Fig. 463.—The third step of the Mosetig-Moorhof plastic operation for the closure of a persistent retro-auricular opening.

Fig. 464.—The fourth step of the Mosetig-Moorhof plastic operation for the closure of a persistent retro-auricular opening.

over it, and the bone, including the styloid attachment and the anterior portion of the mastoid tip, sawed through (Plates XIII and XIV). The

PLATE XV

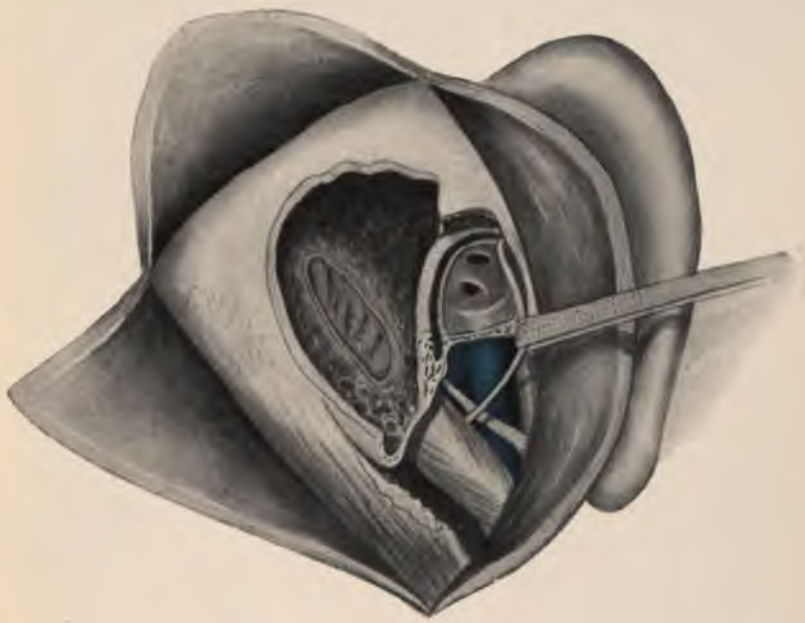

The Exposure of the Jugular Bulb Completed, the Sigmoid Sinus Exenterated and Packed with Gauze, and the Facial Nerve Lifted from its Canal and Retracted Anteriorly. The facial ridge is usually located more anteriorly over the jugular bulb than shown in the drawing.



remaining portion of the bone, especially that lying beneath the floor of the meatus, may be removed with bone forceps.

(*g*) If the transverse process of the atlas projects outward into the field of operation, it should be removed, care being exercised to avoid injuring the vertebral artery (Bardeleben).

(*h*) The outer portion of the thin bone encircling the jugular bulb should be removed with bone forceps.

(*i*) The jugular bulb, being exposed to surgical interference, should be examined, and its condition noted for scientific purposes. As the sigmoid sinus above and the internal jugular vein below have already been obliterated and removed, there is no added danger in removing the bulb which forms the connecting link between them.

FIG. 465

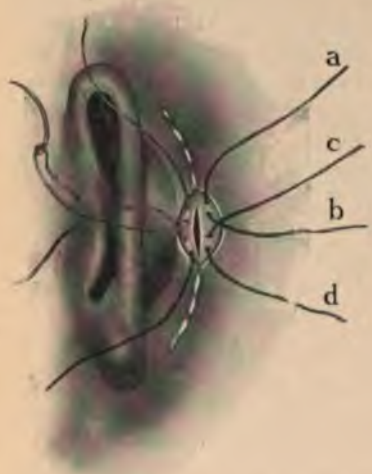

FIG. 466

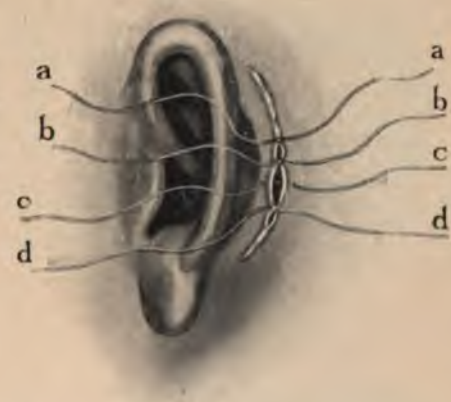

FIG. 465.—The second step in the Passow-Trautmann plastic operation for the closure of a persistent retro-auricular opening. The sutures *a b* and *c d* are to be tied to the opposite sutures to bring the periosteum together.

FIG. 466.—The third step of the Passow-Trautmann plastic operation. Closing the skin.

(*j*) The jugular bulb should be removed from the jugular fossa with a curette.

(*k*) The primary dressing should consist of a gauze wick, the distal end of which is inserted into the jugular fossa, and the proximal end in contact with the external absorbent dressing. The mastoid, sigmoid sinus, and neck wounds should also be drained by spiral tubes with a small gauze wick in the lumen of the tubes.

(*l*) The after-treatment consists in applying suitable internal drainage and external absorbent dressings until all suppuration ceases and the cavities have healed. The mastoid wound should heal by granulation, finally becoming covered with epidermis. Should exuberant granulations form, they should be reduced with caustic applications or with

the electric cautery. Should the mastoid bony surfaces fail to heal within from four to ten weeks, they should be more freely exposed (the postauricular wound is left open at the time of the primary operation), curetted, the hemorrhage checked, and Thiersch grafts applied as previously described.

CLOSURE OF POSTAURICULAR FISTULA.

The Mosetig-Moorhof Method.—This method is adapted to the closure of small openings, and is performed as follows: (*a*) The edges of the fistulous openings are freshened; (*b*) a skin flap corresponding in size with the opening is made below the opening, a pedicled attachment being left at the upper portion of the flap; (*c*) the flap is then turned upward and placed in the fistulous opening, with the skin surface inward; (*d*) it is then fixed in this position by four sutures; (*e*) finally, the freshened edges of the fistulous opening are brought together over the raw surface of the skin flap, thus forming an epithelial lining on the inside as well as on the outside of the fistulous opening (Figs. 461, 462, 463, 464).

Passow-Trautmann Method.—(*a*) Make a circular incision about one-eighth inch or more (Trautmann) from the edge of the fistulous opening, and separate the periosteum and skin within the incised circle from the bone beneath; (*b*) unite the everted margins of the periosteum thus loosened, with absorbent catgut sutures; (*c*) loosen the skin external to the incision and unite the edges over the first periosteal flaps with sutures (Figs. 465 and 466).

CHAPTER XLIX.

FACIAL PARALYSIS.

The Plastic Surgery of the Facial and Hypoglossal Nerves.—The facial nerve is subject to the same diseases as other peripheral nerves, the most frequent affection being paresis or paralysis.

Paralysis is characterized by facial deformity, due to the immobility of the muscles supplied by the facial nerve. The manifestations are the inability to raise the eyebrow, the skin of the forehead, lip, or cheek, and to completely close the eye. The attempt to distend the buccal cavity is attended by the escape of air through the paralyzed side of the mouth. There is also inability to pucker the lips in whistling, because the angle of the mouth droops. The drooping causes the patient a certain embarrassment in speech (Fig. 467).

Fig. 467

Facial paralysis of otitic origin. The patient is attempting to close both eyes and to draw the mouth on both sides; the right facial nerve being paralyzed he is unable to close the right eye or to contract the right angle of the mouth.

Etiology.—1. Exposure to cold and wet, followed by neuritis and perineuritis of the facial nerve.

2. A neuritis due to toxemia, syphilis, rheumatism, diabetes, gout, leukemia, diphtheria, and other infectious diseases.

3. Tumors affecting any part of the course of the facial nerve, as intracranial, intra-osseous, and external neoplasms.

4. Traumatism is one of the most frequent causes of facial paralysis, and one which should concern the otologist. The facial paralysis may arise during suppuration of the middle and internal ear, especially chronic suppuration, or suppuration persisting after operative procedures for its cure.

Facial paralysis may also result from packing the mastoid wound too tightly after a mastoid operation. Paralysis is known to have been caused by the very means devised for the protection of the facial nerve during an operation, namely, Stacke's protector in the hands of an inexperienced

assistant, who presses it too firmly against the facial canal or twists it while it is in the aditus ad antrum.

Curettage of the middle ear for granulations, where the facial nerve is not covered by bone as it passes through the antrum, may injure the facial nerve and cause paralysis.

The vigorous cauterization of granulations in the middle ear with chromic or other caustic acids may also produce facial paralysis. One such case came under my observation.

Treatment.—The treatment is divided into:

1. Medical (local and expectant).
2. Surgical.

In paralysis of toxic origin, following exposure to cold or infectious diseases, the paralysis is usually slight, recovery occurring in from one to six months by the natural process of repair. The usual treatment in such cases is elimination of the toxins by catharsis, the administration of strychnine and other tonics, facial massage, and electricity. These procedures are used principally to keep up the muscular tonicity, while the nerve is regaining its normal function. Paralysis after a mastoid operation from too firm packing, or violent reaction, usually subsides within a short time after the cause is removed. When a tumor is pressing upon the facial nerve, or the nerve is injured in the removal of the tumor, the paralysis will frequently disappear soon after the completion of the operation.

In all other conditions causing facial paralysis, wherein the continuity of structure of the nerve has been destroyed for a greater distance than the process of repair will bridge over, a surgical operation is required to effect a cure. In order to understand the surgery of the facial nerve it is necessary to have a clear conception of its anatomy and physiology.

The facial nerve arises from a large group of cells situated in the upper portion of the medulla oblongata near the junction of the medulla and the pons.

From this nucleus the nerve passes up to the fourth ventricle, forming a knee, to the nucleus of the sixth nerve, and comes out at the junction of the pons and medulla in connection with the sixth nerve. The fibers of the facial lie on the inner side of this composite nerve. From this point the nerve passes through the internal auditory meatus, through the Fallopian canal, beneath the posterior and lower border of the annulus tympanicus, through the anterior border of the mastoid process, and then emerges from the stylomastoid foramen. From this point it passes forward into the substance of the parotid gland, within which it divides into three great branches, known as *pes anserinus* (goose foot). One branch goes to the muscles of the forehead, the eyelid, and the upper portion of the malar zygomatic region. The second branch passes across the face, supplying the angle of the nose and the muscles that raise the upper lip. The third branch supplies the muscle at the angle of the mouth, the lower lip, the platysma, and the stylopharyngeus muscle.

At the exit of the nerve from the stylomastoid foramen one branch, the auricularis posterioris profunda, is given off, and goes to the muscles of

the neck. The interosseous portion of the facial nerve gives off a number of small branches, communicating with other nerves, as the fifth and the pharyngeus. The pneumogastric and sympathetic also give off special branches, the petrosals, stapedius, and chorda tympani.

The function of the nerve is to supply the muscles of expression, as mentioned above, and it is, therefore, a motor nerve. However, a certain amount of sensitive fibers are contained within it, due to its gross association with the other intracranical nerves.

THE SURGERY OF THE FACIAL NERVE.

The operative procedures for the cure of facial paralysis are:

1. Suture of the severed ends of the facial nerve.
2. Plastic operations.
   (*a*) The union of the facial and hypoglossal nerves.
   (*b*) The union of the facial and spinal accessory nerves.
   (*c*) The union of the facial and the glossopharyngeal nerves.

The first procedure, that is, the suturing of the accidentally severed ends of the facial nerve, seems to be unnecessary, because, if only moderate loss of substance between the two ends exists, the proximal ends of the nerve will regenerate and unite with the distal end without suturing.

In the plastic operations, the union between either the facial and spinal accessory or the glossopharyngeal, there are so many untoward symptoms following the procedures (*b*) and (*c*) that they have been practically abandoned and the union of the facial and hypoglossal nerves (*a*) practised instead.

The Methods of Anastomosing the Facial and Hypoglossal Nerves.—

1. End to end.
2. End to side.
3. Side to side.

The easiest method is the end-to-end operation, and it is the most productive of success, but it necessitates paralysis of the muscles of the tongue. The end-to-side operation is to be preferred in all cases, as paralysis of the tongue is avoided. The side-to-side procedure has only been performed once, and with a poor result.

Plastic Surgery of the Facial and Hypoglossal Nerves; Anastomosis of the Facial and Hypoglossal Nerves.—**Technique.**—(*a*) General anesthesia, the patient having been prepared as for any other major operation.

(*b*) An incision of the skin should be made, beginning at the tip of the mastoid process, near the lobe of the auricle, and extending downward and forward along the anterior border of the sternomastoid muscle to the level of the cricoid cartilage of the larynx.

(*c*) It should then be carried through the superficial fascia and the platysma muscle, thus exposing the sternomastoid muscle. The external jugular vein is usually sacrificed in this procedure, the severed ends being tied.

(*d*) The anterior border of the sternomastoid muscle and the internal jugular vein should be located, and retracted posteriorly, to expose the hypoglossal nerve, as shown in Plate XVI. The posterior belly of the digastric muscle is located more anteriorly and superiorly, as it extends from the mastoid tip to its pulley.

(*e*) The dimensions of the parotid gland, which is situated on the posterior border of the ramus of the inferior maxilla, should be determined as the facial nerve divides into three branches within its substance. Having located the boundaries of the parotid gland, trace the facial nerve to it. The facial nerve may then be traced backward and upward to its exit from the stylomastoid foramen.

(*f*) The hypoglossal nerve should then be isolated from the tissues covering it. It crosses the external carotid artery just below the point where the occipital artery is given off. The nerve should be exposed by blunt dissection as far posteriorly as possible, to free it from the tissues, so that it may be brought toward the stump of the divided facial, with which it is to be anastomosed.

(*g*) The facial nerve should then be drawn from the Fallopian canal as far as possible, and severed at the stylomastoid foramen. If it is not thus drawn from the canal it will be so short as to render the anastomosis difficult or impossible.

J. C. Beck has recently dissected the facial nerve from its bed in the Fallopian canal, a procedure which gives more latitude for stretching it so as to meet the hypoglossal nerve.

Having severed the facial nerve, the sheath covering its proximal stump should be removed with scissors to expose its axis cylinders (Fig. 468).

(*i*) Make an incision one-eighth inch long in the sheath of the hypoglossal nerve, in as close proximity to the stump of the facial nerve as possible (Plate XVI).

(*j*) The nerve fibers should then be separated with fine pointed dissecting forceps, so that when the barred axis cylinders of the facial stump are inserted into the hypoglossal incision they will be in direct contact with those of the hypoglossal nerve.

(*k*) A fine silk thread with a small round needle on either end should then be passed through the sheath of the facial nerve from without inward, and each needle passed through the sheath of the hypoglossal nerve from within the incision outward. The same procedure is then carried out on the opposite side of the facial nerve, as shown in Fig. 468.

(*l*) The operator and the first assistant each handle one suture, and draw it tight, while the second assistant separates the lips of the incision in the hypoglossal nerve, the third assistant guiding the pointed stump of the facial into the hypoglossal incision.

The anchor sutures (Fig. 469) are then tied. The axis cylinders of the two nerves are thus brought into direct contact.

The stump of the facial nerve should be directed toward the proximal end of the hypoglossal nerve, so that stimuli from the brain, coming through the hypoglossal, will be more readily transmitted to the facial nerve and carried to the muscle of facial expression.

PLATE XVI

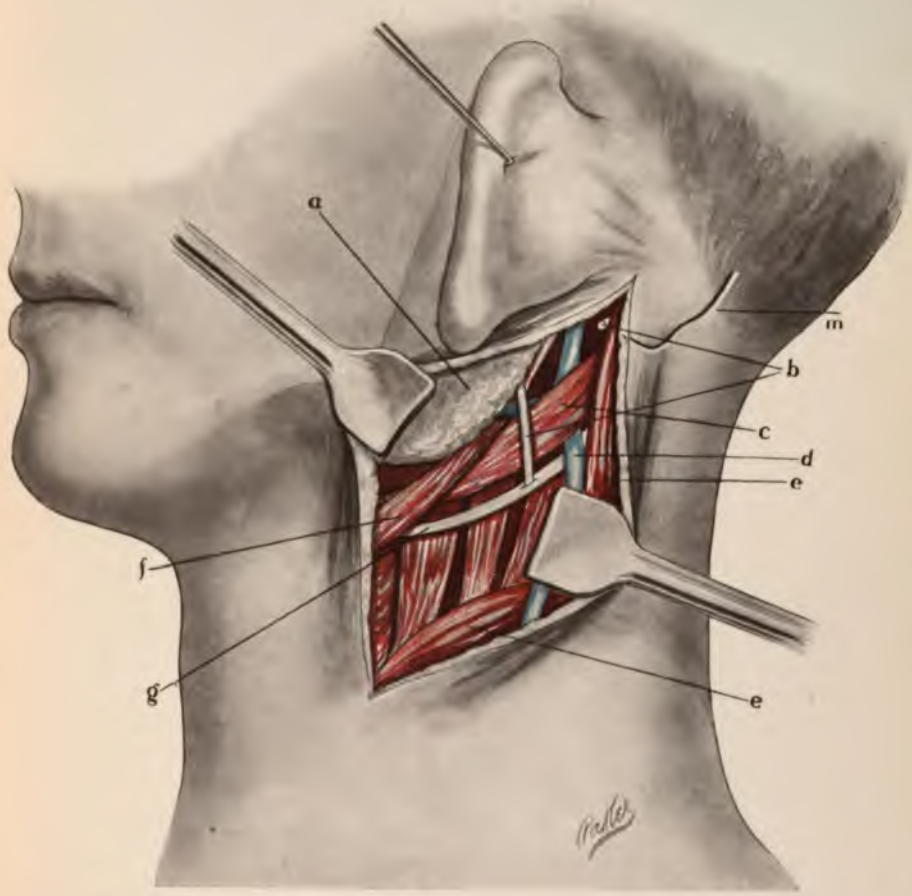

The Anastomosis of the Facial with the Hypoglossal Nerve. *a*, the parotid gland; *b*, the stump of the facial and the facial anastomosed with (*g*) the hypoglossal nerve; *c*, the posterior belly of the digastric muscle; *d*, the external jugular vein; *e*, the sternomastoid muscle retracted to expose the hypoglossal nerve; *f*, the omohyoid muscle; *g*, the hypoglossal nerve; *m*, the mastoid process.

The sutures should be tied with the greatest care. If too great a number of the axis-cylinder fibers of the hypoglossal are caught in the suture, there will be a certain amount of paralysis of the tongue (Fig. 469).

Fig. 468

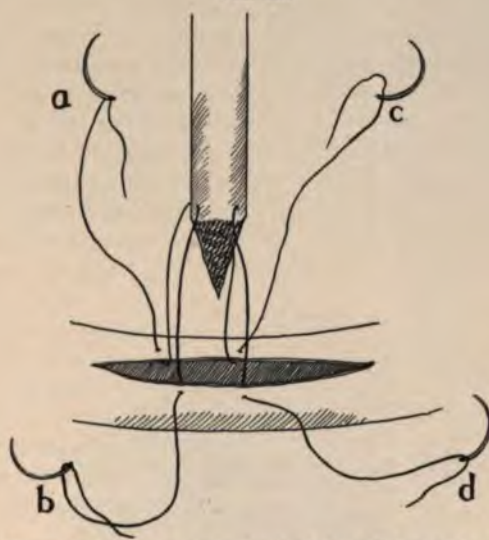

Schema showing the method of suturing the fascia of the facial with the hypoglossal nerve. *a b* and *c d*, double-needled anchor sutures.

Too great a tension of the hypoglossal nerve will also result in lingual paralysis, hence the necessity of drawing the facial from the Fallopian canal, and dissecting the hypoglossal nerve as far posteriorly as possible, to give it greater freedom of displacement toward the stump of the facial nerve.

Fig. 469

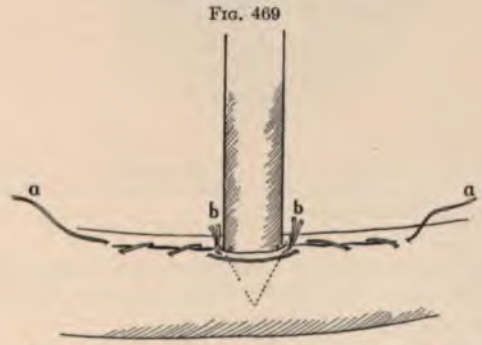

b b, anchor sutures holding the implanted facial nerve in position in the hypoglossus nerve; *a a*, a loose running suture closing the longitudinal incision in the hypoglossus nerve.

(*m*) A secondary continuous suture should then be passed through the lips of the hypoglossal incision, as shown in Fig. 469 *a a*. This suture should not be tied, but drawn tightly.

(*n*) The anastomosed nerves should be covered by a piece of cargile membrane, and the muscles of the neck replaced in their normal positions over the nerves. This prevents the formation of scar tissue and adhesions, which would greatly interfere with the success of the operation.

(*o*) The final step of the operation consists in suturing the superficial fascia and skin, drainage being unnecessary as the operative field is aseptic.

After-treatment and Observations.—The skin stitches should be removed in from five to seven days, and as soon thereafter as possible, massage and electric and tonic remedies should be instituted.

The earliest manifestations of the proper union of the nerves is the appearance of a certain amount of tonicity in the muscles of the paralyzed side of the face. This change is only an indication that anatomical union

Fig. 470

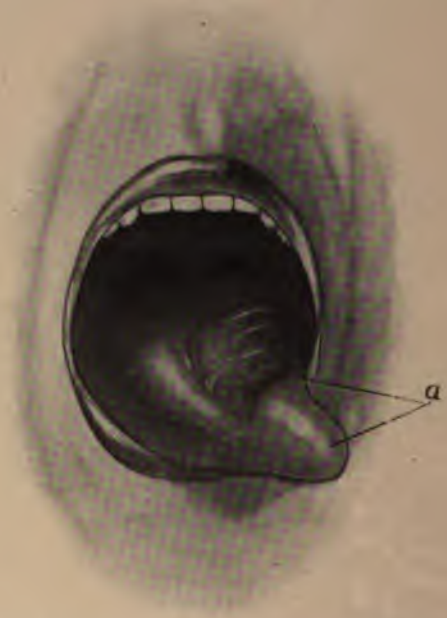

Partial lingual paralysis shown upon protrusion of the tongue, due to the injury of a few of the fibers of the hypoglossus nerve at the time of the union of the facial and the hypoglossus nerves. *a*, the area paralyzed. (Dr. J. C. Beck's case.)

has occurred, and should not be construed as a beginning of functional activity. On the contrary, it may be weeks, months, or even a few years before functional activity is manifested.

The first sign of functional activity is a slight contraction of the muscles supplied by the lower of the three branches of the pes anserinus, namely, the muscles of the lower lip and the angle of the mouth. At a little later period the muscles of the upper lip and of the forehead show functional activity.

A still later development is the contraction of the facial muscles simultaneously with the act of deglutition. This gradually increases until the contraction on the paralyzed side is greater than on the unaffected side, and is very disagreeable to the patient.

The simultaneous contraction of the facial and hypoglossal muscles annoys and confuses the patient. He soon learns, however, to dissociate the movements, and is able to swallow with a constantly decreasing degree of facial distortion, until finally the facial muscles remain quiet during the act of deglutition.

The final and most desirable result is the voluntary contraction of the facial muscles independent of the act of swallowing.

The time equired to obtain such a result varies greatly, depending upon the amount of muscle degeneration before the operation, the accurate apposition of the two nerves, and the general condition of the patient.

The reaction of the muscles supplied by the facial nerve should be tested with the electric current, in long-standing cases, to determine whether they are still active. If contractions are not produced—that is, if complete atrophy of the muscles is present—it is useless to operate. The contraction of the masseter muscles should not be mistaken for the contraction of the facial muscles. One case of fourteen years' standing was successfully operated.

CHAPTER L.

DISEASES OF THE PERCEPTION APPARATUS. AUDITORY NERVE APPARATUS.

HYPEREMIA OF THE LABYRINTH.

Etiology.—The etiology is generally associated with either congestion of the middle ear or the contents of the cranial cavity. It is rarely primary in the labyrinth. It is usually found in acute suppurative otitis media following scarlet fever, diphtheria, and typhoid fever. It may also be caused by the other exanthematous fevers, pneumonia, encephalitis, mumps, puerperal fever, meningitis, and tumors at the base of the brain. Thrombi in the sinuses of the petrous portion of the temporal bone and the internal jugular vein, goitre, angioneurotic congestion of the cranial vessels, intracranial affections of the trigeminus, diseases of the medulla oblongata, and the internal use of quinine, salicylic acid, and amyl nitrite may also cause it (Politzer).

Symptoms.—The symptoms are tinnitus, slight feeling of fulness in the head and ears, nausea, vomiting, and unsteady gait. The handle of the malleus may be injected, and, when present, denotes a general hyperemia of the organ of hearing. The face and auricle may in rare cases be red. If there is a sense of dazzling whiteness before the eyes, the hyperemia is probably of intracranial origin.

Treatment.—If the hyperemia is secondary to middle-ear inflammation, special attention should be addressed to that disease, and with the subsidence of the middle-ear disease the labyrinthine symptoms will disappear. The patient should be put in bed, given laxatives, and have leeches applied to the nape of the neck and mastoid process. If there is active inflammation in the middle ear and mastoid process, the ice-bag or Leiter's coil should be applied to the mastoid region.

If the disease arises from an intracranial lesion, the treatment, should be addressed to that condition, the ice-bag applied to the vertex, saline cathartics given, and alcoholic beverages and tobacco prohibited. In general, the habits should be well regulated, constipation prevented, and the beneficial effects of fresh air and sunshine should be taken advantage of by the patient.

ANEMIA OF THE LABYRINTH.

Etiology.—The etiology is usually a co-existing general anemia. It may exist, however, as a local condition, due to the obstruction of the internal auditory artery from aneurysm of the basilar artery, neoplasms

of the dura or brain extending into the internal auditory canal, emboli of the internal auditory artery, and atheromatous constriction of the internal auditory artery.

Symptoms.—In the angioneurotic and posthemorrhagic forms, the symptoms closely simulate those of seasickness; there is nausea, vomiting, severe tinnitus aurium, deafness, facial pallor, and dizziness. All these symptoms disappear with the return of the blood to the normal state. In the chronic form the tinnitus and deafness are the chief symptoms.

Treatment.—If the labyrinthine anemia is angioneurotic in origin, the neurosis should receive appropriate attention; perhaps a long sea voyage, residence in the mountains or at the seashore, primitive camp life, etc., might be beneficial. If it had its origin in an excessive hemorrhage, transfusions of normal saline solution should be given, or spontaneous relief may come after a more or less prolonged period of waiting. If it occurs in one who is subject to repeated severe hemorrhages, the duration of the ear symptoms is somewhat prolonged, and means to prevent the recurrances of the hemorrhages should be carefully considered in the treatment. In the angioneurotic type the internal administration of the bromide of soda and the application of the galvanic current to the sympathetic nerves of the neck are indicated.

HEMORRHAGE INTO THE LABYRINTH.

Small hemorrhages into the labyrinth may occur during the course of the exanthematous fevers, on account of the increased blood pressure and the rapid degenerative changes which sometimes characterize the progress of the diseases. The hemorrhages also occur in caisson workers and divers, and in prolonged suffocative seizures. Diabetes, nephritis, and sudden cessation of menstruation also cause it. Atheromatous degeneration of the walls of the arteries predispose to labyrinthine hemorrhage.

More extensive hemorrhages into the labyrinth occur in fractures of the skull, involving the petrous portion of the temporal bone; from severe contusions of the skull; from extension of carious processes in the temporal bone, and from primary and tuberculous meningitis (Politzer).

Course and Termination.—The course and termination of the hemorrhages into the labyrinth are obviously variable, according to their severity and origin. The blood clots persist in the labyrinth for a variable time, after which they may be absorbed, become organized, or the epithelium, connective tissue, nerve elements, etc., involved by the pressure may become atrophied and degenerated. Politzer reports a case which ended in suppuration.

MÉNIÈRE'S DISEASE.

This condition is characterized by sudden and complete loss of hearing, attended by tinnitus, nausea, vomiting, and vertigo, without a previous history of ear disease. It is supposed to be due to a hemorrhage into the labyrinth. The patient is usually robust, middle aged, and has never previously complained of deafness. At the onset of the attack he sometimes falls unconscious to the ground. In a case seen by the author the attack came on at night. The patient upon attempting to rise in the morning had severe dizziness (indeed, could not walk), nausea, vomiting, tinnitus, and complete deafness. The history of the case showed that two years previously the left ear was similarly affected, the hearing remaining almost *nil* in that ear, the right being normal. It is now ten years since the last attack, and the hearing is but little improved.

The hearing by bone conduction is lost if the affection is bilateral, and if it is unilateral the sound of the tuning-fork, when placed on the vertex, will be lateralized toward the sound side.

The *course* of Ménière's disease varies. The unconsciousness rapidly disappears, and the vomiting a little more slowly. The dizziness and staggering gait remain for several days. In my case the patient had a tendency to walk to the right, into the gutter or walls of buildings, for four or five weeks after the apoplectiform attack. He was dazed, and thought slowly for some weeks. His handwriting was not tested. Guye and Politzer report that for a time the handwriting is like that of a tremulous old man. The unsteady gait may persist for years. Relapses usually occur, although there are exceptions to the rule.

Diagnosis.—The diagnosis of Ménière's disease can only be made with certainty when the patient is examined immediately after the seizure. If, then, the middle ear, drumhead, and Eustachian tubes appear normal and the patient gives the clinical picture just described, and there is no paralysis of other cranial nerves, a diagnosis of Ménière's disease may be made.

Prognosis.—The prognosis is unfavorable, little improvement being reported in the cases thus far recorded.

Treatment.—The treatment is directed principally to the relief of the dizziness, nausea, and vomiting. The patient should be placed in bed with the head slightly raised, to avoid the necessity of changing his position in giving food and medicines. This precaution should be observed for a few days while the symptoms are annoying. Cold compresses to the head, mustard plasters to the nape of the neck and calves of the legs, and the administration of purgatives may hasten the disappearance of the annoying symptoms. The tinnitus is often relieved by the administration of quinine and the iodide of potash, or, what is probably preferable, iodonucleoid, in which the iodine is united with nucleinic acid, thus rendering it readily digestible and easily and rapidly absorbed, without irritation of the stomach. If the quinine causes mental excitement and increased tinnitus, its use should be discontinued

(Charcot). It should be given in two to five-grain doses three times daily for six or eight weeks. The iodide of potash (or iodonucleoid) may be given for three or four weeks.

To promote absorption of the blood clot and exudate, pilocarpine, in 2 per cent. solution, may be injected 4 to 10 drops daily; or it may be given internally for the same purpose. Its use should not be begun until about the third week, when the acute symptoms have subsided.

MÉNIÈRE'S SYMPTOM COMPLEX.

This condition, while similar in its manifestations in many respects to Ménière's disease, should not be confounded with it. Ménière's symptom complex is characterized by dizziness, staggering gait, nausea, tinnitus, and more or less deafness, *with a distinct history of previous deafness and ear disease.* The deafness is not sudden and complete, nor are the profound disturbances found in true Ménière's disease present. The author once saw a case in consultation, in which nearly all the signs of Ménière's disease were present, the exceptions being: (*a*) There was a history of previous deafness and ear disease; (*b*) the deafness was not sudden or profound; (*c*) inflation of the middle ear through the Eustachian catheter gave immediate and complete relief of all the symptoms. The case was one of Eustachian catarrh, complicating a similar process in the epipharynx. The air in the middle ear became gradually rarefied by the absorption of the oxygen from it by the blood, the drumhead was retracted, and pushed the foot plate of the stapes inward, thus compressing the intralabyrinthine fluids, and giving rise to the foregoing phenomena. The same phenomena may be due to chronic catarrhal adhesive processes. According to Politzer, a great majority of the cases are due to a temporary congestion of, or exudation into, the labyrinth, arising in the course of middle-ear affections, which bring about an irritation of the vestibular and ampullar nerves.

Dr. Geo. E. Shambaugh recently advanced the idea that the tinnitus attending this affection is due to a disturbance of the relation of the membrana tectoria to the hair cells of the organ of Corti. He holds that the membrana tectoria is the resonator of the perception apparatus, whereas according to Helmholtz the basilar membrana is the resonator. (See Physiology of the Labyrinth.)

The use of the tuning-fork enables the observer to differentiate between those cases of middle-ear origin and those of labyrinthine origin. If with marked diminution of hearing there is positive Rinné, with hearing for low tones preserved, the lesion is in the labyrinth; if, on the contrary, there is a negative Rinné, with loss of hearing for low tones, the lesion is in the conduction portion of the temporal bone, *i. e.*, in the middle ear or Eustachian tube. If the disease is unilateral, the vibrating tuning-fork placed upon the vertex will, if the lesion is in the middle ear or Eustachian tube, lateralize toward the affected side; whereas, if it is in the labyrinth it will lateralize toward the normal or unaffected side.

Some cases reported by Pritchard and Lake had an epileptiform type, with a tendency to fall toward the affected side. The room seemed to whirl, the face became pale, the eyes dull, skin covered with cold perspiration, and the pulse was small and often retarded.

The course of the symptoms is extremely variable, lasting from a few moments to several days or weeks.

Treatment.—In those cases due to hyperemia of and exudation into the labyrinth the same treatment recommended under hyperemia of the labyrinth is of value here. If the lesion is in the Eustachian tube or middle ear the remedies suited to the condition present should be used. Quinine is perhaps more valuable for the relief of the tinnitus than it is in Ménière's disease. Pneumomassage, especially rarefaction (suction)

Fig. 471

Siegle's otoscope.

of the air in the external meatus, in either the middle ear or labyrinthine type, is highly beneficial in many cases. Its *rationale* is in the outward movement of the drumhead, thus relieving the pressure upon the foot plate of the stapes, and in the labyrinthine type the lessened pressure in the middle ear relieves the labyrinthine congestion. Rarefaction can be practised by means of a rubber tube with a meatal tip, the patient supplying the suction power with his mouth at the other end of the tube, or it may be done with an electromotor engine and pump, to which is attached Siegle's otoscope (Fig. 471). The Victor electromotor engine and pump is so constructed as to give either rarefaction, condensation, alternate condensation and rarefaction, intermittent rarefaction, or constant rarefaction, hence it is admirably adapted to the needs of the otologist.

INFLAMMATION OF THE LABYRINTH; OTITIS INTERNA; LABYRINTHITIS.

Acute Primary Inflammation of the Labyrinth (Voltilini).—This type of labyrinthitis is usually mistaken for an acute meningitis. There are differences, however, which will enable one to make a differential diagnosis. Voltilini gives the following characteristics: (*a*) It occurs in children who were previously healthy, (*b*) with a sudden rise of temperature, (*c*) the face very red, (*d*) vomiting, followed by (*e*) unconscious-

ness, delirium, and convulsions; (*f*) after a few days all these symptoms disappear, (*g*) leaving the patient totally deaf and with a staggering gait, which persists for some time.

Acute Labyrinthitis Secondary to Meningitis.—This is followed by total deafness and sometimes by a staggering gait. The acute symptoms usually continue for several weeks, whereas in the acute primary inflammation of the labyrinth of Voltilini the acute symptoms disappear in a few days. Politzer calls attention to the fact that an intracranial affection may lead to a total paralysis of the acoustic nerve, generally involving some of the other intracranial nerves as well; but that it does not necessarily do so, as pointed out by Gottstein, in the abortive type of epidemic cerebrospinal meningitis. Hovell also questions Voltilini's conclusions. It seems to the author that, while Voltilini may have erred in reaching such a broad conclusion, namely, that those cases presenting the meningeal symptoms for only a few days, followed by deafness and staggering gait, were all acute primary inflammations of the labyrinth. He should, nevertheless, be given the credit for calling attention to the fact that some of the cases presenting this clinical history are, in all probability, limited to the labyrinth, although some of them are probably abortive types of meningitis.

Chronic Primary Inflammation of the Labyrinth.—To Politzer belongs the honor of first reporting the anatomical and microscopic appearances of a case of chronic primary inflammation of the labyrinth. In his case the following facts are of interest: (*a*) A boy was affected by fever of two weeks' duration; (*b*) aural discharge from both ears until the sixth or seventh year of age; (*c*) at no time was there a staggering gait; (*d*) he died at the age of thirteen of acute peritonitis. The post-mortem findings: (*e*) No middle-ear involvement, except ankylosis of the foot plate of the stapes in both ears; (*f*) the cavities of the cochlea, vestibule, and semicircular canals were filled with newly formed bone tissue; (*g*) the acoustic (auditory) nerve fibers were unchanged up to the point of entrance into the new bone tissue.

The *types of primary inflammation* of the labyrinth are, according to Gruber, plastic and exudative. The first is a simple hyperplasia, while the latter may be serous, serohemorrhagic, or purulent.

The causes of secondary inflammation of the labyrinth are injuries, and in the purulent type the labyrinth is invaded by germs. The other causes are generally obscure, and are variously designated as resulting from a "cold," metastasis, etc. It is undoubtedly sometimes due to syphilis, tuberculosis, and the exanthemata, as well as to meningitis. A frequent cause of the secondary inflammation is caries and necrosis extending from the middle ear, especially in connection with a tuberculous process in these parts.

Pathology.—The pathological findings following inflammation of the labyrinth are: (*a*) Newly formed connective tissue; (*b*) calcareous degeneration, (*c*) hyperostosis of the osseous walls of the labyrinth; (*d*) bony hyperplasia in the spaces of the labyrinth; (*e*) angio-connective-tissue growths in the cavity of the labyrinth; (*f*) thickening of the semi-

circular canals, utricle, ampullæ, and saccule; (*g*) tation, and calcium salts in the membranous lab thickening on the inner wall of the saccule, utric cochlea (Politzer); (*i*) fatty degeneration and atr Corti; (*j*) necrosis in the tuberculous and syphiliti those cases having their origin in (*k*) necrosis of the

Symptoms.—In Voltilini's type of acute prim the labyrinth the disease is ushered in (in children) temperature, the face is quite flushed and red, with unconsciousness, delirium, and convulsions. Wit symptoms entirely disappear, leaving the patient q staggering gait, which may persist for a long time. ary to meningitis the meningeal symptoms usual weeks, and leave the patient deaf and sometimes w The chief diagnostic point is in the shorter duratio geal symptoms in the primary inflammation of the

In the *secondary form* the symptoms are more o cated by those of the primary affection. The fun ing must be chiefly depended upon for the diagnosi are those of labyrinthine disease in general, namely conduction on the affected side, and (*b*) loss of hear of the Galton whistle. In exceptional cases the h is not affected, even in pronounced destructive of the tuning-fork and whistle, the Weber test of hearing toward the unaffected side, while th The tests should be applied on several occasions final opinion.

The *subjective symptoms* are: more or less deafn plete and sudden), tinnitus, a feeling of fulness or o giddiness, vomiting, and a staggering gait.

Inflammation of the labyrinth following cere may occur at the beginning of the disease or at it being unconscious and in bed, the deafness and often not noticed until the mind is clear and the pat In the type secondary to scarlet fever and diphth inflammation usually follows an otorrhea.

Prognosis.—The prognosis is usually unfav wisely said that the percentage of cures and im much larger in the hands of the general practitione specialists; he accounts for this by the fact that th sees the case early, before the changes are so mark conclude that the prognosis is more favorable if t The prognosis is also more favorable when there ment. If, during convalescence, the patient hears has perception for musical tones, the prognosis is m Politzer reports that in his experience there may be ing, with subsequent loss of it. If a child is affe to speak, or soon afterward, he will become a dea

purative type, pachymeningitis, in the posterior cranial fossa may occur, the infection passing through the sheath of the auditory nerve.

Treatment.—The treatment, on the whole, is not likely to result in the restoration of the faculty of hearing. There are other considerations, however, that render it quite important that appropriate treatment be given. For example, (*a*) the extension and severity of the pathological process may be favorably modified; (*b*) the case may be of recent syphilitic origin, and yield to treatment; (*c*) the intensity of the fever may be modified, and thus save the life of the patient; and (*d*) the child may be prevented from becoming a deaf-mute by appropriate training given at the proper time.

If the disease is secondary to an inflammatory affection of the middle ear or epipharynx, this should be carefully attended to. The functional activity of the bowels and kidneys should be watched and regulated. Calomel, followed by saline cathartics, may prove of value. If the temperature is high, the pulse rapid and hard, and the skin dry, antipyrine in v–x gr. doses, hourly, for four to six hours, followed by gr. x of Dover's powder and a hot lemonade, will lower the temperature and pulse and moisten the skin, and thus greatly relieve the patient of discomfort and delirium. Leeches may also be applied over the mastoid process for the same purpose. In the meningeal types, and in the acute primary inflammation of the labyrinth, ice-bags to the head are of great aid in relieving the fever and delirium. Iodide of potassium, or iodonucleoid, and mercury may be given in syphilitic cases, especially if they are recent. They are of no value in the congenital types. Blisters and counterirritants over the mastoid and in front of the ear may also be tried.

If the child has not yet learned to speak, he will surely be a deaf-mute, and should be placed in a school where he will receive careful training. If he has learned to speak, and is under seven years of age, he will almost certainly lose the speech already acquired unless vigorous and intelligent attempts are made to perpetuate it. If he is more than seven years old, he is much more apt to retain his speech and use it in conversation. It is important, therefore, that the physician should impress upon the family the need of special training, to prevent the child becoming a deaf-mute. He may be deaf, but he need not necessarily also become a mute. (See Deaf-mutism.)

PANOTITIS.

This affection is characterized by an inflammation involving, simultaneously or in rapid succession, the middle ear and labyrinth. It usually has its origin in scartalinodiphtheria, affecting both ears, which in a short time causes complete deafness. The prognosis is very unfavorable, although some German writers have reported good results under treatment. Pilocarpine injections in small doses for several months have apparently given good results in a few cases. The iodide of potassium, iodide of ammonia or iodonucleoid, and mercury are also recommended.

LEUKEMIC DEAFNESS.

Leukemic deafness is characterized by either sudden and complete deafness and Ménière's symptoms, or by moderate deafness, which speedily grows worse until, within a few weeks or months, there is total deafness. In acute leukemia the deafness, etc., occur in the early stage of the disease; whereas in chronic leukemia the deafness and other ear symptoms usually appear in the later stages. The pathological changes consist of accumulations of lymphocytes, and hemorrhages into the labyrinth, followed by a reactionary inflammation of the endosteum and membranous labyrinth, which finally results in connective-tissue obliteration and partial ossification of the labyrinth (Politzer). The prognosis is obviously unfavorable.

OTITIS INTERNA PAROTITICA.

Mumps being an infectious disease, and the site of infection being anatomically in close proximity to the labyrinth, the infection may be carried to it by metastasis, or it may be carried through the Gasserian fissure. The symptoms are slight vertigo, with or without vomiting, and sudden deafness on one or both sides. Iodides internally sometimes act favorably upon the course of the disease.

SYPHILIS OF THE INTERNAL EAR; SYPHILITIC OTITIS INTERNA.

The syphilitic diseases of the labyrinth usually appear at the end of the secondary or at the beginning of the tertiary stage. Politzer, however, reports a case in which there was labyrinthine involvement seven days after the initial lesion. It may involve the labyrinth in common with the middle ear, or as one of the signs of a general infection, or it may be limited to the internal ear.

Pathology.—The pathology is but little known, as only a few cases have been carefully studied. From the examinations made it appears that there is either thickening of the periosteum of the vestibule (Toynbee, Moos), the foot plate of the stapes displaced and fixed, small-cell infiltrations and hyperplasia of the connective tissue between the membranous and bony labyrinth; also infiltration of Corti's organ, the ampullæ, and membranous semicircular canals (Moos). The canals and spaces of the labyrinth have also been found filled with new bony tissue. The acoustic nerve may or may not be affected. Adhesive bands, hornification, atrophy and destruction of the ganglionic cells, and syphilitic endarteritis (Baratoux and Virchner) have been reported.

Symptoms.—The symptoms are those of labyrinthine involvement in general, namely, loss of hearing by bone conduction, and for high tones. If the affection is unilateral (rare), the Weber experiment will

show lateralization of hearing to the normal side, and Rinné will be decidedly plus upon the affected side. The symptoms may appear suddenly, with tinnitus, deafness, dizziness, and staggering gait. The deafness may become complete and permanent, the tinnitus increasing at the same time. The staggering gait and dizziness may disappear after a few weeks or months. Diplacusis and pain in the ear may be present, the pain being due to a periosteal growth in the labyrinth.[1]

Objectively, the signs of syphilis of the internal ear may be wanting. It is only when the middle ear, or Eustachian tube, and labyrinth are simultaneously involved that objective signs are found. There may then be the usual appearance of a catarrhal otitis media, or the characteristic swelling of the mucosa of the Eustachian tube. Syphilitic ozena of the nose and epipharynx may also be present.

Course.—In most cases the deafness develops gradually for some weeks or months, remains stationary, and then, after a variable interval, suddenly becomes much worse. More rarely the deafness comes on suddenly. Slight exciting causes may cause a rapid increase in the deafness. Concussions on the head, blows, etc., have been known to do it. In rare cases improvement and recovery take place, and hearing by bone conduction gradually returns.

Diagnosis.—The differential diagnosis between syphilis, hyperostosis of the bony capsule of the labyrinth, and other forms of labyrinthine disease is not always easy. If there are evidences of the secondary or tertiary manifestations of syphilis, it is easy to make a diagnosis. Unfortunately, in many cases no such obvious signs are present, and the diagnosis is, therefore, much obscured. Politzer observes that "those forms of severe or total deafness which usually develop in both ears during childhood must be regarded as syphilitic affections of the labyrinth. Such cases were formerly supposed to be due to scrofula." The diagnosis of hereditary syphilis is aided by the presence of middle-ear catarrh, purulent otitis media, adhesive processes of the middle ear, and chronic interstitial keratitis (opacity of the cornea).

Prognosis.—Recent cases offer a favorable prognosis, while older ones are quite unfavorable. The degree of deafness is not a safe guide in giving a prognosis, as totally deaf cases have been known to recover, while others, with mild deafness, have remained unimproved. General debilitating diseases render the prognosis more grave. The hereditary type, with opacity of the cornea, is unfavorable.

Treatment.—Mercurial injections, with the internal administration of iodonucleoid or iodide of potassium, are indicated. Pilocarpine injections, 4 to 12 drops daily, beginning with 4 drops and increasing to 12 drops, sometimes influences the case favorably (Politzer, Bacon, Gradenigo). The injection of solutions of the iodide of potassium into the middle ear through the Eustachian catheter, as recommended by Politzer, is not to be generally recommended. The *technique* of such a procedure opens it to extreme liability of carrying infection into the

[1] Moss and Steinbrugge, Z. f. O., vol. xiv.

middle ear. Under strict antiseptic precautions and a knowledge of the extremely small size of the tympanic cavity, and the technique of the whole procedure, the danger of infection disappears; and it is possible, though to my mind not probable, that the injection of a solution of the iodide of potassium will affect the course of the disease favorably. The injections of iodoform, iodine vasogen, mercurial ointments, etc., are more rational methods of treatment. It should not be forgotten, however, that the disease is essentially a systemic one.

SUPPURATION OF THE LABYRINTH.

Labyrinthine suppuration probably occurs in about 1 per cent. of the cases of middle-ear suppuration. It has rarely been diagnosticated, because the subjective symptoms are not absolutely characteristic, and because the condition has not been generally understood by otologists until within the last few years. Suppurative leptomeningitis is a serious sequela or complication of labyrinthine suppuration, and the symptoms in some respects are quite similar, hence it is quite probable that many of the cases diagnosticated as leptomeningitis have been labyrinthine suppuration, at least in their initial manifestation.

Etiology.—Suppurative otitis media, with involvement of the mastoid antrum, is the most common cause of disease, though scarlet fever, measles, influenza, and tuberculosis may also cause it. In the 45 cases reported by Bezold about 50 per cent. were in children. The vulnerable points through which the infection may take place are the round and oval windows and the pneumatic spaces around the labyrinth. The retention of the secretions and the accumulation of cholesteatomatous material in the attic, aditus ad antrum, and the antrum may cause pressure necrosis, and thus expose the horizontal and perpendicular semicircular canals to infection. The facial nerve may also be exposed by the same process, as it lies in close proximity to the horizontal semicircular canal in the floor of the antrum. The pneumatic spaces sometimes extend behind the labyrinth, hence the labyrinth may be invaded from this direction. The cells beneath the floor of the middle ear also extend beneath the labyrinth, and should necrosis extend in this direction, labyrinthine involvement may follow. The promontory is rarely the seat of necrosis except when there is extensive destruction of bony tissue in which the promontory is involved. When such a condition is present, granulations usually spring from the area, and the use of a probe-point shows roughened bone or a perforation.

The value of ocular myoseismia in the differential diagnosis of cerebellar abscess and suppuration of the labyrinth is pointed out by Neumann. In suppuration of the labyrinth the myoseismia (Neumann calls it nystagmus) becomes less and less marked, and finally disappears as the suppuration extends; while in cerebellar abscess the myoseismia increases as the disease progresses. In suppuration of the labyrinth it occurs in the beginning, when the eye is turned toward the diseased side;

whereas the strabismus may disappear and the myoseismia still be present when the eye is turned to the well side. In cerebellar abscess the conditions are reversed, and the myoseismia is first observed when the eye is turned to the normal side, and is later turned to the diseased side. When this form of myoseismia is observed a positive diagnosis of cerebellar abscess can be made. Another point in the diagnosis is that, after the labyrinth has been opened by operation, the myoseismia due to the labyrinth trouble rapidly subsides, while the myoseismia due to the cerebellar abscess remains the same.

The etiology of the extension of the labyrinthine suppuration is explained by the avenues of least resistance which extend in that direction, viz., the internal auditory meatus (sheath of the auditory nerve) and the cochlear duct. The infection may also gain entrance to the cranial cavity through a dehiscence or a necrosis of the perpendicular semicircular canal. If the infection extends through the cochlear duct it enters the subarachnoid spaces and is necessarily a very dangerous condition.

The intracranial complications most apt to attend labyrinthine suppuration are suppurative meningitis and extradural abscess, though abscess of the cerebrum and cerebellum and infective lateral sinus thrombosis occasionally occur.

Symptoms.—When rightly understood the symptoms of labyrinthine suppuration are usually very well defined. There are certain characteristic symptoms which should at least lead to a tentative diagnosis. The objective symptoms are not usually obvious, though in some cases the presence of granulations, roughened bone, and the oozing of pus from the inner wall of the middle-ear cavity may be seen. When present they may appear at one of three places, namely (*a*) the round window, (*b*) the oval window, or (*c*) the promontory. Facial paralysis may also be present, as the facial nerve is often involved in the necrotic process attending the suppurative labyrinthitis.

Diagnosis.—The diagnosis may be made without the foregoing objective signs in many cases from the presence of pronounced deafness, tinnitus, vertigo, and headache. The deafness is more pronounced than is usual in middle-ear disease. The hearing for the tuning-forks and whistles is usually greatly diminished at both the lower and upper limits, more particularly the upper, or it may be entirely lost. Bone conduction is greatly diminished or entirely lost. The vertigo may be accompanied by nausea and vomiting. Horizontal nystagmus (ocular myoseismia) has been observed by Neumann.

The *deafness* may be partial or complete, depending upon whether the labyrinth is completely or partially destroyed. Goldstein, of St. Louis, and others have reported cases in which there was exfoliation of the cochlea, in which there apparently still remained considerable power of hearing. Bezold, Hovell, Hartmann, Corradi, Politzer, the author, and others have shown that even with the most complete precautions it is impossible to exclude hearing with the unaffected ear. The meatus of the sound ear may be ever so tightly stopped, and still admit some

sound waves which may be heard. Then, too, sound waves may reach the normal ear by bone conduction. Pynchon has suggested the use of a long speaking-trumpet, to remove the source of sound as far as possible from the normal ear. Even with all these, and other precautionary measures, the sound waves seem to leak through the barriers to the other ear. It is not probable, or even possible, that the sound waves are perceived by the stump of the auditory nerve after its endings in the labyrinth have been destroyed.

Paresis or *paralysis* of the facial nerve is present in all cases in which the cochlea is exfoliated. This is accounted for by the intimate anatomical relationship of the parts, the nerve being either pressed upon or destroyed by the necrotic process and the exfoliation of the cochlea. The nerve is affected in about 55 per cent. of the cases. Hovell divides the course of the nerve into four parts, namely: (*a*) Within the internal meatus, where it is liable to be affected in the exfoliation of the entire labyrinth, and give rise to permanent impairment—complete or partial—of the function of the facial and auditory nerves. (*b*) The second division extends from the beginning of the aqueductus Fallopii to the geniculate ganglion, and is less liable to injury. (*c*) The third division passes in close proximity to the vestibular walls, and, in case of vestibular necrosis, the nerve is in great danger. (*d*) The fourth division, or lower portion, passes downward through the mastoid process, and is in danger when there is extensive mastoid necrosis, but is in little danger from labyrinthine necrosis. Exuberant granulations may exert pressure upon the sequestrum, and thus give rise to facial paralysis.

Restoration of the Facial Nerve.—Bezold and others have reported cases in which there was undoubted loss of the substance of a portion of the facial nerve in the course of necrosis of the labyrinth, in which there was subsequent regeneration and restoration of its function. The chorda tympani is more often destroyed than the facial nerve, and is often restored. It seems, therefore, that there is a strong regenerative power in the facial nerve when destroyed by necrosis, and when it is severed in an operation. One should not infer from this statement, however, that he should regard the facial nerve with indifference during a mastoid operation, as many do not thus regenerate and resume their function. The surgical anastomosis of the facial with the hypoglossal nerve (see pp. 841 and 847) offers a means for re-establishing the movements of the muscles supplied by it, and the dread of facial paralysis is somewhat lessened, though by no means removed.

The *sequestra* vary in size and anatomical composition. The whole petrous portion may come away, the cochlea alone or with contiguous bone, the labyrinth, or the semicircular canals (one or more) may be exfoliated.

Contrary to the opinion expressed by Blake and Reik, in their classical treatise on the *Surgical Pathology and Treatment of the Diseases of the Ear*, I believe labyrinthine suppuration may usually be diagnosticated before operative interference is instituted.

The following comparative table shows the symptoms present in

middle-ear suppuration, and in middle-ear suppuration combined with labyrinthine suppuration:

Middle-ear Suppuration.	*Middle-ear Suppuration Combined with Labyrinthine Suppuration.*
1. Moderate deafness.	1. Pronounced deafness.
2. Range of hearing, lower tone limit lost.	2. Low and high tone limits lost, or the deafness is complete
3. Bone conduction increased	3. Bone conduction diminished or entirely abolished.
4. Aural vertigo absent.	4. Aural vertigo present.
5. Tinnitus not pronounced.	5. Tinnitus pronounced, especially early in the disease.
6. Facial paralysis is occasionally present.	6. Facial paralysis is frequently present.
7. No granulations, and oozing of pus from the inner tympanic wall.	7. Granulations and pus oozing from the inner tympanic wall.
8. Pus on inner wall when wiped away does not soon return.	8. Pus on inner wall when wiped away soon returns.
9. Probing shows no carious bone on inner wall.	9. Probing occasionally shows carious bone on inner wall.
10. Meningeal and intracranial symptoms may be present.	10. Intracranial symptoms may be present.
11. Spinal puncture shows normal spinal fluid.	11. Spinal puncture shows cells and bacteria if the invasion of the cranium is through the cochlear duct.

Prognosis.—The prognosis is always grave, 20 per cent. of the 47 cases collected by Bezold ending fatally, though spontaneous recovery (as to life) may occur. The hearing is usually greatly impaired, whether the recovery is spontaneous or through surgical interference. The facial paralysis may or may not be present, or, if present, may or may not be permanent. Conservative operative treatment does not add to the mortality rate, though it may increase the degree of permanent deafness.

Treatment.—The treatment of necrosis and suppuration of the labyrinth is obviously surgical, and the following indications should be met, viz.: (*a*) The morbid material should be removed; (*b*) free drainage should be established and maintained; and (*c*) asepsis (surgical cleanliness) of the parts should be maintained until regeneration (healing) is complete.

(*a*) *The removal of the morbid material* should be effected through the external meatus or the mastoid process. If the meatus is crowded with granulations, they should be removed with Wilde's snare, the forceps, curettes, or caustic applications of chromic acid. The granulations may be still further controlled by the instillation of alcohol. It may then be possible to remove the sequestrum through the meatus without further operative interference. In some cases it will be necessary to remove the posterior wall of the meatus, while in others the mastoid process will have to be opened. Where the sequestrum is large, the radical mastoid

operation will have to be performed. Having removed the sequestrum in one of these ways, the other morbid material, as small particles of bone, granulations, cholesteatomatous material, pus, etc., should be sedulously looked for and removed.

(*b*) *The maintenance of free drainage* is accomplished by removing the morbid material—sequestra and granulations—thereby enlarging the drainage channel, and by the use of gauze dressings in the diseased cavities. The gauze carries the secretions outward to the external gauze pads, and thus free drainage is established.

(*c*) *The maintenance of asepsis*, the third indication, is met by the establishment of the free drainage, whereby the infective material is constantly discharged, and after a time, there being no more infective material within the wound, the gauze dressing effectually prevents the entrance of infective material. This state of affairs should be maintained until regeneration or epidermization is complete.

It may be necessary in those cases where the posterior wall of the meatus is removed, and where a radical mastoid operation is performed, to resort to a skin-grafting operation, as described in connection with the mastoid operation. (See Grafting Operation, pp. 810 to 815.) In all obstinate cases the outer wall of the labyrinth should be removed, to establish free drainage. (See Surgery of the Temporal Bone, Bourguet's Operation.)

INJURIES TO THE LABYRINTH; CONCUSSION OF THE LABYRINTH.

Etiology.—The injury may be due to *direct* or to *indirect violence*, more commonly the latter. The violence may be transmitted through the bones of the head to the internal ear, or through the air and ossicles in the middle-ear cavity, where there is a *sudden condensation* of the atmosphere by a great explosion, or the *blow of the hand* over the ear. The bony capsule may be injured while the membranous capsule is unharmed, and *vice versa*. When a *fissure* of the skull passes through the labyrinth, it usually, also, extends to the middle ear and external auditory meatus, although this is not always the case. Great *violence* may produce pronounced aural disturbances without fracture of the bone. In those cases it is probable that there is excitation of the terminal nerve filaments of the labyrinth, small hemorrhages, etc.

Injuries to the labyrinth from powerful *compression of the atmosphere* by explosions, boxing of the ears, etc., may or may not cause rupture of the drumhead. Should the drumhead rupture, however, the labyrinth is probably saved from some of the force of the concussion, as the air in the middle ear escapes through the ruptured drumhead, thus relieving the tension which would otherwise expend itself upon the foot plate of the stapes in the oval window of the labyrinth.

Detonations from heavy ordinances, or loud reports of guns in shooting galleries, produce a great deal of harm to the terminal nerve filaments of the labyrinth by irritation, and result in more or less deafness and tinnitus (Sexton).

Symptoms.—The symptoms vary with the severity of the concussion and the location and character of the lesion. If the concussion is powerful the subject may drop to the ground as though he were shot, and remain in an unconscious condition for several hours, after which conconciousness returns, and he finds himself to be entirely deaf. Or if the concussion is light, he will stagger, but not fall, and be stupid or dazed for a short time, with more or less tinnitus and deafness. There may also be nausea and vomiting, with more or less giddiness. If the blow or concussion causes fracture through the cochlea, the deafness will be pronounced; whereas if it passes through the semicircular canals, the staggering gait will be the prominent symptom.

The hearing for high tones is lost or modified. Diplacusis and hyperesthesia acoustica are sometimes present. The sensibility of the skin of the auricle and meatus may be diminished.

According to Politzer, "a medicolegal decision as to the existence of concussion of the labyrinth can be given only in those cases in which there is a fissure of the temporal bone extending to the external meatus, and in which an injury of the labyrinth may be inferred, either from the discharge of cerebrospinal fluid or from complete deafness and the absence of perception through the cranial bones." In the cases due to compression of air in the external meatus he says no opinion can be given.

It may be of medicolegal importance to establish the degree of impairment of hearing, as the patient may seek redress in the courts. If he does so he will sometimes be tempted to magnify his auditory disability. By the use of a series of tuning-forks, whistles, and other functional tests of hearing a correct diagnosis may be made. It will also be necessary to establish as nearly as possible the condition of his hearing apparatus before the injury. Lateralization of the sound in Weber's experiment to the injured ear signifies that the labyrinth is unaffected, whereas, lateralization toward the sound ear is strongly suggestive of labyrinthine involvement in the injured ear. The loss of high tones in the affected ear also points to labyrinthine disease or injury. Of course, it is necessary to prove or disapprove the presence of labyrinthine disease before the date of the injury. This is not often easy to do. The Rinné test is of little value when there is complete deafness, but may prove of some value when there is only partial deafness.

Treatment.—Rest in bed constitutes the whole of the treatment in most cases, whether there is simple concussion or fracture through the labyrinth. Pain in the ear may be controlled with leeches applied to the mastoid region. Tinnitus of an aggravating character may be relieved by the administration of the bromide of soda. After the acute symptoms have subsided iodonucleoid or the iodide of potassium should be administered to hasten the absorption of the inflammatory exudate.

OCCUPATION DEAFNESS.

It has long been recognized that among those who for a long time have been engaged in certain occupations, especially where continuous

or frequently recurring sounds are heard, there is apt to be more or less deafness. The terminal nerve filaments of the labyrinth, being continuously subjected to irritation, undergo a degenerative change often amounting to complete atrophy, and consequent paralysis of the acoustic nerve. Occupation deafness has been observed among blacksmiths, locksmiths, telephone operators, boilermakers, certain machine-shop workers, weavers, and railway employés. Among this class of workers it is probable that the continuous noise to which their ears are subjected causes an irritation of the acoustic nervous apparatus of the labyrinth, and to the circulatory apparatus as well, which after a long time causes a disturbance of the nutrition of the parts, and finally leads to degeneration, atrophy, and paralysis. Both ears are usually affected.

There are other conditions peculiar to certain occupations, which cause dulness of hearing, as exposure to damp, cold atmosphere, dust, and superheated air. Stokers and engineers are particularly exposed to atmospheric changes, heat, cold, dust, and noxious vapors. They are, therefore, subject to nasal and epipharyngeal catarrh, and its extension to the Eustachian tube and middle ear. Many, after from five to ten years' service on the road, have well-marked dulness of hearing. Numerous observers have written on the subject, and their conclusions are as follows: (*a*) The deafness and tinnitus may be due to the constant vibratory movement of the locomotive, resulting in irritation to the terminal nerve filaments of the labyrinth; (*b*) constant straining of the ears to hear above the noise and roar of the train, is thought by some to cause the deafness; (*c*) cold draughts of air and the heat from the furnace cause epipharyngeal and aural catarrh; and (*d*) the inhalation of the noxious gases and vapors cause irritation and catarrhal inflammation of the nose, pharynx, and middle ear.

The chief symptom of the catarrhal cases of occupation deafness are more less dulness of hearing, tinnitus, and in some cases giddiness. Rinné may be positive or negative according to the degree of deafness present. Hearing by bone conduction is increased. If the labyrinth is also involved the tests are somewhat confused, especially as to the relative length of air and bone conduction, both being diminished. If there is also loss of hearing for high tones, the labyrinth may be safely said to be affected.

SIMULATED DEAFNESS.

There are various motives which lead to simulation of ear disease of one form or another. Hysterical individuals sometimes do it to excite attention or sympathy. Those drafted into the army or being in army service, and desiring to avoid duty, and those injured on railways, streets, and in shops sometimes exaggerate or assume or artificially produce ear disease, in order to collect damages through the courts. It is well, therefore, to briefly outline some of the methods for detecting malingering of this sort.

Tests for Simulated Deafness.—(*a*) First make a careful *objective examination* of the external ear, external auditory meatus, drumhead, and the Eustachian tube. It is a significant fact that in the army most cases of suspected simulated deafness are unilateral. This arises from the fact that a double deafness would have previously attracted attention, whereas a one-sided deafness might have existed without having attracted attention. In other words, it is easier, on this account, to simulate one-sided deafness, hence its greater frequency among malingerers. The malingerer often artificially produces an obvious cause for the deafness he wishes to assume by dropping strong solutions of silver nitrate, carbolic acid, creosote, tincture of cantharides, etc., into the meatus. The skin and drumhead are thus cauterized and simulate in some degree suppurative otitis media. A careful examination will usually reveal the source of the inflammation. If silver is used, a dark-brown stain will be seen; whereas if carbolic acid is used, the bleached skin will aid in arriving at a correct conclusion. A bandage placed over the ear will in these cases lead to a speedy recovery, as the malingerer is unable to continue the caustic applications. Foreign bodies placed in the meatus to simulate deafness and ear disease may be detected by a careful examination.

(*b*) It is in those cases in which there are no objective signs of ear disease that the real difficulty of detecting malingering arises. The would-be patient often studies the subjective signs of labyrinthine deafness so well that, if he is especially shrewd, it is well-nigh impossible to detect him in the assumed deafness. In making the examination of this class of cases the eyes of the suspect must be bandaged, thus rendering it somewhat difficult for him to judge distances in testing with the voice, acoumeter, or watch. If he hears the instrument at greatly varying distances with the deaf ear (the other being tightly plugged) it is fair to presume he is malingering. If, on the other hand, during repeated short testings, he hears at about the same distance, it is fair to presume that he is really deaf.

(*c*) **Erhard's Test.**—When a normal ear is tightly closed a loud ticking watch (the Ingersoll watch) may be heard at three or four feet. The patient should have the supposed deaf ear tightly closed, and when the watch is within three or four feet of the normal ear, he should be commanded to count the beats, which he will, of course, readily do. The sound ear should then be closed, the supposed deaf one being open, and the same test made on the open deaf ear. If when the watch is within two or three feet of the ear he says he does not hear it, it is fair to presume that he is simulating the deafness, as at that distance he would hear the watch with the closed normal ear.

(*d*) **Chimani-Moos Test.**—In one-sided deafness a large vibrating c_2 fork is alternately held at an equal distance from each ear, until the suspected malingerer makes it plain to himself that he hears the fork loudest before the normal ear. The vibrating fork is then placed on the vertex, bridge of the nose, or median line of the incisor teeth, and the patient is asked in which ear he hears the fork the plainest. A

patient with true middle-ear disease on one side will, without hesitation, say that it is plainest on the affected side; whereas a malingerer will hesitate, as he hears it equally well on both sides, or he may say he does not hear the fork at all in the suspected ear. The normal ear should now be tightly closed and the vibrating fork again placed on the median line of the skull, and the malingerer will probably say he does not hear it at all, or but faintly; whereas in true one-sided deafness the patient will say he hears the tone louder in the affected side. This only applies to disease, or simulated disease, of the conduction apparatus. If disease of the preception apparatus is being simulated, the problem becomes more difficult.

(*e*) A common stethescope, having one tube closed with a wooden plug, may be used to detect simulated unilateral deafness. The stethoscope should be adjusted to the patient's ears, the open tube leading to the suspected ear, the closed one to the normal ear. The physician should now speak into the bell of the stethoscope, having the patient repeat what he hears. The instrument should then be removed, the normal ear tightly closed, and the same formula repeated to the patient. He will say he cannot hear, whereas he has already repeated after you, with the normal ear tightly closed with the plugged-arm of the stethoscope. In other words, he heard with his suspected ear through the open tube of the stethoscope (the one leading to the normal ear being closed with a wooden plug), thinking, of course, that he would lead the examiner to believe he heard with the normal ear.

(*f*) The use of four ear specula, two open and two half filled with wax, may be used to detect malingering. The patient should sit with bandaged eyes facing the wall. The two open specula should be simultaneously introduced, one in each ear, and the examiner (behind the patient) should repeat certain words, or numerals, at varying distances, and thus ascertain his hearing distance with both ears open. He should then change the specula using one open and one closed, then two open, then two closed, and so on, noting the distances he hears with the varying formulæ of the specula. In this way the patient will unwittingly reveal the true condition of his hearing apparatus.

Repeated examinations and the striking contradictions made by the malingerer during the various examinations will lead to a correct diagnosis in most cases.

PARESES AND PARALYSES.

Angioneurotic Paralysis of the Auditory Nerve.—This is probably a rare affection, or, at least, it has been rarely recognized and described, and is characterized by a transitory facial pallor, nausea, dizziness, tinnitus, and deafness. The attack lasts but a few minutes, and when it disappears the hearing is perfectly normal. The attacks may occur at frequent intervals.

The treatment consists in the administration of sedatives, tonics, and

the application of galvanism over the cervical sympathetics, which have an intimate anatomical connection with the terminal nerve endings in the labyrinth.

Rheumatic Paralysis of the Auditory Nerve.—This is an obscure affection and difficult to diagnosticate. The diagnosis must largely depend upon the history of rheumatism elsewhere in the body, and upon the involvement of other cranial nerves. It may, however, in rare instances involve the auditory nerve alone. Bing reports a case limited to the auditory nerve, and the clinical picture was as follows: (*a*) Female, aged forty-seven years, exposed to a draught. (*b*) Complete deafness, and tinnitus in the right ear, the left being less affected. (*c*) Weber lateralized to the left ear. (*d*) Inflation of the middle ear did not increase the hearing distance. (*e*) The case ended in recovery in eight days from the internal administration of the iodide of potassium and the application of vessicants to the mastoid region. It should be remarked that in these cases there is an absence of the objective signs of middle-ear disease.

Symptoms.—The symptoms are those given above, with the addition of the history of rheumatism elsewhere in the body, the involvement of the facial or other cranial nerves, and the signs of labyrinthine involvement, as lessened, or loss of, bone conduction. If the vestibular portion of the labyrinth is affected there will be dizziness or a staggering gait; whereas if the lesion is limited to the cochlear portion of the labyrinth, deafness and tinnitus will be the chief symptoms.

Hysterical Paralysis of the Auditory Nerve.—This form of ear disease is usually unilateral, and is characterized by unilateral deafness, with tactile hypesthesia, hyposmia, contracted field of vision, and by diminished sensibility of the skin on the affected side. The Eustachian tube, drumhead, external meatus, and auricle are occasionally hypesthetic on the affected side. Weber experiment: tone lateralizes to the normal ear, bone conduction being diminished on the side of the paralysis. Whispered speech can often be heard at six or eight feet, while the tuning-fork may not be heard at all. This is considered by Hammerschlag as characteristic of hysterical paralysis. The same observer calls attention to the fact that a tuning-fork vibrating at its greatest intensity before the affected ear ceases to be heard, and then after a few seconds is heard again. This, he explains, is due to fatigue of the auditory nerve, which after a few moments' rest perceives the sound again (Politzer).

Slight aural lesions in hysterical individuals may give rise to marked disturbance of hearing. Tinnitus and dizziness, however, are signs of organic labyrinthine disease. In hysterical deafness the degree of deafness varies greatly at different times.

Treatment.—The treatment of hysterical deafness should embrace the relief of any middle-ear disease found, no matter how slight in character, as great improvement, all out of proportion to the apparent lesion, often follows it. The nervous and general systems should be built up by tonic and sedative remedies, outdoor life, bathing, etc. The iodonucleoid or the iodide of potash should be given in three to six grain doses three

times daily. Galvanism of the ear and sympathetic system of the neck may also be used to some advantage.

NEUROSES OF THE AUDITORY APPARATUS; HYPERESTHESIA.

1. **Hyperacuteness of Hearing.**—Oxyecoia is a rare form of hyperesthesia, and is characterized by a temporary ability to hear music, or at least certain tones, at a much greater distance than others do with normal hearing. It is usually caused by alcoholic and tobacco poisoning, and is especially prone to occur in hysterical and neurasthenic persons.

2. **Paracusis.**—Paracusis may be due to a disorder of the nervous apparatus the labyrinth or to a disturbed tension of the drumhead and ossicles of the middle ear. In this condition there is a false interpretation of the pitch of a tone, often amounting to $\frac{1}{4}$ to $\frac{1}{2}$ interval.

Paracusis duplex, or diplacusis, is a variety of disturbed perception of pitch, and is characterized by the hearing of two tones for every sound produced, or in certain cases only for certain tones. It is due to certain unknown influences in the course of acute otitis media, serous middle-ear catarrh, chronic suppurative otitis media, and hyperostosis of the bony capsule of the labyrinth.

Paracusis Willisii is characterized by the ability to hear better in a noisy place, as on a railway train, street car, and a machine shop. Its etiology is still a mooted question, although it is commonly present in sclerosis of the middle ear and in hyperostosis. Some hold that the improved hearing in the presence of noise is due to the increased excitability of the terminal nerve filaments of the labyrinth, while others hold that it is due to the mechanical vibration of the bone and secondarily of the terminal nerve filaments, which increases their auditory power. Still others advance the theory that it is due to a shaking and loosening of the ossicles of the middle ear that accounts for the phenomena. The vibration of the cranial bones and the attending stimulation of the nervous apparatus and fluid contents of the labyrinth and cerebrospinal spaces seem to the author to be the most rational explanation. We know from personal observation that mechanical vibration applied to the spinal column and the head improves the hearing in some cases. Whether this is due to a stimulation of the nutritional centres, or to a stimulation of the nervous apparatus of the labyrinth, is still an open question. We know also from personal observation that if these patients are placed in bed and given passive exercise (massage) and wholesome food for a few weeks, that their hearing will improve.

3. **Hyperesthesia Acoustica.**—This condition is characterized by a disagreeable sensation when musical tones or sounds are heard. The condition is usually present in anemic and hysterical individuals, and in those convalescent from severe illness. It may be present in certain forms of neuroses, as hemicrania and trigeminal neuralgia. It is also one of the manifestations attending the administration of quinine and salicylic acid.

4. **Tinnitus Aurium, or Subjective Noises.**—This is one of the commonest ear symptoms, and has been repeatedly referred to in this work in the descriptions of numerous ear diseases. Its exact etiology is obscure in spite of the large amount of literature on the subject. Various theories have been advanced, explaining its cause, the one by Shambaugh being the most lucid and satisfactory.

He advances the interesting and ingenious theory that, "In the first place, the character of tinnitus aurium is usually that of an indefinite sound, like the wind in the forest or the rushing of water, sounds made up of a great complexity of tones and with no definite pitch. Clinically, these subjective sounds arise from a variety of pathological conditions. One of the best known causes of tinnitus is pressure applied to the conducting apparatus, so as to push the foot plate of the stapes into the oval window. This results in tinnitus aurium of the indefinite character described above. What actually takes place when the stapes is thus forced into the oval window is an increase in the pressure of the intralabyrinthine fluid. The result of this alteration in pressure must be a disturbance of the membrana tectoria (see Anatomy and Physiology of the Labyrinth), which has apparently the same specific gravity as the endolymph when the latter is under normal pressure. The hairs from the hair cells, as I have shown, normally penetrate into the lower surface of the membrana tectoria. Any disturbance in this membrane, however slight, would, therefore, alter the normal relations existing between the membrane and the hair cells. It seems that such an alteration from the normal relation between membrana tectoria and the hairs of the hair cells would constitute a stimulation of these cells. When the foot plate of the stapes is pushed into the oval window there would result a slight stimulation of perhaps all the hair cells in the cochlea. The result would be exactly what we meet with clinically, a tinnitus aurium of an indefinite character, like the wind in the forest or the roar of a sea-shell. When a sudden increase or decrease in the blood pressure results in tinnitus aurium the cause is the same as when the stapes is pushed into the oval window. The explanation for the increase or decrease of the intralabyrinthine pressure is here quite evident. The tinnitus aurium arising from the administration of certain drugs is also plausibly explained in the same way as due to an alteration in the blood supply to the labyrinth with resulting alteration in the pressure of the intralabyrinthine fluid. The tinnitus occurring in Ménière's disease, where there has been an escape of blood into the cochlea, is also similarly accounted for by this conception of the physiology of tone perception. The disturbances in the function of hearing arising from an injury produced by a shrill whistle, or an explosion near the ear, are also readily explained. In the first place, when a permanent disturbance in hearing is thus produced, it can be readily accounted for by a partial severance of the relation between the membrana tectoria and hair cells, so that the hairs from a greater or smaller number of these cells project free in the endolymph and do not come in contact with the membrana tectoria, and therefore cannot receive the stimulation from impulses passing through the endo-

lymph. On the other hand, when there results from such an injury a permanent tinnitus aurium, this is explained by a partial, not complete, severance of the membrana tectoria from the hair cells over a certain area. This alteration of the relation existing normally between the hair cells and membrana tectoria may result, as we have repeatedly pointed out, in a stimulation of these cells. This explanation appears all the more rational since the pitch of the tinnitus is often approximately that of the whistle which originally produced the injury."

The external conditions which influence tinnitus are those which influence catarrhal diseases of the upper respiratory tract, namely, sudden changes in the weather and temperature, living in damp places, improper clothing, etc. Bodily conditions, as fatigue, exhaustion from heat or undue exposure to inclement weather, and bodily depression from overmental application, also aggravate the subjective noises.

The *character* of the noises is as various as noises themselves, the usual form being a singing, whistling, chirping, popping, crackling sound, or like the noise of a railway train in the distance. Many other noises are described by patients. They may be intermittent or continuous. The remissions usually occur while the patient's mind is engrossed with other matters, hence they are less troublesome in the daytime. Some patients are so distressed by the noises that they are driven to desperate measures, even to suicide.

In some cases the noises increase in proportion to the deafness, in others they cease with marked deafness, while in still others they continue to increase after the deafness is absolute. They may appear in persons who are not deaf, but who are nervous, or exhausted from overmental or physical exertion, or from grief.

The Hearing of Voices and Music.—Human voices and musical melodies are sometimes heard by persons who have some affection of the cortex of the brain, though rarely or never by subjects with an uncomplicated ear disease. An existing ear disease may aggravate the condition existing in the cortex of the brain, hence the cure of the ear disease is often attended by an improvement of the hallucinations. Some persons hear musical melodies repeated over and over, and are much annoyed thereby. The subjective hearing of human voices is more serious, and often the forerunner of melancholia, or progressive paralysis.

Prognosis and Treatment.—The *prognosis and treatment of tinnitus* is embraced in the various diseases in which it occurs as a symptom. It may be said in general, however, that it is comparatively good in those cases of simple middle-ear and tubal catarrh, that it is more unfavorable in hyperostosis and labyrinthine diseases, in noises of cerebral origin, and where the arterial noises have existed for a long time. Paracusis Willisii is usually taken to indicate a well-marked sclerosis of the middle ear, hyperostosis of the bony capsule of the labyrinth, and the prognosis is unfavorable except where suitable remedial measures are used early. In those cases in which human voices and musical melodies are heard the prognosis is very grave, except in those rare cases in which the relief of the noises follows the cure of the middle-ear disease.

The *treatment* of subjective noises is as broad as the subject of ear and brain diseases themselves, hence further consideration will not be given to it here.

WORD-DEAFNESS OR SENSORY APHASIA.

This form of deafness is characterized by the ability to hear, with the loss of the power to distinguish words, and is thought to be due to a lesion of the cortex in a portion of the middle convolution of the left temporal lobe, or in the left gyrus of that lobe. It may be questioned, however, whether the auditory (acoustic) centre is so restricted in its distribution. When present, it is generally due to an encephalitis, an exudate following a hemorrhagic pachymeningitis, brain tubercle, or to an embolic softening of the brain.

Types of Word-deafness.—(*a*) *Amnesic aphasia* is characterized by the loss of memory for things, or the patients call objects by their wrong names. (*b*) *Monophasia* consists in the naming of all objects to which the attention is directed by the same name. (*c*) *Amnesic agraphia* is an inability to write the words spoken to the patients, or the names of objects placed before them. (*d*) Still *others* hear and understand what is said to them, but are unable to repeat it. (*e*) *Amusia* is a term introduced by Knoblauch to indicate deafness for musical tones. It occurs more frequently than word-deafness, and is probably due to a lesion of the first and second convolutions of the left temporal lobe in right-handed persons. Word-deafness and tone-deafness may exist at the same time. In tone-deafness the amusia varies in degree from absolute loss of hearing for musical tones to false interpretations of them.

DEFECTS OF HEARING DUE TO INTRACRANIAL TUMORS.

Brain tumors, especially of basilar origin, may give rise to disturbances of hearing by pressure upon, or stretching of, the auditory nerve fibers, and by giving rise to an ascending neuritis of the auditory nerve. A lymph stasis at the origin of the auditory nerve may also cause aural disturbances (Gradenigo). This condition is similar to that which occurs in the optic papilla during an increase of intracranial pressure.

Symptoms.—The symptoms are unilateral tinnitus aurium, and deafness, more or less complete, and dizziness. Other symptoms not expressed through the auditory apparatus are a feeling of tightness in the head, glimmering or dull vision, pain or full feeling on the side of the head corresponding to the location of the tumor, slow pulse, choked disk, motor and sensory paralysis over the areas supplied by the other cranial nerves, which are also usually more or less involved.

Diagnosis.—The diagnosis must be made chiefly by the disturbances arising through the lesions of the other cranial nerves, as the aural symptoms are not characteristic of this form of ear disease. An early diagnosis cannot, therefore, often be made. Facial paralysis and

retained perception for the tuning-fork, watch, and acoumeter through the cranial bones, together with dizziness, tinnitus, and deafness, are significant symptoms. The perception of the forks, watch, etc., through the cranial bones exclude labyrinthine disease, even of a mild type. The perception for high tones often remains unaffected, while in some cases it is diminished. The age of the patient should be taken into account in connection with the tests of bone conduction and the hearing for high tones. If the patient is more than fifty years old there is a physiological diminution in the perception by bone conduction, as well as a restriction of the upper limit of hearing. Hence, in a case with the above aural symptoms, in which there is a suspicion of brain tumor, the presence of a slight diminution of hearing by bone conduction and the loss of hearing for the higher tones would not necessarily lead to the conclusion that the labyrinth was affected by the presence of a brain tumor. As first stated, the chief diagnostic guide is the pareses or paralyses of the other cranial nerves, the facial nerve usually affording the most direct and certain information. A slight paresis and anesthesia of the skin over the area of nerve distribution, when found in conjunction with deafness, tinnitus, and dizziness, usually point strongly to an ear disturbance having its origin in tumor of the brain.

NEOPLASMS OF THE INTERNAL EAR.

New-growths in the internal ear may be primary (rare) or secondary. Primary growths at the root of the acoustic (auditory) nerve have been reported, but nearly all accurately reported cases have been secondary. Epitheliomata and malignant round-cell sarcomata may extend from the middle ear to the labyrinth, and destroy the cochlea, vestibule, or even the whole of the petrous portion of the temporal bone. Neuromata of the auditory (acoustic) nerve have also been observed. Cavernous angiomata of the petrous portion of the temporal bone has been reported by Politzer, and is extremely rare.

The symptoms vary with the location and size of the growths, and are deafness, tinnitus, dizziness, staggering gait, nausea and vomiting, together with other extraneous symptoms due to lesions of the other cranial nerves.

LOCOMOTOR ATAXIA DEAFNESS.

Disturbances of hearing occurring in the course of locomotor ataxia are due to an atrophy of the auditory nerve. The atrophy may affect the nervous apparatus anywhere from its cortical origin to its distribution in the labyrinth. According to various statistical reports, the hearing is affected in tabes dorsalis in from 1 to 80 per cent. of the cases recorded. The aural symptoms develop gradually, seldom rapidly. The tinnitus is always present and almost unbearable. The affection is usually bilateral, and dizziness is present in about 65 per cent. of the

cases. The author recently examined a case in which there was deafness, intolerable tinnitus, and dizziness. The bone conduction and upper range of hearing were diminished, but not more than the age of the patient (sixty-five years) would account for. Rotating the head on its various axes with the eyes closed did not increase the dizziness. The appearance of the drumheads was normal. The hearing for low, deep-toned tuning-forks was normal, Rinné negative, and both ears were affected.

CHAPTER LI.

DEAF-MUTISM.

HOLGER MYGIND'S elaborate and classical treatise on deaf-mutism opens with the following paragraph:

"**Definition.**—*Deaf-mutism,* strictly speaking, signifies the abnormality which is characterized by the co-existence of deafness and dumbness. Various circumstances necessitate, however, a more limited definition. Deaf-mutism may, therefore, be defined as a pathological condition dependent upon an anomaly of the auditory organs, either congenital or acquired, in early childhood, causing so considerable a diminution of the power of hearing as to prevent the acquisition of speech; or, should speech have been acquired before the occurrence of the loss of hearing, it is preserved by the aid of hearing alone. Individuals exhibiting this pathological condition are described as *deaf-mutes*, even when speech has been acquired by a special system of instruction."

The foregoing definition will be observed in the consideration of this subject.

Historical.—It is interesting to know, as Mygind has shown, that deaf-mutism has been referred to in literature from the time of Exodus (fourth chapter and second verse) was written. Herodotus, Hippocrates, Aristotle, Pliny, Gellius, and others of the ancient period refer to it.

Cananus, Pedro de Ponce, Andreas Laurentius, and Zachias refer to it in the Middle Ages.

A gradual change of opinion as to the relationship between hearing and speech took place. In the ancient period the idea prevailed that it was due to the inability to use the tongue (Hippocrates and Aristotle). Later, Pliny said, "The man who is born without the power of hearing is also deprived of the power of speech, and none are born deaf who are not also dumb."

During the Middle Ages the influence of Aristotle's writings were so potent that little progress, beyond the opinion expressed by him, was made. Cardanus, 1501 to 1576, first distinctly stated the true relationship, *i. e.*, that deafness is the principal and primary cause of deaf-mutism.

During the last century the subject was placed upon a scientific basis, chiefly through the writings of Itard, Schmalz, Wilde, Meissner, Toynbee, von Tröltsch, A. Hartman, Lemcke, and Mygind.

It is true that institutional work and statistical bureaus have aided very materially in the evolution of the subject. The classical work of Mygind probably represents the most advanced and correct statement

on the subject that has been given, and it is chiefly from his work that I glean the data for this chapter. I also refer directly to the works of von Tröltsch and Toynbee.

Classification.—Deaf-mutes may be classified according to the degree of deafness as:

(*a*) *True deaf-mutes,* or those who are totally deaf to speech, and must depend entirely on the other senses to acquire its use.

(*b*) *Semi-deaf-mutes,* or those who have slight power of hearing, or who retain slight speech acquired before deafness supervened.

Some confuse those who, for other reasons than deafness, have lost the power of speech with deaf-mutism. *It should, therefore, be distinctly understood, without question, that deaf-mutism refers to those who have lost or failed to acquire speech on account of deafness.*

Another classification, which is perhaps better as a practical working basis, is that adopted by Mygind, namely:

(*a*) Congenital deaf-mutism.

(*b*) Acquired deaf-mutism.

The first class refers to those who are born with some defect of the organ of hearing, which, according to modern statistics, includes about 50 per cent. of all the cases. Mygind thinks this estimate too high, as many of the so-called congenital cases are, in all probability, due to some intercurrent disease of the ear which destroys the hearing before articulate speech is acquired. While my observations have been comparatively limited, I have nevertheless seen enough of these cases to know the difficulties to be encountered in determining whether some of them belong to the congenital or to the acquired class. I am, therefore, inclined to coincide with Mygind in thinking that 50 per cent. is too high an estimate to be placed upon the relative proportion of congenital as compared with the acquired types of deaf-mutism.

The *relative proportion* of deaf-mutes to the total population of the various countries in which statistics are to be found varies from 34 (Holland) to 245 (Switzerland) per 100,000 inhabitants. The average in European countries is 79, while in the United States it is 68 per 100,000 inhabitants.

Etiology.—The great variations in the relative number of deaf-mutes in the different countries seems to point to certian localities as predisposing to it. *Old geological* (Escherich) *formations,* as found in the Alps, were formerly thought to be the cause, but more careful investigations have shown this to be incorrect. Social and hygienic (H. Schmaltz) conditions peculiar to the various countries more nearly account for the great variations. In Switzerland, where the rate is so high, it is due to the endemic cretinism so prevalent there. This type of deaf-mutism is not included in the consideration of this subject.

Climate probably has no influence.

Unfavorable *social* and *hygienic* conditions play a very important part in the causation of deaf-mutism.

H. Schmaltz emphasizes this in his work on deaf-mutism in Saxony. In conclusion he says: The industrial population, and especially that

part of it which is worse off from a pecuniary point of view—in fact, all who are in danger of degenerating both morally and physically on account of insufficient means, or poverty, and who, consequently, are unable, or unwlling, to take the necessary care of their children—all such persons exhibit the highest percentage of deaf-mutes among their descendants. Finally, we found that when, in addition to all these unfavorable conditions under which children are born, they are brought up by a family which, from various reasons, is perhaps already more or less degenerated, and have to undergo all sorts of diseases in infancy without having sufficient power of resistance, then deaf-mutism is an only too common result."

Heredity undoubtedly influences the number of deaf-mutes. Mygind very tersely expresses the present status of our knowledge on this point in the following words: "Deaf-mutism is comparatively frequent among the relatives of the deaf-mutes; it is least frequent in the direct ascending line (grandparents, parents); more frequent in the collateral branches (great-uncle, great-aunt, uncles, aunts, grandparent, cousins, parents' cousins, and second cousin); and most frequent by far among the brothers and sisters of the deaf-mutes. This is in exact accordance with the result of an investigation into the appearance of deaf-mutism among the relations of congenital deaf-mutes; therefore, and from many of the facts above mentioned, we are justified in supposing that the manner in which deaf-mutism appears in different generations is a result of certain qualities appertaining to its congenital form."

It is not assumed that deaf-mutism *per se* is transmitted by hereditary influences, but that certain anatomical or nervous states are retained to some extent, and that these may result in deaf-mutism—that is, deaf-mutism is influenced by the transmission of a predisposition to certain ear diseases and to certain nervous disorders. These, in combination, tend to produce deaf-mutism.

Consanguineous marriages seem to influence the number of deaf-mutes, as is shown in the following table:

FORTY-SEVEN MARRIAGES BETWEEN BLOOD RELATIONS PRODUCES SEVENTY-TWO DEAF-MUTES.

1	marriage	between	aunt and nephew	produced	3	deaf-mutes.
4	marriages	"	uncle and niece	"	11	"
26	"	"	first cousins	"	38	"
16	"	"	second cousins	"	20	"

Statistics go to prove that the influence of consanguineous marriages is entirely limited to congenital deaf-mutism.

Various diseases in parents, as alcoholism, syphilis, general debility, epilepsy, insanity, etc., are etiological factors in the production of deaf-mutism. The offspring of such parents do not receive in utero the vital energy necessary to resist the vicissitudes of life after birth. They are, therefore, more liable to be injured by infections and nervous diseases than the offspring of healthy parents. It may be said in this connection, however, that the parents of deaf-mutes are often remarkably healthy and robust individuals.

Hemophilia and deaf-mutism are rather commonly associated among the offspring of marriages producing a large number of children.

The death rate is higher among children in families in which there are deaf-mutes, probably on account of the stigmata of degeneracy, and because suppurative otitis media adds to the mortality rate.

Mygind cites statistics to show that first births produce more deaf-mutes than either the second, third, fourth, or fifth. Other weaknesses are also more common among the first born.

Maternal *impressions* do not appear to exert a marked influence in the production of deaf-mutism.

Having considered some of the remote causes of deaf-mutism, we will next turn our attention to the more immediate causes.

Immediate Causes of Deaf-mutism.—The *age* at which most cases of deafness occur in the acquired type is from the first to the fifth years, more occurring in the second and third years. In the United States the greater number occur in the third year.

Brain diseases, more particularly simple meningitis and epidemic cerebrospinal meningitis, are the chief causes of the acquired deaf-mutism. From 12 to 26 per cent. of the European cases have been attributed to epidemic cerebrospinal meningitis. Moos and Knapp were the first to call attention to this disease as one of the causes of deaf-mutism.

Deafness may occur during epidemic cerebrospinal meningitis resulting from middle-ear or labyrinthine lesions. The former occurs more often, but is not so pronounced nor so permanent as that due to the involvement of the labyrinth. Deafness of middle-ear origin does not so often produce deaf-mutism on this account. Labyrinthine involvement usually occurs about the second week of epidemic meningitis, although it may occur at a much later period (Knapp, Mygind). The deafness occurs suddenly, in contradistinction to that in middle-ear deafness. Postmortem examinations have shown most of them to be due to inflammation of the membranous labyrinth. "This process leads partly to the more or less complete destruction of the contents of the labyrinth, and partly to regeneration of tissue. This new tissue may be either fibrous, calcareous, or osseous, and may fill the normal cavity of the labyrinth either completely or partially" (Mygind).

The original cause of the disease is undoubtedly some microörganism which enters through the ear, nose, or epipharynx, although definite data is not yet at hand to confirm this statement.

The *equilibrium* is often disturbed in deafness due to brain disease, as pointed out by Moos. This is due to the involvement of the semicircular canals and other apparatus of the labyrinth. This may endure for years.

Other *acute infectious diseases,* as scarlet fever, measles, typhus and typhoid fevers, diphtheria, smallpox, vaccination, chicken-pox, erysipelas, dysentery, influenza, malaria, whooping-cough, mumps, croupous pneumonia, and rheumatic fever directly or indirectly cause infantile deafness. The inflammation first attacks the mucosa of the middle ear,

which ulcerates, the bone beneath becomes carious, and the meninges and labyrinth are thus exposed to infection. The ossicles of the middle ear, being covered by the mucous membrane, undergo the same changes. If the destructive changes do not involve the labyrinth, the deafness is not usually profound enough to cause deaf-mutism. If it involves the labyrinth, the same changes described under cerebrospinal meningitis take place and result in complete and permanent deafness. If this occurs before speech is acquired, the child becomes a deaf-mute.

In scarlet fever, measles, and kindred diseases the infection enters the tympanum through the Eustachian tube. The labyrinth is usually invaded through either the oval or round windows, as has been shown in numerous autopsies by the scar on the membrane. In some cases, however, it appears that the middle ear is not involved at all, the drum membrane being normal. It is probable in these cases that the infection reached the labyrinth by metastasis.

Smallpox does not account for many cases of deaf-mutism in those countries where compulsory vaccination is in vogue. It is barely possible that vaccination is a cause of deaf-mutism.

Connor collected the literature of labyrinthine diseases caused by mumps up to 1884, and found 33 cases, 9 of which were fifteen years of age or less.

Certain constitutional diseases, more particularly syphilis, scrofula, and rickets, are occasional causes of deaf-mutism. Inherited syphilis causes it more often than is shown by the statistics, as it is difficult to ascertain the data concerning this affection.

Fright, lightning-stroke, sunstroke, quinine poisoning, colds in the head, sudden immersion in water, and traumatisms occasionally cause deaf-mutism. One or more of the foregoing conditions, singly or combined, cause acquired deaf-mutism. They have been given without the full data to confirm them, as the scope of this volume will not permit. A fuller knowledge of the causes of deaf-mutism should be prevalent among physicians, as it is to them the parents will first appeal for information and relief. Many of these cases may be so educated as to make them useful members of society and a source of gratification to themselves and to their parents, if the needed advice or attention is given them at the proper time, *i. e.*, while their minds are still in the imaginative and perceptive stages of development. (See Lip Reading.)

Pathology.—Reliable postmortem examinations in 139 cases of deaf-mutism are on record. From these the following facts are gleaned (Mygind): The changes in the external ear and the auditory meatus will not be considered, as they could have but little to do with the causation of deaf-mutism. In the drumhead, perforations, calcareous deposits, adhesions, thickening, and entire absence have been found.

In the *middle ear* adhesive processes, calcifications, and ossification from intense inflammation have been found. The oval window is sometimes filled in with a mass of bony tissue (hyperostosis), while the round window is contracted in size. The membrane of the round window is sometimes thickened, or thinned, scarred, calcareous, or absent.

Osseous masses in the attic and other portions of the middle-ear cavity are found. Caries of the bony walls of the middle ear from chronic suppurative inflammations are present in some.

The ossicles are ankylosed, bound down by adhesions, necrotic, or entirely destroyed, from suppurative inflammatory processes, in a considerable number of cases. One or more of the ossicles may be absent, and the others present, the stapes alone being absent in a number of cases.

When atrophy of the *ossicula auditus* is present, it is probably of congenital origin.

Ankylosis of the ossicles is very commonly present.

Atrophy and *caseous degeneration* of the tensor tympani and stapedius muscles is often present. The chorda tympani nerve is also sometimes absent.

The *mastoid process* is found to be affected, as elsewhere described under suppurative diseases of the middle ear and mastoid process. It is sometimes absent from arrested development.

The *Eustachian tubes* are sometimes obstructed by fibrous or osseous tissue, as a result of repeated inflammations.

The Labyrinth.—The most frequent pathological change found in the labyrinth is the deposit of osseous tissue from inflammatory processes. This is sometimes so extensive as to completely obliterate the labyrinthine canals (Mygind), and has given rise to the idea that there was congenital absence of the labyrinth from arrested development (Montain, Michel, Schwartze, Moos). Chalky pigment and fibrous deposits are also found.

Absence of the auditory nerve and labyrinth (partial or complete) are also reported. In one of Mygind's cases the labyrinth was completely filled with osseous tissue, except at certain portions where pus was present. It was due to a suppurative process following scarlet fever.

The membranous labyrinth may be congenitally absent, as shown by Nuhn.

The *vestibule* (excepting its aqueductus) is rarely involved, even in congenital cases. When present, the changes are inflammatory in origin. Pathological changes in the contents of the membranous vestibule have often been found.

The *aqueductus vestibuli* may be distended, in which case the cochlea is also affected (Ibsen), while the aqueductus is not affected, thereby suggesting an intimate relation between the aqueductus and cochlea rather than the vestibule. Habermann explains the distention of the aqueductus vestibuli as being due to pressure in hydrocephalus, especially when the petrous portion of the temporal bone is rachitic.

The *semicircular canals* are quite commonly affected.

Symptoms.—*Deafness* may be partial or complete. If partial, there may be *hearing* for sounds, noises, voice, or speech. One child, for example, may hear a loud noise and not hear speech, or *vice versa;* or he may hear the voice and not hear articulate speech. Again, he may hear tones of a certain pitch and not hear those of another pitch.

As stated in the beginning of this chapter, the best classification is (*a*) true deaf-mutes, and (*b*) semi-deaf-mutes. In other words, into those who have partial hearing and those who have total absence of hearing. It is often difficult to determine this point in young infants, for obvious reasons. In older ones it can be usually done by the use of bells, loud whistles, clapping hands, etc. The child will blink the eyes, or show by a change in its expression that it hears.

A more accurate method of testing older deaf-mutes may be made with tuning-forks and whistles. They should be tested for hearing by both air and bone conduction. Hearing by air conduction is tested by holding the vibrating fork near the external auditory meatus and noting the expression of the child; bone conduction is tested by placing the handle of the vibrating fork on the mastoid or the vertex of the head, the expression of the child being meanwhile watched for signs that he experiences a novel sensation. Other instruments, as the watch and the Politzer acoumeter, may be used if there is considerable hearing present. The voice, especially the articulate vowels, are used, being spoken close to the patients' ears, care being exercised to prevent them seeing the movements of the lips. If they hear the vowels, consonants and words may also be utilized for this purpose.

Semi-deaf-mutes hear better at times than others, for the same reasons that those with less pronounced middle-ear disease have variations in hearing.

The various reports as to the relative number of the totally deaf and partially deaf in the various statistical publications are not reliable, as different tests have been used to determine these facts. There are more cases of profound or total deafness among the acquired than the congenital cases, probably on account of the greater severity of postnatal processes in the ear.

A very significant fact has been announced by Urbantschitsch, namely, that children who had previously reacted to no sound whatever, after having been subjected to certain acoustic exercises, were capable of hearing. This points to the fact that a sensory tract is developed by use. Its powers, or functions, may lie dormant for years, and then be aroused to activity and development. The fact that a child never has heard is not necessarily proof that it never will.

Mutism may be the result of the deafness, or it may be due to the same influences which caused the deafness. There may be an arrested or perverted development of the vocal organs, coincident with the disturbed development of the ear; or aphasia may be due to a congenital or acquired lesion of the brain. If the speech centres of the brain are injured at the same time the ear is affected, the child can never be taught to speak clearly.

The age at which deafness must occur to produce mutism is not to be stated arbitrarily, as the capacity to learn speech varies greatly in different children. Hartmann says that if deafness occurs before seven years of age, mutism is apt to follow. The slight speech already acquired will gradually disappear unless special pains are taken to cultivate the faculty of speech.

The *speech of deaf-mutes* is peculiar, lacking in proper accentuation, which renders it monotonous. The respiratory act is deficient, and the voice feeble. The greater the deafness the more pronounced the peculiarities of the speech become. True deaf-mutes, as well as semi-deaf-mutes, may be taught articulate speech, which is known as "articulation." Deaf-mutes experience great difficulty in retaining "articulation" when they leave the school-room and mingle with those who can scarcely understand them. *Articulation* is quite different from ordinary speech, and it is only after hearing it used to a considerable extent that one learns to understand it. This is one of the difficulties in the way of its more general use among deaf-mutes. Lip reading is learned at the same time as articulation, but, as it requires close attention and good sight, it is also often abandoned when contact with the world at large is established.

Other ear symptoms, as tinnitus, giddiness or staggering gait, and otorrhea, are present in a certain number of deaf-mutes. Otorrhea is quite common, especially among the acquired cases.

Sequelæ.—An impairment of the mental faculties may or may not be present. When it is remembered that a deaf-mute is barred from many avocations, it is easy to understand that ambition is thereby hindered in its expression. The temptation to idleness and dependence upon those more fortunate than himself often stultify his physical and mental and moral faculties. The morbid processes causing the deafness may also impair other portions of the brain, and thus impair the mental faculties. About 50 per cent. of those who are deaf-mutes are notably deficient in mental power.

The laryngeal muscles are slightly atrophied from non-use in deaf-mutes; otherwise the larynx is usually normal.

The *lungs* of deaf-mutes seem to be less resistant than those of other children, as shown by the fact that so many of them die of tuberculosis. This is still further shown by stethoscopic examinations. Their breathing is more superficial and less rhythmical than in normal children. This is true of those who have defects of speech, as stammering, with normal ears.

Tuberculosis, scrofula, sterility, left-handedness, and diminution of muscular energy are quite commonly found among deaf-mutes.

The auricle is rarely malformed in deaf-mutes, as it develops independently of the internal ear. The external meatus and membrana tympani show such changes as are incident to middle-ear diseases in general. The same is true of the Eustachian tubes and mastoid processes.

Adenoids and catarrhal affections of the nose and epipharynx do not seem to be more common among deaf-mutes than in other children. That there is a direct relation between infections which enter the middle ear through the epipharynx and Eustachian tubes there can be no doubt. The same irritation causes the adenoid tissue to enlarge, a fact which explains the apparent etiological relationship of adenoids to deaf-mutism.

Boucheron advances the ingenious theory that deaf-mutism may be caused by *otopiesis*, meaning thereby deafness by "producing exhaustion of the air in the middle ear as the result of the closing of the catarrhally affected Eustachian tube, which process, again, causes overpressure in the inner ear, and consequently degeneration of the terminations of the auditory nerves" (Mygind).

There are other abnormalities coincident to deaf-mutism, as of the cranium, the eye (retinitis pigmentosa, hemeralopia, "hen-blindness," panophthalmia, etc.), thyroid gland, nerves, and bones. They are largely the result of the same influences which primarily cause deaf-mutism.

The relationship between idiocy and deaf-mutism is not that of cause and effect, as they are both the result of the same primary influences. Deaf-mutism does not cause idiocy.

Insanity is estimated (Wines) to be four times as common among deaf-mutes as in individuals in general. Mygind shows that this is probably due to the isolated social position and mental depression, which naturally attends the loss of one of the chief senses.

Diagnosis.—The diagnosis is easy in most cases, and is based on the following facts:

(*a*) Deafness so pronounced that speech cannot be heard.

(*b*) Deafness dates from birth or before the seventh year.

(*c*) Deafness and fragmentary speech (semi-deaf-mutes).

In infants it is difficult to make a diagnosis, as the infant does not yet speak, and it is difficult to determine if it hears. Loud bells, clapping of hands, whistles, etc., should be used without letting the child see them, noting the blinking of the eyes or other signs that it has recognized the noises. A negative result is not, however, conclusive of deaf-mutism. Hartmann has called attention to the fact that some children do not have the organ of hearing fully developed at birth, the development being completed at the first year of extra-uterine life.

Simple mutism (aphasia) may be mistaken for deaf-mutism upon casual examination, although it is seldom congenital or acquired in infancy. Examination will show that hearing is present.

Simulation of deaf-mutism and hysterical deaf-mutism are rarely seen.

Prognosis.—A few well authenticated cases are recorded in which the hearing was improved. The great majority, however, are not thus favorably affected. The number of cases reported by men of the highest standing, as being so much improved that they regained enough hearing to carry on conversation with their fellows, warrants the use of every means within our power to alleviate all ear affections, with the hope that those under our care may also be thus favorably influenced. Some cases undoubtedly improve spontaneously.

Speech will generally improve in proportion to the improvement in hearing.

Treatment.—The treatment should be such as would be given to similar ear affections in those who are not deaf-mutes. Suppurative disease should receive special attention, to prevent it spreading to

neighboring organs. Postnasal adenoids and other diseased processes of the nose and throat should receive appropriate attention according to the methods described elsewhere in this work.

After having done all that can be done to improve the organ of hearing and the general system, the child should be sent to some institution of reputable standing, where he can receive suitable training in the acquirement of speech or other means of communication. Here he will also receive instruction in useful knowledge and manual training, which will fit him for a place in social life.

The prevailing methods of instruction are known as the German and French methods. The first is probably the best for a majority of deaf-mutes, as it teaches them articulate speech. There seems to be no doubt that the use of the vocal organs stimulates the development of the brain and motor tracts. Makuen has called attention to this fact. (See Defects of Speech.) The French method teaches communication by means of signs. This is probably well adapted to some cases. The question of methods should, however, be left to those who are more intimately concerned to decide. It is not the physician's province to train these unfortunate children. His duty is to relieve the physical conditions as nearly as possible and then recommend the parents to send the child to some reputable institution for deaf-mutes, assuring them that only in this way will he be fitted for a useful place in society.

LIP READING.

Deaf-mutes, and persons so deaf as to understand conversation with difficulty, should be taught lip reading whenever possible. It has long been known that persons partially deaf watch the face of the one addressing them, and, by combining what they imperfectly hear with the movements of the lips, the facial expression, and the gestures of the speaker, they are enabled to understand what was being said. This suggested the advisability of reducing lip reading to a scientific basis, and schools for this purpose are now established in nearly all large cities.

The acquirement of facility in lip reading necessitates the closest application on the part of the student, and the most painstaking and persistent effort on the part of the teacher; hence, there is little hope of success outside of a special institution for this purpose. The physician cannot give adequate attention to such patients, and he should recommend that they be sent to a school at as early an age as possible, as orthewise the patient will be greatly handicapped in the pursuit of his business in later life. As there are many charlatan schools advertising to give such instruction, the physician should first make diligent inquiry as to which are conducted upon scientific lines, and then recommend one of them to the parents of the patient.

Lip reading may also be profitably studied by adult deaf persons whose early education in this respect was neglected.

INDEX.

A

D

E

F

G

H

I

M

N

O

P

Q

T

U

V

W

Ballenger, W.L.
Diseases of the nose, throat and ear,

NAME 46890

DATE DUE

MAY 30 1921
JUN 30 1921
OCT 1 1923
DEC 18 1959